

Direct Adhesive Pin-Retained Restorations for Severely Worn Dentition Treatment: A 1.5-Year Follow-Up Report

Camila Lima de Andrade¹, Thais Marques Simek Vega Gonçalves¹, Ícaro Leite dos Santos², Michel Silva Barros², Nubia Rafaela Ribeiro Araújo², Altair Antoninha Del Bel Cury¹

¹Department of Prosthodontics and Periodontology, Piracicaba Dental School, UNICAMP – University of Campinas, Piracicaba, SP, Brazil
²Department of Prosthodontics, Dental School, UFPA – Federal University of Pará, Belém, PA, Brazil

Correspondence: Profa. Dra. Altair Antoninha Del Bel Cury, Avenida Limeira, 901, 13414-903 Piracicaba, SP, Brasil. Tel: +55-19-2106-5294. e-mail: altcury@fop.unicamp.br

Excessive occlusal surface wear can result in occlusal disharmony, functional and esthetic impairment. As a therapeutic approach, conventional single crowns have been proposed, but this kind of treatment is complex, highly invasive and expensive. This case report describes the clinical outcomes of an alternative minimally invasive treatment based on direct adhesive-pin retained restorations. A 64-year-old woman with severely worn dentition, eating problems related to missing teeth and generalized tooth hypersensitivity was referred for treatment. Proper treatment planning based on the diagnostic wax-up simulation was used to guide the reconstruction of maxillary anterior teeth with direct composite resin over self-threading dentin pins. As the mandibular remaining teeth were extremely worn, a tooth-supported overdenture was installed. A stabilization splint was also used to protect the restorations. This treatment was a less expensive alternative to full-mouth rehabilitation with positive esthetic and functional outcomes after 1.5 years of follow-up.

Key Words: tooth wear, dentinal pins, occlusal vertical dimension, full-mouth rehabilitation, case report.

Introduction

Tooth wear is a common and gradual process mainly resulting from masticatory activity commonly required by coarser diet (1) or as result of grinding and clenching teeth. This reduction in tooth structure is usually compensated by the continuous eruption of the tooth and growth of the alveolar bone (2). However, presence of certain causative factors, such as frequent acid regurgitation caused by eating disorders, usual intake of acid-containing food and drinks, or intermittent periods of intensive bruxism, could lead to extensive and pathological tooth wear (1). There is also a growing consensus that tooth wear may be the result of a combination of several possible etiological factors over the lifetime, explaining the increasing prevalence rates and the significant increase in the severity of tooth wear found in the elderly population (2,3).

In this scenario, early diagnosis and management of etiologic factors stand out as primary goals to be achieved. Otherwise, the progressive and irreversible loss of tooth structure will continue, reducing the occlusal vertical dimension (OVD) and this may cause muscle pain and temporomandibular joint (TMJ) dysfunction due to occlusal instability (4,5). Tooth pain and pulpal pathologies may also follow it, depending on the severity of tooth wear. In such case, reconstructive and endodontic procedures should be carried out in order to reestablish the occlusal balance, along with the regular preventive measures and

instructions.

Conventional fixed prosthodontics is still the mainstay of extensively worn dentition rehabilitation; however, such treatments are complex and generally highly invasive and expensive (1). Additionally, patients with severe tooth wear present shortened clinical crowns and the interocclusal space is usually reduced, increasing the risk of prosthetic complications and early tooth loss (5). For this reason, adhesive restorations are more conservative treatment approaches, reducing the necessity for extensive tooth preparation. Previous studies (6-11) evaluating the performance of direct composites to restore worn teeth have shown positive results, even in cases of occlusal vertical dimension recovery. The bulk failure rate of these direct composite restorations was also low (6%) when the anterior dentition was restored, after 2.5 years of follow up (11).

A randomized clinical trial (6) and retrospective analysis of cases (12) have shown interesting results. According to Bartlett et al. (6), the use of composite resin should not be recommended for patients with severe tooth wear because of their higher failure rate (22%). On the other hand, Redman et al. (12) stated that the risk of failure of the anterior tooth composite restorations due to wear increase only in the long term, and this material is a suitable option in the short to medium term. Maintenance of these restorations is straightforward, since localized refinishing or repairs may be all that is required (12).

Therefore, it seems that the severity of tooth wear, the control of etiologic factors, and the mechanical properties of restoration materials play crucial roles in the longevity of direct adhesive restorations, but further studies should be conducted to elucidate this subject.

Alternative treatments have been proposed to increase the mechanical properties of extensive adhesive restorations, such as pin-retained restorations (13,14). Dentinal pins are mechanical features incorporated into a cavity preparation to support and maintain the final restoration (13). Prior to the development of pin retention systems, teeth that were vital but with little coronal tooth substance were devitalized so that metal posts could be placed into the root canal for restoration retention. Use of adhesive technique in addition to self-threading pins could enhance the retention of the composite resin restorations without the need of a root canal treatment (13,15). An experimental study (14) compared the fracture resistance of restorations that were only bonded *versus* the ones that used dentin pins, revealing that the resistance to fracture was higher when dentinal pins were used. In this way, it is reasonable to believe that the alternative use of dentin pins could be a conservative and practical solution to restore severely worn anterior teeth, promoting a long-lasting success. However, to the best of our knowledge, no study has evaluated the long-term performance of direct restorations retained by dentin pins in patients with severe tooth wear. This case report aims to describe a minimally invasive treatment for extremely worn dentition based on direct adhesive pin-retained restorations.

Case Report

A 64-year-old white woman was referred to the Department of Prosthodontics of the School of Dentistry of the University of Pará, Brazil, suffering from severely worn dentition, eating problems related to missing teeth and generalized tooth hypersensitivity. The patient had not seen a dentist over the past 20 years. Clinical examination

revealed good general health, controlled diabetes and no pain symptoms in masticatory muscles or at the TMJ. During clinical interview, the patient reported frequent episodes of tooth grinding and clenching, configuring bruxism. However, the her stomatognathic system had adapted to this gradual tooth wear and absence of teeth.

Clinical examination revealed absence of the maxillary right lateral incisor and left first molar and all mandibular posterior teeth (Fig. 1). The remaining anterior teeth showed a marked reduction of tooth length and consequent occlusal collapse with accentuated loss of OVD and irregular occlusal plane. Absence of anterior and lateral guidance was also observed, which disturbs the mandibular movements. Sharp enamel edges, dentin craters and attritional wears were observed in the anterior teeth due to the loss of posterior support. The possible causes of patient's worn dentition might include loss of posterior support and bruxism.

A complete radiographic exam revealed the presence of apical and periodontal problems in the mandibular incisors and endodontic procedures in the remaining premolars. During the electric and thermal pulp testing, positive responses were obtained in the maxillary remaining teeth while all mandibular teeth were not vital anymore. Root canal therapy was proposed and performed in all mandibular teeth, after patient's acceptance.

Study cast models were obtained from primary impressions (Alginate Hydrogum; Zhermack, Rovigo, Veneto, Italy) and photographs were used to document the patient's current condition. The casts were mounted in a semi-adjustable articulator (BioArt, Equipamentos Odontologicos Ltda., São Carlos, SP, Brazil) using an arbitrary facebow (BioArt). These stone casts were also used for a full-mouth diagnostic wax-up (Fig. 2). During this procedure, a 6 mm increment of the current OVD was planned. This new OVD was carefully determined by esthetic, phonetic and facial proportion methods (2). This procedure aimed to restore the functional harmony of masticatory muscles and the most suitable position of the condyles in the mandibular

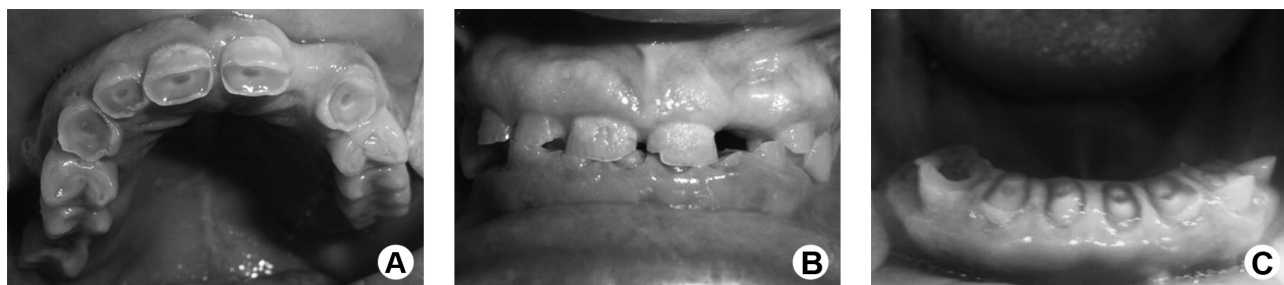

Figure 1. Initial condition showing a marked reduction of tooth length and consequent occlusal collapse with pronounced loss of occlusal vertical dimension and irregular occlusal plane. A: Occlusal view of the maxillary arch. B: Anterior view of the maximum intercuspal position. C: Occlusal view of the mandibular arch.

fossa of TMJ (14), respecting the individuality of the patient.

Proper treatment planning in advance of any nonreversible treatment is paramount when dealing with cases as complex as this one. Also, the diagnostic wax-up simulation used as a guide to determine the proper teeth anatomy is crucial to a final esthetic outcome. The diagnostic wax-up model should also be used to help the patient visualizing the proposed outcome of her full-mouth reconstruction. Based on the wax-up simulation (Fig. 2), the treatment plan was defined. The direct composite resin restorations with dentin pins were planned to reconstruct the maxillary anterior teeth. Since the mandibular remaining teeth were worn up to the gingival level and root canal therapy was performed in the residual roots, the treatment plan was a teeth-supported overdenture. This procedure allows the recovery of esthetics and function of the missing teeth while maintaining the alveolar bone around the remaining roots. This treatment plan was discussed with the patient who accepted it, providing an informed consent after being made aware of the benefits and risks of the treatment options.

Prior to the definitive prosthetic treatment, a removable occlusal overlay splint occluded with a provisional complete overdenture were constructed and installed in the patient's mouth to define the amount of OVD increase, which allowed the patient to adapt herself to this new condition. No pain or discomfort were observed at the TMJ and the masticatory muscles during the four weeks of trial.

The new anatomy of the maxillary teeth was replicated from the wax-up using a silicone impression material (Optosil; Heraeus Kulzer, Hanau, Hesse, Germany). These silicone stops were built on the palatal and occlusal surfaces to guide the proper reconstruction of the teeth by resin restorations. The maxillary anterior teeth were cleaned with prophylactic paste and the operating field

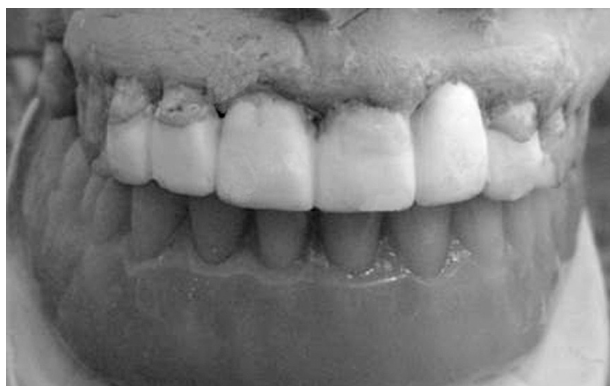

Figure 2. Full-mouth diagnostic wax-up performed in stone casts mounted in a semi-adjustable articulator and used as a guide to determine the proper teeth reconstruction.

was completely isolated.

A pin drill (0.525 mm diameter) was used to prepare a 2-mm-deep pinhole perpendicular to the dentin surface. A regular hand piece at normal and clockwise rotation was used in continuous motion and regular speed (30.000 rpm) to prepare pinholes, maintaining a constant angulation. Each pinhole was prepared to a depth of 2 mm by drilling first to half depth, withdrawing the drill, cleaning the flutes and then drilling to full depth. After that, every pinhole was threaded by stainless steel self-threading dentin Minim pins (diameter 0.584 mm) (Retopin; Edenta AG Dental Rotary Instruments, Au, St. Gallen, Switzerland), applied slightly angulated into the dentin-enamel junction, according to the manufacturer's recommendation. All anterior maxillary teeth received 2 to 4 self-threading Minim dentin pins. The final position and inclination of each pin were observed in the periapical radiographs (Fig. 3). After this, a low-speed diamond bur was used on the adjacent dentin to create rough surfaces in preparation for the adhesive system. All restorations were built-up adhesively and did not require extensive tooth preparation.

All restorative treatment followed the conventional adhesive protocol: 1) 35% phosphoric acid (3M ESPE, St Paul, MN, USA) applied for 30 s to enamel and for 15 s to dentin, followed by thorough rinsing and drying; 2) adhesive system (Adper Single Bond 2, 3M ESPE) applied according to the manufacturer's instruction and light curing with light-emitting diodes (Dabi Atlante Ultraled, Ribeirão Preto, Brazil) for 30 s; 3) composite resin (Filtek Z250, shade A2, 3M ESPE) applied using approximately 2-mm-thick layers with incremental layer and light curing with the same

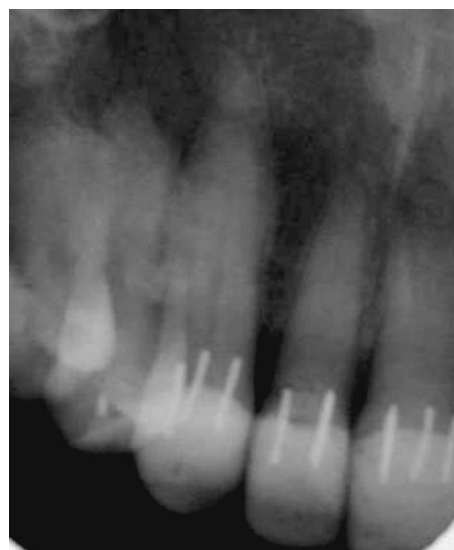


Figure 3. Periapical radiograph of the anterior teeth showing the position and inclination of each self-threading Minim dentin pin.

equipment for 20 s. The resin layers were placed until each tooth was entirely restored according to the silicon stop reference (Fig. 4).

The left lateral incisor was replaced by an adhesive-bonded fixed dental prosthesis supported by the adjacent teeth. The preparation was performed with shoulder-bevel margins in the cingulum region. After completion of tooth preparation, additional polymerizing silicone impression compound (Flexitime Impression Material, Heraeus Kulzer) was used to obtain the final impression of the tooth preparations. Definitive casts were made and mounted on the articulator with the facebow record index and interocclusal registration. The adhesive-bonded restoration was assembled by the laboratory using adhesive-impregnated polyethylene fibers (Ribbond; Ribbond Inc, Seattle, WA, USA) and Polyglass composite (Artglass; Heraeus-Kulzer). This prosthesis was fitted in position and cemented with dual-resin cement (Variolink II; Ivoclar Vivadent, Schaan, Liechtenstein). After restorative

reconstructions, final occlusal adjustments were performed and rough surfaces were finished and polished using Sof-Lex Pop-On polishing discs and silicone tips (3M ESPE). At the same appointment, the mandibular overdenture was installed in a bilateral balanced occlusion scheme (Fig. 5). Good esthetical and phonetic results were obtained (Fig. 6). Cleaning and maintenance instructions were given to the patient and subsequent adjustments were performed after 7, 14, and 21 days.

A hard stabilization splint for night use was installed in the maxilla to prevent nocturnal teeth grinding and clenching caused by patient's bruxism. This acrylic splint also protects the maxillary adhesive restorations, increasing the long-term prognosis. Patient was extremely happy and completely satisfied with the treatment outcomes, both functionally and esthetically.

A recall program was established every 4 months for at least 1 year and a half. During this period, the composite restorations were polished and no restorations has failed,

C.L. de Andrade et al.

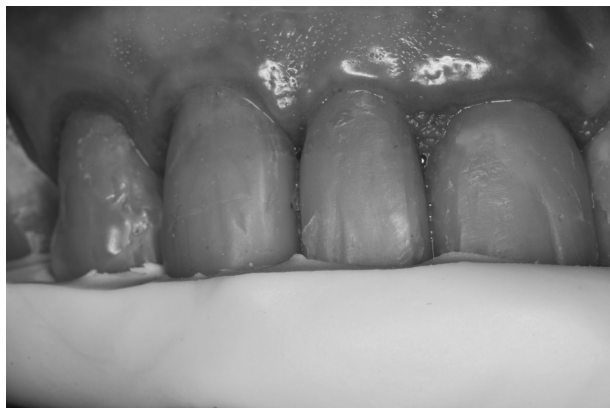

Figure 4. Silicone stop reference used to guide the restoration of each tooth by individual resin layers.

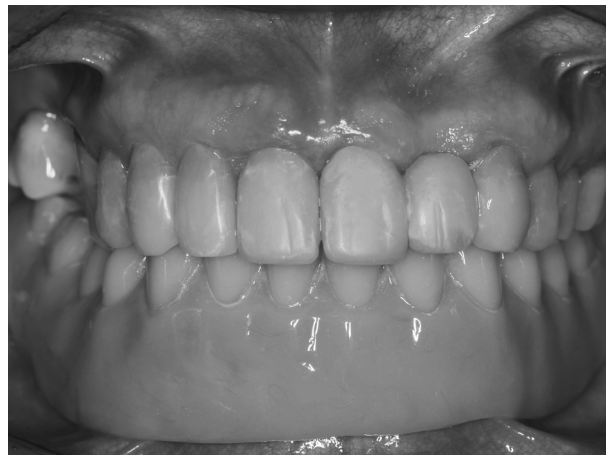

Figure 5. Front view of the full-mouth rehabilitation with direct resin restorations in the maxillary anterior teeth and the mandibular overdenture in position.

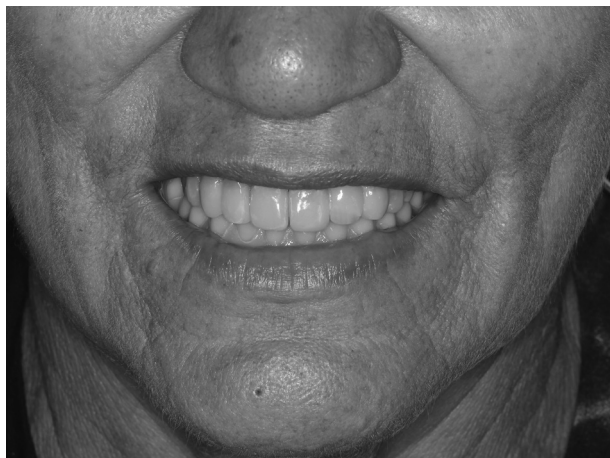


Figure 6. Patient's smile after the full-mouth rehabilitation.

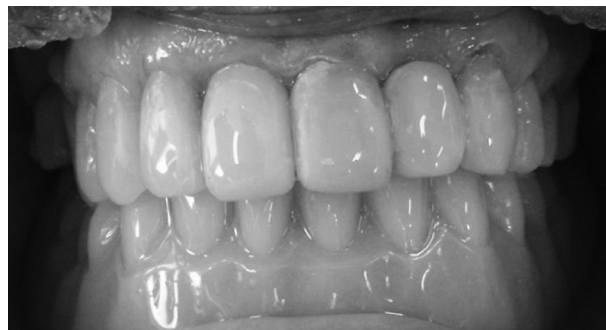

Figure 7. Full-mouth view during the follow-up appointment. No restoration had failed and the mandibular overdenture was stable.

with intact OVD and suitable stability of the mandibular denture (Fig. 7). At the same appointment, a regular implant (Titamax EX Ti; Neodent, Curitiba, PR, Brazil) was installed in the region of the maxillary right first molar, using the two-step technique.

Discussion

Extensive tooth wear has multifactorial etiology (16) and the management of patients with worn dentition is a complex and difficult process. Moreover, the lack of evidence regarding the long-term outcomes of treatment methods and materials difficult the clinical decision-making (1). A treatment strategy based on direct adhesive restorations seems to make sense because it is more conservative and provides reversible restorative oral rehabilitation, allowing a thorough understanding of the etiology and development of occlusal anomalies over time (16). The present clinical report demonstrates the importance of restoring a severely worn dentition with reduced OVD by the use of direct composite resin materials associated to self-threading dentinal pins. In the reported case, patient also received a mandibular overdenture supported by the remaining anterior teeth to recover the natural OVD, creating the required space for esthetic restorations and making possible a comfortable esthetic and functional situation.

The reversibility of the proposed prosthetic treatment is important because the worn dentition is usually the result of a slow process of occlusal breakdown, which allows most patients to adapt gradually to this situation until a level of unacceptability is reached (16-18). In contrast, restoration of occlusal morphology is a sudden action that hinders careful evaluation of the patient's ability to readapt to changed oral conditions (17).

More general wear may only cause absent occlusal morphology, but can also lead to loss of OVD or complete collapse of the occlusal support (17). Inadequate or unstable posterior support has also been identified as a factor in severe anterior attrition, increasing the reduction in OVD and possibly developing pain in temporomandibular joints or muscles (19). Therefore, accurate clinical and radiographic examinations, a diagnostic wax-up, correct determination of OVD, and removable occlusal overlay splints are crucial to allow patient to return to a healthy functional condition prior to any rehabilitation therapy.

Costly conventional fixed dental prosthesis and single crowns were, and still are, the mainstay of rehabilitation for severely worn dentition when treatment is required. However, such treatment options are complex and usually highly invasive, requiring extensive tooth preparation (1). The shortening of clinical crowns is a negative effect of tooth wear that may have significant implications on the retention of the cemented single crowns. Nevertheless, the

adhesive ability of resin-based materials makes them the material of choice for restoring anterior teeth wear, where they seem to perform reasonably well in short and medium term survival (1,5). Direct composite restorations represent a low-cost treatment option with successful esthetic and functional results. In spite of that, it is known that patients with bruxism generally present heavy occlusal loads, which may compromise the clinical performance of this restorative treatment (5). For this reason, several strategies have been proposed to overcome the risk of resin fractures. Since hybrid composites show higher fracture and wear resistance, these materials may be more suitable for patients with severe wear than the microfilled composite resins (5).

Use of self-threading dentinal pins is also a suitable method to increase the long-term stability of resin-based restorations (13). This simple and low-cost procedure increases the retention of adhesive materials, reducing the risk of fracture failures (13,14). Additionally, this alternative therapeutic approach preserves the tooth structure and requires simple clinical procedures (14). However, to the best of our' knowledge, there is no other report in the literature describing the use of this technique in patients with severely worn dentition. Although positive outcomes of the direct resin restorations were found in the reported case, further studies comparing the clinical performance of adhesive restorations with and without the addition of self-threading dentinal pins in patients with severely worn teeth are encouraged in order to confirm the positive advantages of this additional retention.

It is important to highlight that bruxism can be considered a dyskinesia apparently controlled by the central nervous system (20,21). Various cofactors also play important roles in the development and maintenance of bruxism episodes, such as stress, coping strategies, genetics and behavioral characteristics (20,21). Thus, there is no simple method to treat bruxism and the subjective and normative assessments of treatment need may be different. A regular follow-up plays a crucial role for the long-term successful results in severe tooth wear treatment, especially in patients with bruxism. During each clinical appointment, clinicians should be aware to clinically assess the restoration's conditions and constantly monitor the stabilization splint use as well as the conditions of the mandibular overdenture supported by the remaining roots.

Excessive tooth wear has a significant negative impact on patient's oral health-related quality of life, with an impact comparable to that of the edentulous condition (22). In the present clinical report, patient showed remarkable psychosocial problems related to her initial oral condition and, after treatment, the patient was very satisfied, smiling and returning to social activities. Thus, the use of direct composite resin materials in combination with

self-threading dentinal pins restored the severely worn dentition, representing a cost-effective approach to recover the original OVD, making possible a comfortable, esthetic and functional situation.

Resumo

A superfície oclusal excessivamente desgastada pode resultar em desarmonia oclusal e prejuízo à estética e função. Como abordagem terapêutica, coroas unitárias convencionais têm sido propostas, porém este tipo de tratamento é complexo, altamente invasivo e caro. Este relato de caso descreve os resultados clínicos de um tratamento alternativo minimamente invasivo baseado em restaurações adesivas diretas retidas por pinos. Uma paciente de 64 anos apresentando dentição severamente desgastada, problemas mastigatórios relacionados às ausências dentárias e hipersensibilidade dental generalizada foi encaminhada para tratamento. O adequado plano de tratamento baseado no encerramento diagnóstico foi utilizado para guiar a reconstrução dos dentes anteriores superiores com resina composta direta sobre pinos dentinários auto-rosqueáveis. Como os dentes inferiores remanescentes eram extremamente desgastados, uma sobre-dentadura dento-suportada foi instalada. Uma placa estabilizadora também foi utilizada de modo a proteger as restaurações. Este tratamento constituiu uma alternativa mais acessível de reabilitação de boca total com resultados estéticos e funcionais positivos após 1,5 anos de acompanhamento.

References

- Johansson A, Johansson AK, Omar R, Carlsson GE. Rehabilitation of the worn dentition. *J Oral Rehabil* 2008;35:548-566.
- Moslehifard E, Nikzad S, Geraminpanah F, Mahboub F. Full-mouth rehabilitation of a patient with severely worn dentition and uneven occlusal plane: a clinical report. *J Prosthodont* 2012;21:56-64.
- Van't Spijker A, Rodriguez JM, Kreulen CM, Bronkhorst EM, Bartlett DW, Creugers NH. Prevalence of tooth wear in adults. *Int J Prosthodont* 2009;22:35-42.
- Reston EG, Corba VD, Broliato G, Saldini BP, Stefanello Busato AL. Minimally invasive intervention in a case of a noncarious lesion and severe loss of tooth structure. *Oper Dent* 2012;37:324-328.
- Hamburger JT, Opdam NJ, Bronkhorst EM, Kreulen CM, Roeters JJ, Huysmans MC. Clinical performance of direct composite restorations for treatment of severe tooth wear. *J Adhes Dent* 2011;13:585-593.
- Bartlett D, Sundaram G. An up to 3-year randomized clinical study comparing indirect and direct resin composites used to restore worn posterior teeth. *Int J Prosthodont* 2006;19:613-617.
- Schmidlin PR, Filli T, Imfeld C, Tepper S, Attin T. Three-year evaluation of posterior vertical bite reconstruction using direct resin composite--a case series. *Oper Dent* 2009;34:102-108.
- Taubock TT, Attin T, Schmidlin PR. Implementation and experience of a new method for posterior vertical bite reconstruction using direct resin composite restorations in the private practice--a survey. *Acta Odontol Scand* 2012;70:309-317.
- de Moor RJ. Eating disorder-induced dental complications: a case report. *J Oral Rehabil* 2004;31:725-732.
- Van Roekel NB. Gastroesophageal reflux disease, tooth erosion, and prosthodontic rehabilitation: a clinical report. *J Prosthodont* 2003;12:255-259.
- Poyser NJ, Briggs PF, Chana HS, Kelleher MG, Porter RW, Patel MM. The evaluation of direct composite restorations for the worn mandibular anterior dentition - clinical performance and patient satisfaction. *J Oral Rehabil* 2007;34:361-376.
- Redman CD, Hemmings KW, Good JA. The survival and clinical performance of resin-based composite restorations used to treat localised anterior tooth wear. *Br Dent J* 2003;194:566-572; discussion 59.
- Papa J, Wilson PR, Tyas MJ. Pins for direct restorations. *J Dent* 1993;21:259-264.
- Attin T, Hellwig E, Hilgers RD, Zimmermann U. Fracture toughness of pin-retained class 4 restorations. *Oper Dent* 1994;19:110-115.
- Mondelli RF, Azevedo LM, Silva LM, Garrido AM, Ishikiriyama SK, Mondelli J. Conservative approach to restore the first molar with extensive destruction: A 30-month follow-up. *Quintessence Int* 2013;44:385-391.
- Song MY, Park JM, Park EJ. Full mouth rehabilitation of the patient with severely worn dentition: a case report. *J Adv Prosthodont* 2010;2:106-610.
- Creugers NH, van't Spijker A. Tooth wear and occlusion: friends or foes? *Int J Prosthodont* 2007;20:348-350.
- Koksai T, Dikbas I, Kazaoglu E. Alternative restorative approach for treatment of patient with extremely worn dentition. *N Y State Dent J* 2009;75:52-55.
- Pullinger AG, Seligman DA, Gornbein JA. A multiple logistic regression analysis of the risk and relative odds of temporomandibular disorders as a function of common occlusal features. *J Dent Res* 1993;72:968-979.
- Lavigne GJ, Kato T, Kolta A, Sessle BJ. Neurobiological mechanisms involved in sleep bruxism. *Crit Rev Oral Biol Med* 2003;14:30-46.
- Katsoulis J, Nikitovic SG, Spreng S, Neuhaus K, Mericske-Stern R. Prosthetic rehabilitation and treatment outcome of partially edentulous patients with severe tooth wear: 3-years results. *J Dent* 2011;39:662-671.
- Papagianni CE, van der Meulen MJ, Naeije M, Lobbezoo F. Oral health-related quality of life in patients with tooth wear. *J Oral Rehabil* 2013;40:185-190.

Received March 17, 2014

Accepted July 10, 2014