

CLINICAL IMAGES

Improving the success rate of intravenous cannulation

Anthony M.H. Ho, Gregory Klar, Glenio Bitencourt Mizubuti *



Department of Anesthesiology and Perioperative Medicine, Queen's University, Kingston, Ontario, Canada

Received 31 March 2022; accepted 21 May 2022
Available online 1 June 2022

First attempt intravenous (IV) cannulation success rate by anesthesiologists is 50.9–79.7%.^{1,2} Cannulation starts with the needle puncturing the vein at an angle (Fig. 1a). The

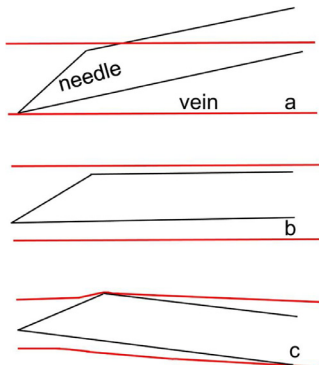


Figure 1 (a) The advancing tip of the needle of the IV cannula can go through the opposite (i.e., posterior) wall of the vein if the incident angle is not adjusted to nearly zero after the initial blood flashback. (b) The advancing tip of the needle is parallel to the vein, avoiding double-puncture, but the safety margin is small as any unsuspected downward tilt will lead to double-puncture. (c) A slight upward tilt of the needle provides the least chance of an inadvertent downward bias, and since the receding side of the bevel does not penetrate, it is the safest, even if the vein is slightly smaller than the IV needle-cannula set.

needle-cannula combo is then advanced further so that the cannula tip is completely within the vein before it can be advanced. During this advancement, if the incident angle of the needle has not been reduced, the tip may puncture the back wall of the vein (Fig. 1a) and become interstitial. Bending the needle slightly (Fig. 2)³ facilitates parallel advancement (Fig. 1b).

Instead of parallel advancement, we suggest a slight upward tilt (Fig. 1c) to create an arrowhead-shaped tip that has the least chance of puncturing the upper/lower vein

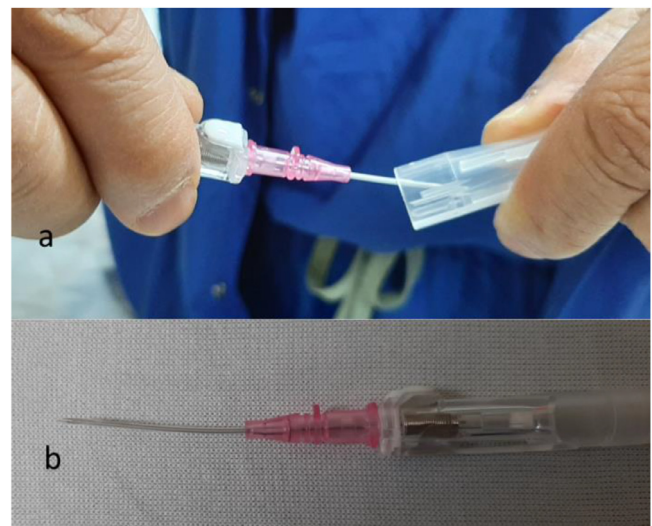

Figure 2 The IV needle-cannula shield (a) can be used to bend the set by a few degrees (b) while maintaining sterility.

* Corresponding author.
E-mail: Gleniomizubuti@hotmail.com (G.B. Mizubuti).

wall. The receding edge of the bevel has little chance of puncturing the vein wall.

Fig. 1c illustrates the situation in which the vein is slightly smaller than the cannula. Here, the challenge is not so much entering the vein since the metal needle tip is tapered. The key is not to double-puncture the vein during advancement. This chance is reduced if there is a small upward tilt of the needle tip (Fig. 1c), made possible by the aforementioned pre-bending of the needle-cannula set (Fig. 2).

Financial support

Departmental and institutional resources. No external funding was acquired for the current work.

Conflicts of interest

The authors declare no conflicts of interest.

References

1. Bensghir M, Chkoura K, Mounir K, et al. Peripheral intravenous access in the operating room: characteristics and predictors of difficulty. *Ann Fr Anesth Reanim.* 2012;31:600–4.
2. Angles E, Robin F, Moal B, et al. Pre-operative peripheral intravenous cannula insertion failure at the first attempt in adults. Development of the VENSORE predictive scale and identification of risk factors. *J Clin Anesth.* 2021;75:110435.
3. Solomowitz BH. Intravenous cannulation: a different approach. *Anesth Prog.* 1993;40:20–2.