

# DETERMINATION OF THE ESTROUS CYCLE PHASES OF RATS: SOME HELPFUL CONSIDERATIONS

MARCONDES, F. K., BIANCHI, F. J. and TANNO, A. P.

<sup>1</sup>Depto. Ciências Fisiológicas, Faculdade de Odontologia de Piracicaba, Universidade Estadual de Campinas, Av. Limeira, 901, CEP 13414-903, Piracicaba, SP, Brazil

Correspondence to: Fernanda Klein Marcondes, Depto. Ciências Fisiológicas, Faculdade de Odontologia de Piracicaba, Universidade Estadual de Campinas, Av. Limeira, 901, CEP 13414-903, Piracicaba, SP, Brazil, e-mail: fklein@fop.unicamp.br

Received October 17, 2001 – Accepted November 14, 2001 – Distributed November 30, 2002

(With 2 figures)

## ABSTRACT

The short length of the estrous cycle of rats makes them ideal for investigation of changes occurring during the reproductive cycle. The estrous cycle lasts four days and is characterized as: proestrus, estrus, metestrus and diestrus, which may be determined according to the cell types observed in the vaginal smear. Since the collection of vaginal secretion and the use of stained material generally takes some time, the aim of the present work was to provide researchers with some helpful considerations about the determination of the rat estrous cycle phases in a fast and practical way. Vaginal secretion of thirty female rats was collected every morning during a month and unstained native material was observed using the microscope without the aid of the condenser lens. Using the 10 x objective lens, it was easier to analyze the proportion among the three cellular types, which are present in the vaginal smear. Using the 40 x objective lens, it is easier to recognize each one of these cellular types. The collection of vaginal lavage from the animals, the observation of the material, in the microscope, and the determination of the estrous cycle phase of all the thirty female rats took 15-20 minutes.

*Key words:* estrous cycle, rat, cytology, smear.

## RESUMO

### **Determinação das fases do ciclo estral em ratas: considerações úteis**

Em razão da curta duração de seu ciclo estral, ratas constituem bom modelo para o estudo das alterações que ocorrem durante o ciclo reprodutivo. O ciclo estral de ratas tem duração média de quatro ou cinco dias e é caracterizado por quatro fases, proestro, estro, metaestro e diestro, as quais podem ser determinadas pelos tipos celulares observados no esfregaço vaginal. Como a coleta da secreção vaginal e o uso de material corado geralmente são demorados, o objetivo deste trabalho foi fornecer aos pesquisadores algumas considerações úteis para a determinação das fases do ciclo estral de maneira rápida e prática. A secreção vaginal de trinta ratas foi coletada diariamente pela manhã, durante um mês, e o lavado vaginal não corado foi observado a fresco, em microscópio ótico, sem a utilização das lentes do condensador. O uso das objetivas de aumento de 10 vezes facilita a análise da proporção entre os três tipos celulares presentes no material. O uso das objetivas de aumento de 40 vezes permite o reconhecimento de cada um dos tipos celulares. Descrevemos o método utilizado, no qual a coleta do lavado vaginal, a observação do material e a identificação das fases do ciclo estral de 30 ratas podem ser realizados em 15-20 minutos.

*Palavras-chave:* ciclo estral, ratas, citologia, esfregaço.

## INTRODUCTION

The reproductive cycle of female rats is called estrous cycle and is characterized as proestrus, estrus, metestrus (or diestrus I) and diestrus (or diestrus II) (Long & Evans, 1922; Freeman, 1988). The ovulation occurs from the beginning of proestrus to the end of estrus (Young *et al.*, 1941; Schwartz, 1964). From the onset of sexual maturity up to the age of 12 months, the mean cycle length in the female rat is 4 days (Long & Evans, 1922; Freeman, 1988; Mandl, 1951), and this short cycle length makes the rat an ideal animal for investigation of changes occurring during the reproductive cycle (Spornitz *et al.*, 1999; Marcondes *et al.*, 2001).

During the estrous cycle, prolactin, LH and FSH remain low and increase in the afternoon of the proestrus phase. Estradiol levels begin to increase at metestrus, reaching peak levels during proestrus and returning to baseline at estrus. Progesterone secretion also increases during metestrus and diestrus with a decrease afterwards. Then the progesterone value rises to reach its second peak towards the end of proestrus (Spornitz *et al.*, 1999; Smith *et al.*, 1975).

In studies about reproductive system as well as studies about the influence of the estrous cycle on non-reproductive functions (Rodriguez *et al.*, 1995; Marcondes, 1995; Marcondes *et al.*, 1996; Vanderelei *et al.*, 1996; Chateau *et al.*, 1996; Marcondes, 1998; Spadari-Bratfisch *et al.*, 1999), vaginal smear cytology is used for the determination of the estrous cycle phases (Long & Evans, 1922; Hoar & Hickman, 1975). The characterization of each phase is based on the proportion among three types of cells observed in the vaginal smear: epithelial cells, cornified cells and leukocytes. The collection of vaginal secretion and the use of stained material generally take 1-2 hours or more. Thus, the aim of this work was to provide the researchers some helpful considerations about the determination of the rat estrous cycle phases in a fast and practical way.

## MATERIAL AND METHODS

Female Wistar rats (*Rattus norvegicus*), three months old, weighing 200 to 300 g were used. The animals were housed in standard cages, five per cage, in a controlled temperature room (22°C), with

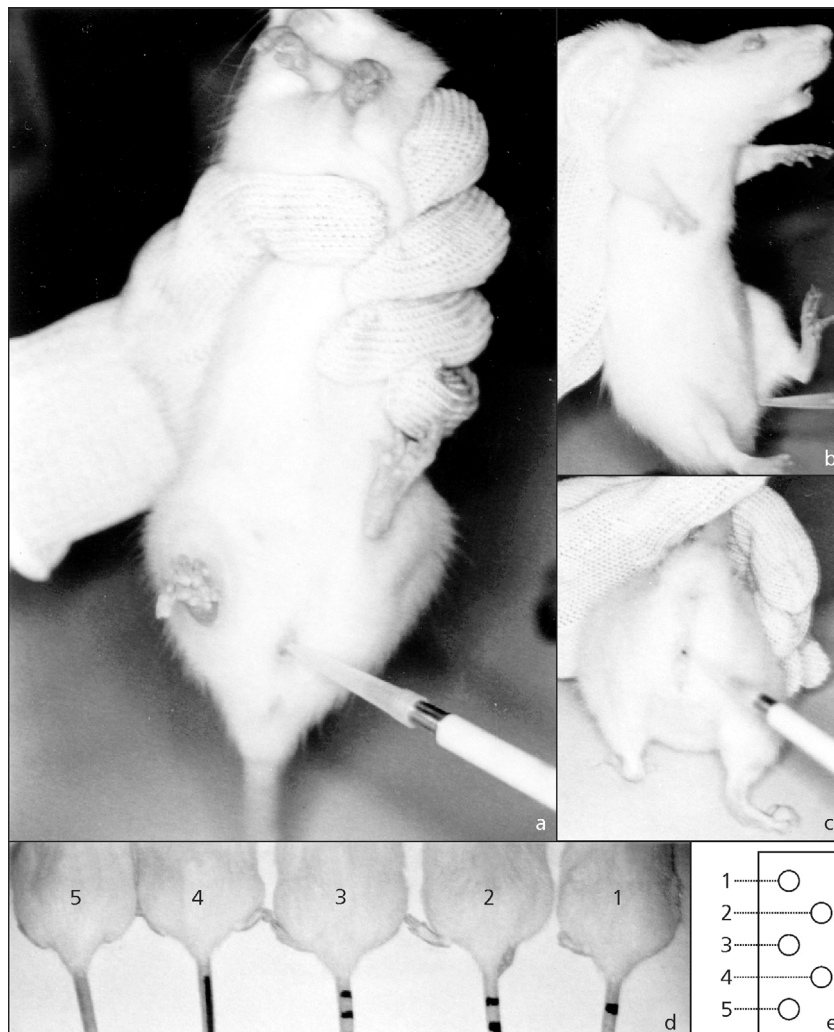
a 12 h light: 12 h dark cycle, lights on at 6:00 a.m. Standard laboratory chow and tap water were available *ad libitum*. All the procedures have been approved by the Institute of Biology/UNICAMP Ethical Committee for Animal Research (CEEA-IB-UNICAMP, certificate 13-1) and were carried out according to the determinations of the Brazilian College of Animal Experimentation (COBEA).

During one month, every morning between 8:00 and 9:00 a.m. each animal cage was carried to the experimental room. Vaginal secretion was collected with a plastic pipette filled with 10 µL of normal saline (NaCl 0.9%) by inserting the tip into the rat vagina, but not deeply. Vaginal fluid was placed on glass slides. A different glass slide was used for each cage of animals. One drop was collected with a clean tip from each rat. Unstained material was observed under a light microscope, without the use of the condenser lens, with 10 and 40 x objective lenses. Three types of cells could be recognized: round and nucleated ones are epithelial cells; irregular ones without nucleus are the cornified cells; and the little round ones are the leukocytes. The proportion among them was used for the determination of the estrous cycle phases (Long & Evans, 1922; Mandl, 1951).

For the collection of vaginal secretion, each rat was grasped in one of the three ways presented in Figs. 1a, 1b, and 1c. Only one slide was used for each cage. There were five rats in each cage and they were marked with an atoxic pencil in the tails according this way: with one, two or three transversal traces, with one longitudinal trace, traceless (Fig. 1d). One drop from each rat was collected and placed on the slide as indicated in the Fig. 1e.

## RESULTS

The Fig. 2 indicates the cellular types from the vaginal smear of female rats, and the proportion among them allows the observer to define the estrous cycle phase of the rat. A proestrus smear consists of a predominance of nucleated epithelial cells (Figs. 2a, 2b); an estrous smear primarily consists of anucleated cornified cells (Figs. 2c, 2d); a metestrus smear consists of the same proportion among leukocytes, cornified, and nucleated epithelial cells (Figs. 2e, 2f), and a diestrus smear primarily consists of a predominance of leukocytes (Figs. 2g, 2h) (Long & Evans, 1922; Mandl, 1951).



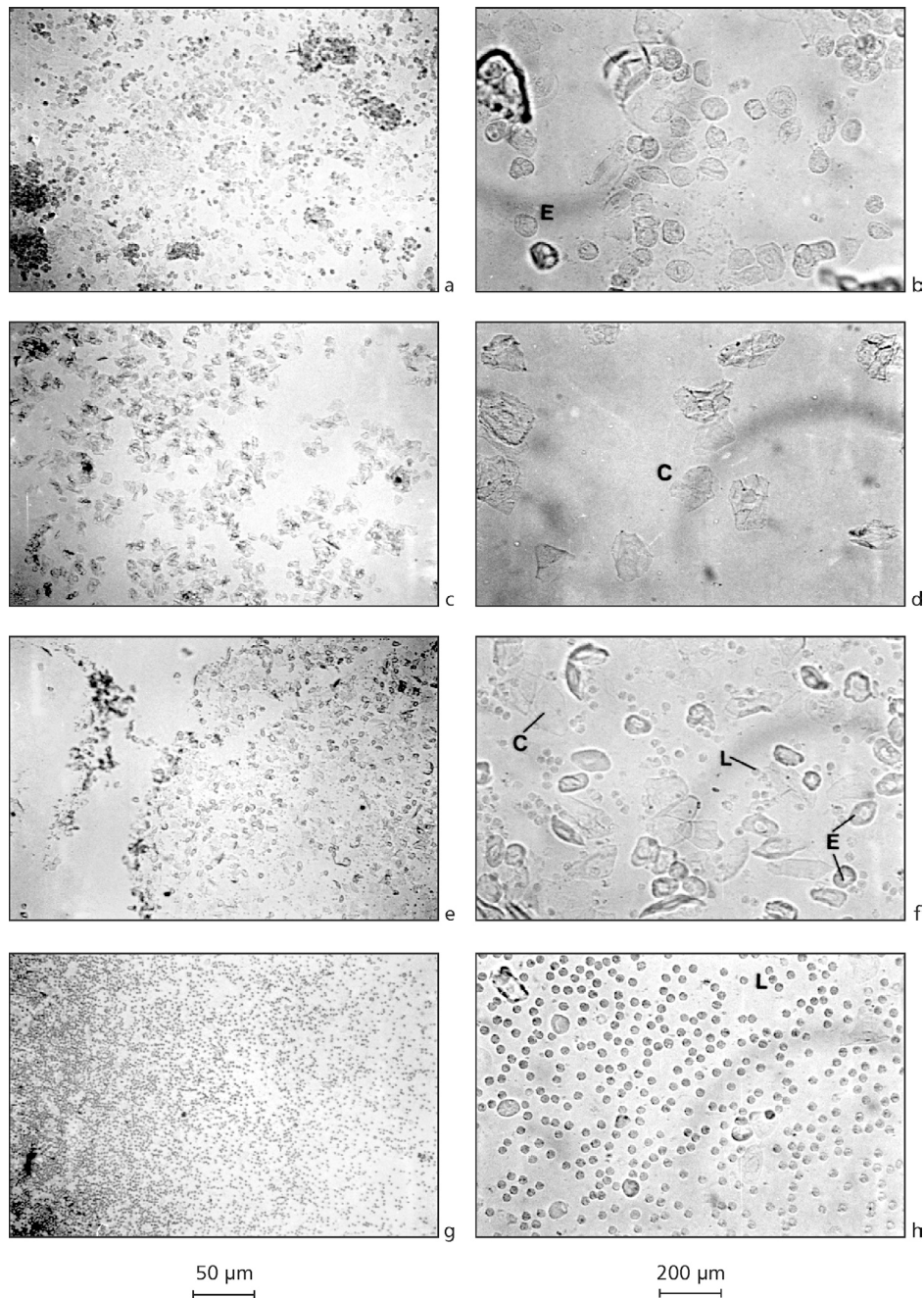
**Fig. 1** — Ways to holding the female rat for the collection of the vaginal lavage (a-c), individual tail marks of five female rats from the same cage (d) and way to distribute the drops of vaginal lavage from each female rats in a glass slide (e). During a month, every morning between 8:00 and 9:00 a.m., vaginal secretion was collected from female rats. It was done by using a plastic pipette filled with 10  $\mu$ L of normal saline (NaCl 0.9%) by inserting the tip into the rat vagina, but not deeply (1a). If the animals were aggressive ways 1b and 1c were used. Vaginal fluid was placed on glass slides and a different glass slide was used for each cage of animals (1e). One drop was collected with a clean tip from each rat (1d, 1e).

## DISCUSSION

The mean duration of the estrous cycle was 4-5 days for 60%-70% of female rats. However, some rats presented longer regular or irregular cycles. Irregular ones were characterized by keeping in the same phase during 4-5 days. Cycles, in which the alternation among the phases didn't follow the sequence proestrus, estrus, metestrus

and diestrus (or intermediates), were also considered irregular. The collection of vaginal secretion from thirty female rats and the observation of the material took 15-20 minutes.

The volume of 10  $\mu$ L of saline solution and the three rat holding ways, presented in Fig. 1, allow to collect sufficient material for observation of vaginal cytology. The choice among them depends on the practice of experimenter to hold the rats.



**Fig. 2** — Photomicrographs of unstained vaginal smear from female rats at proestrus (a, b) and diestrus (g, h). Leukocytes (L), epithelial (E) and cornified (C) cells are indicated. 50 x (left panel) and 200 x (right panel). Unstained native vaginal smear from female rats was observed under a light microscope, without the use of the condenser lens, with 10 and 40 x objective lenses. The proportion the three types of cells was used for the determination of the estrous cycle phases. Round and nucleated ones are epithelial cells (E); irregular ones without nucleus are the cornified cells (C); and the little round ones are the leukocytes (L). A proestrus smear consists of a predominance of nucleated epithelial cells (Figs. 2a, 2b); an estrous smear primarily consists of anucleated cornified cells (Figs. 2c, 2d); a metestrus smear consists of the same proportion among leukocytes, cornified, and nucleated epithelial cells (Figs. 2e, 2f); and a diestrus smear primarily consists of a predominance of leukocytes (Figs. 2g, 2h).

The procedure should not be done in the presence of rats from other cages to avoid stress and increase of aggressiveness of females that will be caught afterwards. As described by Hoar & Hickman (1975), if the rat is treated gently and gets used to handling, it will not object to the procedure and may be grasped as demonstrated in the Fig. 1a. However, if the animal is aggressive, the second and third options (Figs. 1b and 1c) seem to be more efficient. The more the animal is immobilized the easier and faster it will be to collect vaginal lavage. If the rat tries to bite the experimenter, the animal can be grasped as indicated in the Fig. 1c, which makes vaginal fluid easier to collect from an aggressive female rat. Generally, some rats show this behavior during the first and second days of collection of vaginal smear. Afterwards, during the next days, because of daily collection of vaginal secretion, female rats become less aggressive and seem habituated to handling. Therefore, in experimental protocols that use male and female rats with characterization of estrous cycle phases, males should also be manipulated for at least 10 days to assure that they are also habituated to handling (Marcondes, 1995; Marcondes, 1998). Taking this care, the experimenter will avoid manipulation stress in males so that it does not influence on experimental results.

With the distribution of the drops in the way indicated in Fig. 1d the observation of the material in the microscope will be faster if one glass slide is used for all the five rats from the same cage. If a 10  $\mu$ L volume is used, the drop will present a sufficient amount of cells. To avoid two focuses of cells because of the height of the drop, it is possible to use a clean tip to softly spread the material. If so, only one focus will be obtained. It is not necessary to use a cover slip. If the drop dries, it is possible to add more saline with another clean tip, only to dampen it (less than 10  $\mu$ L). The observation of the cells should be done with low illumination in the microscope, and without the use of the condenser lens to assure a good contrast, as indicated in the Fig. 2. Using the 40 x objective lens (Figs. 2b, d, f, and h), the characterization of the cell types is easier than using the 10 x objective one (Figs. 2a, c, e, and g). However, the determination of the estrous cycle phase is based in the proportion among the three cell types which is easier if the 10 x objective lens is used.

As shown in previous reports (Long & Evans, 1922; Freeman, 1988; Mandl, 1951), our results confirmed that the mean duration of the estrous cycle of the rat is 4 days. Finally, the procedures presented in the present work makes the knowledge of the reproductive status of the female faster and easier for utilization on the animals in different experimental protocols. It is really useful in long protocols in which the determination of the estrous cycle phases is made for the experiments that last some hours or all day (Rodriguez *et al.*, 1995; Marcondes, 1995; Marcondes *et al.*, 1996; Vanderelei *et al.*, 1996; Chateau *et al.*, 1996; Marcondes, 1998; Spadari-Bratfisch *et al.*, 1999). Moreover for beginners, it is not easy to recognize the three cellular types in the vaginal smear by using schematic drawings from books. So, the photomicrographs presented in this work may be useful for them.

*Acknowledgments* — The authors thank Dr. Sérgio Line and Eliene A. O. Narvaes Romani for helping FKM taking microphotographs, Jorge Valério and Cíntia M. Tabchoury for the spelling correction. This work was supported by FAPESP (99/00793-1) and FAEP/UNICAMP (0071/99; 0027/00; 1157/00) grants. The authors also thank FAPESP scholarships: FJB and APT (99/02358-0; 99/11442-5).

## REFERENCES

- CHATEAU, D., GEIGER, J. M., SAMAMA, B. & BOEHM, N., 1996, Vaginal keratinization during the estrous cycle in rats: a model for evaluating retinoid activity. *Skin Pharmacol.*, 9: 9-16.
- FREEMAN, M. E., 1988, The ovarian cycle of the rat. In: E. Knobil & J. Neil (eds.), *Physiology of reproduction*. Raven Press Ltd., New York, pp. 1893-1928.
- HOAR, W. & HICKMAN, C. P., 1975, Ovariectomy and the estrous cycle of the rat. In: W. Hoar & C. P. Hickman (eds.), *General and comparative physiology*. 2. ed. Prentice-Hall, New Jersey, pp. 260-265.
- LONG, J. A. & EVANS, H. M., 1922, The estrous cycle in the rat and its associated phenomena. *Memories of University of California*, 6: 1-148.
- MANDL, A. M., 1951, The phases of the oestrous cycle in the adult white rat. *Journal of Experimental Biology*, 28: 576-584.
- MARCONDES, F. K., 1995, *Influence of gender and estrous cycle phases on the stress reaction in rats*. Master's Degree Dissertation, State University of Campinas, Campinas, São Paulo, Brazil.
- MARCONDES, F. K., 1998, *Influence of the estrous cycle on the hormonal responses from female rats submitted to stress*. Ph. D. Thesis, State University of Campinas, Campinas, São Paulo, Brazil.

- MARCONDES, F. K., MIGUEL, K., MELO, L. L. & SPADARI-BRATFISCH, R. C., 2001, Estrous cycle influences the response of female rats in the elevated plus-maze. *Physiol. Behav.*, 74(4-5): 435-440.
- MARCONDES, F. K., VANDERLEI, L. C. M., LANZA, L. B. & SPADARI-BRATFISCH, R. C., 1996, Stress-induced subsensitivity to catecholamines depends on the estrous cycle. *Can. J. Physiol. Pharmacol.*, 74: 663-669.
- RODRIGUES, M. L. V., MARCONDES, F. K. & SPADARI-BRATFISCH, R. C., 1995, Relationship among sensitivity to adrenaline, plasma corticosterone level and estrous cycle in rats. *Can. J. Physiol. Pharmacol.*, 73: 602-607.
- SCHWARTZ, N. B., 1964, Acute effects of ovariectomy on pituitary LH, uterine weight, and vaginal cornification. *Am. J. Physiol.*, 107: 1251-1259.
- SMITH, M. S., FREMAN, M. E. & NEIL, J. D., 1975, The control of progesterone secretion during the estrous cycle and early pseudopregnancy in the rat: prolactin, gonadotropin and steroid levels associated with rescue of the corpus luteum of pseudopregnancy. *Endocrinology*, 96: 219-226.
- SPADARI-BRATFISCH, R. C., NUNES, I. S., VANDERLEI, L. C. M. & MARCONDES, F. K., 1999, Evidence for  $\beta_2$ -adrenoceptors in right atria from female rats submitted to footshock stress. *Can. J. Physiol. Pharmacol.*, 77: 432-440.
- SPORNITZ, U. M., SOCIN, C. D. & DAVID, A. A., 1999, Estrous stage determination in rats by means of scanning electron microscopic images of uterine surface epithelium. *The Anat. Rec.*, 254: 116-126.
- VANDERLEI, L. C. M. MARCONDES, F. K., LANZA, L. B. & SPADARI-BRATFISCH, R. C., 1996, Influence of the estrous cycle on the sensitivity to catecholamines in right atria from rats submitted to footshock stress. *Can. J. Physiol. Pharmacol.*, 74: 670-678.
- YOUNG, W. C., BOLING, J. L. & BLANDAU, R., 1941, The vaginal smear picture, sexual receptivity and time of ovulation in the albino rat. *Anat. Rec.*, 80: 37-45.