

Original Article

## Gastrointestinal parasites in captive and free-living wild birds in Goiânia Zoo

Parasitas gastrointestinais em aves silvestres em cativeiro e de vida livre no Zoológico de Goiânia

Y. J. O. Melo<sup>a</sup> , H. T. Ferraz<sup>b</sup> , K. C. Saturnino<sup>c</sup> , T. D. P. Silva<sup>d</sup> , I. A. Braga<sup>c,e</sup> , A. V. C. Amaral<sup>c</sup> ,  
R. B. Meirelles-Bartoli<sup>c</sup>  and D. G. S. Ramos<sup>c\*</sup> 

<sup>a</sup> Universidade Federal de Goiás, Regional Jataí – UFG, Jataí, GO, Brasil

<sup>b</sup> Universidade Federal de Jataí – UFJ, Laboratório de Anatomia Veterinária, Unidade Acadêmica de Ciências Agrárias, Jataí, GO, Brasil

<sup>c</sup> Universidade Federal de Jataí – UFJ, Programa de Pós-graduação em Biociência Animal, Unidade Acadêmica Especial de Ciências Agrárias, GO, Brasil

<sup>d</sup> Parque Zoológico de Goiânia, Goiânia, GO, Brasil

<sup>e</sup> Centro Universitário de Mineiros, Unidade Básica de Biociências, Mineiros, GO, Brasil

### Abstract

Helminths are endoparasites that infect a variety of bird species. Endoparasite infections can cause severe diseases, including kill captive avian hosts and represents a problem to maintenance and conservation. The eggs and larval forms of these parasites are usually eliminated in the host feces. The main interest of this study is to report the occurrence of eggs and oocysts in feces from captive wild birds in Goiânia Zoo and free-living birds in its surroundings. The fecal samples were subjected to parasitological examination to identify the presence of helminths and to classify their eggs based on morphological characteristics. Eggs of nematode parasites (Positive/N) were identified as *Ascaridia* spp. in *Brotogeris chiriri* (2/2), *Dromaius novaehollandiae* (1/1) and *Rhea americana* (2/2); Ascarididae in *Pavo cristatus nigripennis* (1/1); *Capillaria* spp. in *Ara chloropterus* (1/1) and *Penelope jacucaca* (1/1); *Capillaria plagiaticia* in *Anodorhynchus hyacinthinus* (1/2) and *Ara* spp. (2/2); *Capillaria venusta* in *Rhamphastus tucanus* (1/2); and unidentified nematode eggs from *Amazona amazonica* (2/2). *Eimeria* spp. oocyst was founded in feces from *A. hyacinthinus* (1/2). Considering free-living birds, *Diphyllobothrium* spp. eggs were founded in *Ardea alba* (2/2) and *Nycticorax nycticorax* (2/3). Co-infection of *Eustrongylides* spp. was founded in *A. alba* (1/2). This is the first occurrence of: *Ascaridia* spp. parasitizing *B. chiriri*; and *C. venusta* parasitizing *R. tucanus*. In conclusion, the helminth eggs found in the abovementioned host bird species are consistent with those reported in the literature, and treatment and control protocols were based on their identification.

**Keywords:** coprology, infection, parasitology, preservation.

### Resumo

Helminths são endoparasitas que infectam uma variedade de espécies de aves. As infecções por endoparasitas podem causar doenças graves, podendo matar aves em cativeiro e representam um problema de manutenção e conservação. Os ovos e as formas larvais desses parasitas são geralmente eliminados nas fezes do hospedeiro. O principal objetivo deste estudo é relatar a ocorrência de ovos e oocistos em fezes de aves silvestres em cativeiro no Zoológico de Goiânia e em aves de vida livre em seu entorno. As amostras fecais foram submetidas a exame parasitológico para identificação da presença de helmintos e classificação dos ovos com base nas características morfológicas. Ovos de nematóides (Positivo/N) foram identificados como *Ascaridia* spp. em *Brotogeris chiriri* (2/2), *Dromaius novaehollandiae* (1/1) e *Rhea americana* (2/2); Ascarididae em *Pavo cristatus nigripennis* (1/1); *Capillaria* spp. em *Ara chloropterus* (1/1) e *Penelope jacucaca* (1/1); *Capillaria plagiaticia* em *Anodorhynchus hyacinthinus* (1/2) e *Ara* spp. (2/2); *Capillaria venusta* em *Rhamphastus tucanus* (1/2); e ovos de nematóide não identificado de *Amazona amazonica* (2/2). Oocistos de *Eimeria* spp. foram encontrados nas fezes de *A. hyacinthinus* (1/2). Considerando pássaros de vida livre, ovos de *Diphyllobothrium* spp. foram encontrados em *Ardea alba* (2/2) e *Nycticorax nycticorax* (2/3). Coinfecção de *Eustrongylides* spp. foi encontrada em *A. alba* (1/2). Esta é a primeira ocorrência de: *Ascaridia* spp. parasitando *B. chiriri*; e *C. venusta* parasitando *R. tucanus*. Em conclusão, os ovos de helmintos encontrados nas espécies de aves hospedeiras acima mencionadas são consistentes com os relatados na literatura, e os protocolos de tratamento e controle foram baseados em sua identificação.

**Palavras-chave:** coprologia, infecção, parasitologia, preservação.

\*e-mail: dgramos\_vet@hotmail.com

Received: July 1, 2020 – Accepted: October 28, 2020



This is an Open Access article distributed under the terms of the Creative Commons Attribution License, which permits unrestricted use, distribution, and reproduction in any medium, provided the original work is properly cited.

## 1. Introduction

Parasitic diseases are one of the most frequent and important health problems that affect wild birds (Freitas et al., 2002). According Borgsteede (1996), parasites affects wild animals in feeding, reproduction or killing also. In this sense, free-living and captive wild birds can be parasitized by many helminth species, whose effects range from asymptomatic infections up to the host's death (Carneiro et al., 2011).

The detection and identification of helminths is based on the parasitological examination of feces, which consists in identifying eggs and other parasitic forms eliminated in the feces of host birds (Snak et al., 2014). Diagnostic procedures involve direct microscopic examination of fecal samples and flotation and sedimentation methods (Snak et al., 2014).

Parasites eggs differ in terms of size, eggshell thickness, shape and other morphological characteristics that serve to identify them as well as the host bird species (Carneiro et al., 2011; Cubas et al., 2014). Thus, their identification serves to guide treatment and control strategies against parasitic infections (Cubas et al., 2014).

The impact of helminth infections on the maintenance and conservation of captive birds, as well as on the survival of wildlife populations and their ecosystems, underscore the importance of knowledge about the parasitic diseases of wild birds (Cubas et al., 2014), and the scarce knowledge about the parasitic diseases of wild birds (Carneiro et al., 2011), explains the reason for this study.

This study aims to identify helminth eggs in fecal samples from captive and free-living wild birds belonged to Goiânia Zoo reporting its occurrence and importance for conservation of these species.

## 2. Material and Methods

Fresh fecal samples (n=42) were collected between August 20, 2018 and January 26, 2019. The fecal samples were collected from the floor of aviaries of captive wild birds (n=31) in Goiânia Zoo, and from free-living wild birds (n=11) in the surrounding area of the zoo. The samples of captive birds were from birds in isolation (one bird per cage) or in enclosures with birds of the same species. Some enclosures at the zoo are not fully enclosed or covered, where free-living birds come to feed. Samples of these free-living birds were collected when they were injured for some reason and taken to the zoo's veterinary care. After, were stored in 40 mL flasks and subjected to flotation testing in sucrose solution (Sheather, 1923) and spontaneous sedimentation (Lutz, 1919). In addition, on the day they were collected, fresh samples were subjected to direct microscopic examination. All the samples were examined under 10x and 40x objective lenses as described by Zajac and Conboy (2012), and Taylor et al. (2016). The identification of eggs was based on morphological analysis compared with descriptions in studies and specific descriptions (Vicente et al., 1995; Freitas et al., 2002; Kajerova et al., 2004; Cunha, 2007; Cubas et al., 2014; Atkinson et al., 2008; Hofstatter and Guaraldo, 2015; Santos et al., 2015).

The infected birds (captive or free-living) were treated orally with a combination of fenbendazole, pyrantel pamoate and praziquantel (Cubas et al., 2014), which was repeated after 14 days (Atkinson et al. 2008), except the white-throated toucan (*Ramphastos tucanus*, Linnaeus 1758), which was treated subcutaneously with the dosage recommended by Carpenter (2010), and the hyacinth macaw (*Anodorhynchus hyacinthinus*, Latham 1790), which was treated with a combination of sulfadiazine and trimethoprim (Carpenter, 2010; Tully et al., 2010). Fire was used as a control and prevention measure to disinfect the enclosures (Cubas et al., 2014).

## 3. Results

Of the 31 fecal samples from captive birds, 12 (38.71%) were positive for helminth eggs, while six (54.54%) of the 11 fecal samples from free-living birds contained eggs of these parasites. Eggs of nematode parasites recovered from captive birds were identified (Positive/N - %) as *Ascaridia* spp. Dujardin, 1845 in *Brotogeris chiriri* Vieillot, 1818 (2/2), *Dromaius novaehollandiae* Latham, 1790 (1/1) and *Rhea americana* Linnaeus, 1758 (2/2); Ascarididae Baird, 1853 in *Pavo cristatus nigripennis* Linnaeus, 1758 (1/1); *Capillaria* spp. Zeder, 1800 in *Ara chloropterus* Gray, 1859 (1/1) and *Penelope jacucaca* Spix, 1825 (1/1); *Capillaria plagiatica* Freitas & Mendonça, 1959 in *Anodorhynchus hyacinthinus* (1/2) and *Ara* spp. Lacepede, 1799 (2/2); *Capillaria venusta* Freitas & Mendonça, 1958 in *Rhamphastus tucanus* (1/2); and unidentified nematode eggs from *Amazona amazonica* Linnaeus, 1766 (2/2). *Eimeria* spp. Schneider, 1875 oocyst was founded in feces from *A. hyacinthinus* (1/2). This is the first occurrence of: *Ascaridia* spp. parasitizing *B. chiriri*; and *C. venusta* parasitizing *R. tucanus*. *A. chloropterus* and *R. tucanus* with capillariasis presented clinical signs of prostration, finicky appetite, weight loss and dehydration.

Considering free-living birds, *Diphylobothrium* spp. Cobbold, 1858 eggs were founded in *Ardea alba* Linnaeus, 1758 (2/2 – 100%) and *Nycticorax nycticorax* Linnaeus, 1758 (2/3 – 33,33%). Co-infection of *Eustrongylides* spp. Jägerskiöld, 1909 was founded in *A. alba* (1/2 – 50%)

All results are shown in Tables 1 and 2. Table 1 lists the free-living (FL) and captive © bird species from which fecal samples were collected. Table 2 describes positive birds and the helminth eggs identified in the feces. Some helminth eggs found in this study are shown in Figure 1.

## 4. Discussion

According to Cubas et al. (2014), the genus *Ascaridia* is among the two most common ascarids that infect Psittaciformes birds. Kajerova et al. (2004) stated that seven species of this parasite genus have already been identified in Psittaciformes birds, and the two most common species are *Ascaridia hermaphrodita* Froelich, 1789 and *Ascaridia platyceri* Hartwich & Tscherner, 1979. Atkinson et al. (2008) stated that the genus *Ascaridia* is widely distributed around the world, and reported the occurrence of *Ascaridia sergiomeirai* Pereira, 1933

**Table 1.** List of free-living (FL) and captive © wild birds in Goiânia Zoo subjected to parasitology fecal tests between 20 August 2018 and 26 January 2019.

Birds species	First Description	Common name	Condition	N° of Birds
<i>Alopochen aegyptiaca</i>	Linnaeus, 1766	Egyptian goose	FL	1
<i>Amazona aestiva</i>	Linnaeus, 1758	Turquoise-fronted amazon	C	2
<i>Amazona amazonica</i>	Linnaeus, 1766	Orange-winged amazon	C	2
<i>Amazona farinosa</i>	Boddaert, 1783	Southern mealy amazon	C	1
<i>Amazona ochrocephala</i>	Gmelin, 1788	Yellow-crowned amazon	C	1
<i>Anodorhynchus hyacinthinus</i>	Latham, 1790	Hyacinth macaw	C	2
<i>Ara ararauna</i>	Linnaeus, 1758	Blue-and-yellow macaw	C	2
<i>Ara ararauna</i>	Linnaeus, 1758	Blue-and-yellow macaw	FL	1
<i>Ara chloropterus</i>	Gray, 1859	Red-and-green macaw	C	1
<i>Ara macao</i>	Linnaeus, 1758	Scarlet macaw	C	1
<i>Ara spp.</i>	Lacépède, 1799	Hybrid macaw	C	2
<i>Aratinga jandaya</i>	Gmelin, 1788	Jandaya parakeet	C	2
<i>Ardea alba</i>	Linnaeus, 1758	Great egret	FL	2
<i>Brotogeris chiriri</i>	Vieillot, 1818	Yellow-chevroned parakeet	C	1
<i>Brotogeris chiriri</i>	Vieillot, 1818	Yellow-chevroned parakeet	FL	2
<i>Deroyptus accipitrinus</i>	Linnaeus, 1758	Red-fan parrot	C	1
<i>Dromaius novaehollandiae</i>	Latham, 1790	Emu	C	1
<i>Gnorimopsar chopi</i>	Vieillot, 1819	Chopi blackbird	FL	1
<i>Guaruba guarouba</i>	Gmelin, 1758	Golden parakeet	C	2
<i>Nycticorax nycticorax</i>	Linnaeus, 1758	Black-crowned night heron	FL	3
<i>Orthopsittaca manilata</i>	Boddaert, 1783	Red-bellied macaw	C	1
<i>Pavo cristatus nigripennis</i>	Linnaeus, 1758	Black-shouldered peafowl	C	1
<i>Penelope jacucaca</i>	Spix, 1825	White-browed guan	C	1
<i>Pionus menstruus</i>	Linnaeus, 1766	Blue-headed parrot	C	2
<i>Pitangus sulphuratus</i>	Linnaeus, 1758	Great kiskadee	FL	1
<i>Pyrrhura melanura</i>	Spix, 1824	Maroon-tailed parakeet	C	1
<i>Ramphastos tucanus</i>	Linnaeus, 1758	White-throated toucan	C	2
<i>Rhea americana</i>	Linnaeus, 1758	Greater rhea	C	2

in golden-winged parakeet (*Brotogeris chrysoptera* Linnaeus, 1766) from Brazil, a bird of the same genus as the yellow-chevroned parakeet (*B. chiriri*) of this report, which is the first occurrence of *Ascaridia* spp. parasitizing *B. chiriri*.

Rosa (2003) stated that eggs from parasites of the superfamily Ascaridoidea Baird, 1853 are among the ones most frequently found by the flotation method in ratite birds. The author reported the occurrence of *Ascaridia* spp. in emus (*D. novaehollandiae*) in Rio de Janeiro. In a study by Mattos et al. (2011), *Ascaridia* spp. eggs presented the second highest prevalence in ostrich fecal samples analyzed in Rio Grande do Sul. Vicente et al. (1995) reported the presence of *Ascaridia orthocerca* Tossich, 1902 in greater rhea (*R. americana*) in Brazil. Gallo et al. (2020) reported the importance of ascarid

infection in ratites, although the genus *Baylisascaris* Sprent, 1968 has been reported with greater relevance in this group of hosts.

Parasites of genus *Ascaridia* are monoxenic (Taylor et al., 2016). Monoxenic parasites easily infect wild birds and mammals, with direct cycle and environmental resistance (Santos et al., 2015). According to Ritchie et al. (1994) ascariasis was an recurrent gastrointestinal parasitic infections in Psittaciformes, causing weight loss, anorexia, and death. The most common injury in these parasitic infections was associated to intestinal obstruction (González-Acuña et al., 2007; Hodová et al., 2008; Melo et al., 2013). Considering the monoxenic cycle, in addition to the treatment of parasitized birds, sanitary measures and cleaning of the environment must be adopted, and control of the population density of birds (Taylor et al., 2016).

**Table 2.** Helminth eggs and protozoan oocyst identified in fecal samples from captive © and free-living (FL) birds in Goiania Zoo collected between 20 Aug 2018 and 26 Jan 2019.

Host Specie	Condition	N <sup>1</sup>	Positive	Parasite Specie	Life Cycle Type	First Description
<i>Amazona amazonica</i>	C	2	2	Unidentified nematode	-	-
<i>Anodorhynchus hyacinthinus</i>	C	2	1	<i>Capillaria plagiaticia</i>	Monoxenic	Freitas & Mendonça, 1959
				<i>Eimeria</i> spp.	Monoxecic	Schneider, 1875
<i>Ara chloropterus</i>	C	1	1	<i>Capillaria</i> spp.	*	Zeder, 1800
<i>Ara</i> spp.	C	2	2	<i>Capillaria plagiaticia</i>	Monoxenic	Freitas & Mendonça, 1959
				<i>Diphyllobothrium</i> spp.	Heteroxenic	Cobbold, 1858
<i>Ardea alba</i> <sup>2</sup>	FL	2	2	<i>Diphyllobothrium</i> spp.	Heteroxenic	Cobbold, 1858
				<i>Eustrongylides</i> spp.	Heteroxenic	Jägerskiöld, 1909
<i>Brotogeris chiriri</i>	FL	2	2	<i>Ascaridia</i> spp.	Monoxenic	Dujardin, 1845
<i>Dromaius novaehollandiae</i>	C	1	1	<i>Ascaridia</i> spp.	Monoxenic	Dujardin, 1845
<i>Nycticorax nycticorax</i>	FL	3	2	<i>Diphyllobothrium</i> spp.	Heteroxenic	Cobbold, 1858
<i>Pavo cristatus nigripennis</i>	C	1	1	Ascarididae	*	Baird, 1853
<i>Penelope jacucaca</i>	C	1	1	<i>Capillaria</i> spp.	*	Zeder, 1800
<i>Ramphastos tucanus</i>	C	2	1	<i>Capillaria venusta</i>	Monoxenic	Freitas & Mendonça, 1958
<i>Rhea americana</i>	C	2	2	<i>Ascaridia</i> spp.	Monoxenic	Dujardin, 1845

<sup>1</sup> N is the number of individuals per species present in the zoo. All individuals of each species were analyzed. <sup>2</sup> Co-infection was observed. \*The type of biological cycle can be different at the species level.

The egg identified in *P. cristatus nigripennis* (black-shouldered peacock) belongs to the Ascarididae family. Within this family, the parasites most commonly found in Galliformes Temminck, 1820 birds belong to the genera *Ascaridia* and *Heterakis* Schrank, 1790 (Atkinson et al., 2008; Taylor et al., 2016). In line with this, Cubas et al. (2014) stated that parasites from these genera are common in Galliformes birds, particularly those kept in captivity. The nematodes *Ascaridia galli* Schrank, 1788, *Ascaridia columbae* Gmelin, 1790 and *Ascaridia perspicillum* Rudolphi, 1803 have already been identified in *P. cristatus* (Atkinson et al., 2008). Titilincu et al. (2009) reported that eggs of *Ascaridia* spp. and *Heterakis* spp. parasites were present in 59.9% of the *P. cristatus* samples they analyzed. Costa et al. (2018) reported the presence of *H. gallinarum* Schrank, 1788 in the cecal lumen of necropsied *P. cristatus* on a farm in the state of Rio Grande do Sul, Brazil. The birds presented clinical signs suggestive of *Histomonas meleagridis* Smith, 1895 infection, which is a parasitic protozoan that uses *H. gallinarum* nematodes as intermediate hosts.

Most ascaridids have a monoxenic cycle (Taylor et al., 2016), however Sprent (1954) described that certain species of the group utilize intermediate or paratenic hosts in life cycle. Thus, discussing control strategies becomes a difficult process without more specific identification. The treatment of parasitized birds is recommended, as infections by ascaridids can lead peacocks to death (Ramos et al., 2018).

Nematodes of the genus *Capillaria* are among the main parasites of Psittaciformes birds, including macaws

(Cubas et al., 2014). Santos et al. (2015) identified *Capillaria* spp. in 44.2% of fecal samples from Psittaciformes birds from the Wild Animal Screening Center of Pernambuco, including two specimens of *A. chloropterus* (Red-and-green macaw). Hofstatter and Guaraldo (2015) identified *Capillaria* spp. in *A. chloropterus* specimens from Itatiba Zoo, and also confirmed the presence of this genus in all the zoos of their study. This nematode was also identified in birds of the genus *Penelope* Merrem, 1786 at Dois Irmãos zoo in Recife (Cunha, 2007). The occurrence of *Capillaria* spp. in *A. chloropterus* and *P. jacucaca* is a common problem in zoo and captive animals and can become a bigger problem if the population density of birds is not regulated (Godoy, 2007). Godoy (2007) reports that despite some species of *Capillaria* spp. present annelids as intermediate hosts, most have a monoxenic cycle with high distribution and occurrence in environments with inadequate hygiene conditions, which is an important aspect in the control of parasitosis.

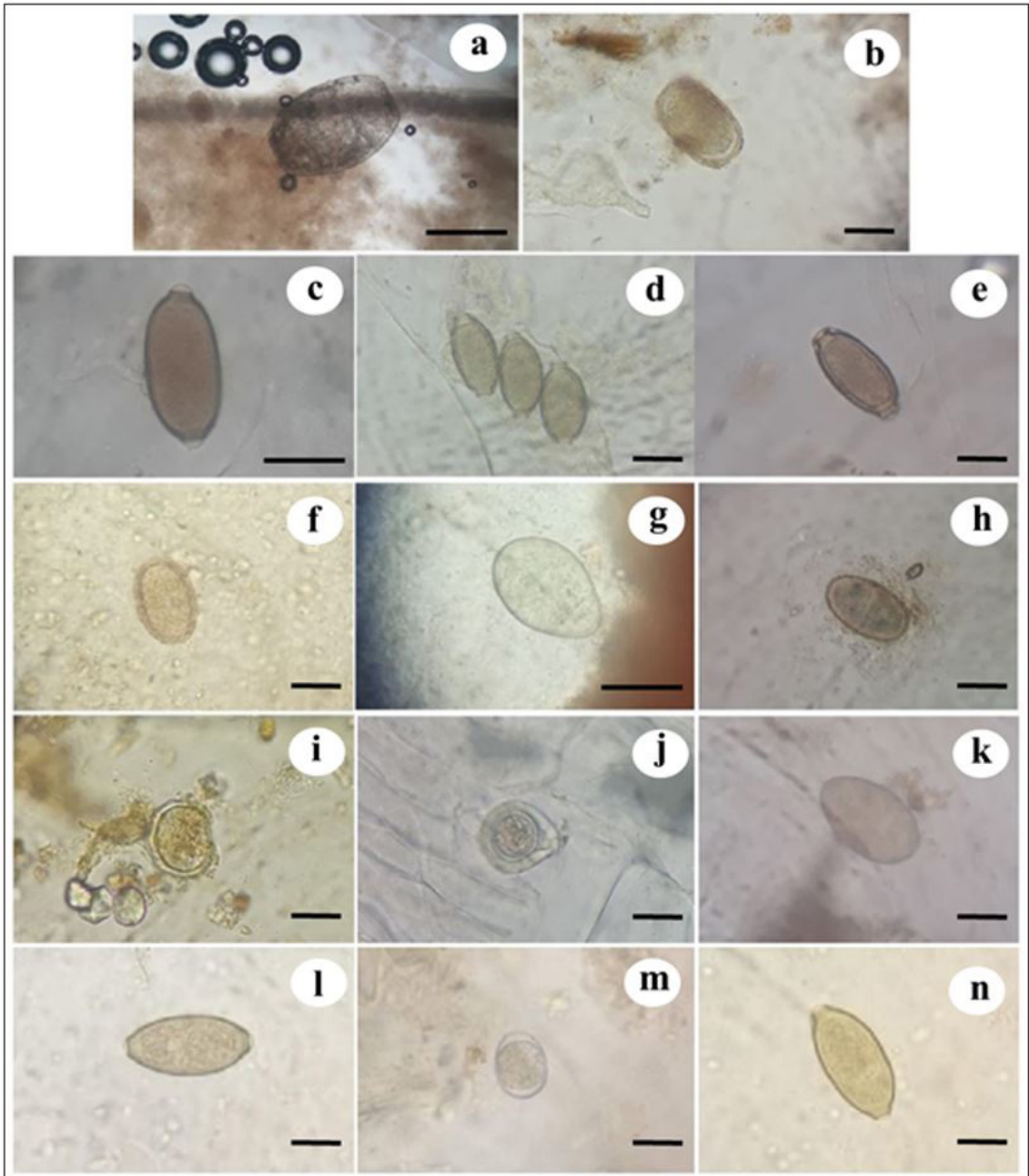
Prathipa et al. (2013) also reported that *C. plagiaticia* specifically infects Psittaciformes. In a study by Snak et al. (2014), 43.3% of the fecal samples testing positive for parasites in birds at Danilo Galafassi Municipal Zoo in Cascavel, state of Paraná, were mixed infections, that included six samples from *Ara ararauna* Linnaeus, 1758, and contained oocysts of *Eimeria* spp. Schneider, 1875. The occurrence of *C. plagiaticia* has been previously reported in *A. hyacinthinus* and *Ara* spp. by Hofstatter (2011), which describes *C. plagiaticia* parasitizing 11 species of Psittaciformes. This parasite was considered to be specific



to psittacids (Kajerová and Baruš, 2005), being reported from different countries and continents (Weekes, 1982; Valdebenito et al., 2015).

Cubas et al. (2014) reported that *Capillaria columbae* Rudolphi, 1819 and *Capillaria obsignata* Madsen, 1945

were the main species infecting Ramphastidae, a family of birds that includes toucans. These authors also reported that capillariosis is the main parasitic disease that affects these birds in captivity in Brazil and that it can be fatal to toucans. However, the *Capillaria* species found in the



**Figure 1.** Helminth eggs found in the feces of captive and free-living birds at Goiania Zoo. (a) unidentified nematode in a fecal sample from *Amazona amazonica*, Bar = 20µm; (b) Ascarididae family egg found in *Pavo cristatus nigripennis* fecal samples, Bar = 20µm; (c) *Capillaria* sp. egg identified in *Ara chloropterus* fecal sample, Bar = 20µm; (d) *Capillaria venusta* eggs identified in *Ramphastos tucanus* fecal sample, Bar = 20µm; (e) *Capillaria* spp. egg identified in *Penelope jacucaca* fecal sample, Bar = 20µm; (f) and *Diphyllbothrium* spp. (g) eggs found in *Ardea alba* fecal sample, Bar = 20µm; *Ascaridia* spp. eggs found in *Brotogeris chiriri* (h), Bar = 20µm, *Rhea americana* (i) and *Dromaius novaehollandiae* (j) fecal samples, Bar = 20µm; (k) *Diphyllbothrium* sp. egg found in *Nycticorax nycticorax*; *Capillaria plagiaticia* egg (l) and *Eimeria* sp. oocyst (m) found in *Anodorhynchus hyacinthinus* fecal sample, Bar = 10 µm; and (n) *Capillaria plagiaticia* egg found in *Ara* sp. fecal sample, Bar = 20µm.

white-tailed toucan (*R. tucanus*) specimen in this report was *Capillaria venusta*, the first host record to this parasite. In addition, Atkinson et al. (2008) described the presence of *C. venusta* in toco toucan (*Ramphastos toco* Muller, 1776) and the green-billed toucan (*Ramphastos dicolorus* Linnaeus, 1766).

Two captive birds with capillariasis (*A. chloropterus* and *R. tucanus*), presented clinical signs of prostration, finicky appetite, weight loss and dehydration. Snak et al. (2014) reported that parasitic diseases are more frequent among captive wild animals than in free-living animals, due to predisposing factors such as stress and inadequate sanitary management. Furthermore, these authors stated that restricted areas enable parasites to complete their cycles within the enclosure (Snak et al., 2014). Captive birds with inapparent infections reinforce the need to perform periodic parasitological evaluations. According to Cubas et al. (2014), such evaluations should be done at 3 or 4-month intervals to ensure the early diagnosis of parasitic infections. Considering the monoxenic cycle of *C. plagiaticia* and *C. venusta*, control of the dispersion of eggs in the environment is necessary, and can be performed with periodic removal of the surface layers of the substrate and feces from the cages, hygiene and disinfection and measures of sanitary vacuum (Godoy, 2007), in addition to the quarantine of newly introduced birds (Dislich, 2007).

The *R. tucanus* specimen had a history of recurrent infections by *Capillaria* spp., and due to its physical limitations, the bird spent more time on the floor of its enclosure, possibly facilitating reinfection. The floor and walls of its enclosure were disinfected with fire in order to control intermediate hosts and prevent further reinfections. With regard to control and treatment measures, Cubas et al. (2014) stated that using fire in animal enclosures does not ensure the destruction of *Capillaria* eggs, and that boiling water is more effective. Drug therapies are more effective when they are based on the diagnosis of a coproparasitological analysis (Bowman, 2014; Cubas et al. 2014). According to Tully et al. (2010), after concluding a treatment the co-parasitological analysis should be repeated to ascertain its efficacy. The birds that presented persistent infections after treatment were treated again using different bases. Cubas et al. (2014) describes difficulty in controlling capillariasis in toucans due to resistance to anthelmintic drugs by *Capillaria* spp. species, also associated with the rapid intestinal transit of toucans causing low absorption of the drug, increases the importance of environmental strategies of parasitosis control.

*Eimeria* spp. is coccidian parasites, that causes a recurrent infection in many species of birds (Taylor et al., 2016), and has been reported parasitizing Psittaciformes Wagler, 1830 (Farr, 1960; Todd et al., 1977; Upton and Wright, 1994; Hofstatter and Kawazoe, 2011). The infection involves a direct cycle, which leads to the occurrence of the disease with destruction of the host's intestinal epithelial cells (Long, 1987). Like most parasites mentioned in this study, the factors that predispose the occurrence of parasitosis are related to population density and are common in captive birds,

being controlled with hygiene measures similar to those already mentioned for other parasites, and administration of anticoccidial drugs (Taylor et al., 2016).

Like this study, Fithri (2017) reported the occurrence *Dipyllobothrium* spp. eggs in *N. nycticorax* (black-crowned night heron). The *N. nycticorax* and *A. alba* (great egret) specimens of this report were free-living birds and the infection may have resulted from their habit of feeding on infected fish, since the genus needs intermediate hosts that are mainly fish and have wide distribution in nature (Taylor et al., 2016).

Atkinson et al. (2008) reported that parasites of the genus *Eustrongylides* widely distributed throughout the world, including tropical regions, and the species *Eustrongylides ignotus* Jägerskiöld, 1909 have been identified in most reports from Central and South America. According to Cubas et al. (2014), Ciconiiformes Bonaparte, 1854 and Pelecaniformes Sharpe, 1891 birds become infected with this parasite by eating fish containing larvae of the parasite. Vicente et al. (1995) reported that *E. ignotus* and *Eustrongylides perpapillatus* Jägerskiöld, 1909 occurred in Brazil, and the latter has already been identified in *A. alba*. The species *E. ignotus* has also been found in *A. alba* by Spalding and Forrester (1993).

Zoos located in urban centers often attract free-living animals such as rats, herons, vultures and pigeons. This facilitates contact between free-living and captive animals and is a major contributing factor to the infection of animals living in captivity (Snak et al., 2014). This situation may have occurred in Goiânia Zoo, given the proximity of free-living animals in the proximities (or at least their excreta) and even inside the zoo enclosures in search of food.

These parasites can generate clinically worrisome conditions, such as those observed in some of the captive species of this report. The presence of helminth eggs in the zoo's captive birds indicates the need for targeted treatments, efficient sanitary management to control intermediate hosts, and proper disinfection of the enclosures. Moreover, it should be kept in mind that contact between free-living and captive birds may play an important role in triggering infections among the zoo's birds. The main route of infection of free-living birds may have been the ingestion of intermediate hosts and, so far, few reports are available about the clinical significance of parasites in these individuals.

## Acknowledgements

To Goiania Zoo for all support provided.

## References

- ATKINSON, C.T., THOMAS, N.J. and HUNTER, D.B., 2008. *Parasitic diseases of wild birds*. Ames: Blackwell, 595 p. <http://dx.doi.org/10.1002/9780813804620>.
- BORGSTEEDE, F.H.M., 1996. The effect of parasites on wildlife. *The Veterinary Quarterly*, vol. 18, suppl. 3, pp. 138-140. <http://dx.doi.org/10.1080/01652176.1996.9694717>. PMID:8933697.

- BOWMAN, D.D., 2014. *Georgis' parasitology for veterinarians*. 10<sup>th</sup> ed. Saint Louis: Elsevier Health Sciences, 499 p.
- CARNEIRO, M.B., CALAIS-JÚNIOR, A. and MARTINS, I.V.F., 2011. Avaliação coproparasitológica e clínica de aves silvestres e exóticas mantidas em criatórios particulares no município de Alegre-ES. *Ciência Animal Brasileira*, vol. 12, no. 3, pp. 525-529. <http://dx.doi.org/10.5216/cab.v12i3.6821>.
- CARPENTER, J.W., 2010. *Exotic animal formulary*. 3rd ed. Philadelphia: W.B. Saunders, 423 p.
- COSTA, R. A., PEREIRA, A. P. M., SILVEIRA, C. S. and ANJOS, B. L., 2018. Infecção natural por *Histomonas meleagridis* em pavões-indianos (*Pavo cristatus*). *Acta Scientiae Veterinariae*, vol. 46, suppl. 1, e333. <https://doi.org/10.22456/1679-9216.88166>.
- CUBAS, Z.S., SILVA, J.C.R. and CATÃO-DIAS, J.L., 2014. *Tratado de animais selvagens*. 2<sup>nd</sup> ed. São Paulo: Roca. 2512 p.
- CUNHA, A.L.B., 2007. *Prevalência de endo e ectoparasitas em cracídeos criados em cativeiro no Parque Dois Irmãos, Recife-PE*. Recife: Universidade Federal Rural de Pernambuco, 42 p. Dissertação de Mestrado em Ciência Animal.
- DISLICH, M., 2007. Tinamiformes (Macuco, Inhambu, Perdiz. In: Z.S. CUBAS, J.C.R. SILVA and J.L. CATÃO-DIAS. *Tratado de Animais Selvagens*. São Paulo: Roca, pp. 158-168.
- FARR, M.M., 1960. *Eimeria dunsingi* n.sp. (Protozoa: Eimeriidae) from the intestine of a parakeet, *Melopsittacus undulatus* (SHAW). Ciudad de México: Editorial Politécnica, pp. 31-35. Libro Homenaje als Dr. Eduardo Caballero y Caballero.
- FITHRI, K., 2017. *Identification of worm in black crowned night heron (Nycticorax nycticorax) in Ujung Pangkah Gresik*. Indonésia: Perpustakaan Universitas Airlangga. Doctoral Thesis in Veterinary Medicine.
- FREITAS, M.F.L., OLIVEIRA, J.B., CAVALCANTI, M.D.B., LEITE, A.S.L., MAGALHÃES, V.S., OLIVEIRA, R.A. and SOBRINO, A.E., 2002. Parasitos gastrointestinais de aves silvestres em cativeiro em el estado de Pernambuco, Brasil. *Parasitología Latinoamericana*, vol. 57, pp. 50-54.
- GALLO, S.S.M., TEIXEIRA, C.S., EDERLI, N.B. and OLIVEIRA, F.C.R., 2020. Gastrointestinal parasites of a population of emus (*Dromaius novaehollandiae*) in Brazil. *Brazilian Journal of Biology = Revista Brasileira de Biologia*, vol. 80, no. 1, pp. 66-72. <http://dx.doi.org/10.1590/1519-6984.189922>. PMID:31116295.
- GODOY, S.N., 2007. Psittaciformes (Arara, Papagaio, Periquito). In: Z.S. CUBAS, J.C.R. SILVA and J.L. CATÃO-DIAS. *Tratado de animais selvagens*. São Paulo: Roca. pp. 222-251.
- GONZÁLEZ-ACUÑA, D., FABRY, M., NASCIMENTO, A.A. and TEBALDI, J.H., 2007. Death of two slender-billed parakeet (King) (*Encognathus leptorhynchus*) (Aves, Psittacidae) by *Ascaridia hermaphrodita* (Froelich, 1789, Railliet & Henry, 1914) at the National Zoo of Santiago, Chile. *Arquivo Brasileiro de Medicina Veterinária e Zootecnia*, vol. 59, no. 2, pp. 539-540. <http://dx.doi.org/10.1590/S0102-09352007000200044>.
- HODOVÁ, I., BARUS, V. and TUKAC, V., 2008. Note on morphology of two nematode species *Ascaridia hermaphrodita* and *Ascaridia platyceri* (Nematoda): scanning electron microscope study. *Helminthologia*, vol. 45, no. 3, pp. 109-113. <http://dx.doi.org/10.2478/s11687-008-0021-4>.
- HOFSTATTER, P.G. and GUARALDO, A.M.A., 2015. Parasitological survey on birds at some selected brazilian zoos. *Revista Brasileira de Parasitologia Veterinária*, vol. 24, no. 1, pp. 87-91. <http://dx.doi.org/10.1590/S1984-296120150005>. PMID:25909259.
- HOFSTATTER, P.G. and KAWAZOE, U., 2011. Two new *Eimeria* species (Apicomplexa: Eimeriidae) from the Yellow-Crowned Amazon, *Amazona ochrocephala* (aves: Psittacidae). *The Journal of Parasitology*, vol. 97, no. 3, pp. 503-505. <http://dx.doi.org/10.1645/GE-2681.1>. PMID:21506846.
- HOFSTATTER, P.G., 2011. *Contribuições ao perfil parasitológico de Psittacidae e descrição de uma nova espécie de Eimeria*. Campinas: Instituto de Biologia, Universidade Estadual de Campinas, 52 p. Dissertação de mestrado em Parasitologia.
- KAJEROVÁ, V. and BARUŠ, V., 2005. Psittacine birds (Aves: Psittaciformes) as new hosts of *Baruscapillaria obsignata* (Nematoda: Capillariidae). *Acta Veterinaria Brno*, vol. 74, no. 4, pp. 571-574. <http://dx.doi.org/10.2754/avb200574040571>.
- KAJEROVA, V., BARUS, V. and LITERAK, I., 2004. Nematodes from the genus *Ascaridia* parasitizing psittaciform birds: a review and determination key. *Veterinarni Medicina*, vol. 49, no. 6, pp. 217-223. <http://dx.doi.org/10.17221/5698-VETMED>.
- LONG, P.L., 1987. Coccidiosis in poultry. *CRC Critical Review*, vol. 1, pp. 25-50.
- LUTZ, A.O., 1919. *Schistosomum mansoni* e a Schistosomatose segundo observações, feitas no Brasil. *Memorias do Instituto Oswaldo Cruz*, vol. 11, no. 1, pp. 121-155. <http://dx.doi.org/10.1590/S0074-02761919000100006>.
- MATTOS, M.J.T., RIBEIRO, V.S. and MARQUES, S.M.T., 2011. Parasitismo gastrointestinal e aspectos do manejo de avestruzes (*Struthio camelus*) de pequenas propriedades do Rio Grande do Sul, Brasil. *Veterinária em Foco*, vol. 8, no. 2, pp. 143-151.
- MELO, C.M.F., OLIVEIRA, J.B., FEITOSA, T.F., VILELA, V.L.R., ATHAYDE, A.C.R., DANTAS, A.F.M., WAGNER, P.G.C. and FEBRÔNIO, A.B., 2013. Parasites of Psittaciformes and Accipitriformes in Paraíba state, northeastern Brazil. *Revista Brasileira de Medicina Veterinária*, vol. 22, no. 2, pp. 314-317. <http://dx.doi.org/10.1590/S1984-29612013000200051>. PMID:23856738.
- PRATHIPA, G., JAYATHANGARAJ, M.G., SANKARALINGAM, G. and THANGAYELU, A., 2013. Prevalence of endoparasites in captive psittacine birds belonging to pet shops and private residences in and around Chennai. *International Journal of Veterinary Science*, vol. 2, no. 2, pp. 58-60.
- RAMOS, D.G.S., SILVA, A.P.J., ABREU, R.R., WESSEL, A.C.R., SILVA, N.G., OLIVEIRA, I.B., NUNES, L.F.B., FREITAS, M.R. and SATURNINO, K.C., 2018. Ocorrência e lesões causadas por ascarídeos em *Pavo cristatus* (Phasianidae) de criatório não comercial em Jatá, Goiás. *Brazilian Journal of Animal and Environmental Research*, vol. 1, no. 2, pp. 268-275.
- RITCHIE, B.W., HARRISON, G.J. and HARRISON, L.R., 1994. Parasites. In: E.C. GREINER and B.W. RITCHIE. *Avian medicine: principles and application*. Flórida: Wingers Publishing; 1994. p. 1007-1009.
- ROSA, F.G.D.I., 2003. *Apostila de criação de avestruzes*. São Paulo: Struthio Consult, 159 p.
- SANTOS, P.M.S., SILVA, S.G.N., FONSECA, C.F. and OLIVEIRA, J.B., 2015. Parasitos de aves e mamíferos silvestres em cativeiro no estado de Pernambuco. *Pesquisa Veterinária Brasileira*, vol. 35, no. 9, pp. 788-794. <http://dx.doi.org/10.1590/S0100-736X2015000900004>.
- SHEATHER, A.L., 1923. The detection of intestinal protozoa and mange parasites by a flotation technique. *The Journal of Comparative Pathology and Therapeutics*, vol. 36, pp. 266-275. [http://dx.doi.org/10.1016/S0368-1742\(23\)80052-2](http://dx.doi.org/10.1016/S0368-1742(23)80052-2).
- SNAK, A., LENZI, P.F., AGOSTINI, K.M., DELGADO, L.E., MONTANUCCI, C.C. and ZABOTT, M.V., 2014. Análises coproparasitológicas de aves silvestres cativas. *Ciência Animal Brasileira*, vol. 15, no. 4, pp. 502-507. <http://dx.doi.org/10.1590/1089-6891v15i425797>.
- SPALDING, M.G. and FORRESTER, D.J., 1993. Pathogenesis of *Eustrongylides ignotus* (Nematoda: Dioctophymatoidea) in Ciconiiformes. *Journal of Wildlife Diseases*, vol. 29, no. 2, pp. 250-260. <http://dx.doi.org/10.7589/0090-3558-29.2.250>. PMID:8487374.

- SPRENT, J.F., 1954. The life cycles of nematodes in the family Ascarididae Blanchard 1896. *The Journal of Parasitology*, vol. 40, no. 5, pt 1, pp. 608-617. <http://dx.doi.org/10.2307/3274028>. PMID:13202021.
- TAYLOR, M.A., COOP, R.L. and WALL, R.L., 2016. *Veterinary parasitology*. 4th ed. Hoboken: Wiley Blackwell, 1006 p.
- TITILINCU, A., MIRCEAN, V., BEJAN, A., IOVU, A., UNGUREANU, R. and COZMA, V., 2009. Prevalence of Endoparasites in Peacocks (*Pavo cristatus*). *Scientific Parasitologica*, vol. 1, no. 2, pp. 101-105.
- TODD, K.S., GALLINA, A.M. and SCHMIDT, J.M., 1977. *Eimeria dunsingi* Farr 1960: A coccidium of parakeet, *Melopsittacus undulatus*. *Proceedings of the Helminthological Society of Washington*, vol. 44, pp. 188-190.
- TULLY, T.N., DORRESTEIN, G.M. and JONES, A.K., 2010. *Clínica de aves*. 2<sup>nd</sup> ed. Rio de Janeiro: Elsevier, 344 p.
- UPTON, S.J. and WRIGHT, T.F., 1994. A new species of *Eimeria* (Apicomplexa) from the orange-fronted conure, *Aratinga canicularis* (Psittaciformes), in Costa Rica. *Acta Protozoologica*, vol. 33, pp. 117-119.
- VALDEBENITO, J.O., MORENO, L., LANDAETA-AQUEVEQUE, C., KINSELLA, J.M., MIRONOV, S., CICCHINO, A., TRONCOSO, I. and GONZÁLEZ-ACUÑA, D., 2015. Gastrointestinal and external parasites of *Enicognathus ferrugineus* and *Enicognathus leptorhynchus* (Aves, Psittacidae) in Chile. *Revista Brasileira de Parasitologia Veterinária*, vol. 24, no. 4, pp. 422-431. <http://dx.doi.org/10.1590/S1984-29612015074>. PMID:26648008.
- VICENTE, J.J., RODRIGUES, H.O., GOMES, D.C. and PINTO, R.M., 1995. Nematóides do Brasil. Parte IV: nematóides de aves. *Revista Brasileira de Zoologia*, vol. 12, suppl. 1, pp. 1-273. <http://dx.doi.org/10.1590/S0101-81751995000500001>.
- WEEKES, P.J., 1982. Checklist of helminth parasites of birds in New Zealand. *New Zealand Journal of Zoology*, vol. 9, no. 4, pp. 451-460. <http://dx.doi.org/10.1080/03014223.1982.10423876>.
- ZAJAC, A.M. and CONBOY, G.A., 2012. *Veterinary clinical parasitology*. 8<sup>th</sup> ed. Hoboken: Wiley-Blackwell, 354 p.