

Original Article

## ***Myxobolus* spp. (Cnidaria: Myxobolidae) in the circulating blood of fishes from Goiás and Mato Grosso States, Brazil: case report**

*Myxobolus* spp. (Cnidaria: Myxobolidae) no sangue circulante de peixes dos estados de Goiás e Mato Grosso, Brasil: relato de caso

L. P. Úngari<sup>a\*</sup> , D. H. M. D. Vieira<sup>a</sup> , A. L. Q. Santos<sup>b</sup> , R. J. da Silva<sup>a</sup>  and L. H. O'Dwyer<sup>a</sup> 

<sup>a</sup>Setor de Parasitologia, Departamento de Bioestatística, Biologia vegetal, Parasitologia e Zoologia – DBBVPZ, Instituto de Biociências, Universidade Estadual Paulista – UNESP, Botucatu, SP, Brasil

<sup>b</sup>Laboratório de Ensino e Pesquisa em Animais Silvestres – LAPAS, Faculdade de Medicina Veterinária, Universidade Federal de Uberlândia – UFU, Uberlândia, MG, Brasil

### Abstract

Myxosporidiosis is an infectious disease caused by myxozoans of the Phylum Cnidaria, Class Myxosporea, and Order Bivalvulida, considered a common parasite in fresh and saltwater fishes that parasitize many organs, especially gills. In the present study, 49 specimens of fishes belonging to eight genera: *Tetragonopterus*, *Leporinus*, *Myleus*, *Pirinampus*, *Rhapiodon*, *Pygocentrus*, *Ageneiosus*, and *Serrasalmus* were collected and blood smears were made, fixed with absolute methanol, and stained with Giemsa 10% to survey hemoparasites. However, myxospores were found in the circulating blood of five (10.20%) fishes belonging to genus *Tetragonopterus*, *Myleus*, and *Pygocentrus*. Two morphological types of *Myxobolus* spp. were identified in all the five fish specimens analyzed. Usually, investigations on myxozoans in fish are carried out with the search for plasmodia or cysts in the fish organs and observation of the cavity of organs. Nevertheless, this study highlights the importance of also examining the blood of these animals, since these parasites can cause severe pathogenic diseases in fish. Thus, the blood analyses can proportionate preventive sanitary control for commercial fish avoiding economic loss.

**Keywords:** Morphology, *Myleus*, *Pygocentrus*, *Tetragonopterus*, occurrence.

### Resumo

A mixosporidiose é considerada uma doença infecciosa causada por mixozoários pertencentes ao Filo Cnidaria, Classe Myxosporea e Ordem Bivalvulida, considerados parasitos comuns de peixes de água doce e salgada, parasitando vários órgãos, principalmente as brânquias. No presente estudo, 49 espécimes de peixes pertencentes a oito gêneros: *Tetragonopterus*, *Leporinus*, *Myleus*, *Pirinampus*, *Rhapiodon*, *Pygocentrus*, *Ageneiosus* and *Serrasalmus* foram coletados e extensões sanguíneas foram feitas com a finalidade de encontrar hemoparasitos. Entretanto, mixoesporos foram observados em cinco (10.20%) espécimes de peixes, pertencentes aos gêneros *Tetragonopterus*, *Myleus* e *Pygocentrus*. Dois morfotipos de *Myxobolus* spp. foram identificados parasitando esses peixes. Normalmente, as investigações sobre mixozoários em peixes é realizada com a procura de plasmódios ou cistos nos órgãos dos peixes e observação da cavidade de órgãos. Porém, esse trabalho ressalta a importância de se examinar também o sangue desses animais, já que esses parasitos podem ocasionar patologias severas em peixes. Sendo assim, a análise sanguínea pode proporcionar controle sanitário preventivo para peixes comerciais e evitar perdas econômicas.

**Palavras-chave:** Morfologia, *Myleus*, *Pygocentrus*, *Tetragonopterus*, ocorrência.

## 1. Introduction

Brazil has a large and dense hydrographic network distributed in eight major basins, with a considerable diversity of fishes and lucrative economy around farmed fish (Graça and Pavanelli, 2007). However, pathogenic parasites can cause fish diseases resulting in substantial economic losses to aquaculture and fisheries (Okamura et al., 2015).

Among the diseases reported in fishes, infections with myxozoans are frequently observed (Feist and Longshaw, 2006). These parasites belong to the Phylum

Cnidaria Hatschek, 1888 and Order Bivalvulida Shulman 1959; and until now, more than 2,400 species have been described (Eiras et al., 2014; Vidal et al., 2017). Regarding the genus *Myxobolus* Bütschli 1882, about 900 species were described so far, which approximately 60 were described from Brazilian fishes (Lom and Dyková, 2006; Okamura et al., 2015).

The pathogenesis reported so far, includes reduced respiratory capacity (Adriano et al., 2005), intestinal

\*e-mail: letspungari@hotmail.com

Received: August 27, 2020 – Accepted: November 5, 2020



This is an Open Access article distributed under the terms of the Creative Commons Attribution License, which permits unrestricted use, distribution, and reproduction in any medium, provided the original work is properly cited.

necrosis (Alvarez-Pellitero et al., 2008), longitudinal compressions of the body (Longshaw et al., 2003), degenerative cardiomyopathy (Yokoyama et al., 2005), and significant mortalities in wild and farmed fishes (Naldoni et al., 2009).

During a hemoparasite survey of fishes from Goiás and Mato Grosso States, Brazil, myxospores of myxozoans were observed in the blood of some specimens. This study reported the presence of two different morphotypes of *Myxobolus* spp. parasitizing *Tetragonopterus araguaiensis* Silva, Melo, Oliveira, and Benine, 2013, *Myleus rubripinnis* (Müller and Troschel, 1844), and *Pygocentrus nattereri* Kyner, 1858.

## 2. Material and Methods

In July 2017, blood samples of 49 fishes belonging to eight genera were collected during field surveys in two distinct localities: species of *Leporinus*, *Myleus*, *Pirinampus*, *Potamotrygon*, *Rhapiodon*, *Pygocentrus*, and *Tetragonopterus* were captured at the Vermelho Red River (14°57'08.4" S and 51°06'30.7" W), municipality of Britânia, Goiás State, Brazil; and two genera, *Pygocentrus* and *Serrasalmus*, at the Celeste Lake (14°46'32.27" S and 51°32'50.29" W), municipality of Barra do Garças, Mato Grosso State, Brazil.

All applicable international, national, and/or institutional guidelines for the care and use of animals were followed (Ibama Licences: 60640-1, 52063-3, 17625-4; CEUA-UFU approval: 106/15).

The fishes were captured by fishing rod and were submitted to blood collection with disposable and sterile 1 mL syringes and needles (13 x 4.5 mm), by puncturing the caudal vein. Three blood smears per specimen were made, fixed with methanol, stained with Giemsa Eosin Methylene Blue (Eisen and Schall, 2000), and examined using an optical microscope (Leica DMLB 5000, Leica Microsystems, Wetzlar, Germany) at 40x and 100x magnification.

Morphometric measurements of spore length, spore width, polar capsule length, polar capsule width, sporoplasm length, and sporoplasm width from myxospores were taken from digital images at 1000x magnification, under light microscopy with Leica software application suite LAS V3.8 (Leica Microsystems).

## 3. Results

From 49 specimens screened, myxospores were found in circulating blood of five (10.20%) fishes, being one *T. araguaiensis*, two *M. rubripinnis*, and two *P. nattereri* (Table 1).

Through the morphological analysis, it is possible to observe myxospores with two polar capsules with similar sizes and without a tail projection. Therefore, these morphological characteristics are compatible with the genus *Myxobolus* (Figure 1). Moreover, the morphometric analysis revealed two different morphotypes of *Myxobolus* spp. (Figure 1 and Table 1). The first one (M1), identified in blood smears of *T. araguaiensis*, revealed larger measures concerning the second morphotype (M2), identified in the blood smears of *M. rubripinnis* and *P. nattereri* (Table 1).

## 4. Discussion

In the literature, studies on myxozoans infecting fishes have been developed using morphological, morphometric, and molecular diagnostic tools, with a great number of new species being reported over the years. Regarding the molecular tool, normally, the DNA extraction is made direct from parasite cyst or plasmodia, which contains myxospores (Lom and Arthur, 1989; Úngari et al., 2019). In this study, few myxospores were found in the circulating blood of fishes, thus the parasite DNA extraction from the blood, and consequently its amplification did not succeed. Therefore, there is a need for a standardized DNA extraction method from the blood for myxozoans.

Regarding the myxobolid group, *Myxobolus* and *Henneguya* Thélohan, 1892, are commonly reported in fishes. The main morphological difference between these genera is that *Henneguya* spp. have spore projections (Lom and Dyková, 2006; Úngari et al., 2019). Thus, through morphological analysis, it was possible to state the infection with *Myxobolus* spp. in the circulating blood of the five positive fishes from this study.

There are no reports on myxozoans parasitizing *Tetragonopterus* spp. and *Myxobolus* sp. parasitizing *P. nattereri*, being this study the first one. However, *Myxobolus myleus* Azevedo, Clemente, Casal, Matos, Alves, Al-Quraishy and Matos, 2012 was described parasitizing the gall bladder from *M. rubripinnis* (Azevedo et al., 2012). When compared morphometrically with *Myxobolus* sp. (M2) found parasitizing the blood of *M. rubripinnis* in this study, large differences were observed. *Myxobolus myleus* has a larger body when compared to *Myxobolus* sp. M2 ( $19.3 \pm 0.5$  vs  $9.37 \pm 1.75$ ). Besides, differences in body width are observed ( $8.3 \pm 0.5$  vs  $6.43 \pm 0.93$ ).

Myxozoans parasitize various organs of fresh and saltwater fishes; can be found in intracellular spaces, inside cells, gills, spleen, liver, kidney, and musculature (Maciel et al., 2011). According to Eiras et al. (2006), myxozoans can also be found in circulating blood and blood vessels. Maciel et al. (2011) reported myxozoans in blood smears of tambaqui, *Colossoma macropomum* Cuvier, 1818 (Osteichthyes, Characidae). Although less frequent, the spores present in circulating blood of fish can be explained as a part of the life cycle of some *Myxobolus* species, reported by Molnár (2002). Another possible explanation is that blood tissue is also considered a form of a dispersion of these pathogens to other organs of the fishes (Maciel et al., 2011).

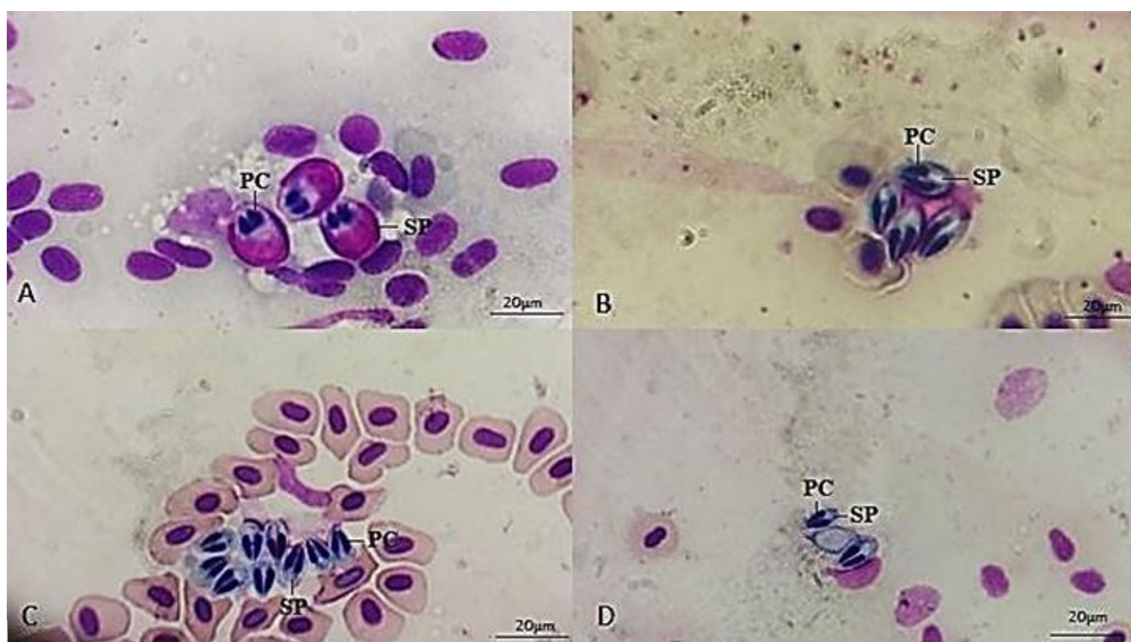
Lom et al. (1983) reported the presence of *Sphaerospora molnari* Lom, Dyková and Pavlásková, 1983 in the circulating blood of *Cyprinus carpio* Linnaeus, 1758 from Europa. The blood contained numerous developmental stages, beginning with early pseudoplasmodia containing one sporogonic cell (Lom et al., 1983). In this study, only mature myxospores of *Myxobolus* spp. were observed.

Notwithstanding, it has been suggested that the screening of spores in the fish blood is questionable since the low-intensity parasitosis and few reports in the literature (Eiras et al., 2006; Maciel et al., 2011). However, the circulating blood and tissue blood should also be investigated for the presence of myxozoans since

**Table 1.** Morphometric characteristics of the *Myxobolus* spp. (M1 and M2) myxospores reported in the blood of fishes from Goiás State and Mato Grosso State, Brazil.

Hosts	Fish data		Myxospores measurements										N <sup>o</sup>
	N (P %)	Size (mm)	State		SL (µm)	PCL (µm)	SPL (µm)	SW (µm)	PCW (µm)	SPW (µm)			
<i>Tetragonopterus araguaiensis</i>	1 (2.04)	48.10	GO	M ± SD	15.20±0.59	6.99±0.36	5.73±0.09	9.30±0.46	3.12±0.48	6.79±0.37		13	
				Max - Min	15.59- 14.51	7.36-6.64	5.81-5.62	9.67-8.77	3.71-2.80	7.22-6.54			
<i>Myiulus rubripinnis</i>	2 (4.08)	270.22	GO	M ± SD	9.37±1.75	3.70±1.73	3.79±1.75	6.43±0.93	2.30±0.80	3.76±0.42		8	
				Max - Min	10.34-8.34	4.85-2.80	4.79-2.05	6.82-5.58	4.37-3.74	5.87-4.90			
<i>Pygocentrus nattereri</i>	2 (4.08)	199.30	GO	M ± SD	9.87±0.92	4.01±0.73	2.99±1.85	6.33±0.95	2.35±0.72	3.97±0.95		19	
				Max - Min	9.81-8.93	5.33-4.29	3.10-1.51	6.70-5.42	2.94-2.01	4.15-2.97			
Total	5 (10.2)		MT										

Number of positive individuals (N) and prevalence (P); Mean (M); Standard deviation (SD); maximum measure (Max); minimum measure (Min); spore length (SL); polar capsule length (PCL); sporoplasm length (SPL); spore width (SW); polar capsule width (PCW); sporoplasm width (SPW); morphological characteristics type 1 (M1); morphological characteristics type 2 (M2); Number of myxospores measured (N<sup>o</sup>); Goiás (GO); Mato Grosso (MT).



**Figure 1.** Blood smears of *Myxobolus* spp. parasites in the circulating blood of fishes from Goiás State and Mato Grosso State, Brazil (A-D): (A) Morphological type 1 (M1) of *Myxobolus* sp. in the blood of *Tetragonopterus araguaiensis*; (B-D) Morphological type 2 (M2) of *Myxobolus* sp. in the blood of *Myleus rubripinnis* (b) and *Pygocentrus nattereri* (c-d). Polar capsule (PC); Sporoplasm (SP).

blood can be part of its life cycle. Also, the blood smear analysis is low cost and can be used as a preventive sanitary control for commercial fish avoiding economic loss.

In conclusion, this study reported 10.20% prevalence of myxobolid mature spores infecting the circulation blood of Brazilian fishes from Goiás and Mato Grosso States, being the first record of myxozoans parasitizing a species of the genus *Tetragonopterus* and the first record of *Myxobolus* sp. parasitizing *P. nattereri*.

### Acknowledgements

We thank the team of the Laboratory for Teaching and Research in Wild Animals (LAPAS-UFU) and Non-governmental organization for the preservation of Brazilian wild animals (ONG PAS) for their assistance in the fish blood collection. All applicable international, national, and/or institutional guidelines for the care and use of animals were followed (Ibama Licences: 60640-1, 52063-3, 17625-4; CEUA-UFU approval: 106/15). R.J.S. is supported by CNPq #309125/2017-0. L.P.U. is supported by FAPESP #2018/00754-9 and # 2018q09623-4. L.H.O. is supported by FAPESP #2018/09623-4. D.H.M.D.V. is supported by FAPESP 2019/19060-0.

### References

ADRIANO, E.A., ARANA, S. and CORDEIRO, N.S., 2005. An ultrastructural and histopathological study of *Henneguya pellucida* n. sp. (Myxosporaea: Myxobolidae) infecting *Piaractus mesopotamicus* (Characidae) cultivated in Brazil. *Parasite (Paris,*

*France)*, vol. 12, no. 3, pp. 221-227. <http://dx.doi.org/10.1051/parasite/2005123221>. PMID:16218209.

ALVAREZ-PELLITERO, P., PALENZUELA, O. and SITJÀ-BOBADILLA, A., 2008. Histopathology and cellular response in *Enteromyxum leei* (Myxozoa) infections of *Diplodus puntazzo* (Teleostei). *Parasitology International*, vol. 57, no. 2, pp. 110-120. <http://dx.doi.org/10.1016/j.parint.2007.09.004>. PMID:18373973.

AZEVEDO, C., SÃO CLEMENTE, S.C., CASAL, G., MATOS, P., ALVES, A., AL-QURAIISHY, S. and MATOS, E., 2012. *Myxobolus myleus* n. sp. infecting the bile of the Amazonian freshwater fish *Myleus rubripinnis* (Teleostei: Serrasalmidae): morphology and pathology. *Systematic Parasitology*, vol. 82, no. 3, pp. 241-247. <http://dx.doi.org/10.1007/s11230-012-9360-0>. PMID:22711511.

EIRAS, J.C., LIMA, J.T.A.X., CRUZ, C.F. and SARAIVA, A., 2014. A note on infection of *Scomberomorus brasiliensis* (Osteichthyes, Scombridae) by *Kudoa* sp. (Myxozoa: multivalvulidae). *Brazilian Journal of Biology = Revista Brasileira de Biologia*, vol. 74, no. 3, pp. 164-166. <http://dx.doi.org/10.1590/1519-6984.23712>.

EIRAS, J.C., TAKEMOTO, R.M. and PAVANELLI, G.C., 2006. *Métodos de estudo e técnicas laboratoriais em parasitologia de peixes*. 2. ed. Maringá: Universidade Estadual de Maringá, 199 p.

EISEN, R.J. and SCHALL, J.J., 2000. Life history of malaria parasite (*Plasmodium mexicanum*): independent traits and basis for variation. *Proceedings. Biological Sciences*, vol. 267, no. 1445, pp. 793-799. <http://dx.doi.org/10.1098/rspb.2000.1073>. PMID:10819149.

FEIST, S.W. and LONGSHAW, M., 2006. Phylum Myxozoa. In: P.T.K. WOO, ed. *Fish diseases and disorders. Protozoan and metazoan infections*. CABI Publishing: Wallingford, pp 230-296 <http://dx.doi.org/10.1079/9780851990156.0230>.

GRAÇA, W. and PAVANELLI, C.S., 2007. *Peixes de planície de inundação do alto rio Paraná e áreas adjacentes*. Maringá: EDUEM, pp. 241.

LOM, J. and ARTHUR, J.R., 1989. A guideline for preparation of species descriptions in Myxosporaea. *Journal of Fish Diseases*, vol. 12,

- no. 2, pp. 151-156. <http://dx.doi.org/10.1111/j.1365-2761.1989.tb00287.x>.
- LOM, J. and DYKOVÁ, L., 2006. Myxozoan genera: definition and notes on taxonomy, life-cycle terminology and pathogenic species. *Folia Parasitologica*, vol. 53, no. 1, pp. 1-36. <http://dx.doi.org/10.14411/fp.2006.001>. PMID:16696428.
- LOM, J., DYKOVÁ, I., PAVLÁSKOVÁ, M. and GRUPCHEVA, G., 1983. *Sphaerospora molnari* sp. nov. (Myxozoa: Myxosporea), an agent of gill, skin and blood sphaerosporosis of common carp in Europe. *Parasitology*, vol. 86, no. 3, pp. 529-535. <http://dx.doi.org/10.1017/S003118200005071X>.
- LONGSHAW, M., FREAR, P. and FEIST, S.W., 2003. *Myxobolus buckei* sp. n. (Myxozoa), a new pathogenic parasite from the spinal column of three cyprinid fishes from the United Kingdom. *Folia Parasitologica*, vol. 50, no. 4, pp. 251-262. <http://dx.doi.org/10.14411/fp.2003.043>. PMID:14971593.
- MACIEL, P.O., AFFONSO, E.C., BOIJINK, C.L., TAVARES-DIAS, M. and INOUE, L.A.K.A., 2011. *Myxobolus* sp. (Myxozoa) in the circulating blood of *Colossoma macropomum* (Osteichthyes, Characidae). *Revista Brasileira de Parasitologia Veterinária*, vol. 20, no. 1, pp. 82-84. <http://dx.doi.org/10.1590/S1984-29612011000100018>. PMID:21439240.
- MOLNÁR, K., 2002. Site preference of fish myxosporeans in the gill. *Diseases of Aquatic Organisms*, vol. 48, no. 3, pp. 197-207. <http://dx.doi.org/10.3354/dao048197>. PMID:12033706.
- NALDONI, J., ARANA, S., MAIA, A.A.M., CECCARELLI, P.S., TAVARES, L.E.R., BORGES, F.A., POZO, C.F. and ADRIANO, E.A., 2009. *Henneguya pseudoplatystoma* n. sp. causing reduction in epithelial area of gills in the farmed pintado, a South American catfish: histopathology and ultrastructure. *Veterinary Parasitology*, vol. 166, no. 1-2, pp. 52-59. <http://dx.doi.org/10.1016/j.vetpar.2009.07.034>. PMID:19695782.
- OKAMURA, B., GRUHL, A. and BARTHOLOMEW, J., 2015. Introduction. In: B. OKAMURA, A. GRUHL and J.L. BARTHOLOMEW, eds. *Myxozoan evolution, ecology and development*. USA: Springer Int Publ, pp. 1-20. [http://dx.doi.org/10.1007/978-3-319-14753-6\\_1](http://dx.doi.org/10.1007/978-3-319-14753-6_1).
- ÚNGARI, L.P., VIEIRA, D.H.M.D., DA SILVA, R.J., SANTOS, A.L.Q., DE AZEVEDO, R.K. and O'DWYER, L.H., 2019. A new myxozoan species *Henneguya unitaeniata* sp. nov. (Cnidaria: Myxosporea) on gills of *Hoplerythrinus unitaeniatus* from Mato Grosso State, Brazil. *Parasitology Research*, vol. 118, no. 12, pp. 3327-3336. <http://dx.doi.org/10.1007/s00436-019-06533-1>. PMID:31728724.
- VIDAL, L.G.P., IANNACONE, J., WHIPPS, C.M. and LUQUE, J.L., 2017. Synopsis of the species of Myxozoa Grassé, 1970 (Cnidaria: Myxosporea) in the Americas. *Neotropical Helminthology*, vol. 11, pp. 413-511.
- YOKOYAMA, H., ITOH, N. and TANAKA, S., 2005. *Henneguya pagri* n. sp. (Myxozoa: Myxosporea) causing cardiac henneguyosis in red sea bream, *Pagrus major* (Temminck & Schlegel). *Journal of Fish Diseases*, vol. 28, no. 8, pp. 479-487. <http://dx.doi.org/10.1111/j.1365-2761.2005.00655.x>.