

Extended treatment with interferon and ribavirin in a hemodialysis patient with chronic hepatitis C

ABSTRACT

Hemodialysis patient with chronic HCV infection, who was started on monotherapy with interferon. Qualitative HCV RNA remained positive at 12 weeks of treatment; ribavirin was associated. HCV RNA was negative at week 24 and treatment was extended to 72 weeks. HCV RNA negative six months after treatment.

Keywords: hepatitis C virus, hemodialysis, treatment, interferon, ribavirin.

[Braz J Infect Dis 2010;14(2):193-196]©Elsevier Editora Ltda.

INTRODUCTION

The prevalence of hepatitis C virus (HCV) infection ranges from 1% to 3% in general population,¹ but it is higher in hemodialysis (HD) patients, ranging from 3% to 23%.¹ This difference can be related to the fact that patients on HD have risk factors for acquisition of HCV, such as receipt of blood transfusions and use of illicit intravenous drug, and may also acquire bloodborne infections as a result of healthcare-associated transmission in HD units. Several mechanisms have been implicated in HCV transmission among HD patients, such as dialyzer reuse, contamination of hands of staff members, or items shared among patients.¹

HCV infection increases mortality in HD patients and in renal transplant recipients (RTR).^{2,3} Cirrhosis and hepatocellular carcinoma (HCC), major complications of HCV-associated chronic liver disease, have been implicated as causes of increased mortality in HD patients with HCV infection.^{2,4} A study among HD patients showed that HCC accounted for 5.5% of all deaths in the group with HCV infection compared with 0% in the group without HCV infection.⁵ In addition, cirrhosis was documented in 8.8% and 0.4% of deceased patients with and without HCV infection, respectively ($p < 0.001$).⁵

Reduced survival in RTRs with HCV is attributable to advanced liver disease and sepsis.⁶ Both liver disease and sepsis in RTRs with HCV are likely to be direct consequences of cirrhosis. In a case-control study, cirrhosis was the most significant independent predictor of death after

renal transplantation.⁷ Despite the increase of liver disease and sepsis in RTRs, renal transplantation improves overall survival in non-cirrhotic patients with HCV in HD.⁸

The presence of cirrhosis in HD patients with HCV infection is considered a relative contraindication for renal transplantation due to possible progression of liver disease.⁶ Combined transplantation (liver/kidney transplantation) is recommended in renal transplantation candidates with decompensate cirrhosis. It is often recommended that HD patients with compensated cirrhosis whose liver function is too well compensated to require liver transplantation remain on dialysis.⁶

Because sustained HCV suppression prevents progression of liver disease and HCV therapy with interferon (IFN) is not recommended after renal transplantation, antiviral therapy should be considered for patients in HD with HCV infection prior to transplant.⁶ Patients with compensated hepatitis C cirrhosis who achieve sustained viral response (SVR), i.e., negative HCV RNA six months after treatment, may become suitable candidates for isolated renal transplantation.⁶ This emphasizes the potential benefit of HCV antiviral treatment. However, at present, therapy for hepatitis C in HD patients is difficult, especially because of potential adverse effects of treatment and presence of comorbidities in these patients. In this report, we present a HD patient with chronic HCV infection and cirrhosis treated with IFN monotherapy for 16 weeks, and IFN plus ribavirin (RBV) for additional 56 weeks.

Authors

Aline Gonzalez Vigani, MD, PhD¹
 Maria HP Pavan¹
 Raquel Tozzo¹
 Eduardo SL Gonçalves¹
 Maria SK Lazarini²
 Alexandre Macedo de Oliveira²
 Fernando L Gonçalves Jr¹

¹Viral Hepatitis Study Group, Department of Medical Clinic, Faculdade de Ciências Médicas, Universidade Estadual de Campinas – Unicamp, Campinas, Brazil.

²Epidemiology Consultant.

Submitted on: 05/30/2009
 Approved on: 06/07/2009

Correspondence to:
 Aline Gonzalez Vigani, MD, PhD
 Departamento de Clínica Médica, Faculdade de Ciências Médicas, Universidade Estadual de Campinas – UNICAMP
 Caixa-postal: 6198
 Campinas – SP – Brazil
 CEP: 13083-970
 Phone: 55 29 35217727
 Fax: 55 19 35217727
 E-mail: aline.vigani@sigmanet.com.br

We declare no conflict of interest.

CASE REPORT

A 44-year-old man in HD and with serum anti-HCV antibodies detected by enzyme immunoassay (Abbott AxSYM AntiHCV 3.0, Abbott Laboratories, Wiesbaden, Germany) was referred to the Viral Hepatitis Study Group of Clinics Hospital, State University of Campinas for HCV infection evaluation and follow-up. Patient reported use of illicit drugs 20 years before that time, has been in HD for six months, and denied current alcohol abuse. The chronic renal failure was of unknown etiology. Patient used erythropoetin (EPO) 10,000 UI once a week. Serum HCV RNA was detected by qualitative PCR (Cobas Amplicor HCV Test v2.0, Roche Molecular Diagnostic Systems, Branchburg, USA), and HCV genotype 1 was identified. Baseline laboratory findings are shown in Table 1. Of note, thyroid function tests and protein electrophoresis did not reveal any abnormality. HIV and hepatitis B serologies were both negative.

Patient's physical exam was unremarkable with a weight of 80 kg and a body mass index (BMI) of 27.5 kg/m². Abdomen ultrasound showed signals of liver cirrhosis and splenomegaly; digestive endoscopic did not reveal esophageal varices. Monotherapy treatment with IFN- α 3 million units subcutaneously, three times a week was initiated. Qualitative HCV RNA remained positive at weeks 4 and 12 of treatment (Figure 1). Oral RBV was associated with IFN at week 16 of treatment, at a dose of 500 mg per day. HCV RNA was negative at week 24. At week 30, RBV dose was increase to

750 mg/day. By week 72, end of HCV treatment, HCV RNA was negative. Patient had negative HCV RNA when tested six months after treatment, which characterizes SVR.

Patient tolerated treatment well and did not present with significant side effects. During the first month of therapy, he had flu-like symptoms managed with paracetamol. Patient did not experience a decrease in serum hemoglobin (Hb) level (Figure 1) during treatment, and it was not necessary to increase EPO dose already in use in HCV treatment.

Figure 1: Alanine aminotransferase (ALT) and hemoglobin (Hb) levels during interferon and ribavirin treatment.

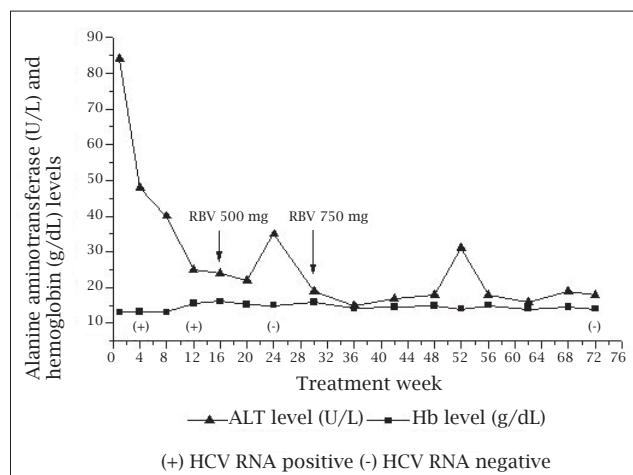


Table 1. Baseline laboratory findings of patient with chronic hepatitis C and on hemodialysis

Exam	Patient result	Reference value
Leukocytes (cells/mm ³)	6,800	4,000–10,000
Platelets (cells/mm ³)	223,000	150,000–400,000
Hemoglobin (g/dL)	13.10	14.0–18.0
Total bilirubin (mg/dL)	0.8	< 1.0
Glucose (mg/dL)	89	70–100
Alanine aminotransferase (U/L)	84	< 40
Aspartate aminotransferase (U/L)	42	< 37
Alkaline phosphatase (U/L)	67	40–129
Glutamyltransferase (U/L)	47	9–40
Albumin (g/dL)	4.8	3.4–4.8
Alfa-feto protein (mg/mL)	1.78	< 7
RNI	1.02	1.0
Creatine	10.75	< 1.2
Urea nitrogen	150	10–50
Serum cryoglobulins	Positive	Negative
Rheumatic factor (UI/mL)	< 8.5	< 15

DISCUSSION

The standard treatment for patients with chronic hepatitis C genotype 1 infection is pegylated interferon alfa (PEG-IFN) therapy in combination with RBV for 48 weeks and 24 weeks for patients with genotype 3 infection. In non-HD patients, this combination achieved SVR in 50% to 60% of patients.¹ There is no current optimal therapy for hepatitis C in HD patients. The combination of PEG-IFN and RBV has not been studied extensively in HD patients, as most studies have focused on monotherapy with IFN. Two meta-analyses reported SVR rates of 33% and 37% in HD patients treated with IFN as monotherapy.^{10,11} These rates are significantly greater than the SVR rates observed in previously published studies, 10% to 20%, among non-HD patients treated with IFN monotherapy.¹ These increased response rates may be partially explained by an increased half-life of IFN in HD patients, resulting in greater plasma levels and consequent increase in efficacy and also in the incidence of side effects.

In HD patients, SVR rates in three studies of PEG-IFN monotherapy were similar (37%) to those for IFN monotherapy, but SVR rates increased to 97% and 44% in two studies using PEG-IFN and RBV.¹ In this report, we described a patient in HD with HCV chronic infection treated with IFN- α monotherapy for 16 weeks and then with IFN- α and RBV for additional 56 weeks. HCV RNA became negative only after RBV was initiated.

Clinicians are usually reluctant to use RBV in HD patients because only a small part of the drug is eliminated during HD sessions and side effects include a dose-dependent hemolysis, which may be even more severe in chronically anemic HD patients.¹² In addition, a lack of knowledge about adequate RBV dosing and presence of other comorbidities (e.g., cardiac ischemia) has further discouraged the use of RBV in HD patients. However, studies have evaluated combination therapy of either PEG-IFN or IFN- α plus RBV in patients in maintenance HD.^{13,14} In one study, SVR rate in HD patients treated with IFN- α plus RBV was 83.3%, and the most frequent side effect of RBV was a dose-dependent hemolysis, which required treatment discontinuation in some patients.¹⁴ This concentration-monitored safety study indicated that it was possible to use combination therapy, IFN- α plus RBV, in HD patients. However, some precautions were suggested for RBV use in this setting, including close monitoring of Hb levels, reduced doses of RBV, start using EPO or, in those patients already using EPO, increase its dosing either increasing doses of EPO in patients already in use or its initiation others.¹⁵ Transfusions and RBV discontinuation may be necessary to manage RBV-induced anemia in some patients.

In our report, the initial RBV dose could be considered low for an 85 kg patient. The standard RBV dose for a non-HD patient infected with genotype 1 is 15 mg/kg, equivalent to 1,200 mg in this patient. Patient tolerated treatment well

and did not develop RBV-induced anemia. So, it was not necessary to increase his EPO dose. The small sample size of previous studies in HD and chronic hepatitis C patients hampers definitive conclusions about optimal therapy, but encouraging results in terms of efficacy and safety have been reported.^{4,14} Randomized trials with large numbers of patients are necessary to investigate optimal combination therapy and management of side effects among HD patients.

There is a lack of comprehensive information on HCV-related cirrhosis in patients in HD, as studies are limited to a few case reports. Standard IFN- α monotherapy in three HD HCV-infected patients with cirrhosis showed reversibility of cirrhosis by biopsy in two of them.¹⁶ Our patient had evidence of cirrhosis on ultrasound and we decided not to perform liver biopsy before and after antiviral treatment, but SVR after treatment as seen in this patient is usually associated with improved liver histology.¹⁷

Virological response to HCV treatment in non-HD patients is influenced by different host and virus factors. Host factors associated with a reduced virological response to PEG-IFN and RBV combination therapy are older age, male gender, African-American ethnicity, elevated BMI, advanced fibrosis or cirrhosis, and liver steatosis.¹⁸ The most important viral factor for prediction of virological response is the HCV genotype. HCV genotype 2- or 3-infected patients generally have higher SVR rates than genotype 1-infected patients. In addition, a low baseline viral load is also associated with increased rates of virological response.¹⁷ Similar to non-HD patients, greater SVR rates were observed in HD patients with non-HCV genotype 1 infections, without cirrhosis or bridging fibrosis, and low mean pretreatment HCV RNA levels.¹

We noticed that our patient had some factors, such as genotype 1 infection, male gender, elevated BMI, and cirrhosis, that have been shown to be predictors of decreased response to IFN- α and RBV therapy.¹⁸ For non-HD patients, a slow virological response to HCV treatment can be defined as patients who become HCV RNA negative only at week 24.

As shown by previous studies, prolongation of therapy from 48 to 72 weeks may be necessary in patients with slow virological response.¹⁹ Extending combination therapy from 48 to 72 weeks led to an increase of SVR rates from 17% to 29% among patients with detectable HCV RNA at week 12 who became HCV RNA negative only by week 24.¹⁹ Because our patient was a slow virological responder, HCV RNA negativation at week 24, we decided to extend his treatment to 72 weeks, and he attained SVR. At the present, no studies evaluating extended HCV therapy in HD patients are available; therefore, further studies are necessary to determine the appropriate duration of HCV treatment in HD patients.

There is little information on optimal treatment of hepatitis C among HD patients. The decision to initiate IFN and

RBV therapy in such patients should be based on histological severity of liver disease, presence of comorbidities, and expected tolerance of side effects. In addition, clinicians should carefully monitor the patient during treatment and make necessary adjustments to reach desired outcomes and minimize side effects. By doing so, it may be possible to achieve high rates of SVR with the already available treatment options.

REFERENCES

- Gordon CE, Uhlig K, Lau J, Schmid CH, Levey AS, Wong JB. Interferon treatment in hemodialysis patients with chronic hepatitis C virus infection: a systematic review of the literature and meta-analysis of treatment efficacy and harms. *Am J Kidney Dis.* 2008; 51(2):263-77.
- Dattolo P, Lombardi M, Ferro G, Michelassi S, Cerrai T, Pizzarelli F. Natural history of HCV infection and risk of death in a cohort of patients on long-term hemodialysis. *G Ital Nefrol.* 2006; 23(6):585-90.
- Fabrizi F, Martin P, Dixit V, Bunnapradist S, Dulai G. Hepatitis C virus antibody status and survival after renal transplantation: meta-analysis of observational studies. *Am J Transplant.* 2005; 5(6):1452-61.
- Carriero D, Fabrizi F, Uriel AJ, Park J, Martin P, Dieterich DT. Treatment of dialysis patients with chronic hepatitis C using pegylated interferon and low-dose ribavirin. *Int J Artif Organs.* 2008; 31(4):295-302.
- Nakayama E, Akiba T, Marumo F, Sato C. Prognosis of anti-hepatitis C virus antibody-positive patients on regular hemodialysis therapy. *J Am Soc Nephrol.* 2000; 11(10): 1896-902
- Gane E, Pilmore H. Management of chronic viral hepatitis before and after renal transplantation. *Transplantation.* 2002; 74(4):427-37.
- Mathurin P, Mouquet C, Poynard T, Sylla C, Benalia H, Fretz C *et al.* Impact of hepatitis B and C virus on kidney transplantation outcome. *Hepatology.* 1999; 29(1):257-63.
- Knoll GA, Tankersley MR, Lee JY, Julian BA, Curtis JJ. The impact of renal transplantation on survival in hepatitis C-positive end-stage renal disease patients. *Am J Kidney Dis.* 1997; 29(4):608-14.
- Kamar N, Toupance O, Buchler M, Sandres-Saune K, Izopet J, Durand D *et al.* Evidence that clearance of hepatitis C virus RNA after alpha-interferon therapy in dialysis patients is sustained after renal transplantation. *J Am Soc Nephrol.* 2003; 14(8): 2092-8.
- Fabrizi F, Dulai G, Dixit V, Bunnapradist S, Martin P. Meta-analysis: interferon for the treatment of chronic hepatitis C in dialysis patients. *Aliment Pharmacol Ther.* 2003; 18(11-12):1071-81.
- Russo MW, Goldsweig CD, Jacobson IM, Brown RS Jr. Interferon monotherapy for dialysis patients with chronic hepatitis C: an analysis of the literature on efficacy and safety. *Am J Gastroenterol.* 2003; 98(7):1610-5.
- Glue P. The clinical pharmacology of ribavirin. *Semin Liver Dis.* 1999; 19 Suppl 1:17-24.
- Rendina M, Schena A, Castellaneta NM, Losito F, Amoroso AC, Stallone G *et al.* The treatment of chronic hepatitis C with peginterferon alfa-2a (40 kDa) plus ribavirin in haemodialysed patients awaiting renal transplant. *J Hepatol.* 2007; 46(5):768-74.
- Bruchfeld A, Stähle L, Andersson J, Schvarcz R. Ribavirin treatment in dialysis patients with chronic hepatitis C virus infection--a pilot study. *J Viral Hepat.* 2001; 8(4):287-92.
- Fabrizi F, Poordad FF, Martin P. Hepatitis C infection and the patient with end-stage renal disease. *Hepatology.* 2002; 36(1):3-10.
- Pol S, Carnot F, Nalpas B, Lagneau JL, Fontaine H, Serpaggi J, Serfaty L, Bedossa P, Bréchet C. Reversibility of hepatitis C virus-related cirrhosis. *Hum Pathol.* 2004; 35(1):107-12.
- Maylin S, Martinot-Peignoux M, Moucari R, Boyer N, Ripault MP, Cazals-Hatem D *et al.* Eradication of hepatitis C virus in patients successfully treated for chronic hepatitis C. *Gastroenterology.* 2008; 135(3):821-9.
- Mihm U, Herrmann E, Sarrazin C, Zeuzem S Review article: predicting response in hepatitis C virus therapy. *Aliment Pharmacol Ther.* 2006 15; 23(8):1043-54.
- Berg T, von Wagner M, Nasser S, Sarrazin C, Heintges T, Gerlach T *et al.* Extended treatment duration for hepatitis C virus type 1: comparing 48 *versus* 72 weeks of peginterferon-alfa-2a plus ribavirin. *Gastroenterology.* 2006; 130(4):1086-97.