



The Brazilian Journal of INFECTIOUS DISEASES

www.elsevier.com/locate/bjid



Clinical image

Tertiary syphilis: tubero-serpiginous and tubero-ulcerous syphilids



Lívia Montelo Araújo Jorge^{a,*}, José Augusto da Costa Nery^b, Fred Bernardes Filho^c

^a Dermatology Service, Policlínica Geral do Rio de Janeiro, Rio de Janeiro, RJ, Brazil

^b Laboratório de Hanseníase – Fundação Oswaldo Cruz (LaHan-Fiocruz), Rio de Janeiro, RJ, Brazil

^c Dermatology Division, Department of Medical Clinics, Faculdade de Medicina de Ribeirão Preto, Universidade de São Paulo (USP), Ribeirão Preto, SP, Brazil

ARTICLE INFO

Article history:

Received 16 January 2016

Accepted 19 January 2016

Available online 26 March 2016

A 50-year-old heterosexual, HIV seronegative, male patient presented at the Dermatology Service with asymptomatic erythematous lesions on his left elbow and forehead for four months. He denied previous treatment, comorbidities and had no systemic symptoms. The dermatological examination showed erythematous purplish tuberos circinate plaque on his forehead (Fig. 1A), reddish purplish tubers, some ulcerated on the left elbow (Fig. 1B), and bulky lymphadenopathy in the neck (Fig. 1C); absence of mucosal lesions; preserved skin sensitivity and peripheral nerves without changes. Test results: VDRL 1/64, TPHA reagent, and anti-HIV nonreactive. The diagnosis of tertiary syphilis was established and treatment with penicillin benzathine 7,200,000 IU in three weekly intramuscular doses of 2,400,000 IU was administered. Reduction of the

lesion was observed one week thereafter and clinical cure was achieved after the end of treatment (Fig. 2).

Syphilis is a millenarian disease but still remains rather prevalent, especially in some high-risk behavior individuals.^{1,2} In contrast to the increasing incidence of early syphilis (primary and secondary), cases of classic late syphilis (tertiary) as a result of untreated syphilis are rarely seen.^{3,4} Approximately half of patients with tertiary syphilis presents “benign” late syphilis with gums emergence.^{4,5} Around a quarter develop cardiovascular manifestations and another quarter develop neurological symptoms.^{4,6} Gums are locally destructive lesions in the skin, liver, bones, and other organs.^{4,7} Skin gums are nodular or nodular ulcerative lesions, with an arciform pattern.^{3,4}

* Corresponding author.

E-mail address: livia_montelo@hotmail.com (L.M.A. Jorge).

<http://dx.doi.org/10.1016/j.bjid.2016.01.007>

1413-8670/© 2016 Elsevier Editora Ltda. This is an open access article under the CC BY-NC-ND license. (<http://creativecommons.org/licenses/by-nc-nd/4.0/>)

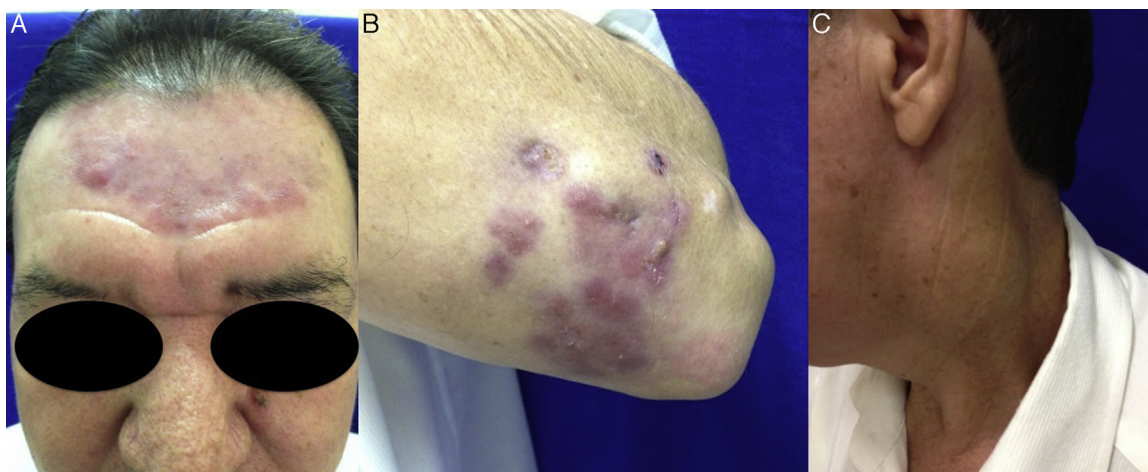


Fig. 1 – Tubero-serpiginous syphilids on forehead (A), tubero-ulcerous syphilids on left elbow (B) and bulky lymphadenopathy in the neck (C).

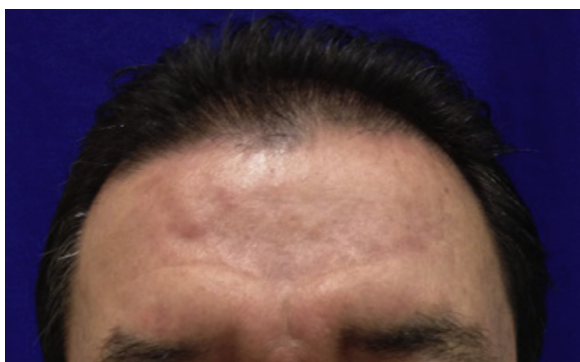

Fig. 2 – The disappearance of tubero-serpiginous syphilids on forehead after the end of treatment.

Conflicts of interest

The authors declare no conflicts of interest.

REFERENCES

1. Bernardes Filho F, Santos MVPQ, Cariello LBA, et al. Syphilis in presentation with overlapping phases: how to lead? *DST – J Bras Doenças Sex Transm.* 2012;24:109–12.
2. Fernandes FR, Zanini PB, Rezende GR, et al. Syphilis infection, sexual practices and bisexual behaviour among men who have sex with men and transgender women: a cross-sectional study. *Sex Transm Infect.* 2015;91:142–9.
3. Avelaira JCR, Bottino G. Syphilis: diagnosis, treatment and control. *An Bras Dermatol.* 2006;81:111–26.
4. Sary A, Sary G. Infecções Sexualmente Transmissíveis (Sífilis). In: Bologna JL, Jorizzo JL, Rapini RP, editors. *Dermatology.* 3rd ed. New York: Mosby Elsevier; 2015. p. 1367–79.
5. Wu SJ, Nguyen EQ, Nielsen TA, Pellegrini AE. Nodular tertiary syphilis mimicking granuloma annulare. *J Am Acad Dermatol.* 2000;42:378–80.
6. Revathi TN, Bhat S, Asha GS. Benign nodular tertiary syphilis: a rare presenting manifestation of HIV infection. *Dermatol Online J.* 2011;17:5.
7. Rocha N, Horta M, Sanches M, Lima O, Massa A. Syphilitic gumma—cutaneous tertiary syphilis. *J Eur Acad Dermatol Venereol.* 2004;18:517–8.