

Fulminant pancytopenia due to cytomegalovirus infection in an immunocompetent adult

Authors

Maria Koukoulaki, MD,
M.Phil¹
Georgia Ifanti, MD²
Eirini Grispou³
Vassilios Papastamopoulos,
MD¹
Georgia Chroni, MD²
Emmanouil
Diamantopoulos, MD²
Athanasios Skoutelis, MD¹

¹15th Department of
Medicine, Division of
Infectious Diseases,
"Evangelismos" General
Hospital, 45 - 47
Ipsilantou street, 106 76
Athens, Greece.

²4th Department of
Medicine,
"Evangelismos" General
Hospital, 45 - 47
Ipsilantou street, 106 76
Athens, Greece.

³Department of
Microbiology,
"Evangelismos" General
Hospital, 45 - 47
Ipsilantou street, 106 76
Athens, Greece.

Submitted on: 06/03/2009
Approved on: 05/20/2009

Correspondence to:

Maria Koukoulaki, M.D.,
M.Phil
5th Department of
Medicine, "Evangelismos"
General Hospital
45-47 Ipsilantou street,
106 76 - Athens - Greece
Phone: 30 210 7201830
Fax: 30 210 7216408
E-mail: mkoukoulaki@
gmail.com

We declare no conflict of
interest.

ABSTRACT

A case of severe and irreversible pancytopenia secondary to acute primary cytomegalovirus infection in an immunocompetent woman is described. The patient presented with thrombocytopenia, lymphopenia, anemia, and abnormal liver function tests. Treatment with corticosteroids and intravenous immunoglobulin was ineffective in reconstituting hemopoiesis. The patient developed severe sepsis and eventually expired.

Keywords: cytomegalovirus, pancytopenia, immunocompetent, fulminant, irreversible.

[Braz J Infect Dis 2010;14(2):180-182]©Elsevier Editora Ltda.

INTRODUCTION AND OBJECTIVE

Human cytomegalovirus (CMV) is a β human herpesvirus and a member of *Herpesviridae* family and can cause life-threatening infections in immunocompromised patients. CMV infection in healthy host, on the contrary, is either asymptomatic and resolves spontaneously or, in rare occasions, can cause a self-limited mononucleosis-like syndrome presented with fever, myalgia, hepatitis, and cervical adenopathy.¹

Significant involvement of hematopoietic system due to acute CMV infection in immunocompetent patients is scarcely reported in literature.²⁻⁶

We describe a case of fulminant pancytopenia secondary to CMV infection in a previously healthy woman. To our knowledge, no other case of sustained and irreversible leukopenia and thrombocytopenia with subsequent death due to bacterial sepsis in an immunocompetent individual has been reported so far, except for a case of disseminated CMV infection in an apparently normal adult.²

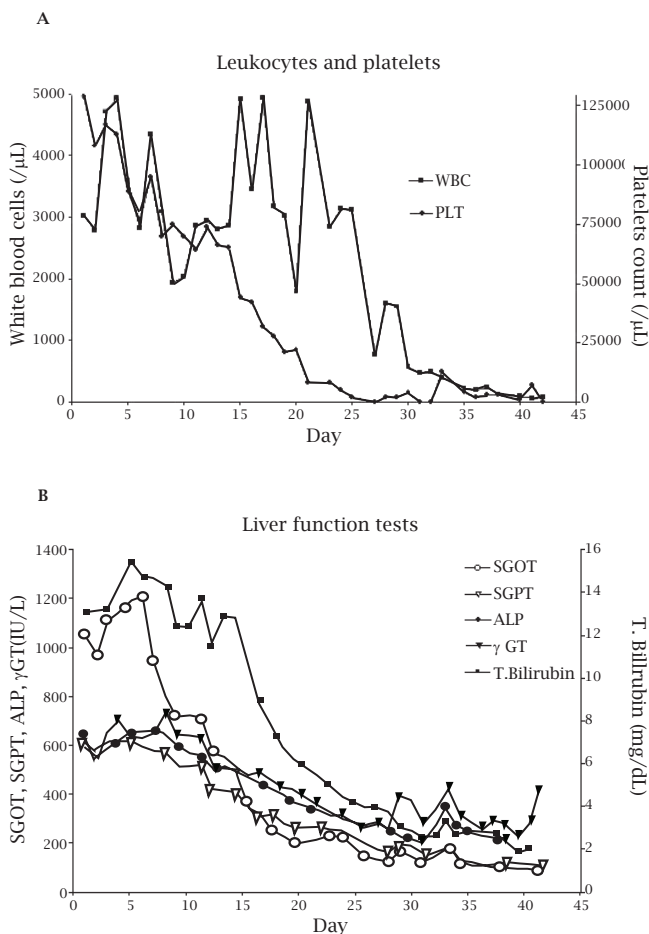
CLINICAL PRESENTATION

A 61-year-old woman was admitted to our hospital due to persistent diarrhea, malaise, loss of appetite, and weight loss one month prior to admission. She denied any health problems and use of medications. Her past medical history revealed cholecystectomy and appendectomy more than 10 years ago. On physical examination, jaundice and hepatosplenomegaly were present.

Laboratory examination showed mild anemia [hematocrit (Ht): 35.6%], leukopenia with lymphopenia [white blood cells (WBC): 3,030/ μ L, lymphocytes: 600/ μ L] and thrombocytopenia [platelet count (PLT): 129,000/ μ L] (Figure 1A). Biochemistry revealed elevated liver function tests [serum glutamic oxaloacetic transaminase (SGOT): 1,066 IU/L, serum glutamate pyruvate transaminase (SGPT): 598 IU/L, alkaline phosphatase (ALP): 627 IU/L, γ -glutamyl transpeptidase (γ -GT): 568 IU/L, total bilirubin: 13.21 mg/dL, direct bilirubin: 10.41 mg/dL, indirect bilirubin: 2.8 mg/dL] (Figure 1B). Abdominal ultrasound and computed tomography revealed mild hepatosplenomegaly. Serum antibodies for hepatitis B and C, human immunodeficiency virus, Epstein-Barr virus, herpes simplex viruses 1 and 2, herpes zoster virus, parvovirus, coxsackie and ECHO virus were negative, except for positive IgM and IgG antibodies against CMV detected with indirect immunofluorescence (IFA CMV test; Gull Laboratories, Salt Lake City, UT, USA). Serology tests for *Rickettsia conorii* or *R. mooseri*, *Coxiella burnetii*, *Leptospira* sp., *Leishmania* sp. and *Brucella* sp. were also negative.

The patient was stable 10 days following admission with resolution of diarrhea and gradual recovery of liver function tests (Figure 1B). PLT count further decreased (Figure 1A). Peripheral blood smear showed abnormal distribution of PLT and thrombocytopenia, anisocytosis of red blood cells together with lymphopenia. Bone marrow aspiration indicated reactive cel-

Figure 1: Time course of leukocytes and platelets (A) and liver function tests (B) during patient hospitalization. WBC, white blood cell; PLT, platelets; SGOT, serum glutamic oxaloacetic transaminase; SGPT, serum glutamate pyruvate transaminase; ALP, alkaline phosphatase; γ -GT, γ -glutamyl transpeptidase.



lularity. More specifically, erythroid cell line matured with megaloblastic characteristics, myeloid cell line showed white blood cell left shift, and megacaryotic cell line had normal representation. A slight increase of macrophages was also noted with no signs of hemophagocytosis. Moreover, reticulocytes represented 2.13% in peripheral blood. Autoantibodies (anti-nuclear, anti-endothelial cell, anti-smooth-muscle cell antibodies), anti-platelet antibodies, Coombs' and cryoglobulin tests were negative. Complement, plasma hemoglobin, and haptoglobin levels were within normal limits. Both viral load of CMV measured with real-time PCR and CMV pp65 antigen in peripheral WBC and bone marrow samples were undetectable. Titers of IgM and IgG antibodies were 1/80 and 1/640, respectively, suggesting primary CMV infection or reactivation. Immunophenotyping of peripheral white blood cells showed a marked decrease of CD4 T-lymphocytes (7%), B-lymphocytes (1%), and natural killer cells (2%), along with major increase of CD8 T-lymphocytes (84.9%) supportive of CMV infection.

Upon diagnosis of acute CMV infection, treatment with prednisolone (50 mg/day for 10 days), intravenous immunoglobulin (IVIg) (0.4mg/kg for 5 days) and ganciclovir (5 mg/kg twice daily IV) was initiated. Despite therapy, thrombocytopenia and neutropenia worsened, requiring granulocyte-colony stimulating factor (G-CSF) and PLT transfusions. On day 30, patient developed febrile neutropenia. Blood cultures yielded *Serratia marcescens* and, despite appropriate antibiotics and supportive measurements, she expired on day 43. Neutropenia and thrombocytopenia were never resolved.

DISCUSSION

A previously healthy woman presented with generalized malaise, jaundice, elevated liver function biochemical markers and mild anemia, leukopenia and thrombocytopenia. Diagnosis of primary CMV infection was based on identification of positive IgM antibodies in a high titer, which are considered highly specific and sensitive in immunocompetent hosts.⁷ CMV infection induced sustained and irreversible pancytopenia, despite normal findings in bone marrow aspiration.

In immunocompetent hosts, primary CMV infection is usually asymptomatic or it could present as a mononucleosis syndrome. Diagnosis is based on clinical presentation and seroconversion. Detection and quantification of viral load can be used to monitor and predict CMV disease, especially in immunocompromised patients. In a study of dynamics of primary CMV infection in 48 immunocompetent patients, it was reported that 43% of examined serum samples (37/87) from 27 of these 48 patients (56.8%) had detectable CMV DNA.⁸ Even though viral load has been correlated with development of CMV disease in transplant recipients, invasive CMV gastrointestinal or retinal disease may have undetectable viral load.^{9,10} Therefore, based on published studies of CMV kinetics, diagnosis of primary CMV infection is relied on seroconversion without compulsory detection of viral DNA, as it was noticed in the case described.

Several mechanisms have been proposed on the effect of CMV on hematopoiesis in immunocompetent hosts. One mechanism indicates direct effect of CMV on bone marrow cells leading to cellular injury and decrease of erythrocytes, lymphocytes, granulocytes, and platelets. Several in vitro studies have shown the ability of certain strains of CMV to infect hematopoietic progenitor cells and subsequently inhibit hemopoiesis.¹¹ In addition, it has been suggested that CMV infection results in down-regulation of G-CSF and hematopoietic suppression.¹² In our case, bone marrow aspiration showed normal cellularity and CMV antigen was not detected. Therefore, this mechanism should not be the cause of pancytopenia. However, reticulocyte count in peripheral blood, an indi-

rect marker of bone marrow erythroid cell line function, showed a marked decrease from day 20 to day 42.

In addition, hemophagocytosis triggered by CMV could result in proliferation of mature histiocytes that destroy hematopoietic cells. Although hemophagocytic syndrome typically occurs in patients with malignant diseases, acquired immunodeficiency syndrome, bone marrow or solid organ transplantation and in those with autoimmune diseases receiving immunomodulating therapies, very few cases have been reported in immunocompetent patients. Two cases of gastrointestinal complications with hemophagocytic syndrome caused by CMV infection have been described.¹³ Nevertheless, no evidence of hemophagocytosis was found in our case.

Immunological mechanisms involve the formation of anti-platelets, anti-endothelial cells, anti-smooth-muscle cells, anti-nuclear antibodies, and cryoglobulins that link CMV infection with thrombocytopenia, autoimmune disorders, and haemolysis. Molecular mimicry has been implicated in onset of autoimmunity. Viral peptides that share homology with host-peptides could initiate an immune response both against itself and the virus. Additionally, during viral cell lysis, intracellular proteins, the secured host antigens not previously recognized, are exposed to circulating antigen-presenting cells that activate autoreactive lymphocytes.¹⁴ Consequently, bone marrow necrosis should be accompanied by formation of autoantibodies. Soderberg *et al.* reported a correlation between CMV induced formation of antibodies against CD13, which is expressed on myelomonocytic cells, and the development of graft-versus-host disease following allogeneic bone marrow transplantation.¹⁵

Cell destruction in the periphery should be attributed to an immunological mechanism. Previously published case reports confirm that anti-platelet antibodies are rarely detected during the acute phase of CMV infection.^{4,6} Thus, it is most likely that in our patient autoimmunity was responsible for CMV-induced pancytopenia, despite the absence of anti-platelet antibodies.

Despite intensive supportive treatment, recovery of hematopoiesis was not achieved. Initial corticosteroid administration and IVIg were given for presumed immunological origin of thrombocytopenia and lymphopenia.

CONCLUSION

In conclusion, even though CMV infection in immunocompetent adults is usually asymptomatic, only in rare cases CMV could affect hematopoiesis because of autoimmune mechanisms, manifested either as thrombocytopenia or hemolytic anemia. This case presents a previously healthy

woman who developed irreversible pancytopenia secondary to CMV infection. Therapeutic interventions were ineffective, leading to patient's death. Therefore, CMV infection should be considered in immunocompetent individuals with unexplained and refractory cytopenias.

REFERENCES

1. Sissons JG, Carmichael AJ. Clinical aspects and management of cytomegalovirus infection. *J Infect.* 2002 Feb; 44(2):78-83.
2. Rustgi VK, Sacher RA, OBrien P, Garagusi VF. Fatal disseminated cytomegalovirus infection in an apparently normal adult. *Arch Intern Med.* 1983 Feb; 143(2):372-3.
3. Wright JG. Severe thrombocytopenia secondary to asymptomatic cytomegalovirus infection in an immunocompetent host. *J Clin Pathol.* 1992 Nov; 45(11):1037-8.
4. van Spronsen DJ, Breed WP. Cytomegalovirus-induced thrombocytopenia and haemolysis in an immunocompetent adult. *Br J Haematol.* 1996 Jan; 92(1):218-20.
5. Gavazzi G, Leclercq P, Bouchard O, Bosserey A, Morand P, Micoud M. Association between primary cytomegalovirus infection and severe hemolytic anemia in an immunocompetent adult. *Eur J Clin Microbiol Infect Dis.* 1999 Apr; 18(4):299-301.
6. Ichiche M, Fontaine C, Lacor P. Severe thrombocytopenia secondary to cytomegalovirus infection in an immunocompetent adult. *Eur J Intern Med.* 2003 Feb; 14(1):56-9.
7. Gandhi MK, Khanna R. Human cytomegalovirus: clinical aspects, immune regulation, and emerging treatments. *Lancet Infect Dis.* 2004 Dec; 4(12):725-38.
8. Steininger C, Kundi M, Kletzmayer J, Aberle SW, Popow-Kraupp T. Antibody maturation and viremia after primary cytomegalovirus infection, in immunocompetent patients and kidney-transplant patients. *The Journal of infectious diseases.* 2004 Dec 1; 190(11):1908-12.
9. Emery VC, Sabin CA, Cope AV, Gor D, Hassan-Walker AF, Griffiths PD. Application of viral-load kinetics to identify patients who develop cytomegalovirus disease after transplantation. *Lancet.* 2000 Jun 10; 355(9220):2032-6.
10. Cytomegalovirus. *Am J Transplant.* 2004 Nov; 4 Suppl 10:51-8.
11. Maciejewski JP, Bruening EE, Donahue RE, Mocarski ES, Young NS, St Jeor SC. Infection of hematopoietic progenitor cells by human cytomegalovirus. *Blood.* 1992 Jul 1; 80(1):170-8.
12. Simmons P, Kaushansky K, Torok-Storb B. Mechanisms of cytomegalovirus-mediated myelosuppression: perturbation of stromal cell function *versus* direct infection of myeloid cells. *Proc Natl Acad Sci U S A.* 1990 Feb; 87(4):1386-90.
13. Ina S, Tani M, Takifuji K, Yamazoe S, Nakatani Y, Yamaue H. Virus-associated hemophagocytic syndrome and hemorrhagic jejunal ulcer caused by cytomegalovirus infection in a non-compromised host; a case report of unusual entity. *Hepatology.* 2004 Mar-Apr; 51(56):491-3.
14. Panoutsakopoulou V, Sanchirico ME, Huster KM *et al.* Analysis of the relationship between viral infection and autoimmune disease. *Immunity.* 2001 Jul; 15(1):137-47.
15. Soderberg C, Larsson S, Rozell BL, Sumitran-Karuppan S, Ljungman P, Moller E. Cytomegalovirus-induced CD13-specific autoimmunity--a possible cause of chronic graft-*vs*-host disease. *Transplantation.* 1996 Feb 27; 61(4):600-9.