

Heterotopic transplantation of glycerin-preserved trachea: effect of respiratory epithelium desquamation on acute rejection

M.G. Saueressig¹,
M.I.A. Edelweiss²,
F.H. Souza¹,
A.H. Moreschi¹,
F.L. Savegnago¹ and
A.V. Macedo Neto¹

¹Serviço de Cirurgia Torácica, ²Serviço de Patologia,
Hospital de Clínicas de Porto Alegre, Faculdade de Medicina,
Universidade Federal do Rio Grande do Sul, Porto Alegre, RS, Brasil

Abstract

An effective preservation method and decreased rejection are essential for tracheal transplantation in the reconstruction of large airway defects. Our objective in the present study was to evaluate the antigenic properties of glycerin-preserved tracheal segments. Sixty-one tracheal segments (2.4 to 3.1 cm) were divided into three groups: autograft (N = 21), fresh allograft (N = 18) and glycerin-preserved allograft (N = 22). Two segments from different groups were implanted into the greater omentum of dogs (N = 31). After 28 days, the segments were harvested and analyzed for mononuclear infiltration score and for the presence of respiratory epithelium. The fresh allograft group presented the highest score for mononuclear infiltration (1.78 ± 0.43 , $P \leq 0.001$) when compared to the autograft and glycerin-preserved allograft groups. In contrast to the regenerated epithelium observed in autograft segments, all fresh allografts and glycerin-preserved allografts had desquamation of the respiratory mucosa. The low antigenicity observed in glycerin segments was probably the result of denudation of the respiratory epithelium and perhaps due to the decrease of major histocompatibility complex class II antigens.

Key words

- Graft rejection
- Trachea
- Transplantation
- Glycerol
- Respiratory mucosa

Correspondence

M.G. Saueressig
Rua Ramiro Barcelos, 2171, Apto. 21
90035-007 Porto Alegre, RS
Brasil
Fax: +55-51-2101-8684
E-mail: msaueressig@hcpa.ufrgs.br.

M.G. Saueressig is the recipient
of grants from CNPq, FINE (Fundo
de Incentivo à Pesquisa e Eventos
do Hospital de Clínicas de Porto
Alegre) and FAPERGS.

Received August 16, 2004
Accepted April 26, 2005

Introduction

Tracheoplasty is the first therapeutic option for obstructive tracheal diseases up to 6 cm in length (1). In major inflammatory strictures, an effective long-term option is to maintain the tracheal lumen open by means of the Montgomery T-tube or stents. However, in some patients with extensive carcinoma, especially of the adenoid-cystic type,

there are doubts about the best approach, since curative treatment imposes the reconstruction of large airway defects resulting from the wide resection of the tumor.

Transplantation appears to be an alternative for reconstructing these extensive tracheal defects. However, problems with rejection and graft preservation must be solved experimentally, before the clinical use of this procedure. The first important step in the

study of a preservation method is to build a tissue bank in order to increase the supply of organs. Since major histocompatibility complex (MHC) class II antigens have been identified in the tracheal epithelium (2), the desquamation of the respiratory mucosa by the preservation method, as observed with cryopreservation (3) and with chemical detergents (4), or by radiotherapy (5), should be explored as a way to reduce tracheal antigenicity.

Despite the promising results with tracheal cryopreservation (3,6), there are limitations concerning conservation time and difficulties in maintaining viable chondrocytes, which are important for the tracheal structure (1).

The search for alternatives in tracheal conservation has led us to test a trialcohol with antiseptic and preservative properties, 99% glycerin, in order to reduce the antigenicity of the allograft by denuding the respiratory epithelium.

Material and Methods

Adult mongrel dogs of both genders submitted to proper sanitary control, provided by the Kennel of the Zoonosis Center, Mu-

nicipal Secretary of Health, Porto Alegre, were used. All animals, weighing 6.5 to 12 kg, were housed and handled according to Normative Resolution number 196/96 of the National Health Council of the Health Ministry (7), and the study was approved by the Research and Health Ethics Committee of Hospital de Clínicas de Porto Alegre.

We randomized 51 dogs into three experiments (Figure 1): 1) 20 dogs were used as allograft donors and were sacrificed; 2) in 21 dogs, two grafts, an autograft and an allograft, were implanted into the greater omentum (glycerin-preserved allograft or fresh allograft); 3) in 10 dogs, two allografts (a glycerin-preserved allograft and a fresh allograft) were implanted into the greater omentum.

From the above experiments we obtained a research sample consisting of 61 tracheal segments (each trachea harvested from experiment 1 originated two allografts, see below), divided into the following groups: A) autograft (N = 21), B) fresh allograft (N = 18), and C) glycerin-preserved allograft (N = 22).

Anesthesia

Animals were medicated with atropine sulfate (0.044 mg/kg, *sc*) and acepromazine (0.2 mg/kg, *im*) and then anesthetized with thiopental sodium (15 mg/kg, *iv*). Following orotracheal intubation with a 7-mm tube (Rüschelit®, Rüsch, Montevideo, Uruguay) we maintained the anesthesia with halothane inhalation (0.5 to 1%) with the dog breathing spontaneously a mixture of air and oxygen (3 l/min).

During the induction of anesthesia, all animals received ampicillin (20 mg/kg, *iv*). We did not use any immunosuppressive drug.

Allograft harvest

Twenty dogs (experiment 1) were sacrificed with an overdose of thiopental sodium

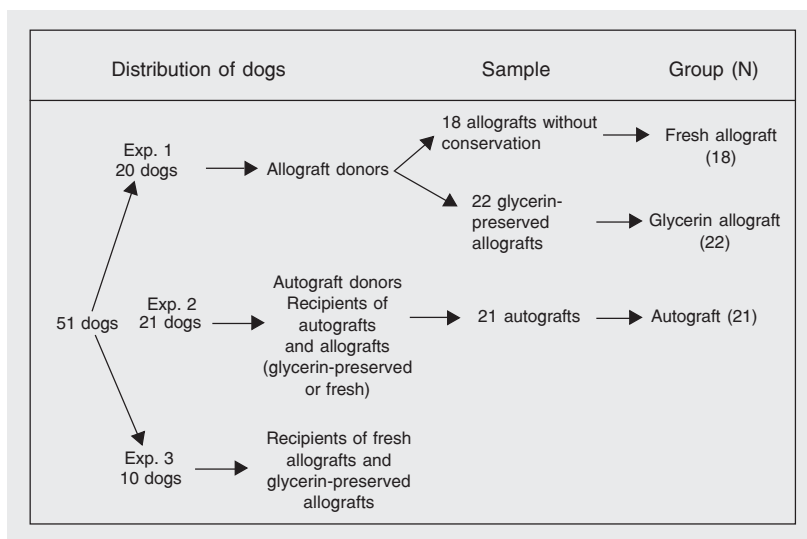


Figure 1. Experimental design. The figure shows the distribution of 51 dogs in three experiments showing the history of the grafts.

(100 mg/kg, *iv*). We then made a cervical midline incision using an aseptic technique and excised the entire cervical trachea. Each trachea originated two segments having six cartilaginous rings (2.4 to 3.1 cm in length), with 20 dogs providing 40 tracheal segments (allografts).

Eighteen of these tracheal segments (group B) were immediately allografted. The other 22 allografts were placed in glass flasks containing twice-distilled 99% glycerin and hermetically sealed and kept there at room temperature for at least two months and less than six months (group C). After this period, the glycerin-preserved tracheas were re-hydrated for 30 min with physiological saline before being transplanted (Figure 2).

Autograft harvest

In experiment 2, we harvested a smaller tracheal segment consisting of six cartilaginous rings from 21 dogs using the same approach as described above. Thereafter, these segments were autografted in the greater omentum and constituted the group A. We then reconstructed the airway immediately by trachea-to-trachea end-to-end anastomosis with continuous suture using 3-0 polyglactin (Ethicon, Johnson & Johnson, São José dos Campos, SP, Brazil). The cervical muscular layer was sutured with 3-0 polyglactin suture (Ethicon, Johnson & Johnson) and the skin with 4-0 nylon suture (Ethicon, Johnson & Johnson). These dogs received their two grafts immediately after cervical closure.

Transplant into the greater omentum

Thirty-one dogs were transplanted (experiments 2 and 3). Two grafts were performed in each animal, but in experiment 3 a dog received only the graft from group C.

We mobilized the greater omentum out of the peritoneal cavity through a 10-cm median laparotomy. Each of the two tracheal

grafts was wrapped with the greater omentum and fixed with some 3-0 polyglactin stitches 2 cm from the greater curvature of the stomach. We put the graft 10 cm away from the other. We closed the muscular abdominal layer with 0 polyglactin suture and the skin with 4-0 nylon suture.

Graft harvest from the greater omentum

The transplanted dogs were sacrificed 28 days after surgery. After opening the laparotomy, the grafted tracheal segments were removed along with a small portion of adhered greater omentum and fixed in 10% formalin for subsequent histological study.

Histological analysis

After cross-sectioning the tracheal piece in its mid-portion, the resulting fragments were embedded in paraffin, cut into 5- μ m thick sections. One section from each tracheal piece was stained with hematoxylin-eosin. We examined all the histologic sections.

Graft rejection. The presence of mononuclear cells in the tracheal interstice was graded according to the following mononuclear infiltration score: 0 for absent or mild infiltration with mononuclear cells present in less than 25% of the examined interstice, 1 for moderate infiltration with mononuclear cells present in 26 to 50% of the examined interstice, and 2 for intense infiltration present in more than 50% of the




Figure 2. Photograph of a glycerin-preserved trachea segment after hydration. Its stiffness and macroscopic structure were closely similar to those of fresh trachea. (tracheal segment with 9 cm in length).

assessed interstice. We reported the mean score for each group.

Respiratory epithelium. We considered the epithelium to be denuded when more than 50% of the lumen circumference was deprived of mucosa. We reported these results in proportions without statistical analysis.

Statistical analysis

Data regarding the mononuclear infiltration

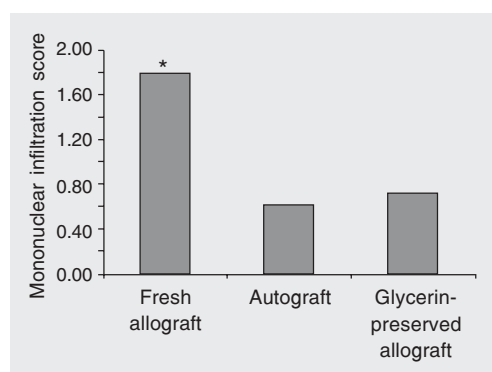
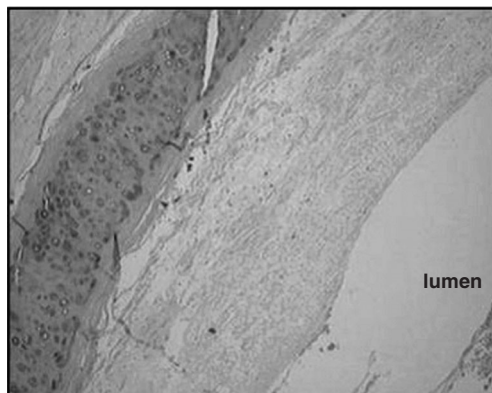


Figure 3. Mean mononuclear infiltration scores for the autograft, glycerin-preserved allograft and fresh allograft groups. * $P < 0.05$ compared to the autograft and to the glycerin-preserved allograft (Dunn test).

Figure 4. Photomicrograph of the tracheal allograft transplanted into the greater omentum after 28 days. Intense mononuclear infiltration is seen in the tracheal adventitia and perivascular space (hematoxylin-eosin; 100X).

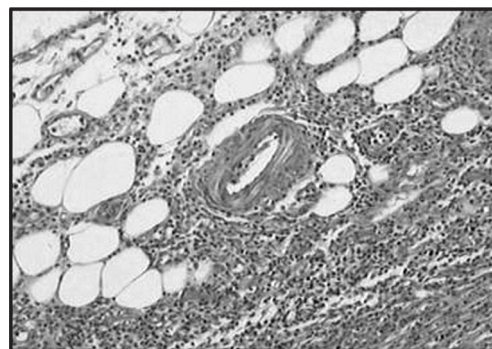

Figure 5. Photomicrograph of a glycerin-preserved tracheal segment transplanted into the greater omentum after 28 days. Note respiratory epithelium desquamation (hematoxylin-eosin; 400X).



tion score were compared between the three research groups. The Dunn test for multiple comparisons between averages was applied when the Kruskal-Wallis test presented $P < 0.05$. The levels of significance were set at 5% ($\alpha \leq 0.05$).

Results

Histological analysis

Graft rejection. The fresh allograft group presented the highest mean score for mononuclear infiltration (1.78 ± 0.43) when compared to the autograft (0.60 ± 0.75 , $P = 0.000$) and to the glycerin-preserved allograft (0.71 ± 0.72 , $P = 0.001$; Figure 3). There was no significant difference between the scores for the autograft group and the glycerin-preserved allograft group. A mononuclear cell infiltrate was detected in 77.8% of fresh allografts, distributed throughout more than 25% of the examined interstice (Figure 4).

Respiratory epithelium. The respiratory epithelium regenerated in 80% of autografted tracheas. All tracheal segments from the fresh allograft and glycerin-preserved allograft groups had desquamation of the respiratory epithelium (Figure 5).

Discussion

In any tracheal replacement technique, easy applicability and a minimal risk of complications should be imperative, especially in cases of benign tracheal obstruction (1). Additionally, the absence of immunosuppression is desirable, since such techniques are largely required in cases of extensive neoplasia.

MHC antigens are related to acute rejection. In the trachea, MHC class II antigens were found in the epithelium, in glands and in submucous capillaries (2). According to several studies, the presence of such epithelial antigens was probably the main trigger for the immunological reaction, which re-

sulted in ischemic necrosis and obliterative airway disease identified in the experimental tracheal allograft (8,9).

Nakanishi et al. (8) and Delaere et al. (10) described microscopically acute rejection in the trachea as an infiltrate of mononuclear cells, particularly in the capillary walls, similar to the arteritis occurring in renal transplantation.

In a previous study by our group (11), we presented evidence that vasculitis, represented by vascular and perivascular lymphocytic infiltration, was the predominant morphologic component in the rejection of tracheal allografts. Additionally, the quantitation of arteritis intensity indicated a decrease in the antigenicity of glycerin-preserved tracheal allografts.

Based on the pathophysiology of the immunological reaction and its similarity to the renal one, in the present study we adapted the quantitation of the cellular component (mononuclear infiltration) in acute rejection from the Banff 97 classification (12) and detected signs of rejection in non-preserved fresh allografts. On the other hand, the smaller presence of such inflammatory cells in gly-

cerin-preserved tracheas as well as in autografted tracheas suggested only ischemia during the first post-transplantation days and especially the absence of rejection.

The desquamation of the respiratory epithelium in glycerin-preserved tracheas observed in the present study most probably was related to the preservation process itself and to the lack of tissue vitality. However, in fresh allografts, the mucosal denudation was apparently a reflection of the ischemia secondary to arteriolar obstruction due to rejection arteritis.

On the basis of the present results, we suggest that the lower antigenic stimulation by glycerin-preserved tracheal allografts, as also reported in cryopreservation studies (3,6,13), may result from the denudation of native epithelium, with reduction and maybe absence of MHC class II antigens.

Acknowledgments

We are grateful for the editorial support provided by the Post-Graduate Research Group (GPPG) of Hospital de Clínicas de Porto Alegre.

References

1. Grillo HC (1992). Tracheal replacement. *Annals of Thoracic Surgery*, 73: 1995-2004.
2. Bujia J, Wilmes E, Hammer C et al. (1990). Tracheal transplantation: demonstration of HLA class II subregion gene products on human trachea. *Acta Oto-Laryngologica*, 110: 149-154.
3. Nakanishi R, Hashimoto M, Muranaka H et al. (2001). Effect of cryopreservation period on rat tracheal allografts. *Journal of Heart and Lung Transplantation*, 20: 1010-1015.
4. Liu Y, Nakamura T, Yamamoto Y et al. (2000). Immunosuppressant-free allotransplantation of the trachea: the antigenicity of tracheal grafts can be reduced by removing the epithelium and mixed glands from the graft by detergent treatment. *Journal of Thoracic and Cardiovascular Surgery*, 120: 108-114.
5. Yokomise H, Inui K, Wada H et al. (1994). High-dose irradiation prevents rejection of canine tracheal allografts. *Journal of Thoracic and Cardiovascular Surgery*, 107: 1391-1397.
6. Kumon BC, Shiraishi T, Makihata S et al. (2000). Cartilaginous injury limits cryopreservation of tracheal isograft. *Respirology*, 5: 105-110.
7. Resolução Normativa número 196/96 do Conselho Nacional de Saúde. [<http://www.saude.gov.br>]. Accessed March 10, 2002.
8. Nakanishi R, Shirakusa T & Hanagiri T (1994). Early histopathologic features of tracheal allotransplant rejection: a study in non-immunosuppressed dogs. *Transplant Proceedings*, 26: 3715-3718.
9. Qu Ning, de Haan A, Harmsen MC et al. (2003). Specific immune responses against airway epithelial cells in a transgenic mouse-trachea transplantation model for obliterative airway disease. *Transplantation*, 76: 1022-1028.
10. Delaere PR, Ziyang L, Hermans R et al. (1995). Experimental tracheal allograft revascularization and transplantation. *Journal of Thoracic and Cardiovascular Surgery*, 110: 728-737.
11. Saueressig MG, Moreschi AH, Barbosa GV et al. (2003). Rejection and indirect revascularization of glycerin-preserved tracheal implant. *Asian Cardiovascular and Thoracic Annals*, 11: 237-244.
12. Racusen LC, Solez K, Colvin RB et al. (1999). The Banff 97 working classification of renal allograft pathology. *Kidney International*, 55: 713-723.
13. Yokomise H, Inui K, Wada H et al. (1996). Long-term cryopreservation can prevent rejection of canine tracheal allografts with preservation of graft viability. *Journal of Thoracic and Cardiovascular Surgery*, 111: 930-934.