



Brazilian Journal of OTORHINOLARYNGOLOGY

www.bjorl.org



CONSENSUS

Rhinosinusitis: evidence and experience

October 18 and 19, 2013 - São Paulo

Coordination

Wilma T. Anselmo-Lima e Eulalia Sakano

Participants

André Alencar, Atilio Fernandes, Edwin Tamashiro, Elizabeth Araújo, Érica Ortiz, Fabiana Cardoso Pereira Valera, Fábio Pinna, Fabrizio Romano, Francini Padua, João Mello Jr., João Teles Jr., José E. L. Dolci, Leonardo Balsalobre, Macoto Kosugi, Marcelo H. Sampaio, Márcio Nakanishi, Marco César, Nilvano Andrade, Olavo Mion, Otávio Piltcher, Reginaldo Fujita, Renato Roithmann, Richard Voegels, Roberto E. Guimarães, Roberto Meireles, Shirley Pignatari, Victor Nakajima

For the purpose of citation

Wilma Terezinha Anselmo Lima, Eulalia Sakano, Edwin Tamashiro, Elizabeth Araújo, Érica Ortiz, Fábio Pinna, Fabrizio Romano, Francini Padua, João Mello Jr., João Teles Jr., José E. L. Dolci, Leonardo Balsalobre, Macoto Kosugi, Marcelo H. Sampaio, Márcio Nakanishi, Marco César, Nilvano Andrade, Olavo Mion, Otávio Piltcher, Reginaldo Fujita, Renato Roithmann, Richard Voegels, Roberto E. Guimarães, Roberto Meireles, Victor Nakajima, Fabiana Cardoso Pereira Valera, Shirley Pignatari

Introduction

Rhinosinusitis (RS) is an inflammatory process of the nasal mucosa, and according to the evolution of signs and symptoms, it is classified as acute (ARS; < 12 weeks) or chronic (CRS; ≥ 12 weeks). According to the severity of the condition, it is classified as mild, moderate, or severe. Disease severity is graded using a visual analog scale (VAS) (Fig. 1), from 0 to 10 cm. Patients are asked to quantify, from 0-10 at the VAS, the degree of discomfort caused by their symptoms, with 0 meaning no discomfort and 10 the highest discomfort. Severity is then classified as: mild; 0-3 cm; moderate; > 3-7 cm; and severe; > 7-10 cm.¹

1cm  10cm

Figure 1 Visual Analogue Scale (VAS).

Although VAS has only been validated for CRS in adults, the European Position Paper on Rhinosinusitis and Nasal Polyps (EPOS) 2012¹ also recommends its use in ARS. There are several specific questionnaires for rhinosinusitis, but in practice, most have limited application, particularly in acute cases.²⁻⁴

Acute rhinosinusitis

Definition

ARS is an inflammatory process of the nasal mucosa of sudden onset, lasting up to 12 weeks. It may occur one or more times in a given period of time, but always with complete remission of signs and symptoms between episodes.

Classification

There are several classifications for RS. One of the most often used is the etiological classification, which is based mainly on symptom duration:¹

- Common cold or viral ARS: a condition that is usually self-limited, in which symptoms last less than ten days;
- Post-viral ARS: defined when there is symptom worsening after five days of disease, or when symptoms persist for more than ten days;
- Acute bacterial RS (ABRS): a small percentage of patients with post-viral ARS can develop ABRS.

Viral ARS or common cold symptoms traditionally last less than ten days. Symptom worsening around the fifth day, or persistence beyond ten days (and less than 12 weeks), can represent a case of post-viral RS. It is estimated that a small percentage of post-acute viral RS (around 0.5% to 2% of cases) develop into a bacterial infection.

Regardless of duration, the presence of at least three of the signs/symptoms below may suggest ABRS:

- Nasal discharge (with unilateral predominance) and purulent secretion in the nasopharynx;
- Local intense pain (with unilateral predominance);
- Fever > 38°C;
- Elevated erythrocyte sedimentation rate or C-reactive protein levels;

- “Double worsening”: acute relapse or deterioration after the initial stage of mild symptoms.

Associated factors

Environmental exposure

Exposure to increasing levels of humidity, but not fungi, has been associated with ARS.⁵ Seasonal variations have also been reported in the literature, with increased incidence of ARS during the winter months.⁵⁻⁹ Exposure to air pollution,¹⁰⁻¹² irritants used in the production of pharmaceuticals,¹³ in photocopiers,¹⁴ and smoke from forest fires,¹⁵ have all been associated with increased prevalence of ARS symptoms.

Anatomical factors

Anatomical variations including Haller cells, concha bullosa, nasal septal deviation, choanal atresia, pharyngeal tonsil hypertrophy, nasal polyps, hypoplastic sinuses, and odontogenic origin of infections may be associated with ARS.^{10,16-18}

Allergy

The role of allergy in ARS is controversial. There have been studies that assessed the association between allergic rhinitis and ARS,¹⁹⁻³⁵ while others dismissed such an association.³⁵⁻³⁷

Ciliary injury

Ciliary injury has been considered a characteristic of viral and bacterial RS.³⁸ It includes the loss of cilia and ciliated cells, as well as alteration of the normal mucociliary transport. However, smoking and allergies have also been implicated in the alteration of the mucociliary transport,^{39,40} and the alteration in the mucociliary clearance in patients with allergic rhinitis has been shown to predispose to ARS.²²

Primary ciliary dyskinesia (PCD)

This is a rare autosomal recessive disease, in which the cilia are either immotile or beat with a pattern incompatible with mucus transport in the airway. PCD is associated with chronic upper airway symptoms such as rhinorrhea, episodic facial pain, anosmia, and bronchiectasis.⁴¹ Newborns may present rhinorrhea from the first day of life.^{42,43} There are no data on the frequency of ARS episodes in this group of patients. According to the European Respiratory Society Task Force on Primary Ciliary Dyskinesia, recurring ARS is rare in patients with PCD, although the episodes should be treated with appropriate antibiotics and for a prolonged period of time.^{44,45}

Smoking

Children living in environments with adult smokers are more prone to episodes of ARS than those who are not exposed to this environment.⁴⁶ Active smokers with ongoing allergic inflammation have increased susceptibility to ARS when compared to non-smokers during the course of allergic inflam-

mation, suggesting that exposure to cigarette smoke and allergic inflammation are mediated by different pathways and possible synergistic mechanisms.⁴⁷

Smoking (active and passive) has been shown to alter the normal bacterial flora present in the nasopharynx, resulting in greater potential for colonization of pathogens than in non-smokers.⁴⁸ Once smoking is discontinued, the microbial population begins to show the same pattern found in nonsmokers.⁴⁹

Gastroesophageal reflux

Little is known about the association between ARS and gastroesophageal reflux. Although studies conducted between 1997 and 2006 have observed a significant association between the two diseases,⁵⁰ a recent systematic review found a weak association between acid reflux, nasal symptoms, and ARS.⁵¹

Anxiety and depression

States of impaired mental health, anxiety, or depression are often associated with increased susceptibility to ARS.⁵² However, the involved mechanisms remain unclear.

Antimicrobial resistance

The main pathogens of ABRS include *S. pneumoniae*, *H. influenzae*, *S. pyogenes*, *M. catarrhalis*, and *S. aureus*.³⁸ Despite the problems related to bacterial resistance, it is estimated that approximately 80% of cases of mild ARS respond to amoxicillin at a dose of 70 to 90 mg/kg/day. A study by Principi and Esposito⁵³ demonstrated that most cases of ARS caused by *H. influenzae* and *M. catarrhalis* and approximately 15% of those caused by *S. pneumoniae* resolve spontaneously. Lin et al. observed that 70% of *S. pneumoniae* and 71.4% of *H. influenzae* cases isolated from 69 children were resistant to amoxicillin and clavulanate.¹⁹

Concomitant chronic disease

Concomitant chronic disease (bronchitis, asthma, cardiovascular disease, diabetes mellitus, or malignant tumor) in children has been associated with an increased incidence of ARS after *influenza*.⁵⁴

Clinical diagnosis

Signs and symptoms

At primary health care levels and for epidemiological purposes, ARS can be diagnosed based on symptoms alone, without detailed otorhinolaryngological assessment and/or without imaging studies.

In these cases, the distinction between the types of ARS is mainly determined through clinical history and physical examination performed by general practitioners and specialists, whether or not otorhinolaryngologists. It is worth mentioning that, at the time of the examination, patients may not report symptom worsening if not asked carefully. The report of symptoms occurring a few days before with a

recurrence of symptoms just before evaluation is frequent. Health care professional should realize that, in most cases, this may represent the evolution of the same disease, from a viral to a post-viral ARS, rather than two distinct infections. Subjective evaluation of patients with ARS and their diagnosis is based on the presence of two or more of the following cardinal symptoms:¹

- Nasal obstruction/congestion;
- Anterior or posterior nasal discharge/rhinorrhea (most often, but not necessarily, purulent);
- Facial pain/pressure/headache;
- Disorder of olfaction.

In addition to the symptoms described above, odynophagia, dysphonia, cough, and ear fullness and pressure, as well as systemic symptoms such as asthenia, malaise, and fever, may also occur. The few studies on the frequency of these symptoms in ARS in the community have shown great variability.⁵⁵⁻⁵⁷ The possibility of ABRS is greater in the presence of three or more of the following signs and symptoms:¹

- Nasal secretion/presence of pus in the nasal cavity with unilateral predominance;
- Local pain with unilateral predominance;
- Fever > 38°C;
- Deterioration/worsening of symptoms after the initial period of the disease;
- Elevated erythrocyte sedimentation rate (ESR) and C-reactive protein (CRP) levels.

ARS symptoms have a characteristically abrupt onset, without a recent history of RS symptoms. In the acute exacerbation of CRS, the diagnostic criteria and treatments similar to those used for ARS should be used.¹ “Cough”, although considered an important symptom according to most international guidelines, is not one of the cardinal symptoms in this document. Nonetheless, in the pediatric population, cough is considered one of the four cardinal symptoms, replacing olfaction disorders.^{1,58} Gwaltney et al.,⁵⁹ when studying the symptoms of spontaneous rhinosinus infections by rhinovirus in relation to the time of onset and duration, observed that the peak of typical symptoms such as nasal obstruction, rhinorrhea, and cough occurs between

the second and third days of infection (Fig. 2), with a tendency to decrease thereafter. Symptoms can, however, last for 14 days or more.

Nasal obstruction is one of the important symptoms of ARS and should be assessed together with other patient complaints. In spite of the scarcity with which methods of objective evaluation of nasal obstruction (such as rhinomanometry, nasal peak inspiratory flow, and acoustic rhinometry) are applied in daily practice in patients with ARS, studies have shown a good correlation between the symptoms reported by patients and the objective measurements obtained by these methods.¹

Purulent rhinorrhea is often interpreted in clinical practice as indicative of bacterial infection and need for antibiotic use.^{60,61} However, evidence of this association is limited. Although it is a symptom that appears to increase the chances of positive bacterial culture, in isolation it does not characterize ABRS.⁶² Purulent rhinorrhea with unilateral predominance and pus in the nasal cavity have a positive predictive value of only 50% and 17%, respectively, for positive bacterial culture obtained by maxillary sinus aspirate.⁶³ Thus, the presence of purulent rhinorrhea does not necessarily indicate the existence of a bacterial infection and should not be used as an isolated criterion for the prescription of an antibiotic.⁶²⁻⁶⁴ Decreased olfaction is one of the most difficult symptoms to quantify in clinical practice and usually only is evaluated subjectively. Complaints of hyposmia and anosmia are commonly associated with ARS, and can be assessed with good correlation by employing validated objective tests with subjective scales.^{65,66} It is important that these tests of olfactory function are translated and culturally and socioeconomically adapted for their use in different populations.⁶⁷

Facial pain and pressure commonly occur in ARS. When unilateral, facial or dental pain has been considered a predictor of acute maxillary sinusitis.^{55,68} The complaint of dental pain in the upper teeth abutting on the maxillary sinus showed a statistically significant association with the presence of positive bacterial culture obtained from sinus aspirates, with a predominance of *S. pneumoniae* and *H. influenzae*.⁶⁹ However, in another study, the predictive pos-

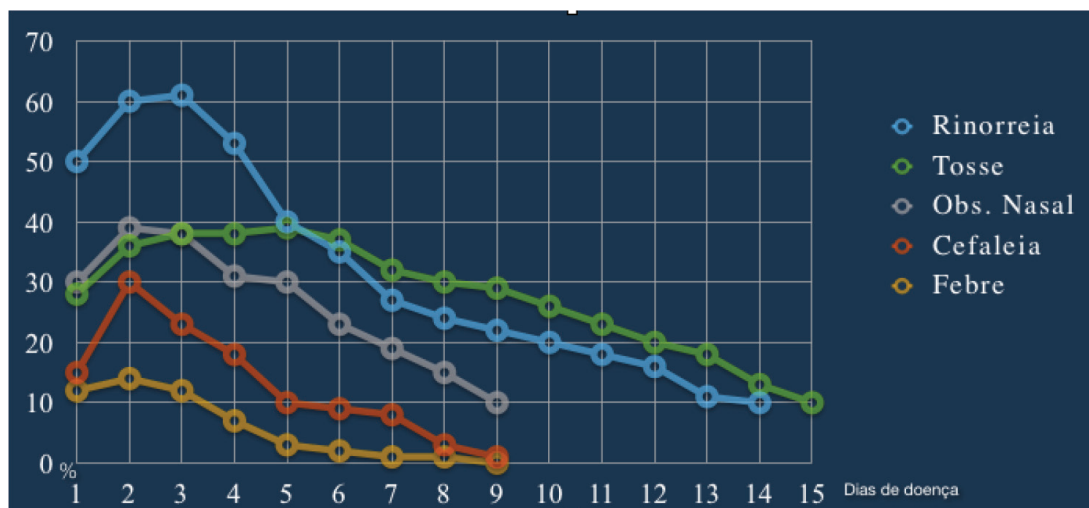


Figure 2 Rhinosinusitis symptoms of acute infection caused by rhinovirus in relation to the start time and duration. (Adapted from Gwaltney et al. [1967]).⁵⁹

itive value of unilateral facial pain for bacterial infection was only 41%.⁶⁸

Several studies and guidelines have sought to define the combination of symptoms that best determine the highest probability of bacterial infection and antibiotic response.¹ In the study by Carenfelt and Berg,⁶⁸ the presence of two or more findings (purulent rhinorrhea and unilaterally predominant local pain, pus in the nasal cavity, and bilateral purulent rhinorrhea) showed 95% sensitivity and 77% specificity for the diagnosis of ABRS.

The clinical examination of a patient with ARS should initially comprise assessment of vital signs and physical examination of the head and neck, with special attention aimed at the presence of localized or diffuse facial edema. At oroscopy, posterior purulent oropharyngeal secretions⁵⁸ are important. Anterior rhinoscopy is a part of the physical examination that should be performed in the primary assessment of patients with rhinosinus symptoms; although it provides limited information, it may reveal important aspects of the nasal mucosa and secretions.¹

Fever may be present in some patients with ARS in the first days of infection⁵⁹ and, when higher than 38°C, it is regarded as indicative of more severe disease and may indicate the need for more aggressive treatment, especially when associated with other severe symptoms. Fever is also significantly associated with positive bacterial culture obtained from nasal aspirate, especially *S. pneumoniae* and *H. influenzae*.

In patients with ARS, the presence of edema and pain on palpation of the maxillofacial region may be indicative of more severe disease requiring antibiotics, despite the limited data available in literature.⁶⁰

At the primary health care level, nasal endoscopy is usually not routinely available and is not considered a mandatory examination for ARS diagnosis. When available, it allows the specialist to better visualize the nasal anatomy and to obtain a topographic diagnosis and material for microbiological analysis.¹

At the assessment and clinical examination of patients, possible variations between geographical regions and different populations should be considered. Among other factors, climatic, social, economic, and cultural differences, as well as opportunity of access to health care, can change the subjective perception of the disease and potentially generate peculiar clinical features. The importance of this variability is unknown; more studies are needed to establish this.

Complementary examinations

Nasal endoscopy

As previously mentioned, it is not a mandatory examination for the diagnosis of ARS, but it may be useful for the assessment of the nasal anatomy, biopsy, and culture. Several microbiological studies have shown a reasonable correlation between the findings collected by puncture from the middle meatus, allowing for a microbiological confirmation of the agent and its therapeutic response. Some authors recommend diagnostic confirmation through nasal endoscopy and culture, as many patients with clinical or radiological evidence of ABRS do not have a positive culture.^{1,70}

C-reactive protein (CRP)

Low or normal levels of this protein can identify patients with low likelihood of bacterial infection, preventing unnecessary antibiotic use. Treatment guided by polymerase chain reaction (PCR) has been associated with a reduction in antibiotic use, without affecting the outcome. Although more studies are still required to include this routine diagnostic examination for ABRS, some studies have shown that CRP levels are strongly associated with the presence of changes in computed tomography (CT), and that high CRP levels can be considered predictive of positive bacterial culture from puncture or sinus lavage.^{69,71,72}

Erythrocyte sedimentation rate (ESR)

Inflammatory markers such as ESR and plasma viscosity are elevated in ARS, and may reflect disease severity and the need for more aggressive treatment. Their levels are associated with the presence of CT alterations in ARS and values greater than 10 are considered predictive of fluid level or opacity at CT. High values are also predictive of positive bacterial culture by puncture or lavage.^{1,73,74}

CT

It should not be used in the initial diagnosis of ARS, although it is indicated in special situations, such as unilateral signs and symptoms, suspected complications, and treatment failure. It must be considered in severe disease and immunosuppressed patients. Recent studies suggest that routine use of CT in patients with ARS adds little information to their management.^{1,75,76}

Simple X-ray

It has low sensitivity and specificity, being of little use in the diagnosis of ABRS due to the high number of false-positive and false-negative results.¹

Ultrasonography (USG)

USG of the paranasal sinuses has low sensitivity and very limited usefulness in the diagnosis of ARS, due to the high number of false-positive and false-negative results.¹

Treatment

There is a worldwide concern regarding the indiscriminate use of antibiotics and bacterial resistance. It is estimated that approximately 50 million unnecessary antibiotic prescriptions for RS are given in the US and used to treat viral infections. When a more selective algorithm for antibiotic therapy is followed, the benefit is greater and only three patients need to be treated for one to achieve the expected result.⁷⁷ Thus, there is a worldwide trend to treat ARS according to disease severity and duration.

Antibiotic therapy

Meta-analyses of placebo-controlled, randomized, and double-blinded trials show the efficacy of antibiotics in improving symptoms of patients with ABRS, especially if carefully administered. They are not recommended in cases of viral RS, as they do not alter the course of

the disease;⁷⁸ they are never indicated for symptomatic treatment and their indiscriminate use should be avoided, since that can increase the risk for the development of bacterial resistance.⁷⁹

Clinical studies have demonstrated that approximately 65% of patients diagnosed with ABRS show spontaneous clinical resolution⁸⁰ sometimes within the first few days;⁷⁸ therefore, the initial adjuvant treatment without antibiotics is a viable option in cases of mild and/or post-viral sinusitis. The introduction of antibiotics should be considered when there is no improvement after adjuvant therapy or if symptoms exacerbate. Antibiotics are indicated in cases of moderate to severe ABRS; in patients with severe symptoms (fever > 37.8°C and in the presence of severe facial pain); in immunocompromised patients, regardless of disease duration; and in cases of mild or uncomplicated ABRS that do not improve with initial treatment with topical nasal corticosteroids.^{81,82}

There are no studies that define the optimal duration of antibiotic treatment. In general, treatment duration varies from seven to ten days for most antimicrobial agents and 14 days for clarithromycin. Amoxicillin is considered the antibiotic agent of first choice in primary health centers, due to its effectiveness and low cost. Macrolides have comparable efficacy to amoxicillin and are indicated for patients allergic to β -lactams.^{79,82,83} In cases of suspected penicillin-resistant *S. pneumoniae*, severe cases, and/or associated comorbidities, broader-spectrum antimicrobials are indicated.

Intranasal topical corticosteroids

Patients older than 12 years with post-viral RS, or with uncomplicated ABRS with mild or moderate symptoms⁸¹ without fever or intense facial pain,⁸² benefit from topical nasal corticosteroids as monotherapy. In addition to relieving the symptoms of rhinorrhea, nasal congestion, sinus pain, and facial pain/pressure,⁸¹ topical corticosteroids minimize the indiscriminate use of antibiotics, thus reducing the risk of bacterial resistance.⁸²

Studies suggest that topical nasal corticosteroids in combination with appropriate antibiotic therapy results in faster relief of general and specific symptoms of RS, especially congestion and facial pain,⁸⁴⁻⁸⁹ and accelerates patient recovery, even when there is no significant improvement in the radiological image.^{87,88,90} However, the optimal dose and treatment duration still need to be established.⁸⁵⁻⁸⁸ Although there are no studies comparing the effectiveness of several types of nasal corticosteroids in ARS, many of them (such as budesonide, mometasone furoate, and fluticasone propionate) have shown benefits.⁹⁰ Their use is recommended for at least 14 days to effect improvement in symptoms.

Oral corticosteroids

The use of oral corticosteroids for adults with ABRS and intense facial pain is recommended, as long as there are no contraindications to their use.^{91,92} Oral corticosteroids should be used for three to five days, in the first few days of the acute event only, and always associated with antibiotic therapy, in order to shorten the duration of facial

pain⁹¹ and decrease the need for analgesics.⁹² Evaluation after ten to 14 days of treatment shows no significant differences in symptom resolution or treatment failure when comparing antibiotic therapy alone and antibiotics with oral corticosteroids.⁹² The few studies in the literature using oral corticosteroids in the treatment of ABRS showed favorable results with methylprednisolone and prednisone.

Nasal lavage

Despite the frequent use of isotonic or hypertonic saline solution in nasal lavage of patients with rhinitis and RS, little is known about their real benefits in ARS.

Randomized trials⁹³ comparing nasal saline and hypertonic solutions showed greater intolerance to hypertonic solution. A meta-analysis of placebo-controlled, randomized, double-blinded trials showed evidence of limited benefit of nasal saline irrigation in adults, with no difference observed between case and control groups. A single study showed a mean difference of improved time to symptom resolution of 0.3 days, without statistical significance.⁹⁴

In another meta-analysis of patients younger than 18 years with ARS, there was no clear evidence that antihistamines, decongestants, and nasal lavage were effective in children with ARS.⁹⁵

Despite little evidence of clinical benefit, the use of nasal saline lavage is generally recommended in patients with ARS. It promotes improvement of ciliary function, reduces mucosal edema and inflammatory mediators, and helps to cleanse the nasal cavity, by removing the infectious secretions, and saline lavage has no reported side effects.⁹⁶

Oral and topical decongestants

The use of oral decongestants alone or associated with antihistamines in patients with ABRS does not significantly change the clinical or radiological evolution, either in children⁹⁷ or in adults.⁹⁸

Topical nasal decongestants (topical vasoconstrictors), such as 0.1% xylometazoline, are not indicated alone for the treatment of ABRS,⁹⁹ but they do provide subjective and objective improvement of nasal obstruction in patients with viral ARS. In cases of patients with ABRS as a complication of persistent rhinitis, the use of topical nasal vasoconstrictors may relieve nasal obstruction¹⁰⁰ and increase inspiratory nasal flow.¹⁰¹ Even in this restricted population, it is important to consider the complications caused by interactions with other drugs, as well as the possibility of adverse effects on hypertension, glaucoma, diabetes mellitus, thyroid disease, urinary retention, and benign prostatic hyperplasia (BPH).⁹⁹

Due to the rebound effect, the use of topical nasal vasoconstrictors should be restricted to a maximum of five days. They should not be used by children younger than 2 years.

Nonsteroidal anti-inflammatory drugs (NSAIDs)

A systematic review with Cochrane collaboration demonstrated that NSAIDs do not significantly reduce the overall symptom score of patients with common cold, or the duration of

colds. Nonetheless, their analgesic effect is beneficial, with improvement of headache, ear pain, and muscle and joint pain, and without evidence of increased adverse effects in this population. Therefore, they can be used for the symptomatic improvement in patients with common cold.¹⁰²

In spite of their analgesic effect in acute inflammatory processes of the ear, oropharynx, and paranasal sinuses,¹⁰³ NSAIDs are not recommended as the only treatment of ARS, and should be used with caution even when associated with antibiotics, due to the increase in possible side effects.^{104,105}

Mucolytics

The association of mucolytics in the treatment of ARS is still controversial. It is believed that they reduce nasal secretion viscosity due to their mucoregulatory activity, resulting in fragmentation of acid mucopolysaccharide (AMPS) fibers and, therefore, facilitating mucociliary transport and their elimination through the nose and paranasal sinuses.¹⁰⁶ When combined with antibiotics, they may facilitate penetration into the paranasal sinus mucosa and improvement of the inflammatory process.¹⁰⁷ There have been some studies using oral bromhexine combined with oral antibiotics and acetylcysteine combined with topical nasal antibiotics.¹⁰⁶⁻¹⁰⁸ However, those studies did not clearly state the time and severity of RS; therefore, their results should be analyzed with caution. Studies with oral erdosteine showed no significant benefit in children.¹⁰⁹

Phytotherapies

There are few placebo-controlled, randomized, and double-blinded studies of herbal medicines in the treatment of ARS. In spite of the benefits demonstrated by some of them, their use in clinical practice should be approached cautiously because of the scarcity of published evidence regarding the pharmacokinetics and pharmacodynamics of these components and their mechanisms.

- *Pelargonium sidoides*:¹¹⁰ A study with Cochrane collaboration for the treatment of acute respiratory infections concluded that it can be effective in alleviating the symptoms of the common cold and post-viral ARS in adults.
- Myrtle Essential Oil: which is extracted from *Pinus* spp. (pine), *Citrus aurantifolia* (lime) and *Eucalyptus globulus*. A controlled, randomized, multicenter trial reported a statistical difference in symptom improvement score of post-viral ARS (from 10.5 to 9.2) when compared to placebo, reducing the need for antibiotics (20% in patients who used the medication vs. 40% in those who used a placebo). In Germany, it is recommended for the treatment of ARS.¹¹¹

Probiotics

A Cochrane review¹¹² with ten studies demonstrated that probiotics are superior to placebo in reducing the number of patients with upper respiratory tract infection episodes, number of episodes per participant, and antibiotic use. Therefore, they may be indicated for the prevention of the common cold.

Immunomodulators

A systematic review¹¹³ of eight randomized controlled trials (RCTs) in children with more than three episodes of upper airway infections per fall/winter (six months) who used OM-85 BV extract demonstrated that these children had fewer episodes of upper airway viral infections when compared to the placebo group (38% vs. 52%; $p < 0.001$), and that the benefits are greater for patients with risk factors for recurrent infections.

Acute rhinosinusitis complications

RS complications are caused by acute or chronic infections; although they are more common in children, they may also occur in adults and can be orbital-palpebral, bone, and intracranial.

Epidemiology

Most RS complications originate from ethmoid sinus infections. It is estimated that prior to the advent of antibiotics, the rate of blindness arising from complications was up to 20%, and is currently around 11% of cases. Mortality from meningitis of sinus origin in the past was approximately 17%; it currently ranges from 1% to 2.5%.^{1,114-116} The mortality rate from intracranial complications is around 20% to 40%,^{114,117} and from neurological deficits, 25%.^{117,118} The incidence varies by geographic region. In the Netherlands, for instance, the complication rate is estimated at 1:12,000 ARS in children and 1:36,000 ARS in adults,¹¹⁹ whereas in the United States it ranges from 2.7 to 4.3:1,000,000;¹²⁰ and in France, 2.5:1,000,000/year, excluding pediatric patients.¹²¹ It is more frequent in males. In children, complications usually occur from the acute processes, whereas in adults, they are more often seen with CRS with or without polyposis.^{119,120,122} There are no exact prevalence data for the several types of complications. Orbital complications comprise from 60% to 75%; intracranial, from 15% to 20%; and osseous, 5% to 10%.¹²³ Childhood sinus disease is the presumed cause of 10% of intracranial suppuration, 10% of preseptal cellulitis, and 90% of orbital cellulitis, subperiosteal and intraorbital abscesses.¹²⁴ Antibiotic prescription does not appear to reduce the incidence of complications.^{5,119}

Physiopathogenesis

Dissemination occurs by direct extension, bone erosion, through diploic veins and hematogenously through venous involvement.¹²⁵ Certain anatomical characteristics are important in the genesis of these complications:^{1,114}

- the thin bony lamina papyracea that separates the orbital contents from ethmoid cells;
- in children, a number of larger neurovascular foramina and several bony sutures that remain open in the medial orbital wall and facilitate the dissemination of infection; and
- the valveless venous system that allows blood to flow unimpeded into the interior of the skull. The principal pathway is through the superior and inferior ophthal-

mic veins, which communicate with intraorbital vessels and directly with the cavernous sinus.

Classification of orbital complications

Existing classifications are based on anatomical-clinical criteria, but none is universally accepted. It is important to remember that the orbital septum consists of a deflection or extension with change in direction, laterally forming the lateral palpebral ligament, and medially, the medial palpebral ligament, behind the lacrimal sac. It functions as a protective barrier against infections for the internal orbital area.^{116,118,123} The earliest classification was that of Hubert, which dates from 1937.¹¹⁸ In 1970, Chandler et al.¹²³ proposed a classification that is still the most cited in the world literature, which takes into account the orbital septum:

- Group 1 - periorbital cellulitis: eyelid inflammation with edema, without dissemination into the orbit;
- Group 2 - Orbital cellulitis: the infection crosses the orbital septum and penetrates the orbital cavity;
- Group 3 - subperiosteal abscess: post-septal abscess between the lamina papyracea and the periosteum, contained by the latter;
- Group 4 - orbital abscess: true orbital abscess, purulent secretion inside the orbit, within the extrinsic eye musculature, near the optic nerve;
- Group 5 - thrombosis of the cavernous sinus.

Due to failures observed in this classification revealed by imaging studies (CT and magnetic resonance imaging [MRI]), Mortimore and Wormald¹²⁶ suggested removing the cavernous sinus thrombosis group from orbital complications and placing it into the cranial complications group.

- Group 1 - preseptal infection;
- Group 2 - subperiosteal post-septal infection;
- Group 3 - intraconal post-septal infection.

In Brazil, Velasco et al.¹²⁷ proposed a simpler classification, with only three groups, considering preseptal cellulitis as a palpebral rather than orbital infection:

- Orbital cellulitis;
- Subperiosteal abscess;
- Orbital abscess.

Among all classifications, most authors still use that proposed by Chandler.^{116,128-131}

Bacteriology

Regarding the bacteriology in orbital complications, the most common microorganisms are the same that are identified in RS.¹²⁸ The widespread use of the heptavalent pneumococcal conjugate vaccine (PCV7) has reduced the frequency of *S. pneumoniae* in RS complications, with a subsequent increase in infections by *S. aureus*, as well as in the prevalence of methicillin-resistant *S. aureus* (MRSA) associated with orbital infections.¹³²

Orbital-palpebral cellulitis

The presence of palpebral edema, erythema, localized pain, nasal obstruction, rhinorrhea, difficulty opening the eyes, and possibly fever, can be observed in cases of or-

bital-palpebral cellulitis. It is caused by venous obstruction created by the pressure on the ethmoid vessels,^{116,118} and can progress into palpebral abscess and rarely, to cutaneous fistula. Visual acuity and ocular motility are preserved and this assessment is difficult in some children.¹³³ Inflammation of the eyelid and conjunctiva is observed on CT as edematous tissue.¹³⁴ It occurs as a complication of viral upper respiratory tract infection, acute dacryocystitis, skin infection and, less commonly, RS.¹³⁵⁻¹³⁸ It has a favorable prognosis with antibiotics and often requires no imaging tests, being treated as simple acute ethmoiditis.¹²¹

Orbital cellulitis

It is characterized by edema extending into the post-septal region. It appears most often as a complication of acute RS.^{137,138} It presents exophthalmia, chemosis, and conjunctival hyperemia,¹³⁰ and affects the orbital adipose tissue without forming an abscess. Visual acuity and ocular motility are usually preserved, but a slight decrease of the latter may occur, and some children initially may lose the ability to distinguish green and/or red colors.^{126,139,140} Ophthalmologic evaluation and emergency CT are necessary, and treatment should be aggressive and immediate.

Subperiosteal abscess

The clinical picture presents with high fever (39.5°C or higher), chills, changes in general status, exophthalmos with exophoria, decreased ocular motility, severe pain, preserved visual acuity (although decreased in some cases),¹⁴¹ and leukocytosis with a shift to the left.¹⁴¹ The CT discloses the presence of purulent collection in the medial orbital wall, between the periorbital and the orbital bone, with an extraconal location and, thus, outside the ocular muscles.¹¹⁶ The most common microorganisms are Streptococci in children and anaerobic bacteria in adults. Total vision loss can occur, especially in diabetic adults. Abscesses located more superiorly can result in intracranial complications by extending into the frontal lobe.

Orbital abscess

It is an intraconal lesion, commonly the consequence of late diagnosis or immunosuppression.¹⁴² The clinical picture is more severe with irreducible, painful exophthalmos with severe chemosis, complete ophthalmoplegia, and marked decrease in visual acuity.¹³⁰ The CT image shows purulent collection in the soft tissues around the eyeball. It may remain localized or extend through the orbital septum, emerging as a floating mass in the eyelid. It is a severe condition that can lead to amaurosis. The visual impairment depends on the orbital pressure and optic neuritis. Thromboembolism may occur in the vascular supply of the nerve, choroid, and retina. With increasing pressure, there is retinal artery occlusion, which, if lasting over 90 minutes, leads to irreversible degeneration of the optic nerve and retina.^{116,118}

The orbital apex syndrome is a localized form of orbital cellulitis, wherein vascular-nervous lesions occur in cranial nerves III, IV, and VI, and in the ophthalmic branch of the V nerve, which pass through the superior orbital fissure

and optic foramen.^{116,118} Clinically, the eyeball is fixed and pupils are dilated and nonreactive to light; ptosis, and palpebral, corneal, and conjunctival hypoesthesia are also observed. When there is a concomitant lesion in the optic foramen, ophthalmoplegia, amaurosis, severe ocular pain, and sensory deficits from anesthesia to neuralgia are seen in the distribution of the ophthalmic nerve. Since the posterior orbital bone is thicker than the anterior bone, these findings are rare and, when present, are more common in sphenothmoiditis.

Cavernous sinus thrombosis

It consists in the dissemination of an infection along the optic canal or intravenously to the cavernous sinus. It causes blindness, abolition of the pupillary reflex to light, corneal anesthesia, and paralysis of nerves III and VI. The following are also observed: high fever, altered sensorium, prostration, severe deep retro-orbital pain, bilateral involvement, and central nervous system signs. The accompanying photophobia and neck stiffness may be mistaken for meningitis. The mortality rate is approximately 30%.¹¹⁴

Diagnosis

The diagnosis of complications should involve otorhinolaryngologic, ophthalmic, and neurological evaluations, as well as neurosurgical assessment, when necessary. Imaging studies, particularly CT with contrast and MRI, play an important role. High-resolution CT is the technique of choice when orbital complications are suspected. MRI better characterizes the local extent of disease or its dissemination beyond the nasal and paranasal cavities. A combination of CT and MRI is useful in cases of difficult diagnosis.¹⁴³ It usually discloses swelling of the medial rectus muscle, periorbital lateralization, and downward and lateral displacement of the eyeball. When obliteration of the extraocular muscle detail is evident and the optic nerve appears as confluent mass, an orbital abscess is present. Imaging studies may also detect air bubbles produced by anaerobic bacteria. The predictive accuracy of the clinical diagnosis is 82% and of the CT is 91%.¹⁴⁴⁻¹⁴⁶

Laboratory analysis usually shows leukocytosis with a left shift; an elevated CRP level is associated with more severe outcomes and may suggest or indicate the need for more aggressive treatment in the early phase.⁷¹

Differential diagnosis

Patients with RS and proptosis may have a subperiosteal orbital hematoma; 13 cases have been reported in the literature.¹⁴⁷ Orbital lymphatic malformations can lead to proptosis, compressive optic neuropathy, vision loss, and cellulitis. The MRI shows a well-outlined intraorbital mass with a heterogeneous signal.¹⁴⁸

General treatment standards

Treatment is medical for orbital-palpebral or periorbital cellulitis. It requires hospitalization, careful observation, and intravenous antibiotic therapy. Clindamycin or amoxi-

cillin + clavulanate potassium with metronidazole and/or, particularly in children, oxacillin + ceftriaxone can be used in the treatment. Most patients respond well to the conservative treatment, and surgical intervention is not necessary.^{115,116,118} It is always recommended to discuss with the local Hospital Infection Committee which antibiotic is the most appropriate.

The identification of abscesses on the CT, orbital or progressive visual findings, or lack of response to intravenous antibiotics, are all indications for surgical exploration. Intensive ophthalmological control is crucial.¹⁴⁹

Children with small and medium-sized subperiosteal abscesses, without significant ocular signs, may be successfully treated medically. Surgical drainage is indicated for medium-sized to large abscesses with severe visual loss, and in cases with inadequate response to medical treatment.¹⁵⁰ Usually, a medium-sized subperiosteal abscess that does not improve with medical therapy can be drained endoscopically, while a lateral or intraconal abscess may require an open procedure.¹⁵¹

There are controversies regarding the surgical indication in subperiosteal abscesses. For the initial treatment,¹⁴¹ many studies have documented an improvement in young children with medical therapy alone.^{133,142,152} If medical treatment is chosen, it is essential that clinical improvement occurs within 24 to 48 hours; that there is no visual impairment; that the abscess volume is less than 0.5 to 1.0 mL; the abscess is located medially; that there are no systemic symptoms and that the child is less than four years of age.¹⁵³ Surgical drainage should be strongly considered when an older child has a subperiosteal abscesses with significant ocular findings, when improvement is not observed after 48 hours of medical treatment, when the abscess volume > 0.5 mL, the length > 17 mm, and the width > 4.5 mm.¹⁵⁴ In general, immediate surgical drainage is indicated in the following situations: the abscess is not in a medial location, or there is visual loss, clinical deterioration or an absence of clinical improvement in 24 to 48 hours.^{114,116,141}

Based on the diagnosis of a subperiosteal abscess, in which there is no purulent secretion after opening the lamina papyracea, an orbital abscess should be suspected, and incisions should be performed along the periosteum to release the purulent material from the orbit.¹⁵⁵ Some authors always recommend surgical treatment for subperiosteal abscess, with drainage of the abscess and sinuses involved.¹⁴¹ The endoscopic approach is always safer and more effective, but associated external approaches may be necessary.

Acute sphenoid RS may cause thrombosis of the ipsilateral or contralateral cavernous sinus. Early surgical sphenoidotomy and aggressive medical treatment are the bases of the successful management of this life-threatening complication.¹⁵⁶

Intracranial complications

These include extradural and subdural abscesses, brain abscesses, meningitis, cerebritis, and thrombosis of the cavernous and superior sagittal sinus.^{120,122,123,131,153,156} The most common are: subdural abscess (56%), epidural abscess (44%), and brain abscess (19%). Multiple intracranial complications were observed in 31% of cases.^{117,122,157} All clinical forms begin as encephalitis, but as necrosis and liquefaction

occur, a capsule develops, forming the abscess. There is a high incidence of anaerobic bacteria and mixed flora. Microorganisms most frequently mentioned in the literature include *Streptococcus millieri* and *S. anginosus*, *Fusobacterium* sp. and *S. aureus*.^{114,128,158,159} *S. anginosus* causes more severe infections, higher rates of neurological complications, more neurosurgical interventions, and more central nervous system sequelae.¹⁶⁰ Polymicrobial cultures are obtained in 50% of patients.¹⁶¹

Meningitis

In decreasing order of frequency, the paranasal sinuses related to the origin of meningitis, are the sphenoid, followed by the ethmoid, frontal, and maxillary sinus. Clinical manifestations include fever, severe headache, neck stiffness, irritability, and behavioral disorders. CT defines and delimits the disease and can identify the presence of additional complications. Lumbar puncture¹²⁵ reveals increased proteins and cells, and a culture and sensitivity test should be performed. Lumbar puncture is contraindicated in the presence of intracranial hypertension (ICH) or abscess.¹²⁵ The treatment is medical, and sinus intervention is reserved for refractory cases. The mortality rate is around 5%.^{116,118}

Extradural abscess

This consists of a purulent collection between the dura mater and the cranium. Occasionally, it is associated with frontal osteomyelitis. The clinical manifestations are vague, with few or no neurological signs, which, when present, include persistent headache, fever, and rarely, behavioral changes. The diagnosis is usually delayed because of a failure to recognize the significance of the clinical findings. By the time of diagnosis there is usually ICH with worsening headache, vomiting, and behavioral changes.^{116,118}

Subdural abscess

Subdural abscess is characterized by the presence of purulent collection between the dura mater and the pia-arachnoid. Patients present severe headache, fever, and decreased level of consciousness. CT shows a decreasing image, not extending beyond the midline, thus differentiating from the extradural abscess. Surgery is performed at the neurosurgeon's discretion.^{116,118}

Brain abscess

The incidence of cases of sinus origin varies greatly, ranging from 3% to 11% up to 66%. The most common location is in the frontal lobe. Focal symptoms and increased intracranial pressure appear late with poor general condition, coma, and cranial nerve palsy. The frontal lobe is an area of clinical silence that yields inconstant symptoms. Fever, ICH, seizures, waking period disorders, coma, motor deficit, sensory disturbances, and altered vision may occur.

Imaging studies show a rounded lesion with a hypodense center and peripheral enhancement that initially is irregular but becomes more well defined as the necrotic portion

progresses. It can be multilocular. Lumbar puncture is contraindicated due to the risk of brain stem decompression and herniation. The initial treatment during the phase of cerebritis is based on antibiotic therapy, although empirical. Once an abscess is formed, surgical drainage is indicated by puncture or craniotomy^{159,162,163} combined with concomitant paranasal sinus drainage.¹⁶² The latter, alone, does not substitute for intracranial drainage.¹⁵⁷ Antibiotics should be maintained for four to eight weeks.¹²⁸ Third-generation cephalosporins can be used in combination with metronidazole, mannitol, hyperventilation, and dexamethasone, with or without anticonvulsants.¹²⁸

Bone complications

They occur with the extension of the infectious process to the bone, possibly involving the brain and nervous system. The most common associated sinus infections are in the frontal and maxillary sinuses.¹ In the frontal region, there is a diploic spongy bony layer, with a rich vascular network including diploic veins that course between the external and internal bone laminae. These veins do not have valves and allow unimpeded passage of blood between the spaces of the sinus mucosa and the skull.¹ Series of patients with complications of sinusitis demonstrated that osteomyelitis occurs in 9%¹⁴⁶ to 32% of cases.¹⁶⁴ A peculiar clinical form of localized frontal osteomyelitis may be focal or circumscribed, often with progression to a cutaneous fistula. The diffuse or disseminated frontal form is characterized by thrombophlebitis of the diploic veins, which progresses to the frontal bone and the cranial cavity, leading to avascular necrosis, bone sequestration, and expansion to subperiosteal infection. It is more common in young individuals with extensive, pneumatized, and vascular diploe, increasing the risk of infection.¹⁶⁵ A softened, floating tumor may be observed, without signs of inflammation, called Pott's tumor.¹¹⁸ It corresponds to a subperiosteal abscess of the frontal bone associated with underlying osteomyelitis.^{117,166} Radiographically, it has three phases: 1) condensation with bone sequestration; 2) rarefaction, when there is bone necrosis; and 3) decalcification or absence of bone tissue in irregular areas, interspersed with islands of calcification and areas of bone sequestration. A CT scan confirms the diagnosis. Scintigraphy with technetium 99 for diagnosis and with gallium 67 for the follow-up is useful, but not essential.¹⁶⁵ Treatment consists in the administration of clindamycin and abscess drainage through coronal access, with reconstruction.

Osteomyelitis of the maxillary sinus is often a complication of odontogenic infection, more common in infants.

Atypical rhinosinusitis complications

The literature contains case reports with unusual complications, such as lacrimal gland abscess,¹⁶⁷⁻¹⁶⁹ orbital hematoma,¹⁴⁷ nasal septal abscess,¹⁷⁰ nasal septal perforation,¹⁷¹ frontocutaneous fistula,¹⁷² clival osteomyelitis with paralysis of the VI nerve,¹⁷³ acute ischemic stroke,¹⁷⁴ and septicemia.¹⁷⁵ Cases of children with orbital sequelae after cochlear implant surgery^{176,177} have also been observed. In one study, 14% of patients showed evidence of RS. The

most likely hypotheses were: the patient's position during surgery, duration of surgery, or minor trauma to the lamina papyracea during perforation of the mastoid.¹⁷⁷

Chronic rhinosinusitis

Definition and epidemiology

CRS is an inflammatory disease of the sinonasal mucosa that persists for at least 12 weeks. In specific cases, exclusive sinus involvement can be observed, as in odontogenic sinusitis or fungal ball.

CRS can phenotypically be divided further into two main entities: CRS without nasal polyps (CRSsNP) and CRS with nasal polyposis (CRSwNP). Currently, there is evidence to suggest that these two entities have distinct physiopathogenic mechanisms.

CRS is a common disease in the population, and studies about its epidemiological data are important to evaluate its distribution, analyze its risk factors, and promote public health policies. However, such data are scarce in the literature. Additionally, data comparison is hindered by the different definitions and methodologies used in the studies.

This disease has a high direct cost for public health, which includes medical visits, supplementary and radiological exams, hospitalization, surgery, and drug treatment, as well as indirect costs, such as decreased work productivity and absenteeism.¹⁷⁸⁻¹⁸¹ In the United States, the estimated expenditure on these patients is US\$ 8.6 billion per year,¹⁸² of which US\$ 150 million are related to antibiotic use.¹⁸³ Additionally, overall quality of life and disease-specific questionnaires show great impact of CRS on patients' quality of life.¹⁸⁴⁻¹⁸⁷

In 2007, the European Position Paper on Rhinosinusitis and Nasal Polyps (EPOS)¹⁸⁸ was published, and a CRS definition was introduced for epidemiological purposes, characterized by the presence of two or more of these symptoms for more than 12 weeks, a) nasal obstruction/congestion; b) rhinorrhea (anterior or posterior); c) facial pain/pressure; d) reduction or loss of olfaction. One of the two symptoms had to be either a) or b) above. Supplementary examinations, such as nasal endoscopy or imaging studies were not required for diagnosis.

The annual study by the National Center for Health Statistics (NCHS) of the United States population by means of household surveys observed a prevalence of self-reported medical diagnosis of sinusitis of 13% of the adult population in 2010 and a response rate of 60.8%. However, there was no distinction between ARS and CRS in this study, as the criteria that defined CRS in this questionnaire was an affirmative answer to the question: "In the last 12 months, have you had sinusitis diagnosed by a physician or healthcare professional?"¹⁸⁹ However, this prevalence is used in most published studies that refer to CRS.

In Canada, an epidemiological study of complex sampling design, with a national response rate of 82%, was performed through telephone interviews with individuals aged 12 years and older, with symptoms of chronic diseases for more than six months.¹⁹⁰ Individuals were considered as having CRS when the following question was answered affirmatively: "Do you have sinusitis diagnosed by a healthcare professional?" In that study, the prevalence of self-reported RS was 5%.¹⁹⁰

In South Korea, a nationwide study was performed through complex cluster and multistage sampling. A medical team that included an otorhinolaryngologist visited households and performed interviews with participants aged 12 years or older. The diagnosis of CRS was defined by a positive response to symptoms of nasal obstruction and rhinorrhea for more than three months and an endoscopic examination with findings of polyps or secretion in the middle meatus. The estimated CRS prevalence in South Korea was 6.95%.¹⁹¹

Hastan et al.¹⁹² published part of the results of the Global Allergy and Asthma Network of Excellence (GA2LEN) European multicenter study related to the investigation of CRS epidemiology. A questionnaire was mailed to a randomized sample of adults between 15 and 75 years in 19 centers in Europe, covering 12 countries, using as a diagnostic criterion the epidemiological definition published in EP3OS 2007 (The European Position Paper on Rhinosinusitis and Nasal Polyps)¹⁸⁸ The estimated prevalence of CRS in Europe was 10.9% (6.9% to 27.1%), but the overall response rate was 48%, with wide variation between centers (23.2% to 80.3%).²¹³ Tomassen et al.¹⁹³ reported the consistency and validity of the epidemiological criterion of CRS defined by EP3OS 2007m¹⁸⁸ using data from the GA2LEN study.

Pilan et al.,¹⁹⁴ in a recent study in the city of São Paulo, Brazil, with complex sampling design incorporating stratification and multiple selection stages to obtain a representative sample of the population, used the epidemiological definition of CRS recommended by EP3OS 2007.¹⁸⁸ The questionnaire involving this definition was applied in 2006, through household interviews, to individuals aged 12 years or older, and a prevalence of CRS of 5.51% and high response rate of 87.8% was observed.¹⁹⁴ No statistically significant difference was found in prevalence by gender. In that study, there was a higher prevalence of CRS in patients who had asthma and rhinitis. However, there was no significant association with smoking. For the purpose of comparison with the methodology used in the study by Pleis et al.,¹⁸⁹ the same question was inserted: "In the last 12 months, have you had sinusitis diagnosed by a physician?" The self-reported prevalence of RS diagnosed by a physician (with no distinction between acute and chronic) was 16.55%.

Physiopathogenesis

Microbiology

In contrast to the etiopathogenesis of ABRS, which involves a continuum of changes promoted by a viral infection followed by bacterial superinfection, the role of microbial agents in the pathogenesis of CRS is not yet fully elucidated.

No microbial agent alone is capable of creating the diversity and heterogeneity of the physiopathogenic processes involved in CRS; therefore, a microbial theory is not always applicable to all patients. Great advances have been made in the last decade, with studies that have explored new interactions between the host and the environment in the genesis of chronic inflammation, opening perspectives for new therapies.

Viral participation

Currently, there is little research regarding viral involvement in the physiopathogenesis of CRS. Despite the high frequency of acute infections of the upper airways, it is not very clear yet whether viruses act as a source of chronic stimulation or trigger the initial inflammatory process. As they have the capacity to incorporate into the host DNA as the episomal form, the virus may persist chronically in the respiratory mucosa. Recent studies of viral genomic detection have demonstrated from none¹⁹⁵ to significant rates of the main respiratory viruses, especially rhinovirus¹⁹⁶ and metapneumovirus.¹⁹⁷ However, there is still no evidence whether these viruses are involved in a latent infection without cytopathic effects for the host, or whether they are active, producing antigens and replicating.

Fungal participation

Among the different classifications of sinonasal chronic inflammatory processes involving a fungal etiology, it is indisputable that, in some conditions, such as fungal ball and the invasive chronic forms, the role of fungi is essential.^{198,199} However, the participation of fungi in the forms of idiopathic CRS, those without apparent cause, is still a subject of much controversy.

The theory of a fungal etiology for CRS²⁰⁰ was heightened by the correlation of the high incidence of the detection of fungi in CRS patients, associated with a high number of eosinophils in tissue and secretions. Several *in vitro* studies have demonstrated that stimulation of lymphocytes by fungal antigens could produce increased amounts of IL-5, IL-13, and IFN-gamma²⁰¹ and stimulate eosinophil degranulation.^{202,203} However, other investigators failed to reproduce such findings or even found divergent results.²⁰⁴⁻²⁰⁶

The attempt to prove the fungal theory through clinical trials with topical and systemic antifungals did not produce encouraging results. Controlled studies have failed to demonstrate the efficacy of oral²⁰⁷ and topical antifungals for the treatment of CRS.²⁰⁸⁻²¹³

The fact that the ubiquity of fungal elements could act as a constant stimulator of innate immunity receptors and, in turn, could lead to stimulation of specific inflammatory responses cannot be ignored.^{214,215} In light of the present evidence, fungi appear to have universal participation in CRS, and play a modulatory role in some patients.²¹⁶

Bacterial participation

Studies involving conventional bacterial growth and identification techniques have been widely performed in patients with CRS. Most Brazilian^{217,218} and international studies²¹⁹⁻²²² observed a higher prevalence of *S. aureus*, Gram-negative, and anaerobic bacteria in patients compared to controls, or even those with ARS. However, the identification of bacteria by the traditional method, through *in vitro* culture, has some sensitivity and specificity limitations. In general, the conventional method only shows positivity for dominant microorganisms or those with favorable growth on that medium, representing only the collection site (middle meatus, nasal cavity, and paranasal sinus) with a risk of contamination from other regions (such as the nasopharynx and the

nasal vestibule), or does not allow the differentiation of colonizing microbes from pathogenic microorganisms (for instance, *S. epidermidis*).

In order to overcome such limitations of flora interpretation in individuals with CRS, more sensitive and specific techniques have been used for the characterization of nasal flora in healthy individuals and those with CRS. Recent studies using molecular techniques have shown high prevalence of bacteria, with a predominance of *S. aureus*, *P. aeruginosa*, and anaerobic bacteria, characteristically polymicrobial.²²³⁻²²⁵ These studies have demonstrated that individuals with CRS have the same bacterial load as their healthy peers, but with lower flora diversity, indicating a possible microbiota disorder.²²⁶ Broader studies including the analysis of the human microbiome are still necessary to assess the importance of the quantity and biodiversity of these bacteria in patients and healthy individuals, considering that the genetic, geographic, and environmental characteristics may influence the microbiota in different health scenarios.

Based on conventional microbiology and some molecular studies, it was observed that *S. aureus* is the main bacterial agent found in Western patients with CRS, both in pre- and postoperative conditions,²²⁷ with a lower prevalence in the Chinese population;²²⁸ it is more frequently identified in patients with extensive sinonasal polyps than in controls or even individuals with CRSsNP.²²⁹

A peculiar characteristic of *S. aureus* is its capacity to produce exotoxins with superantigen properties. There is evidence that staphylococcal superantigens may play a role in the physiopathogenesis of CRS, especially in CRSwNP, with induction of specific polyclonal IgE and mast cell stimulation;²³⁰ increases in IL-4, IL-5, eosinophils, and eosinophil cationic protein;²³¹⁻²³⁴ and association with severe asthma.^{230,235-238} However, the mere presence of enterotoxin-producing *S. aureus* in the nasal cavity is not sufficient to produce a chronic inflammatory reaction and polyp formation.²³⁹ It is believed that the primary action of superantigens is to modulate inflammation in the upper airways, depending on the distinct reactions of each individual.²⁴⁰

Another bacterial form, which has been demonstrated in CRS, is bacterial biofilms. Despite the great variability in the prevalence of biofilms in different studies, probably due to the different techniques used, it is estimated that at least 25% of cases are associated with their presence.^{241,242}

In general, patients with CRS have significantly higher rates of biofilm when compared to healthy individuals. However, similar to planktonic bacteria, it is unclear what the real role of biofilms is in the physiopathogenesis of CRS and it is not possible to determine whether the colonization of biofilms would be the cause or the consequence of chronic inflammation.²⁴³

In addition to the possible involvement of multiple species of bacteria in biofilms, simultaneous fungal and bacterial colonization has also been observed.²⁴⁴

The presence of certain bacterial species in biofilms can diversely influence the outcome of patients undergoing surgical treatment. *S. aureus* and *P. aeruginosa* are associated with worse postoperative outcome or a greater number of revision surgeries.²⁴⁵⁻²⁴⁹ Moreover, patients with biofilms that include *H. influenzae* or *S. epidermidis* have better postoperative prognoses.²⁴⁷

In terms of pathogenic mechanisms, two independent studies, using different detection methods for different populations, showed opposite results on polarization of the inflammatory response, whether to Th1 (neutrophils, IFN- γ , interferon- γ , macrophage inflammatory protein-1 [MIP-1], granulocyte colony stimulator factor [G-CSF])²⁵⁰ or Th2 (IL-4, IL-5, eosinophil cationic protein [ECP])²⁵¹ in patients with biofilm. Recent studies have shown that the presence of biofilm is associated with increased positivity of tumor necrosis factor (TNF) receptor expression types I and II and increased plasma cells and eosinophilic markers, both in CRSwNP and CRSsNP.²⁵²

In CRSwNP, the presence of biofilms modifies the pattern of antigen-presenting cells in the subepithelial layer, with a possible change in the stimulatory mode of adaptive responses and consequent production of specific inflammatory mediators.²⁵³ Finally, the presence of bacterial biofilms in CRS is associated with increased expression of toll-like receptor-4 (TLR-2) and nuclear factor κ B (NF- κ B), but not TLR-4, possibly with activation of innate immunity in different ways than in CRS without biofilm.²⁵⁴

In addition to the bacterial forms that colonize the surface of the sinonasal mucosa, viable intracellular bacteria have also been identified in the respiratory mucosa of patients with CRS, especially *S. aureus*.^{255,256}

The presence of viable intracellular bacteria could justify another form of bacterial persistence in the respiratory mucosa, especially in chronic and recurrent disease. Although the mechanisms that lead to the internalization and intracellular survival of *S. aureus* are not known, curiously the intracellular niche of microcolonization is associated with lower adjacent inflammatory triggering, with reduced recruitment of surrounding T lymphocytes and eosinophils.²⁵⁷ Also, Tan et al.²⁵⁸ demonstrated a significant correlation between the intracellular presence of *S. aureus* with bacterial biofilms on the mucosal surface of individuals with CRS, reporting that both the intracellular persistence and the adhesion of bacterial forms on the surface can contribute to the maintenance of the chronic inflammatory process. Another relevant fact is that the type of strain of *S. aureus* can also determine the impact on the host. Thus, the capacity to form biofilms on the surface, internalization in specific cells, and the production of certain pro- and anti-inflammatory cytokines also depend on the morphological and functional characteristics of the bacteria.²⁵⁹

The great diversity of sinonasal microbiota, either as planktonic bacteria, biofilm, or intracellular forms, as well as the numerous possibilities of interaction with mechanisms of innate and adaptive immunity of the host, probably acts as an important factor of tissue inflammation in CRS, either as a triggering or modulating factor or even as a factor that maintains chronic sinonasal inflammation.

Inflammatory mechanisms

Although similar in their symptoms, CRSsNP and CRSwNP are different at molecular and cellular level. There is growing scientific evidence that the phenotypic differentiation of CRS is insufficient, making it necessary to differentiate between the different types of CRS based on the disease endotype, i.e., the cellular and molecular markers.²⁶⁰ That

would be useful not only to better predict patient prognosis but also to develop new therapies, prescribed according to the CRS endotype.

Histologically, CRSsNP is characterized by neutrophil infiltration, increased fibrosis, and collagen deposition in the stroma. The basement membrane is slightly thickened and there are no pseudocyst deposits.²⁶¹ CRSwNP is characterized by extensive leukocyte infiltration (eosinophilic in 80% of cases) with the overt presence of pseudocysts with albumin accumulation and edema, associated with decreased collagen in the stroma; the basement membrane is thickened and there are significant histological alterations in the epithelium.²⁶¹

The most recent theories suggest that there is a disorder in the interaction between innate and adaptive immunity in both cases. Adaptive immunity is phylogenetically more recent, coordinated mainly by lymphocytes. This system depends on the individual's prior exposure to this antigen.¹

Innate immunity is phylogenetically older and immediately recognizes (without prior exposure) that which does not belong to the body. For example, after one exposure to a single-stranded DNA virus that is not characteristically present in human beings, innate immunity is immediately activated. This system was formerly believed to be extremely rudimentary, but it is now known that it is extremely complex and dynamically interacts with adaptive immunity.

Thus, in simplistic terms, it has been suggested that CRS follows irreparable damage to the epithelium and activation of innate immunity. The latter is ultimately responsible for the activation of the individual's adaptive immunity.²⁶² In this sense, the main cell that initiates this process is the epithelial cell.

The nasal epithelium is important, not only as a mechanical barrier against different pathogens and stimuli, but also as an active participant in the innate and adaptive immune processes.^{263,264} In ideal conditions, the epithelium is able to destroy these particles without activating the adaptive system.²⁶⁵ Therefore, an epithelial lesion is essential for the chronic inflammatory process.

In such an epithelial lesion, the pathogen-associated molecular patterns (PAMPs) bind to pattern recognition receptors (PRRs) present in the cell membrane and cytoplasm of epithelial cells. These PRRs are activated by the presence of pathogens, antigens, and necrotic cells, among other inciters. The best-known PRRs are currently the toll-like receptor (TLR) and NOD-LR-nucleotide-binding and oligomerization domain-like receptors (NLR). TLRs are the most often studied in the nasal epithelium. There are over ten known TLRs, and each is specific for a pathogen. As an example, while TLR-2 binds to Gram-positive bacteria and some fungi, TLR-3 predominantly binds to viruses, and TLR4 to Gram-negative bacteria.

Once bound to PAMPs, TLRs induce the secretion of proteins in nasal mucus (such as lysozymes and lactoferrins),²⁶⁰ cytokines, and chemokines.²⁶⁶ Cytokines are molecules that promote the inflammatory pattern; chemokines are responsible for the recruitment of inflammatory cells toward the injured tissue.

Some studies have reported a decreased secretion of these defense molecules against pathogens (defensin, lysozyme, lactoferrin, S100A7)²⁶⁶⁻²⁶⁸ in patients with CRS, which impairs the immune function of the epithelial barrier.

Additionally, the expression of tight junctions (TJs) is also decreased in nasal polyps.²⁶⁹ The TJs are molecules that bind epithelial cells to each other, control epithelial permeability for the influx of substances or inflammatory cell permeability, and prevent the entrance of external particles.²⁶⁰ The decrease in expression of these molecules demonstrates epithelial fragility, specifically that of nasal polyps. Both gamma-interferon (IFN- γ , typical Th-1 cytokine) and interleukin-4 (IL-4, typical Th-2 cytokine) can increase epithelial permeability by decreasing TJs.²⁷⁰

There have been reports of changes in the expression of TLRs; while CRSsNP shows increased expression of TLR-2 and TLR-4, nasal polyps have reduced expression of TLR-2 and TLR-9.^{263,271-273} These changes were especially observed in patients with early recurrence of CRSwNP,²⁷² suggesting the importance of innate immunity in CRS pathogenesis.

Once bound to the specific particle, the TLR activates its inflammatory cascade. Essentially, this cascade occurs through its canonical pathway (via myeloid differentiation primary response-88 [MyD88]) or an alternative pathway (via TIR domain containing adapter inducing interferon- β [TRIF]). Both pathways activate transcription factors, molecules that have the capacity to enter the cell nucleus and bind directly to DNA, inducing or repressing gene transcription of some molecules, especially cytokines, chemokines and adhesion molecules. The difference between the two pathways is that the alternative pathway induces the production of IFNs, which triggers the Th-1 adaptive inflammatory response.²⁷⁴⁻²⁷⁶ The MyD88 pathway triggers the transcription factors nuclear factor κ B (NF- κ B),^{274,277} mitogen-activated protein kinase (MAPK), and signal transducer and activator of transcription-3 (STAT-3),²⁶⁰ which amplify the adaptive immune response in some cases with a predominantly Th1 pattern and in other Th2.

In fact, NF- κ B is a transcription factor that has an increased expression in patients with CRSwNP.^{278,279} This factor is especially important, not only for its extensive pro-inflammatory effect, inducing the production of several cytokines such as IL-1 β , TNF- α , IFN- γ , eotaxin, (intercellular adhesion molecule 1 (ICAM-1), and vascular cell adhesion molecule 1 (VCAM-1),^{278,280} but also because it can directly inhibit the action of corticosteroids in the cell by preventing the binding of its receptor (glucocorticoid receptor [GR]) to the cell's DNA.^{278,280} A prospective study²⁸¹ demonstrated that overexpression of NF- κ B was related to an earlier relapse CRSwNP. The epithelial cells themselves direct the inflammatory response pattern: examples are IL-33, IL-25, and thymic stromal lymphoprotein (TSLP) cytokines, which induce the polarization of dendritic cells and T-cells to Th2 pattern and, hence, tissue eosinophilia.^{263,266,282,283} The expression of IL-33 that is increased in CRS, has a direct association with the degree of tissue eosinophilia,²⁸² and is present to a greater degree in cases that do not respond to treatment.²⁸⁴ IL-25 and TSLP induce Th2 lymphocyte expansion, regardless of the adaptive response.^{285,286} TSLP is particularly important for the interface between epithelial and dendritic cells,²⁸² activating them and finally polarizing T cells to Th2 pattern. IL-6 is an essential cytokine for the transition between this phase and the activation of adaptive immunity²⁶⁶ (Fig. 3).

Several cells from the nasal mucosa produce chemokines to attract inflammatory cells and adhesion molecules that facilitate the vascular permeability for the influx of these cells. Together, they increase the influx of inflammatory cells to the site. Examples of chemokines are RANTES (regulated on activation normal T cell expressed and secreted) and eotaxins, which especially recruit eosinophils and are increased in CRSwNP,^{264,278,287-289} while IL-8 recruits neutrophils and is specifically increased in CRS, with or without NPs.²⁹⁰ With respect to the adhesion molecules ICAM-1

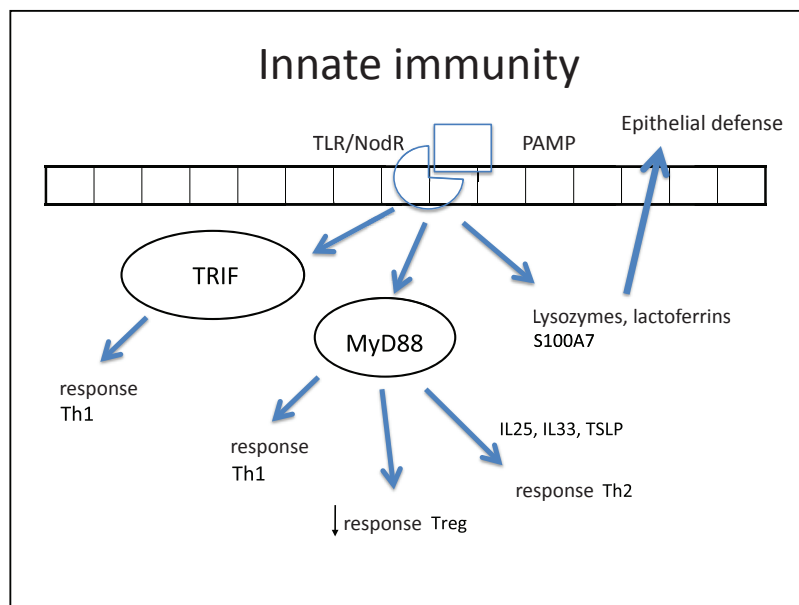


Figure 3 Figure illustrating the participation of innate immunity in the pathogenesis of chronic rhinosinusitis (CRS): once the toll-like (TLR) or nod-like (NLR) receptors bind to pathogen-associated molecular pattern (PAMP), the production of Th1 and Th2 cytokines is stimulated, in addition to the decrease in Treg cytokines through two pathways: myeloid differentiation primary response-88 (MyD88) and TIR domain containing adapter inducing interferon- β (TRIF). Furthermore, lactoferrins and lysozymes are produced.

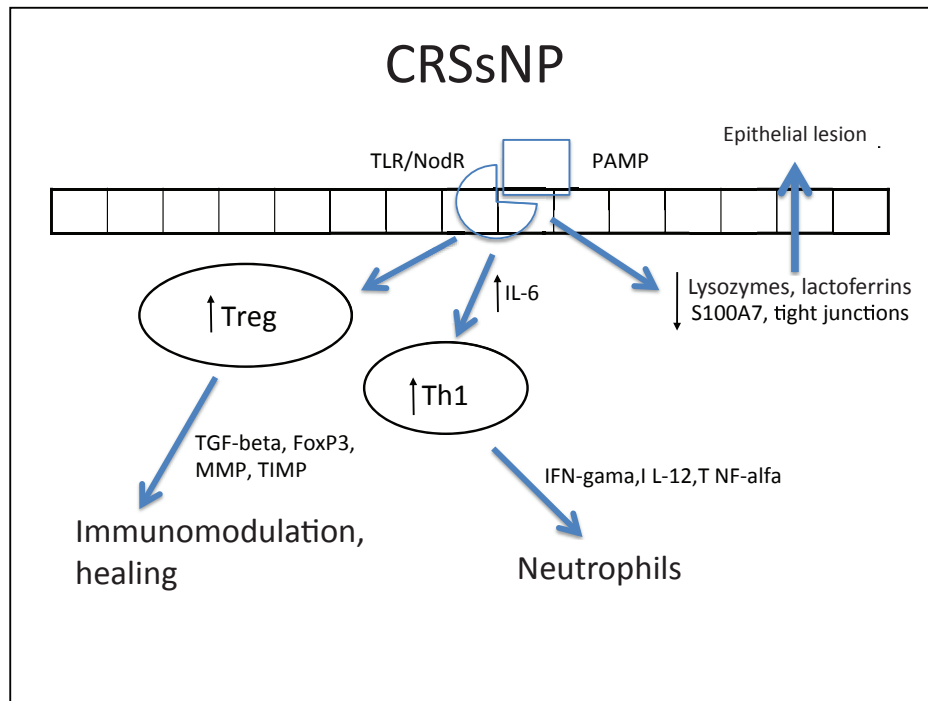


Figure 4 Specific response to chronic rhinosinusitis without nasal polyps (CRSsNP). After stimulation of innate immunity in the presence of high concentrations of IL-6, there is a polarized adaptive response to Th1, with associated increase in Treg. That results in neutrophil response and a modulated inflammatory process.

and VCAM-1, results are controversial in the literature, with some studies showing no increase in ICAM-1 expression.²⁸⁸ However, this expression was related to a poorer response to corticosteroids in patients with CRSwNP.²⁹¹ In cases with CRSsNP, the inflammatory pattern is almost exclusively neutrophilic, mediated by Th1²⁶³ with increased IFN- γ , IL-12, and TNF- α ^{283,292} (Fig. 4).

In CRSwNP, there is a predominantly mixed Th1/Th2 inflammatory pattern^{287,290} in European and American populations, but with a clear Th2 predominance, significant increase in expression of IL-5, in addition to other cytokines, such as IL-4 and IL-13 and GATA-3 transcription factor.^{1,4,282,283,289,292} IL-5 has particular importance in CRSwNP, as it is primarily produced by eosinophils and its main function is to induce tissue eosinophilia by increasing the influx of these cells and reducing their apoptosis.^{283,287,290,293} Moreover, IL-5 is associated with increased risk of asthma and other comorbidities,²⁹³ as well as a worse postoperative prognosis.²⁹³ Eosinophils induce tissue damage, edema, and intense vasodilation by producing proteins such as ECP (eosinophil cationic protein)^{283,290,292,294,295} and LTs (leukotrienes),²⁹⁶ in addition to producing collagen and thickening the basal membrane in tissue.²⁹⁷ This inflammatory pattern is notably found in patients who have acetylsalicylic acid-exacerbated respiratory disease (AERD, an association of CRSwNP, asthma, and acetylsalicylic acid intolerance).²⁶³

In contrast, in patients with cystic fibrosis (CF) and those of Chinese origin, nasal polyps are predominantly neutrophilic,^{263,292} with intense infiltration of IL-8, IFN- γ , myeloperoxidase (MPO), and IL-1B. In the specific case of CRSwNP in Chinese subjects, there is a significant involvement of Th1/Th17 mixed response, with marked increase in the expression of IL-17 by the tissue.^{260,282,283,292,298}

IL-1B expression is increased in polyps, both eosinophilic and neutrophilic. Although it is less significant in the differentiation between Th1 and Th2 patterns, this cytokine is an important pro-inflammatory molecule and its expression is associated with a poorer response to treatment with topical corticosteroids²⁹¹ and a worse postoperative prognosis.²⁹³

In spite of the difference between inflammatory patterns of nasal polyps in Europeans/Americans and Chinese individuals, all share the Treg deficiency.^{282,298} This is another pattern of T cell response, whose function is to inhibit and contain the inflammatory process. The expression of Fox-P3, a transcription factor that is the main marker of Treg response, is reduced in CRSwNP.^{282,298,299} Unlike what is observed in CRSsNP, in which the expression of Fox-P3 and TGF-B (transforming growth factor B) was preserved,²⁹² the expression of both of these molecules is reduced in CRSwNP.^{282,292,298,299} It is currently believed that this is the main difference between the two diseases, as while in CRSsNP the inflammatory pattern is more localized and contained through the maintenance of Treg function, in CRSwNP the inflammatory pattern is diffuse and exacerbated.^{261,292}

In addition to its extremely important role in the containment of the inflammatory process, TGF-B is one of the main inducers of remodeling, a phase during which tissue recently injured by inflammation is regenerated.^{260,261} While TGF-B is increased in CRSsNP, it is quite decreased in CRSwNP.^{260,261,283,287,289,290,300,301} TGF-B is essential for the balance between the expression of matrix metalloproteinases (MMPs),^{1,282,292} whose essential function is to degrade the extracellular matrix of the polyp stroma (thus contributing to edema) and of its inhibitor (tissue inhibitor of metalloproteinases [TIMP]). MMPs are increased in nasal samples from patients with CRSwNP and CRSsNP.^{260,261,287,292,297,302,303}

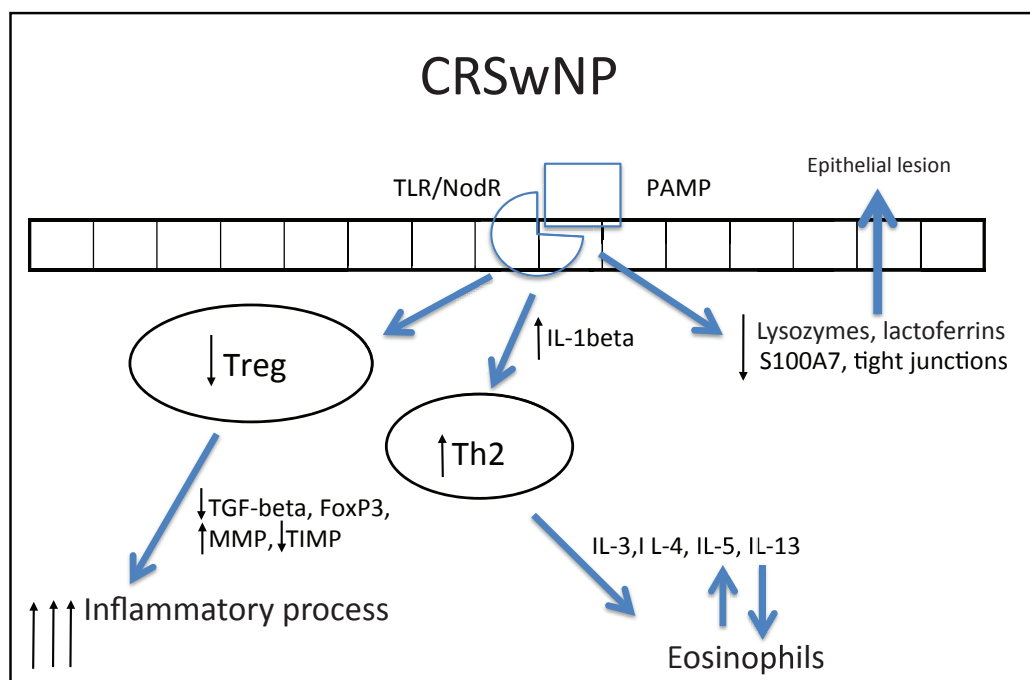


Figure 5 Specific response to chronic rhinosinusitis with nasal polyps (CRSwNP). After stimulation of innate immunity, polarized adaptive response to Th2 occurs and Treg response decreases. As a result, the response is primarily eosinophilic and exacerbated, resulting in edema.

facilitating the influx of inflammatory cells. TGF- β , Fox-P3, and TIMPs are increased in CRSsNP but decreased in CRSwNP, which could explain the difference in the extent of inflammatory disease.^{260,261,292,302,303} The expression of MMP-9 is also related to the recurrence of CRSwNP; therefore, patients with higher expression have a worse prognosis.^{261,292,303}

Despite the advances, there are more endotypes yet to be identified for a full understanding of the pathogenesis of CRS. This knowledge is essential to define the subgroups that are more likely to benefit from one therapy or another. For example, in patients with CRSwNP mepolizumab (anti-IL-5), would be more appropriate for use in patients with increased IL-5 and macrolides for patients without marked eosinophilia.²⁶⁰ The endotyping study of CRS is essential for the development of new, more effective therapies.

Genetics in chronic rhinosinusitis

Genomics analyzes the alterations in DNA sequence (genetic polymorphisms) in two ways: studies based on hypotheses and studies free from hypotheses.^{1,304,305} Most of the published articles addressing CRS are studies based on hypotheses (or candidate gene) that investigate mechanisms or pathways already known to be altered in the disease. A few polymorphisms are analyzed at a time and the cost of research is relatively low.^{304,306} The more well-known studies free from hypotheses are linkage studies and genome-wide association studies (GWAS).^{304,306-309} GWAS use expensive high-density chips, and can evaluate over one million polymorphisms simultaneously. One way to decrease the costs of that type of evaluation (but not without loss of genetic information) is to perform pools of DNA from cases and controls using just one chip for each group, a strategy known as pooling-based GWAS (pGWAS).^{304,306-309}

Evidence from genetic research in chronic rhinosinusitis

Genetic basis for chronic RS

The initial idea of a genetic basis for the existence of CRS came from the existence of familial aggregation. A study of the descendants of two brothers, one with and one without CRS, showed a higher prevalence of CRS in the first group.³¹⁰ Other studies have also shown familial aggregation,³¹¹⁻³¹⁴ with concordance between family prevalence and disease severity,³¹¹ increased chance of positive CRS family history among patients with CRS,³¹⁴ and a report of monozygotic twins with CRSwNP, even though they lived in different regions.³¹⁵

HLA system genes

Mutations in the human leukocyte antigen (HLA) genes are strongly associated with inflammatory diseases, but the association with CRS is not fully understood.^{1,304} Alterations were identified in the frequencies of several HLA alleles.³¹⁶⁻³²⁰ A study of Mexican mixed-race individuals with CRSwNP associated the HLA-DRB1*04 allele to the disease,³¹⁹ but this was not observed in a Turkish population with CRSwNP, except for CRSwNP with asthma or AERD.³¹⁸ These findings show that this allele may be associated with different CRS phenotypes in different populations.

CFTR gene

It is located on chromosome 7q and its mutations are the cause of CF. It is the gene most often related to CRS. There is a correlation between homozygosity of the $\Delta F508$ mutation and the presence of polyps in CF in the Brazilian pop-

ulation.³²¹ The presence of CF mutations (even without CF) is a risk factor for CRS,³²²⁻³²⁴ and patients with CRS without CF are more likely to carry mutations in the CFTR gene than controls; the $\Delta F508$ are those most frequently identified, followed by M470V mutations.³²⁵

Innate immunity genes

Candidate gene studies with TLR-2 polymorphisms did not find any association between CRSwNP and TLR2 R753Q rs5743708 polymorphism;^{326,327} however, there is an association with TLR2 polymorphisms rs3804099 and rs380410048. The polymorphism of the gene for the bitter taste receptor TAS2R38 appears to influence the ability of cells to fight respiratory infections and may be an unknown component of the innate immune response, acting as a sentinel for infections by *Pseudomonas aeruginosa*.³²⁸ CD14 is a component of innate immunity, whose C-159T polymorphism in its gene was associated with CRSwNP.³²⁹ Nitric oxide (NO) is a molecule whose function is the defense against bacterial biofilms produced by NO synthase (NOS). Sixteen polymorphisms in the NOS1 gene and its ligand were assessed, and the polymorphisms rs1483757 and rs9658281 may exert a protective effect against CRS.³³⁰ The microsatellite polymorphism CCTTT in the NOS2A gene was associated with CRSwNP when it presented 15 or more repetitions.³³¹

Other genes involving inflammation, remodeling, and metabolism

The T allele of the polymorphism C-590T of IL-4, an important Th2 IL, appears to exert a protective effect against CRSwNP, but the same allele increases the expression of IL-4, instead of decreasing it.³³² The G allele of G-174c polymorphism of IL-6 was associated with asthma and CRSwNP.^{333,334} The AA genotype of polymorphism A-1510C and the CC genotype of the C-1055T were associated with CRS in patients with asthma and acetylsalicylic acid intolerance.³³⁵ IL-33, another IL associated with Th2 response, was also associated with CRSwNP, through its A allele of polymorphism rs3939286.³³⁶

The C-1562T polymorphism in the MMP-9 gene appears to be associated with CRSwNP,³³⁷ although another study only observed an association in CRSwNP with asthma and acetylsalicylic acid intolerance.³³⁸ The T allele of the polymorphism of the TGF- β gene C-509T was associated with CRS in acetylsalicylic acid-intolerant asthmatics and was related to lower levels of protein.³³⁹ Furthermore, there is a genetic association between polymorphisms TGF- β C-509T and IL-10 A-1082G; mutated alleles are more associated with CRS.³⁴⁰

The leukotriene C4 synthase enzyme is critical for the regulation of cysteinyl-leukotriene synthesis, which is increased in CRSwNP mainly in AERD, and the C allele of rs730012 polymorphism of its gene was more associated with CRSwNP.^{341,342}

Studies free of hypotheses

The binding study on CRS confirms the role of the CFTR gene in CRS. The highest binding peak was found in the connecting region 7q31.1 to 7q32.1, where the CFTR gene is located.³⁰⁷ However, genotyping of 38 mutations of this gene did not reveal which was responsible for this signal.³⁰⁷ Probably, this failure is due to the large number of different mutations in this gene that are not covered by the usual tests.

The first pGWAS study used one chip for over 550,000 genetic polymorphisms, and observed associations with several genes not previously linked with CRS, such as ba-

sal membrane and extracellular matrix genes (for instance, laminin- $\alpha 2$ [LAMA2] and laminin-B1 [LAMB-1]) genes of mitochondrial function (for instance, prolyl-tRNA synthetase [PARS2]), and genes for the degradation of lipopolysaccharides (for instance, acyloxyacyl hydrolase [AOAH]).³⁰⁸ The association with AOAH was confirmed in a replication study for CRSsNP, but not for CRSwNP.³⁴³

The second pGWAS study was a secondary analysis of the data according to disease severity. In this analysis, there was an association of the G allele of TP73 gene polymorphism (rs3765731) with risk of more severe CRS.³⁰⁹ All these new findings implicated in pGWAS studies require replication and functional validation of polymorphisms.

Final considerations

Some points should be considered for future genetic studies of CRS. Firstly, adequate phenotyping is important in order to prevent mixing different physiopathological mechanisms. Another focus should include replication of results. Moreover, gene-environment interactions should be analyzed; tobacco and pollution are two environmental factors that deserve consideration. GWAS need to be further explored in the research of CRS, as well as other techniques, such as epigenomics and the complete sequencing of genomes and exomes. Finally, it is necessary to develop functional studies. Only then it will be possible to infer that a certain genetic alteration actually interferes with or causes the disease.

Clinical diagnosis

Several clinical tests have been developed for the clinical diagnosis of CRS, but in most patients diagnosis is based only on the presence of sinonasal signs and symptoms with over 12 weeks of evolution.^{1,188,344,345} Sinonasal endoscopy and CT are complementary examinations and help in disease classification. In both CRSwNP and CRSsNP, the main symptoms are:

Nasal obstruction^{344,345}

An extremely subjective symptom, it is one of the most frequent complaints in clinical practice, affecting approximately 83.7% of patients;¹⁹² it is more important in patients with sinonasal polyposis. It is caused by congestion of sinusoidal vessels, resulting in local edema, followed by tissue fibrosis and, ultimately, only improves with the use of vasoconstrictors. Despite being a subjective symptom, several articles in the literature validated nasal obstruction as an important symptom of CRS³⁴⁶ using acoustic rhinometry and peak nasal inspiratory flow.

Rhinorrhea

It can be anterior or posterior, secretions can vary from hyaline to mucopurulent, and is present in 63.6% of patients with CRS. It can also be associated with cacosmia, cough, and hoarseness. It is a symptom of difficult validation or quantification.¹⁹²

Olfaction alterations

Hyposmia or even anosmia is common, especially in CRSwNP and is present in up to 46% of patients.^{192,345} It can be caused by an obstructive process (polyps), edema, and/or mucosal degeneration, or be caused by local surgical interventions and can result from a chronic inflammatory process with or without the

presence of nasal polyps^{1,188,347} There are several studies in the literature that clearly and reproducibly demonstrate alterations of olfaction in patients with CRS.^{1,66}

Facial pain or pressure

A symptom with variable prevalence (18% to 80%).¹ It is more frequently associated with CRSwNP, patients who have difficult-to-control allergic rhinitis, or during the flare-up processes.¹ The rhinogenic headache is a diagnosis of exclusion, according to the International Headache Society (IHS).¹

Cough

In childhood, cough is a frequent symptom; it is usually non-productive and may be the only manifestation of CRS. In addition to the usual symptoms, complaints such as hoarseness, pharyngeal-laryngeal irritation, dysphonia, halitosis, ear fullness, adynamia, and sleep disorders should be questioned.^{1,188,344,345} During anamnesis, it is important, in addition to the abovementioned classic symptoms, to include questions about systemic diseases and predisposing factors that may favor the development of CRS. Personal habits such as smoking, cocaine use, exposure to toxic inhalants, type of climate in the region where the patient resides, and environmental pollution should be investigated.

Physical examination

Anterior rhinoscopy (with and without vasoconstrictor) is of limited value, except in cases of polyposis, when it can be visualized by simple inspection of the nasal vestibule. Nonetheless, it is important to describe signs such as hypertrophic inferior and middle turbinates, septal deviations, or mucosal degeneration. It is noteworthy that there are no pathognomonic signs of CRS.^{1,344}

Oropharyngoscopy

Regardless of the color, the presence of retropalatal mucopurulent secretion justifies the symptom of postnasal discharge.^{1,344,345}

Complementary examinations

Nasal endoscopy

Nasal endoscopy enables the systematic visualization of the nasal cavity (lower, middle, and upper turbinate), the nasal septum, and the nasopharynx and drainage pathways; it can be performed with or without topical nasal decongestant. The presence of polyps, mucosal degeneration, secretion, crusts, structural alterations, scars and nasal tumors can also be observed. It can be performed at baseline and at regular intervals (e.g., three, six, nine, and 12 months) to aid diagnosis, to supervise disease follow-up and postoperative period, as well as to collect material for supplementary tests.^{348,349}

It is important to perform a systematic assessment of the nasal cavities, such as analysis of the nasal septum, turbinates, and visualization of the middle meatus, of the sphenoidal recesses, and the nasopharynx. It is also necessary to verify the presence of crusts, ulceration, septal perforation, signs of nasal bleeding, and secretions, and

to exclude the possibility of associated polyposis and expansive lesions. It is very important to perform the endoscopic assessment in patients undergoing surgery. The evidence of mucosal disease six months after surgery should be considered as CRS. Another factor to be taken into account in patients with previous surgery is the recirculation of mucus by not including the natural ostium of the maxillary sinus in the antrostomy.

Fokkens et al.¹ established an endoscopic score for CRS monitoring, as shown in Table 1.

The scoring is performed as follows:

- Polyps (0 = absent; 1 = only in the middle meatus; 2 = originate from the middle meatus, but do not completely obstruct the nasal fossa; 3 = completely obstruct the nasal fossa);
- Edema / synechiae / crusts (0 = absent; 1 = mild; 2 = severe);
- Nasal discharge (nasal secretion; 0 = absent; 1 = clear, fluid; 2 = thick, purulent).

Nasal endoscopy is an examination of utmost importance to assist in establishing the diagnosis, supervising disease follow-up in the postoperative period, as well as collecting material for supplementary tests.

Imaging assessment

CT is the imaging method of choice for CRS evaluation; however, it is not the first step in the diagnosis, except in cases with unilateral signs and symptoms and suspected complica-

Table 1 Endoscopic score for CRS follow-up (Source: adapted from Fokkens et al.)¹

Characteristic	Initial assessment	Follow-up 3/6/12/24 months
Polyp -		
LNC (0, 1, 2, 3)		
Polyp -		
RNC (0, 1, 2, 3)		
Edema -		
LNC (0, 1, 2)		
Edema -		
RNC (0, 1, 2)		
Nasal discharge -		
LNC (0, 1, 2)		
Nasal discharge -		
RNC (0, 1, 2)		
Postoperative		
Synechiae -		
LNC (0, 1, 2)		
Synechiae -		
RNC (0, 1, 2)		
Crust -		
LNC(0, 1, 2)		
Crust -		
RNC (0, 1, 2)		
Total		

tion. There are several staging systems described in literature, but the most commonly used is the Lund-Mackay system that established the staging based on opacification of paranasal cavities and the ostiomeatal complex³⁵⁰ (Table 2).

It is noteworthy that incidental abnormalities are observed in up to 50% of CTs of “normal” patients.¹⁸⁸ Therefore, the diagnosis of CRS based on the CT alone is not appropriate. When compared with CT, MRI is a better test to define soft tissues, and allow for the differentiation of secretions and tumors. Thus, it is a test that complements the CT in patients with suspected neoplasia.

Other examinations

Bacterioscopy/sinus secretion culture

Indicated in cases refractory to treatment and when the collected material is not contaminated. It is performed through puncture of the maxillary sinus through the canine fossa and through the endoscope to perform the collection in the middle meatus.³⁵¹

Nasal cytology

More often used in the presence of an associated allergic condition. Its use alone does not confirm the diagnosis of CRS.

Biopsy

It is important for the study and classification of the inflammatory state of CRS and sinonasal polyposis. It is indicated for the differential diagnosis of autoimmune and granulomatous diseases, and to rule out neoplasms (especially in unilateral cases).

Mucociliary function

Mucociliary function can be evaluated by mucociliary clearance (saccharin test or radioisotope particles), study of ciliary beat frequency, electron microscopy, and nitric oxide measurement.³⁵²⁻³⁵⁴ The saccharin test can give false-positive results. Scanning transmission electron microscopy is important for the diagnosis of primary ciliary dyskinesia.

Table 2 Tomographic staging - Lund-Mackay system. (Source: adapted from Fokkens et al.)¹⁸⁸

Paranasal sinuses	Right	Left
Maxilla (0, 1, or 2)		
Anterior ethmoid (0, 1, or 2)		
Posterior ethmoid (0, 1, or 2)		
Sphenoid (0, 1, or 2)		
Frontal (0, 1, or 2)		
Ostiomeatal complex (0* or 2*)		
<i>Total score for each side</i>		

Score: 0 = no abnormalities; 1 = partial opacification; 2 = total opacification;

0* = not occluded; and 2* = occluded.

Nasal patency

Nasal patency can be assessed by the peak inspiratory flow, rhinomanometry, acoustic rhinometry, and rhinosterometry. However, it does not define the diagnosis of CRS.^{355,356}

Olfaction assessment

The evaluation of olfaction can be performed with threshold and quantitative tests. The smell identification test of the University of Pennsylvania was recently culturally adapted to the Brazilian population and validated in Brazil.⁶⁷

Acetylsalicylic acid sensitivity test

When AERD is suspected, patients should be advised not to take the drug, as the challenge test that confirms the diagnosis may carry risks for the patient. In the USA, the most common challenge test begins with the ingestion of 30 mg of acetylsalicylic acid, increasing the dose until a reaction occurs. Subclinical sensitivity to that drug is probably between 5% and 15%.

Laboratory tests

Several laboratory tests can be performed in specific cases as part of the differential diagnosis. The clinical history and physical examination determine what tests are requested, that among others include: complete blood count with eosinophils, CRP, ESR, assessment of renal, liver and thyroid function, markers of humoral immunity (immunoglobulins, IgG, IgE subclasses, specific antibodies for tetanus, hemophilus *influenzae*, pneumococcus, aspergillus), response to immunization, and markers of cellular immunity (T and B lymphocytes), human immunodeficiency virus (HIV), ANCA (antineutrophil cytoplasmic antibodies), and measurement of chloride in sweat.³⁵⁷

Allergological assessment

It is crucial for patients with a positive history of allergy, AERD, or even with suspected fungal infection.

Comments

The diagnostic investigation of CSR is based on the patient's natural history, signs and symptoms, endoscopic examination, and CT. The latter is considered as a major factor in the analysis of disease progression and the decision-making of surgical intervention.

More studies are necessary to demonstrate the involvement of predisposing factors in the pathogenesis of CRS, such as: environmental, genetic factors, allergies, LPRD, and immunological and ciliary dysfunctions. The presence of *Helicobacter pylori* does not preclude screening, by the otorhinolaryngologist, of diseases associated with CRS refractory to treatment.

Social habits are another factor that must be taken into account. Recent studies have demonstrated midline destructive lesions induced by cocaine with ANCA (+) mimicking Wegener's granulomatosis associated with maxillary sinusitis. This finding opens up reflection on the relevance and complexity of the subject, importance of the multidisciplinary study and the social impact in the cause/effect association of CRS.

Associated factors and diseases

CRS has a multifactorial cause that results in persistent inflammation. Current knowledge of its pathogenesis does not identify one solitary inflammatory pathway that explains the entire process, from the initial lesion to the structural changes in sinonasal tissue.³⁵⁸ However, there is an emerging consensus that the persistent inflammation that defines CRS results from a dysfunction of the host-environment binomial, which makes apparent the imbalance of external agent interaction, predisposition of the sinonasal mucosa, commensal flora, potential pathogens, and exogenous stress.³⁵⁹

This section will discuss the main diseases and factors associated with CRS, sometimes overlapping, sometimes tangential, as conditions that trigger, exacerbate, or perpetuate persistent inflammation.

Predisposing factors and associated diseases

Predisposing factors and associated diseases to CRS can be grouped into three broad and overlapping categories:

Environmental, local anatomical, and systemic factors

Environmental exposure

Exposure to toxins such as tobacco, ozone, sulfur dioxide, and particulate air pollutants (e.g., smoke from diesel combustion), has the potential to trigger epithelial injury and exacerbate airway inflammation.³⁶⁰ Exposure to air pollution, several chemical irritants, inhalants used in photocopying, and smoke from forest fires^{1,361} are related to increased prevalence of RS and asthma.^{362,363} A comparative study among individuals who work in an environment with air conditioning and natural ventilation showed a positive association with increased nasal and nasal-ocular symptoms, persistent cough, and symptoms of RS in those exposed to artificial air conditioning.³⁶⁴

Smoking

Children of parents who smoke are more prone to acute respiratory disease compared with children of nonsmoking parents.⁴⁶ The adult population also shows a higher prevalence of RS in smokers (53.1%) when compared with nonsmokers (26.4%). Subjects with allergic rhinitis exposed to tobacco have more episodes of respiratory disease when compared with control groups.¹

Anatomical factors

Anatomical abnormalities such as septal deviation, concha media bullosa, deviations of the uncinate process, Haller cells, hypertrophic ethmoid bulla, and prominent *agger nasi* cells are correlated with CRS. These anatomical variations may play a role in the pathogenesis of CRS and increase the risk of sinus mucosa disease.^{365,366} However, some studies have shown that these anatomical changes are not correlated with CRS.³⁶⁷⁻³⁶⁹ It is observed that there is no specific study in the literature that correlates anatomical variations with obstruction

of ostiomeatal complex drainage and CRS. Although there is no causal evidence that anatomical variations are responsible for CRS, many sinus symptoms improve with surgical correction, which that improves drainage of secretions, and favors sinus ventilation. Therefore, in patients with CRS, it is important to evaluate the anatomy of the nasal cavity.

Odontogenic infections

Oroantral fistula, periodontal disease, periapical abscess, and tooth roots that project into the maxillary sinus are causal factors of acute maxillary sinusitis. In recent years, complications of dental implants were also shown to be the cause of infections. Although the odontogenic causes of sinusitis are common, they are rarely mentioned in recent guidelines and are neglected by many otorhinolaryngologists, dentists, and radiologists.³⁷⁰

The pain is often sinus and isolated, without nasal involvement. It is most commonly located in the infraorbital region, unilaterally or bilaterally, and may worsen with postural changes of the head. It may also radiate to the forehead, to the maxillary premolar and molar regions. In addition, patients complain of fever and thick retronasal secretion. In cases of purulent nasal discharge despite the use of antibiotics and persistence of infraorbital pain, odontogenic sinusitis should be suspected. On physical examination, there is pain on palpation of the anterior wall of the affected maxillary sinus or the bony prominences adjacent to the first molars.

In some cases, no alterations were observed in the external dental structure and there were no signs of tooth decay.³⁷¹

PCD

PCD is a rare autosomal recessive disorder, in which the cilia are immotile or have an altered pattern of movement, causing failure of mucus transport in the airways. The incidence of immotile cilia syndrome ranges from 1 in 15,000 to 1 in 30,000.

PCD is associated with bronchiectasis and chronic upper airway symptoms such as nasal secretion, episodes of facial pain and anosmia. In neonates, there is continuous rhinorrhea since the first day of life.¹ The diagnosis should be suspected in children with atypical asthma, bronchiectasis, chronic productive cough, thick continuous nasal discharge, and severe chronic otitis media (especially in children with continuous aural drainage despite placement of tympanostomy ventilating tubes). Diagnosis is suggested by below normal nasal nitrous oxide levels, and a saccharin test > 30 min.³⁷²

More specific tests in specialized centers include examination of cilia by electron microscopy. The most common structural abnormalities are the absence of external dynein arms or the combination of absence of both the internal and external dynein arms.⁴¹

Kartagener's syndrome is a subgroup of PCD inherited as an autosomal recessive disorder. The structural abnormality is the absence of dynein arms. *Situs inversus* of organs is found in approximately 50% of cases of dyskinesias.

Young's syndrome is unusual, being a combination of obstructive azoospermia of the epididymis, which is associated with infertility.

Laryngopharyngeal reflux (LPR)

The association of LPR with RS is controversial, requiring further studies for confirmation. In children, gastroesophageal reflux disease (GERD) has been associated with RS in many studies. Phipps et al.³⁷³ performed a prospective study of 30 pediatric patients with chronic RS who underwent 24-hour pH monitoring and observed that 63% of children with CRS had GERD. Among children diagnosed and treated for LPR, 79% showed improvement in signs and symptoms of RS.³⁷³ Although other studies also describe similar results between LPR and CRS, routine antireflux treatment is not recommended for CRS patients.

Allergy

Review articles suggest that atopy predisposes to CRS.^{374,375} Both conditions are frequently associated and share an increasing prevalence.^{376,377} A number of studies report that atopy markers are more prevalent in populations with CRS.^{35,378-380} However, the role of allergy in CRS is questioned by other epidemiological studies, which showed no increase in the incidence of infectious diseases.³⁸¹

Between 0.5% and 4.5% of subjects with allergic rhinitis have NPs.³⁸²⁻³⁸⁴ Conversely, the prevalence of allergy in patients with NPs ranges from 10% to 64%.³⁸⁵⁻³⁸⁷ Contrary to studies that reported atopy as more prevalent in patients with NPs, other authors found no such association.^{384,387-389} Allergy does not appear to have a direct association with NPs, but can be an aggravating factor.

Recently, Bachert et al.³⁹⁰ found an association between levels of both total and specific IgE and eosinophilic infiltration in NPs.

A recent study³⁹¹ that compared the bacterial flora of the nasal mucosa between allergic and nonallergic individuals, did not demonstrate greater bacterial growth in those with allergies. Nonetheless, in allergic rhinitis, there is no doubt that the mucosal edema in the region of the sinus ostia may compromise ventilation and sinus drainage, causing mucus retention and increasing the risk for infection.

Non-allergic eosinophilic rhinitis

Nonallergic eosinophilic rhinitis has similar clinical characteristics to those of allergic rhinitis. Its onset occurs in adulthood, around the age of 20-30 years, and it is often associated with RS with polyps and 30% of patients also have asthma. It shows normal skin test and IgE levels. The use of acetylsalicylic acid and other NSAIDs is not recommended.

Asthma

CRSwNP and asthma are frequently and closely related, but their interaction is still not well understood.^{392,393} Asthma occurs in 26% of patients with CRSwNP compared with 6% of controls.^{394,395} Alternatively, 7% of asthmatic patients have NPs,³⁸² with a prevalence of 13% in non-atopic asthma and 5% in atopic asthma.³⁸⁸ There is a high prevalence of radiological abnormalities of the paranasal sinuses in asthmatics.³⁹⁶⁻³⁹⁸ Asthmatic individuals with CRSwNP have more severe nasal symptoms. This combination should be a clinical clue to suggest severity in both diseases.³⁹⁹

Acetylsalicylic acid intolerance or acetylsalicylic acid-exacerbated respiratory disease (AERD)

Acetylsalicylic acid intolerance, asthma, and NPs are frequent associated, and then are known as Samter's or Widal's Syndrome. It commonly initially presents with only NP and asthma with acetylsalicylic acid intolerance appearing later. The etiology is unknown, although its evolution is well known there is a very high rate of recurrence and frustration after surgical treatment.

Thirty six to ninety six percent of patients intolerant to acetylsalicylic acid have CRSwNP.^{35,383,400-404} Radiological evaluation of these patients reveals that up to 96% have alterations in the paranasal sinuses.⁴⁰⁵ From an epidemiological viewpoint, patients intolerant to acetylsalicylic acid are usually non-atopic, with an increased prevalence after forty years of age. Children of patients with asthma, NPs and acetylsalicylic acid intolerance had NPs and CRS more often than children of the controls,⁴⁰⁶ suggesting a hereditary factor. Zhang et al.⁴⁰⁷ found that the enterotoxin-specific IgE can be found in most NPs of patients with acetylsalicylic acid intolerance.

Cystic fibrosis

The finding of NPs in a child is rare (less than 0.1% of children) and should elicit an investigation for CF, which is present in up to 60% of children with NPs. In contrast, NPs do not affect all patients with CF, and the presence of NPs varies with the particular mutation of the CF gene responsible for the disease, but, in general, approximately 20% of CF patients have NPs. CRS is present in 70% to 100% of the patients. The clinical manifestations of CF are variable, and adults in their fifth and sixth decades of life can, on rare occasions, be newly diagnosed with CF.^{408,409}

Adults with NPs dating from childhood should get tested for sodium/chloride in sweat or genetic testing or both to evaluate the presence of CF. Up to 7% of patients with CRS are heterozygous for a CF gene, when compared with less than 1% of normal controls. The physiopathological implications of this finding remain unknown. CRSwNP in CF is usually characterized as non-eosinophilic and more neutrophilic CRS.⁴¹⁰

Immunodeficiencies

Primary or congenital immunodeficiencies manifest with symptoms of RS since childhood, usually associated with infections in other organs. In acquired immunodeficiency, especially in HIV-positive patients, RS is quite common, being present in over 50% of patients. Immunosuppressed patients after immunotherapy treatment or patients with diabetes mellitus may have CRS, and can have either indolent or fulminant invasive fungal RS, which are usually severe and should be promptly treated after they are diagnosed.

Concomitant chronic diseases

A number of diseases can be associated with CRS; due to their broad involvement with general practice, it is impossible to exhaust the subject. Sometimes the sinonasal complaints can

offer the first suggestion to attain an important clinical diagnosis, positively contributing to patient evolution. They are:

- *Wegener's granulomatosis*: associated with vasculitis, it often starts in the nose and paranasal sinuses with CRS, and at advanced stages, disseminates to other organs, especially the kidneys and lungs. The diagnosis is difficult, and requires biopsy confirmation of vasculitis; the possibility of a positive biopsy is increased when performed in an affected maxillary sinus region.
- *Sjogren's syndrome*: mainly characterized by dry eyes and mouth; it is associated with CRS and rheumatologic symptoms.
- *Churg-Strauss syndrome*: CRSwNP, severe asthma, and vasculitis are observed. Widespread eosinophilia has also been reported; a complete blood count showing an increase of more than 20% in eosinophils is a very suggestive finding.
- *Systemic lupus erythematosus*: it is sometimes difficult to diagnose, depending on a number of criteria, but it is often associated with CRS.
- *Sarcoidosis*: often associated with CRS, it is also difficult to diagnose, showing non-caseous granuloma at biopsy. At anterior rhinoscopy, fine slightly yellowish granules are a suspicious finding that suggests that other tests necessary to establish the diagnosis be performed.

Other systemic diseases are associated with CRS, and patient management is easy when a diagnosis has already been established, but the challenge of finding a possible systemic cause of CRS or a factor for its recalcitrance is an obligation of the otorhinolaryngologist.

Comments

The multiple causes of CRS can result in isolated sinonasal manifestations, but it is important to note that the nose and paranasal sinuses may reflect the first symptoms of systemic diseases. The identification of predisposing factors and diseases associated with rhinosinusitis are of utmost importance for adequate patient management.

Clinical treatment

Treatment with systemic and topical antibiotics

The growing perception of CRS as a multifactorial inflammatory process has been clearly expressed in the latest consensus, i.e., it is not a persistent bacterial infection.⁴¹¹ This fact has led to an obligatory theoretical reassessment of the use of antimicrobials for treatment of this entity. However, and unfortunately, it is not surprising that, in practice, antibiotics remain a constant part of the drug arsenal used in these patients' everyday life, and is persistently present in different proposals for disease management.⁴¹² This is possibly due to the lack of awareness of the absence of bacteria both in free form and/or in biofilms in the paranasal sinuses of these patients. This main theoretical basis for the choice of antibiotics also suffers from the inability to differentiate the true role of bacteria found in

the paranasal sinuses, because their identification alone does not mean the presence of an infectious condition or inflammatory reaction to their presence.⁴¹³ However, the identification of bacteria, such as *Staphylococcus* and *Pseudomonas*, in higher percentages among patients with recurrent conditions (postoperative) perpetuates the belief about the need to consider them as part of the physiopathogenesis of CRS. In spite of those statistically significant results, it must be highlighted that, in terms of percentage, the number of positive cultures in that study was higher both in the group with a poor outcome and in those with a favorable outcome (87% vs. 73%); for the bacteria in question, the absolute difference was 14% (39% vs. 25%).⁴¹⁴

Recent studies have investigated bacteria as a necessary element responsible for maintaining the balance of inflammatory response, depending on their interaction with the host. The topical use of probiotics and bacteria in an attempt to create flora and biofilms that can induce nasal homeostasis is an example.⁴¹⁵ In the past five years, there has been no truly remarkable evidence for the use of antimicrobials in CRS. Despite this lack of evidence, there are still recommendations for the use of macrolides for long periods, for instance, in the absence of elevated serum IgE.^{1,416-420} Meltzer et al.,⁴²¹ in a review article concluded that there is a lack of publications that establish a proven effective proposal for the treatment of CRS. The authors point out that, as long as the different presentations of the disease are not well defined, several different treatments will follow, with limitations regarding interpretation and extrapolation of results.

They also stated there are signs of increased interest in developing research protocols, but the identification of ongoing studies of RCTs *versus* placebo (i.e., adequate designs to search for such responses) at the United States National Institute of Health (NIH-ClinicalTrial.gov) does not support that claim (<http://clinicaltrials.gov/ct2/results>). Thus, more specific inclusion and exclusion criteria, randomization, prospective design, and control groups are required for the study of antibiotic treatment in CRS.

Systemic antibiotics

Few studies have evaluated the use of systemic antibiotics in patients with CRS with and without NPs. They have been studied mainly in relation to their effects during flare-ups of chronic conditions. Undoubtedly, the most common long-term use (over four weeks) is due to the anti-inflammatory effect exhibited by some drugs in this class, such as macrolides.

Van Zeele et al.⁴²² studied doxycycline in the treatment of patients with CRSwNP compared to methylprednisolone (20 days) in an RCT *versus* placebo design. During the 12-week follow-up period, the antimicrobial showed less dramatic results than oral corticosteroids, but the effects persisted longer, both with respect to endoscopic characteristics (size of polyps) and the measurement of inflammatory markers that were different than those of the corticoid. These findings lead to the hypothesis that the drugs might have a synergistic effect when used concomitantly. In another study, al-

beit observational with 125 patients, the authors found no evidence of the effectiveness of antibiotics, as they also deduced that typical findings, on endoscopy and CT, are nonspecific and are not compelling as an indication for these drugs.⁴²³ Still following the line of treatments with antimicrobials for a short period of time (21-30 days), Shlalek et al.⁴²⁴ studied different antimicrobials (ciprofloxacin, amoxicillin/clavulanic acid, and co-trimoxazole) in patients with polyposis, and observed no statistically different results. If there is consensus that the bacteria may be part of the etiology, but certainly are not the main factor in CRS, studies such as that by Liu et al.,⁴²⁵ become significant. Unfortunately, with a sample of only six patients, the authors studied the effects of treatment on the microbiota of the maxillary sinus of patients with clinical picture and findings consistent with persistent disease in this sinus, even after surgical treatment. In addition to describing individual variations in the flora, they observed significant changes, such as the emergence of less susceptible bacteria.

In the 2008 guidelines,⁴¹¹ the possibility of using of some antibiotics, identified as having anti-inflammatory effects, appeared to be the start of a new era for some patients with CRS. However, the lack of definitive studies and the increased risk of inducing bacterial resistance brought on new questions. Videler et al.⁴²⁶ conducted an RCT *versus* placebo study to evaluate azithromycin for 12 weeks in 60 patients, with and without polyposis, with and without asthma, as well as a percentage who had already been submitted to surgery, assessing several objective and subjective outcomes, none of which showed statistical differences compared to the placebo group. The comparison of the characteristics of this sample in relation to the sample from a previous study, also RCT *versus* placebo, which showed significance in favor of the treated group, indicated the possibility that this type of treatment benefits a specific population of patients with CRS (without polyps, with normal IgE and, possibly, with less mucosal disease).⁴²⁷ In another retrospective study, Videler et al.⁴²⁸ observed improvement in some outcomes among Dutch patients with CRS with both azithromycin and trimethoprim-sulfamethoxazole, when compared to those who did not receive any antimicrobial drug. The authors noted that, considering the type of design, it would not be appropriate to define the true impact of these drugs.

In the same year, Majima et al.⁴²⁹ compared the efficacy of clarithromycin for 12 weeks or associated with clarithromycin plus carbocysteine in 425 patients, and concluded that the combination of the two drugs yields significantly better results compared to the use of antimicrobials alone. While they had a large sample and significant results, the lack of a placebo group significantly hindered the extrapolation of their results.

Comments

The authors warn about the frequent use of antibiotics and the importance of knowing how to differentiate them among the therapeutic options for CRS. Nonetheless, there is not enough information to completely eliminate their use. It is necessary to find ways to identify exactly the patients who could benefit from antimicrobial use in cases of unequivocal clinical flare-ups and to identify the specific bacterial agent through culture and sensitivity test. Regarding the extended

use in CRSwNP cases in which there is persistence of severe symptoms without improvement and without serum IgE elevation after multiple treatments (including surgery), there is still not enough evidence; their possible biological effects must be significantly considered when restricting their use.

Topical antibiotics

In light of the difficulties in CRS management, treatment with topical solutions has drawn the attention of the scientific community in the last decade, hoping for a new improvement in therapeutic results. With respect to the assessment of systemic antibiotics, the problems regarding the quality of the available literature are similar. There are problems not only with the appropriate study design (RCTs *versus* placebo), but also with the choices of the populations studied. Among the topical options are antibiotics, which are part of the available treatments for patients with chronic lower airway diseases.

In addition to the effectiveness of these drugs in their topical form, other issues must be addressed. One concern is the possible adverse effects from an unknown degree of systemic absorption. For instance, gentamicin, although given in low concentrations, was detected in serum after lavage during a sinonasal surgical procedure.⁴³⁰ Another concern, rarely addressed but nonetheless important, is the possible impact on the microbiota in terms of the induction of resistance. Finally, it is necessary to know whether the drugs used topically actually reach the paranasal sinuses. In a cadaver study only small particles (0.67 to 0.99 microns) reached the maxillary sinuses with large antrastomies. Larger particles were deposited on the nasal valve.⁴³¹

Few studies have addressed quality of life improvement in patients with CRS treated with topical antibiotics delivered by a small-particle nebulizer, and some did not find different results from those obtained with saline solution lavage, and cautioned against the possible adverse effects related to the absorption of these drugs.⁴³² More recently, a clinical trial by Videler et al.⁴³³ did not find any statistical difference between nebulized colimycin and bacitracin in patients previously submitted to a surgical procedure who were resistant to other treatments.

In conclusion, there is no evidence for recommending the use of topical antibiotics for CRS with and without NPs.

Corticosteroids in chronic rhinosinusitis

In CRS, whether with or without nasal polyps, there is only one consensus at the moment: it is an inflammatory disease with different triggers. Therefore, no choice is more rational than the use of drugs with anti-inflammatory effects, whose main representatives are corticosteroids. The potential of these drugs as modulators of bacterial presence has also been investigated. This group of drugs includes options for topical intranasal, oral systemic, and injectable use. The indications include continuous symptomatic control, surgical preparation, and postoperative maintenance. The surgical procedure-related use will be discussed in another section of this document. The use of these medications will be divided between patients with and without NPs. This division is justified because they are two distinct groups in

terms of physiopathogenesis, symptoms and therapeutic results.¹

Topical corticosteroids (CRSwNP)

These medications favorably alter the cytokine profile in the subepithelial layer, but do not effect any change in the characteristics of the biofilm.⁴³⁴

Goggin et al.⁴³⁵ demonstrated the *in vitro* inhibitor potential of bacterial growth in the form of biofilm when exposed to topical corticosteroids. In a systematic review of 48 studies, it was observed that early surgical treatment is a beneficial factor for topical corticosteroid effectiveness, especially by helping with drug distribution in the sinonasal mucosa.⁴³⁶

In another systematic review, 25 studies on the use of these drugs in patients with CRS and polyposis showed that these drugs were effective, but the same effectiveness was not seen in patients without polyposis.⁴³⁷ Similar results were reported in another meta-analysis.⁴³⁸ In a recent Cochrane review, topical corticosteroids were effective in improving symptoms and reducing polyp size and the rate of post-surgical recurrence. The authors also observed that patients submitted to previous sinonasal surgery responded better to this therapy. They also reported there was no difference regarding adverse effects compared to the placebo group.⁴³⁹

The major adverse effects of topical corticosteroids, in addition to varying degrees of local irritation, are epistaxis and rarely septal perforation.¹ It is also worth mentioning that in the international literature there are discussions about the benefits of different techniques of distribution and devices used with the drugs.^{436,437}

Topical corticosteroids in CRSsNP

Unlike patients with polyposis, the results in the group without polyps are not as homogeneous; there are reports of positive effects on symptoms, but not on other outcomes, such as endoscopic scores and radiological aspect.⁴⁴⁰

Systemic corticosteroids in CRSwNP

A recent systematic review recommended that these drugs be used only for a short period and for preoperative preparation.⁴⁴¹ EPOS 2012 also discussed the beneficial effects in relation to symptoms and polyp reduction, but since this is a chronic disease, it is worth mentioning that the duration of these beneficial effects was brief.¹

Systemic corticosteroids in CRSsNP

The same recent systematic review suggested that there is no evidence that either indicates or contraindicates the use of systemic corticosteroids in this subgroup.⁴⁴¹ EPOS 2012 corroborates this opinion, reflecting the available literature.¹

Comments

Therapy with topical and/or systemic corticosteroids is an important part of CRS treatment. This effect is demonstrated most convincingly in patients with polyposis. Although

more studies are required to support this claim, they are considered as allies in the fight against CRS in general, especially when used topically. Systemic administration is suggested for cases of CRS with uncontrolled symptoms, in which the goal is to decrease, even temporarily, the impact of the disease on the patient's life. In these situations, it is recommended to use the lowest effective dose for the shortest possible time, to minimize the potentially more severe side effects.

Antileukotrienes and chronic rhinosinusitis

Nasal polyposis (NP) is a chronic inflammatory disease of the upper respiratory tract that affects 2% to 4% of the population and two thirds of patients with acetylsalicylic acid-sensitive asthma. The histology of polyps is similar to that seen in polyps of patients with asthma, and is characterized by abundant eosinophils, mast cells and high levels of pro-inflammatory cysteinyl leukotrienes.¹

It has been suggested that one potential cause of CRSwNP is any potential defect in the eicosanoid pathway that is strongly associated with acetylsalicylic acid intolerance.⁴⁴² Specifically, the increased synthesis of pro-inflammatory leukotrienes and decreased synthesis of anti-inflammatory prostaglandins have been the accepted mechanism, not only for CRSwNP in acetylsalicylic-acid-sensitive polyposis, but for acetylsalicylic-acid-tolerant individuals as well.⁴⁴³

Regarding leukotrienes and CRS, there is abundant data demonstrating their role in reducing inflammation, especially with respect to eosinophils and the eicosanoid pathway.⁴⁴⁴ The use of montelukast showed a reduction in eosinophilic inflammation, viability, and cytokine production in nasal polyps after treatment with montelukast.⁴⁴⁵

Di Capite et al.⁴⁴⁶ used immunohistochemistry, immunoassays, and cytoplasmic calcium ion imaging in human mast cells from cultures acutely isolated from patients with polyposis. They demonstrated that calcium influx into the mast cell through the activation pathway of calcium channel release stimulates the production of leukotrienes C4, which, in turn, activates greater calcium influx. The combination of low concentrations of calcium release activated channel blockers and leukotriene receptor antagonists was as effective as the concentration of the two antagonists alone to inhibit mast cell activation. This fact should be further studied in order to assess whether there is any clinical significance in this mast cell inhibition of antileukotrienes.⁴⁴⁶

The data regarding the pathophysiology of CRS very clearly support the use of antileukotrienes, but when the data from randomized, double-blinded clinical trials on the effectiveness of leukotriene inhibitors are analyzed they do not support theoretical studies as clearly.⁴⁴⁷

After more than 15 years of their use, the effectiveness of antileukotrienes in allergic rhinitis and asthma has been clearly demonstrated. Montelukast showed good effectiveness for the treatment of seasonal and perennial allergic rhinitis in large, double-blinded RCTs, indicating significant improvement in nasal and ocular symptoms between one and three days, as well as in nocturnal symptoms, quality of life, and sleep.⁴⁴⁸

The allergic rhinitis and its impact on asthma (ARIA) initiative suggests that leukotriene receptor antagonists are effective, well tolerated and very safe; they are rec-

ommended for use in adults and children with intermittent allergic rhinitis and in preschool children with persistent allergic rhinitis.⁴⁴⁹ Leukotriene antagonists such as montelukast, zafirlukast, and zileuton were evaluated in studies involving several patients with CRSwNP and AERD,^{450,451} but the results were not definitive. Many were open uncontrolled studies that suggested a benefit of leukotrienes regarding symptomatology, the size of the NPs, and the tomographic scores.⁴⁵² Other results include significant score improvement in symptoms of headache, facial pain and pressure, ear discomfort, dental pain, purulent nasal discharge, postnasal drip, nasal congestion with obstruction, as well as olfaction.⁴⁵³ These authors also concluded that leukotriene-modifier drugs, when added to standard medications, including corticosteroids, result in nasal symptom improvement in patients with CRS with and without polypsis.⁴⁵⁴⁻⁴⁵⁶ However, data from a double-blinded RCT did not consistently support the benefit of antileukotriene therapy in patients with CRS.^{450,457} Although they are effective in patients with AERD, that effect is no greater than is seen in acetylsalicylic-acid-tolerant individuals.^{456,458}

The combination of montelukast with intranasal corticosteroids has been shown to be effective in CRS. According to Fergusson et al.,⁴⁵⁹ montelukast added to intranasal corticosteroids improves symptoms in patients with CRS, with excellent safety profile. A recent study evaluating the postoperative effects of montelukast and intranasal mometasone in patients with CRSwNP showed complementary results between the drugs. Both treatments led to a significant reduction in SNOT-22 scores and NPs, with a marginal benefit of montelukast alone.⁴⁶⁰ For these reasons, leukotriene action, when analyzed from the perspective of evidence-based medicine, reveals limited level of efficacy (III) and low grade of recommendation (C) for patients with CRSwNP.⁴⁶¹

Comments

Initially used in the treatment of asthma and then allergic rhinitis, antileukotrienes have been used for more than 15 years, and have proven efficacy, level of evidence A and recommendation for these diseases.⁴⁴⁹ Later, they were used in other chronic nasal diseases, mainly CRS with or without nasal polyps, because of the high morbidity and the low quality of life of affected patients.

Montelukast has been the most often used antileukotriene to date, and there are data demonstrating its action as a leukotriene receptor antagonist. Its anti-inflammatory actions, mainly those related to eosinophils, and its cytokines have been demonstrated by several studies. Another important factor related to montelukast is its high safety and tolerability, being free of adverse effects, even in children.⁴⁴⁴ What is clearly concluded is its usefulness in allergic patients with asthma and in those with acetylsalicylic acid intolerance. These are the patients with CRS that should use antileukotrienes as treatment, whether as an adjunct therapy or not, in the postoperative period, and as maintenance therapy.

According to Scadding et al.,⁴⁶² over time, it becomes apparent that certain patients respond better to antileukotrienes than others. The reasons for this fact are becoming gradually clearer,⁴⁶² and genetic characteristics are being associated with these responses. The pharmacogenetic tests required to identify patients who might benefit more are not

yet available. Therefore, a simple therapeutic test for approximately one month, with monitoring through objective and subjective measures is suggested, especially in patients whose treatments with other medications have shown limited response. Patients who may present with Churg Strauss syndrome are the exception.

Acetylsalicylic acid desensitization

Acetylsalicylic acid desensitization in cases of CRS has been a clinical treatment option in patients with AERD. This disease is characterized by CRS with polypoid degeneration, asthma, and acetylsalicylic acid intolerance. Patients have a high rate of disease recurrence, depend on corticosteroids, and have a high rate of recurrent nasal surgery, or require NSAID therapy for other medical reasons, such as chronic arthritis or coronary disease.⁴⁶³ Desensitization can be performed through the nasal, inhalation, and injectable routes. The proposed desensitization therapy was first described in 1976 and was supported by the observation of improvement of sinonasal symptoms with the use of acetylsalicylic acid for the treatment of other systemic diseases.^{464,465}

Desensitization methodology

The drugs used for desensitization are acetylsalicylic acid and lysine acetylsalicylate. The improvement obtained with this process is dose dependent and after maintenance dose discontinuation, nasal symptoms recur within a few days. Regardless of the route, there is no pre-defined dose for the start of desensitization or for its daily maintenance. The protocols are based on controlled and progressive administration of small and increasing doses of acetylsalicylic acid ingested within two to three days; when the patient can ingest 650 mg and exhibit no adverse reactions three hours later, they are said to be tolerant. The procedure should always be performed in a hospital setting, due to potential occurrence of severe adverse reactions, which can occur in 12.5% to 23% of cases.^{464,466,467} Maintenance is performed by daily administration of doses of 100 to 300 mg.

Standard desensitization is performed with the use of acetylsalicylic acid administered orally for three to five days, and thereafter, the dose should be maintained daily.⁴⁶⁸ Due to gastrointestinal effects, approximately 30% of patients discontinue treatment, but treatment withdrawal decrease to 9% when proton pump inhibitors are used concomitantly.^{464,468} Lysine acetylsalicylate administered through nasal route has been employed in more recent studies and carries a lower risk of side effects, as shown in the study by Miller et al.,⁴⁶⁹ that evaluated 150 patients; only three had an adverse reaction to a dose higher than 375 mg of acetylsalicylic acid. When using lysine acetylsalicylate through the inhalation route, the adverse effect is usually moderate bronchospasms, reversible with beta-agonists; when the intravenous route is used, there is no higher incidence of adverse effects than with the other routes, with the advantage of discontinuing the infusion if severe adverse effects occur.⁴⁷⁰ Any of the routes used require monitoring due to the risk of these severe adverse effects, which may occur after ingestion of from 30 to 150 mg of acetylsalicylic acid.⁴⁶⁴ The addition of intranasal ketorolac in the desensitization test was effective, safe, and achieved the

desensitization dose of acetylsalicylic acid more quickly. In the assessed protocols, ketorolac is used in four increasing doses at 30-minute intervals and then oral acetylsalicylic acid is introduced.^{471,472}

Mechanism of desensitization

The desensitization mechanism is based on the blockade of the lipoxygenase pathway. A decrease in leukotriene B₄ and thromboxane B₄ has been demonstrated in a cultured cell model after desensitization, as has a reduction in bronchial responsiveness to leukotriene B₄ after desensitization has started.⁴⁷³ Eosinophils activation has also been described following intranasal desensitization with lysine acetylsalicylic acid, which is maintained both in the initial and late phases. Cysteinyl leukotriene was also increased in the initial phase, but it did not remain so in the late phase.⁴⁷⁴ Rizk suggests the possibility of the inhibition of an intracellular biochemical pathway involving anti-inflammatory interleukins IL-4 and IL-13.⁴⁶⁴ In a recent study, it was postulated that acetylsalicylic acid ingestion reduces the activation of tyrosine kinase, which inhibits the phosphorylation of STAT6, reducing the production of IL-4, with consequent decrease in the production of cysteinyl leukotriene (Cys-LT) and the expression of CysLT receptor, resulting in inflammatory tissue reduction.⁴⁷⁵ The authors have found significant symptom improvement when desensitization was continued for a period of one to six years, with significant decreases in the use of oral corticosteroids for asthma, the dose of nasal corticosteroids, the number of infections, the need to undergo nasal surgery per year, the number of hospitalizations and improvement in olfaction in these patients.⁴⁶³

The effectiveness of desensitization was also demonstrated in the assessment of polyp recurrence rate. In the group of patients undergoing desensitization, the recurrence rates at one and six years were 6.9% and 65%, whereas in the group without desensitization it was 51.3% and 93.5% respectively. There was a dramatic difference in cost due to the low cost of acetylsalicylic acid and impressive reduction of hospitalizations and surgeries.^{463,476}

In conclusion, desensitization is a treatment option for cases with increased morbidity, and can result in significant improvement for most sinonasal symptoms compared to its use for asthma; the use of acetylsalicylic acid lysine and intranasal ketorolac may contribute to the reduction of adverse effects of desensitization. However, further studies should be performed to standardize the methodology and the acetylsalicylic acid maintenance dose to be used.

Antifungals

Although several studies have demonstrated the coexistence of fungi in the nose, both in healthy individuals and in those with CRS, there are still some who recommend the use of topical antifungals for the treatment of this disease.⁴⁷⁷ The use of topical nasal amphotericin B was associated with lower NP recurrence and improvement in symptoms and computed tomography findings, especially when administered together with lysine acetylsalicylate, according to studies without a control group.^{432,478-481} Nasal irrigation with am-

photericin B suspension twice daily for four weeks showed resolution of the NPs in 39% of cases.^{432,479} However, subsequent controlled-group studies, using topical amphotericin B (irrigation or spray) did not demonstrate significant beneficial effect for patients with CRS with or without polyposis. There was no difference in inflammatory markers in the control group with the use of antifungals, and healing was better in the control group.^{212,432} A randomized double-blinded study highlighted the higher rate of adverse effects and the lack of benefit with antifungal treatment.⁴⁸² Another double-blinded, randomized, multicenter study also showed no difference in symptom improvement after treatment with amphotericin B for three months when compared to placebo.²¹¹

Recently, three meta-analyses agreed that, although the use of topical antifungal improved the radiological appearance, symptoms did not improve significantly, and a high rate of side effects was observed.^{213,432,483-486} Some studies, which used increasing frequency and amounts of topical amphotericin B (four times daily for eight weeks) did not achieve additional effects when compared to the exclusive use of nasal saline solution in the treatment of CRS.^{208,210} The use of a systemic antifungal, such as oral terbinafine, showed no improvement even in cases of CRS with the presence of fungus in the investigation and a positive culture.²⁰⁷

Studies have also shown bias due to a lack of standardization regarding the type of administration, drug dose, and length of treatment, which ranged from four to 80 weeks.⁴³² Moreover, the type of storage used for amphotericin B was questioned, as this drug loses its stability when exposed to light.⁴³² Thus, Shin et al.²⁰¹ conducted a prospective, double-blinded, placebo-controlled RCT using amphotericin B for 12 months, and found no significant benefits in 33 patients with CRSwNP.

Currently, the use of antifungal therapies in CRS is very limited.^{207,212,213,432,477,478,483-487} Sacks et al.⁴⁸⁵ performed a placebo-controlled RCT to evaluate the treatment of CRS with topical and/or systemic antifungal, and showed that the side effects outweigh the benefits of treatment with antifungal agents. However, other recent studies have found, through PCR analysis of sinonasal cavity secretion, a large volume of unusual types of fungi (*A. alternata*, *C. cladosporioides*, *C. herbarum*, *P. brevicompactum*, *P. crustosum*, and *P. chrysogenum*) only in patients with CRS.^{483,488} The authors reported that there are subgroups of patients with high concentrations of these fungi and others without fungi.⁴⁸⁸ Furthermore, they report that *in vitro* studies did not test for the entire available antifungal spectrum and the tests were not performed for these unusual species. Therefore, more than one antifungal may be needed in order to eradicate the fungi found in the sinonasal mucosa.^{483,486} The authors also discussed the possibility of antifungal treatment failure in CRS due to incomplete eradication of the fungi in the nasal cavity.^{483,488}

Khalil et al.⁴⁸⁴ evaluated antifungal treatment in recurrent allergic fungal CRS after endoscopic sinusotomy using an oral antifungal agent (itraconazole for three months) and/or antifungal nasal spray (500 mL fluconazole in saline solution) and the same topical antifungal agent through nasal irrigation. Their results showed that the recurrence rate was similar between patients who received placebo and oral itraconazole (67%). The group that had the fewest

recurrences was the one that used fluconazole spray (10%), suggesting that when allergic fungal RS (AFRS) is suspected, it would be appropriate to obtain a culture for fungi, even with a negative result for fungi in the anatomopathological assessment. Moreover, they comment that some authors recommend the use of topical antifungals in combination with topical nasal corticosteroids in AFRS.^{489,490} However, other studies contradict the use of topical antifungals, reporting that their use may even worsen symptoms and cause deleterious side effects, including the nephrotoxicity and hepatotoxicity seen with systemic antifungals. Some authors have observed good results with itraconazole in refractory AFRS.^{491,492} Rains and Mineck⁴⁹³ defend the use of a combination of itraconazole and oral and topical steroids with endoscopic surgery for the control of AFRS, considering that, in refractory cases, there may be minimal fungal invasion in the sinonasal mucosa. The authors concluded that the topical antifungal fluconazole (spray or irrigation) can significantly reduce CRSwNP recurrence after endoscopic sinusectomy. In their opinion, there is no benefit in adding systemic treatment with itraconazole,⁴⁹³ because the systemic antifungal agent does not reach the target since the fungus lies on the mucosal surface without penetrating it, and therefore is not reached by blood; i.e., the fungus acts by triggering an allergic and noninfectious reaction.⁴⁹³ For some authors, the conventional treatment with topical corticosteroids and antibiotics in patients during the postoperative period of AFRS shows reasonable benefits in preventing polyp recurrence.^{484,493} The results correlated well with the findings of a study by Jen et al.,⁴⁹⁴ who observed that 12 of 16 (75%) patients with allergic fungal RS (AFRS) improved after treatment with fluconazole nasal spray. Moreover, Weschta et al.⁴⁸² performed a randomized, double-blinded, placebo-controlled trial with topical antifungal amphotericin B in 60 patients with CRS, with ineffective results.

Due to the controversial results of these studies, it is believed that there are different genotypes and, according to environmental and behavioral influences, different CRS phenotypes are generated. Therefore, fungi ceased to be the main agent in the physiopathogenesis of CRS, and exert limited influence in the AFRS subgroup. Both the treatments with topical and systemic antifungals in CRS have not shown evidence of their effectiveness in the current literature.^{432,483-494}

Preoperative period in patients with surgical indications

The procedures used before CRS surgical procedures are not homogenous and there are few evidence-based publications.

Combinations of antibiotics, steroids, nasal lavage, and nasal decongestants are the most commonly used medications/procedures in the preoperative management. The use of antibiotics to prevent postoperative infections has been adopted in endoscopic sinonasal surgery (ESS), in which 77% of the cases have potentially pathogenic species in the nasal cavity, such as *S. aureus*, *Klebsiella* spp., and/or *E. coli*. Moreover, patients with CRS usually receive repeated courses of antibiotics, which favors the development of resistant pathogenic species. Although antibiotics are widely used by surgeons preoperatively, aiming to de-

crease inflammation by minimizing infection and therefore improving the operative field, there are no clinical trials justifying this practice, and only a few studies have assessed the postoperative management.⁴⁹⁵

According to Portela et al.,⁴⁹⁶ 27% of the surgeons prescribed antibiotics preoperatively, whereas 35% did so postoperatively. The drugs used were amoxicillin-clavulanate, clarithromycin, erythromycin, and doxycycline, among others, for a period ranging between seven to 40 days. A recent survey among members of the American Rhinologic Society found that approximately 90% of otorhinolaryngologists prescribed antibiotics for three to four weeks in the treatment of CRS.⁴⁹⁷

In some institutions, such as Stanford University and the Johns Hopkins Hospital, patients are advised about the possibility of using antibiotics preoperatively, in the presence of active infection. In Brazil, the University of São Paulo (USP) protocol proposes amoxicillin-clavulanate, five to seven days before surgery, for patients with severe inflammatory infections.⁴⁹⁸⁻⁵⁰⁰

Maier and Strutz⁵⁰¹ designed a study with 106 patients, including some submitted to parotidectomy and neck dissection. Thirty-six patients in the sinonasal endoscopic surgery subgroup were randomly administered a single dose of 1.5 g cefuroxime intravenously preoperatively or that drug plus three additional doses every eight hours postoperatively. There were no reports of infection or side effects for any patient in the ESS subgroup from either treatment arm.

Intraoperative prophylactic antibiotic therapy is also controversial. Some guidelines^{501,502} for antibiotic prophylaxis in surgery, such as that by the Surgical Infection Society-Latin America, do not recommend the use of antibiotics in endoscopic surgeries. In Brazil, however, first-line hospitals recommend the administration of prophylactic antibiotics. Cefazolin is effective against methicillin-susceptible *Staphylococcus* and *Streptococcus* (except pneumococcus and some Gram-negative bacilli), and is the first choice for the prophylaxis of potentially contaminated surgeries. Clindamycin can be used in patients allergic to beta-lactam. Amoxicillin-clavulanate is the first choice for surgeries with risk of contamination by anaerobic microorganisms. Antibiotic prophylaxis must be used during anesthesia. The dose should be repeated if the operating time exceeds the half-life of the antibiotic or if major bleeding (10% to 20% of blood volume) occurs, requiring no further doses postoperatively.^{495,503-506}

Regarding preoperative use of corticosteroids, both oral and topical administrations have well-documented effects on CRS, especially in bilateral nasal polyposis. Nonetheless, there is no standardization of dose and/or type of oral corticosteroid to be used. Some studies have shown the effectiveness of preoperative corticosteroids on operative field improvement, reduced bleeding and surgical time.⁵⁰⁷⁻⁵⁰⁹

Wright and Agraval⁵⁰⁷ performed a double-blinded, placebo-controlled RCT in patients undergoing endoscopic surgery with CRSwNP. Participants were randomized to receive 30 mg of prednisone or placebo for five days preoperatively and nine days postoperatively. There was no difference between the groups with respect to postoperative symptoms.

Another randomized clinical trial evaluated the effect of a single dose of prednisolone (1 mg/kg/dose 24 h prior

to surgery) *versus* five days of prednisolone (1 mg/kg/day before surgery), and preoperatively, in 80 patients with bilateral NPs. The patients underwent surgery under general anesthesia, using the same protocol. Mean arterial blood pressure was 70-80 mm Hg in both groups. Mean bleeding during the operation was 266.5 ± 96.31 mL in group A and 206 ± 52.81 mL in group B, with a significant difference between groups. There was no significant difference between groups regarding the surgeons' opinion on the quality of the operative field. In conclusion, in contrast to the single 1 mg/kg/ dose of prednisolone, treatment with that dosage for five days can reduce blood loss during surgery and improve the quality of the operative field.⁵⁰⁸

A double-blinded, randomized study analyzed 70 patients with CRS with and without NP. Of that group, 35 received mometasone furoate (MF) and the other 35, a placebo for four weeks prior to ESS. Bleeding in the group treated with MF was 142.8 mL, less than that in the control group (170.6 mL). The difference between groups was 27.7 mL, which was statistically significant. The time of surgery was 59 minutes in the MF group and 70 minutes in the control group. The difference was 11.2 minutes, which was statistically significant. The quality of the endoscopic surgical field was significantly better in patients treated with MF. The use of the topical corticosteroid MF preoperatively can improve endoscopic vision, reduce bleeding, and decrease time of surgery in patients with CRS with and without polyps undergoing endoscopic surgery of the paranasal sinuses.⁵⁰⁹

Comments

Although there are controversies in patients with CRSsNP with purulent secretion, amoxicillin-clavulanate 875 mg, 12/12h, or cefuroxime 500 mg, 12/12h, for seven to ten days can be used preoperatively and maintained for seven to 21 days postoperatively. In some cases, fluoroquinolones and macrolides may be prescribed.

In patients with CRSwNP, the use of oral corticosteroids for three to five days (e.g., prednisone 0.50 mg/kg/day) is suggested, which is continued postoperatively according to extent of the disease.

Irrigation of the nasal mucosa with isotonic saline and hypertonic saline solutions, with and without preservatives, is a classic and safe measure in the treatment of CRS; it is very useful to mobilize secretions and to promote mucosal hydration pre- and postoperatively. However, there is no evidence for a beneficial action if it is used alone.⁴¹¹

Preoperative evaluation according to patient age and comorbidities

Because they increase coagulation time and thus increase bleeding, patients are advised to stop taking acetylsalicylic acid, ibuprofen, and other NSAIDs, vitamin E, ginkgo biloba, ginseng, and garlic tablets seven to ten days preoperatively. If the patient is anticoagulated, it should be discontinued seven to ten days prior to endoscopic sinus surgery, if at all possible. The partial thromboplastin and prothrombin time should be normal. Asthmatics patients or those with other comorbidities should be compensated preoperatively. For instance, patients with asthma may maintain broncho-

dilator sprays until the day of surgery. Those using steroids chronically can receive 100 mg of intravenous hydrocortisone at the immediate preoperative period. CT is essential in surgical planning, and must be able to be viewed in the operating room. The patient should be instructed regarding the procedure to be performed, the steps of the surgery, and the inherent risks of the procedure, and this should be documented by a signed informed consent.

Surgical treatment: techniques

Several surgical techniques have been described for use in patients with CRS with and without nasal polyposis who are refractory to medical treatment. There is no single gold standard technique that can be applied to all cases. Due to the lack of RCT, several aspects of the surgical management remain controversial. The most important of these is the extent of surgical dissection. As a result, based mainly on case series studies and expert opinions, current guidelines suggest that surgical management should be individualized. The current trend in CRS with and without nasal polyposis is that the surgical dissection proceed as far as the extent of the disease.¹

The most commonly used surgical approach is the endonasal access route. However, some cases may require an external or a combined access routes, such as lesions of the lateral maxillary sinus, the frontal sinus, or when there are no reliable anatomical landmarks for an exclusive endonasal approach. Regardless of the technique and the instruments used, there is clearly a learning curve in ESS. The surgeon should have deep knowledge of the surgical anatomy and should have undergone training in specific courses on dissection of the nose and paranasal sinuses.

Surgical treatment of CRS has advanced greatly with the use of sinonasal endoscopy. The image accuracy provided by the endoscopes (0 degree wide angle lens), as well as their angulations (30, 45, and 70 degrees), allows for the visualization of all the details and recesses of the paranasal cavities. Moreover, the development of other specific equipment and tools for intranasal and sinus use (e.g., dilation balloons, neuronavigator, and microdebrider) allow performing surgical procedures ranging from simple dilation of drainage ostia to complete marsupialization of the paranasal sinuses into the nasal cavity.⁵¹⁰⁻⁵¹²

The following paragraphs will briefly review the main endoscopic techniques described for the surgical treatment of CRS.

The most widely used technique for the surgical treatment of CRS is the functional endoscopic sinus surgery (FESS).⁵¹³ However, the word "functional" was questioned, and many now prefer the term endoscopic sinus surgery (ESS), which we will use hereafter. The word "functional" was previously used by authors to differentiate the procedure from the traditional techniques, which promoted complete removal of paranasal sinus mucosa for the treatment of CRS. The FESS technique, as originally described by Messerklinger,^{513,514} aimed to improve ventilation of the paranasal sinuses and, consequently, mucociliary function, while preserving the mucosa as much as possible. Judicious removal of inflamed tissue and bone to clear and, where necessary, extend the natural drainage ostia are the basic

tenets of ESS.

The surgical techniques employed by surgeons are quite variable, especially the surgical instruments, the anatomic landmarks, methods for hemostasis, the sequence and especially the extent of dissection. Most surgeons follow the anteroposterior lamellar dissection, as systematized by Stammberger et al.⁵¹⁴ that begins with the unciform process, then the ethmoid bulla, followed by the basal lamella, and the sphenotomy. Others have as main parameters the outer limits of the dissection, that is, the lamina papyracea laterally, the middle turbinate medially, and the skull base posteriorly. This is the centripetal technique.⁵¹⁵

The way surgeons handle the sinus ostia, especially of the maxillary, frontal, and sphenoid, as well as the intrasinus inflammatory alterations and the middle turbinate, is quite variable. Regardless of the technique used, it is vital that the natural drainage ostia are included in surgical dissections to prevent the mucus recirculation phenomena with possible perpetuation, or even worsening, of the chronic condition.

The traditional ESS was the initial proposal focused on the removal of the disease, particularly located in the ostiomeatal complex, with enlargement of the natural drainage ostia and maximum preservation of the sinonasal mucosa. The procedure quickly developed into dissection and more extensive resections, including polypoid tissue, osteitis, and enlargement of other natural drainage ostia, when affected. Another objective of the technique is the possibility of allowing further penetration of topical medications postoperatively. For that purpose, larger openings of the paranasal sinuses are necessary.⁴³⁶ However, some authors choose the surgical approach focused only on the transition spaces of sinuses (pre-ostial spaces of natural sinus drainage through which the air circulates and secretions are drained), regardless of disease extent.^{516,517} In this technique, called minimally invasive sinus technique (MIST), the drainage ostia are not extended and the procedure is performed mostly with the microdebrider. At the opposite extreme, a technique called nasalization is used, particularly in the surgical management of severe CRSwNP.⁵¹⁸ It consists of complete sphenoethmoidectomy with mucosal removal associated with total resection of the middle turbinate.

A major obstacle to this discussion is the lack of well-designed comparative studies to allow for a more standardized behavior among surgeons. More importantly, is the lack of a precise understanding of the etiological factors of CRS, as well as the great variability and disease severity among patients. Thus, the inclusion and exclusion criteria of studies often do not take into account such factors as the associated presence or absence of polyps, greater or lesser degree of eosinophilia, intolerance to anti-inflammatory steroids etc. The great deciding factor for surgeons is the endoscopic and tomographic findings.

For these reasons, current guidelines indicate that surgical treatment should be individualized according to the patient's clinical situation,¹ typically correlating greater extent of the disease with a more extensive procedure.

Masterson et al.⁵¹⁹ compared anterior ethmoidectomy with complete ethmoidectomy in 149 patients with CRSwNP undergoing ESS. The three-year follow-up showed polyp recurrence in 12.5% of patients submitted to anterior ethmoidectomy *versus* 4% of those undergoing complete ethmoidectomy. The study also demonstrated that, in expe-

rienced hands, the complication rates are small and do not depend on the extent of the procedure.

More recently, Wu et al.⁵²⁰ evaluated the factors affecting the time to revision surgery in patients with CRSwNP. The authors observed that middle turbinate resection appears to increase the time of effectiveness of endoscopic surgery in these cases. This is in agreement with data previously described by Jankovski et al.⁵¹⁸

Several studies, mainly case series, have demonstrated very high success rates of ESS, as traditionally described (88%, on average).⁵²¹⁻⁵²³ However, recent evaluations showed that, given the high degree of mucosal inflammation, surgical outcomes are worse.⁵²⁴⁻⁵²⁶ Moreover, these patients may have better outcomes with more radical and extensive surgery, such as endoscopic maxillary mega-antrostomy and endoscopic modified Lothrop procedure.⁵²⁷⁻⁵²⁹ Fortunately, technological improvements allow these more radical techniques to be performed safely by endoscopic endonasal approach in patients with CRS recalcitrant to medical treatment and to traditional endoscopic surgery.

The advent of the microdebrider brought great advances in endonasal surgery. By facilitating the removal of structures safely and quickly, in addition to maintaining the operative field clean by constant aspiration of blood and secretions, the microdebrider is an important assistant, especially in cases of extensive polyposis.⁵³⁰ The use of the neuronavigator, especially in cases of extensive surgery or reoperation cases when there are no reliable anatomical parameters, significantly increased the safety of the procedure.⁵³¹ Another technique is the use of balloon sinuplasty.⁵¹¹ The procedure involves inserting a catheter with a balloon of different sizes through the transition space of the paranasal sinuses; after verifying its location in the drainage ostium (transillumination or image), it is used to enlarge the ostia, without tissue resection. The procedure is also feasible for the maxillary, frontal, and sphenoid sinuses, but it is not useful for the ethmoid. The procedure is relatively simple to perform and is theoretically compelling, because there is less trauma to the non-affected intranasal structures and a decreased risk of post-operative scarring. However, the few comparative studies with traditional endoscopic techniques have failed to demonstrate convincing results that would justify its high cost.^{511,532-534}

Many authors consider balloons as instruments and not as a surgical technique, much in the same way as they use the microdebrider or neuronavigator and perform hybrid surgeries. That is, together with traditional endoscopic dissection, for instance, of the ethmoid, balloon catheters are used to dilate the natural drainage ostia of the other paranasal sinuses.⁵³⁵

Postoperative topical treatment

Several products are available for postoperative topical treatment. They can be applied at high or low volumes with high, low, or negative pressure.⁵³⁶ The capacity of the drug to reach the appropriate anatomical region in the paranasal sinuses has been the subject of extensive research in the past five years. Effective topical therapy depends on several factors, including application technique, postoperative sinonasal anatomy, and fluid dynamics (volume, pressure,

position). These combined factors appear to have significant impact on the effectiveness of topical therapy on the affected sinonasal mucosa.⁵³⁷⁻⁵⁴⁰

The mechanical removal of mucus, antigens, pollutants, bacteria, and inflammatory products/biofilms is the goal of the topical treatment. These interventions often depend on high-volume and positive-pressure solutions to provide shearing forces that change the surface tension between liquid and air. However, the same approach may not be suitable for the use of pharmaceutical compositions that require properties aimed at complete distribution in the paranasal sinus, long period of contact with the mucosa for local absorption, and minimal waste.⁵³⁶

It is of utmost importance to continue medical treatment postoperatively in almost all forms of CRS. Currently, nasal saline lavage and topical nasal steroids are recommended after ESS for CRS.^{437,536}

The use of medication directly at the disease site has the advantage of allowing high local doses and minimizing side effects.⁵³⁷

The topical solution distribution into the non-operated sinuses appears to be limited. Thus, ESS is essential to allow effective topical distribution to the paranasal sinuses.¹ The postoperative distribution is superior with positive-pressure, high-volume devices.⁵³⁸⁻⁵⁴⁰ Low-volume sprays and drops show poor distribution, and should be considered only as treatment for the nasal cavity, especially before the ESS. There are limited data on the exact volume necessary to allow complete distribution. Among the topical therapies used in the postoperative period of ESS, the following are noteworthy:

Topical corticosteroids

There are four randomized, double-blinded, placebo-controlled, level 1b trials that evaluated the use of topical corticosteroids in the early postoperative period; three of them recommend their use,⁵⁴¹⁻⁵⁴³ and only one did not show any benefits.⁵⁴⁴

CRSsNP

The effectiveness of topical corticosteroids has been investigated in different studies and almost all have shown that CCs can reduce patient symptoms.⁵⁴⁵ Studies have compared the effectiveness of clinical treatment in patients not submitted to surgery with clinical treatment after ESS, showing that the latter group presented a better response to treatment and better olfactory function, based on objective and subjective criteria.⁵⁴⁵

In patients with CRSsNP, only those who had undergone prior ESS showed symptom improvement with topical corticosteroid use. When the types of corticosteroids were evaluated, comparing the more recent (mometasone, fluticasone, ciclesonide) with the first-generation drugs (budesonide, betamethasone, triamcinolone, dexamethasone), no significant difference was observed regarding symptoms in either group.¹ A recent Cochrane review has demonstrated that the use of topical corticosteroids in patients with CRSsNP showed greater benefit in symptom control when they were introduced directly in the sinus cavity, instead of using common nasal sprays.⁵⁴⁶

CRSsNP

Topical nasal corticosteroids are safe medications to use in postoperative period of patients with CRSsNP, with significant improvement in symptoms, polyp size and rate of polyp recurrence in the first year after the surgery.⁵⁴⁷

Patients in the postoperative period of sinonasal surgery responded better to topical corticosteroids than those who did not undergo surgery with respect to a decrease in the size of polyps. However, symptom and nasal airflow improvement were not statistically different between the two groups. In a study by Rowe-Jones et al.,⁵⁴¹ 109 patients (77 of whom had polyps) were randomized to receive fluticasone spray postoperatively, starting six weeks after ESS. The change in the visual analog scale and the endoscopic alterations of polyps were significantly better in the fluticasone group in five years, whereas more courses of prednisolone were prescribed in the placebo group in this period.

There appears to be no significant benefit in using newer corticosteroids (mometasone, fluticasone, and ciclesonide) in comparison to the first-generation drugs (budesonide, beclomethasone, triamcinolone) for symptom or polyp reduction.⁵⁴⁷

Topical antibiotics

The use of topical antibiotics is controversial, with disagreement about the choice of antibacterial agent to be used, the dosage, method of use, and whether effectiveness is improved in a cavity postoperatively. Studies have been conducted with topical preparations of tobramycin, mupirocin, neomycin, bacitracin/colimycin, and ciprofloxacin. There is insufficient evidence to support a clear benefit of using topical antibiotics in the postoperative period of ESS.⁴³⁷

Nasal irrigation with saline solution

Many theories about the potential physiological benefit of using nasal saline solution irrigation have been proposed, such as improvement in mucus clearance, increased ciliary beat activity, and break-up and removal of antigens, biofilm, and inflammatory mediators, as well as direct sinus mucosal protection. The use of nasal saline irrigation has been recommended by otorhinolaryngologists, both as an adjuvant therapy for chronic sinonasal symptoms, as well as to moisten and cleanse sinonasal clots and crusts and promote mucosal healing in the postoperative period.⁴³⁷

Isotonic or hypertonic saline solutions are often used as nasal shower (irrigation with high-volume and low positive-pressure syringes to achieve a greater degree of mechanical debridement), nasal spray, or nebulizer for the treatment of paranasal sinus diseases, especially as an adjuvant to other therapies, such as ESS.^{532,548}

Nasal saline solution irrigation can improve chronic RS symptoms, especially after sinonasal surgery.

Depending on the mode of application, the penetration of isotonic or hypertonic saline solutions in the paranasal sinuses differs, depending on whether patients are submitted to ESS or not.

Wormald et al.⁵⁴⁹ compared the use of nasal spray, nasal

mist, and nasal showers in patients undergoing ESS. Each method was tested using a technetium tracer. The accumulation of radioactivity was assessed in the anterior and posterior nasal cavity, maxillary, sphenoid, and frontal sinuses, in addition to the frontal recess. Although the nasal cavity was well irrigated by the three techniques, the spray was significantly more effective in penetrating the maxillary sinus and frontal recess compared to the other methods. The sphenoid and frontal sinuses were poorly irrigated by all three methods.

The nasal shower effectiveness after surgery was evaluated in a blinded RCT. Nasal showers were used by 22 patients after surgery on one side of the nasal cavity, three times a day for six weeks. The opposite nasal cavity was not irrigated. The presence of adhesions, polyps, crusts, secretions, or edema was evaluated three weeks and three months after surgery. At three weeks, the saline solution showers improved the presence of secretion or edema, but had no effect on adhesion or crusts. At three months, there were no significant differences between both nasal cavities.⁵⁵⁰

A study that evaluated three randomized trials in patients after sinonasal endoscopic surgery demonstrated that two of them obtained better outcomes with intranasal saline solution when compared with the group without irrigation, whereas the third showed no difference in symptom scores between patients who used hypertonic saline solution and those without irrigation. Patients who used hypertonic saline solution had more pain. In general, normal saline solutions are well tolerated. Side effects, including nasal discomfort, nasal discharge, epistaxis, headache, and earache are rare. Most studies show improvement in symptoms and quality of life with the use of nasal irrigation, but whether the hypertonic saline solution is superior to the isotonic solution remains unclear.⁵⁵¹

Rudmik et al.⁵⁵² reviewed six studies on care after ESS and found that most of them showed improvement in symptom scores using saline solutions postoperatively. Among these studies, the one by Liang et al.⁵⁵³ compared irrigations with saline solutions combined with postoperative debridement *versus* debridement alone, and found that postoperative debridement combined with the use of saline solution irrigation significantly improved the endoscopic appearance and symptoms in patients with mild CRS, although no improvement was observed in moderate and severe cases. The authors concluded that nasal irrigation with saline solution is well tolerated and improves the endoscopic appearance and early postoperative symptoms, with evidence level 1b and 2b.⁵⁵² Nasal lavages are therefore recommended for CRS in the postoperative period in adults.

Others

- **Surfactants:** There are no RCTs to recommend the use of surfactants (including baby shampoo) postoperatively.^{554,555}
- **Antifungals:** No benefit was observed in RCT or systematic reviews on the use of topical antifungals in the postoperative period of CRS.^{437,486}
- **Furosemide:** Based on current data of long-term postoperative period of nasal surgery, treatment with furosemide is not recommended.⁵⁵⁶

- **Capsaicin:** RCT was performed in patients at the postoperative period of ESS using capsaicin (cotton swab) into the middle meatus of both nostrils for 20 minutes once a week for five weeks, comparing them with the control group. The treated group showed improved staging of polyposis; this is a grade C recommendation.^{1,556}

Comments

Nasal lavage with isotonic saline solution may be used in the immediate postoperative period of CRS, as well as topical nasal corticosteroids, which can be initiated two to three weeks after surgery, or after the disappearance of crusts. There are no relevant data in the literature to support the use of other topical nasal agents in the postoperative period of CRS.

Postoperative systemic treatment

Postoperative systemic treatment of CRS with or without nasal polyps may involve the use of corticosteroids and antibiotics, and is discussed below.

Corticosteroids

After the surgical treatment of CRS, systemic corticosteroids may be used in mainly two ways: in short doses, between seven and 14 days, with a maintenance dose throughout treatment, or for longer periods, using decreasing doses.^{556,557} The main role of corticosteroids in this type of disease is to reduce mucosal inflammation, thus providing better surgical results. However, these drugs are still avoided by many surgeons due to their potential side effects.

A phase 1b trial (randomized, double-blinded, placebo-controlled), performed by Wright and Agrawal,⁵⁰⁷ evaluated the endoscopic findings in the postoperative period in patients with CRSwNP, who used 30 mg daily of prednisone five days before the surgical procedure, plus 30 mg a day for nine days postoperatively. In addition to a better intraoperative status in the patients taking corticosteroids, the results showed significant improvement in endoscopic mucosal appearance up to six months postoperatively, more evident in the second week. It is worth mentioning that, regarding postoperative symptoms, there was no difference between the treatment groups. Both groups (placebo and prednisone) showed significant improvement postoperatively when compared with the preoperative period.

After careful assessment of the risks and benefits, the use of oral corticosteroids for short periods of time can be considered, aiming to minimize inflammation during the healing period and prevent complications associated with mucosal edema and crust formation, especially in cases of CRSwNP.⁵⁵⁶

Regarding the use of corticosteroids in the postoperative period of patients with AFRS, many non-placebo-controlled studies showed a positive effect.⁵⁵⁸⁻⁵⁶⁰ Rupa et al.,⁵⁶¹ in a prospective, randomized, double-blinded, placebo-controlled trial (level 1b), compared the outcomes of patients submitted to surgery with a diagnosis of AFRS. One group of patients received 50 mg of prednisone orally a day for six weeks and subsequently, decreased doses for six weeks,

while another group was given placebo for 12 weeks. After this period, a significant improvement was observed regarding symptoms and at the endoscopic examination in the group that had used corticosteroids. All patients received topical corticosteroids and systemic antifungal (itraconazole) for 12 weeks. At 18 months postoperatively, patients who had interrupted the treatment, including topical corticosteroids, had disease recurrence. It is therefore difficult to assess whether treatment with oral corticosteroids for 12 weeks had an impact on evolution at 18 months.

Antibiotics

The purpose of antibiotic use postoperatively is to prevent infection of the secretions retained in the paranasal sinuses immediately after surgery. If there is purulent secretion during the surgical procedure, antibiotics should be prescribed, based on the culture and sensitivity test. Otherwise, antibiotics effective against the most common pathogens should be employed.⁵⁵⁷ A meta-analysis and systematic review published in 2011, that included three articles, demonstrated that the prophylactic use of antibiotics in the postoperative period did not result in statistically significant reduction of infection, endoscopic scores, and symptoms.⁵⁶² It is worth mentioning the randomized, double-blinded, placebo-controlled trial (level 1b) conducted by Albu et al.,⁵⁶³ which evaluated the protocol for the use of 625 mg of amoxicillin twice daily for two weeks postoperatively. The results showed improvement of symptoms within the first five days and of the endoscopic appearance within the first 12 days. Additionally, there was a significant reduction in crust formation. Another level 1b study assessed the use of antibiotics for just two days postoperatively and observed no effective result.⁵⁶⁴

There is only one level 1b study, published in 1995, which found benefits regarding the use of macrolides for long periods (12 weeks) postoperatively.⁵⁶⁵ As there are no other specific studies that assessed the effects of this medication specifically in the postoperative period, macrolides have been used for a long time, regardless of the postoperative period. In this sense, the evidence is contradictory; in light of current knowledge, it points to possible positive results in patients with CRSsNP and normal IgE.^{426,427}

Comments

In spite of the scarcity of literature data on antibiotic effectiveness in the postoperative period of endoscopic sinus surgery, it is believed that they can improve symptoms and endoscopic appearance, if used for a longer period (at least 14 days), but there is no conclusive data about the duration of these benefits. In general, penicillin derivatives, particularly amoxicillin-clavulanic acid and cefuroxime-axetil are the most commonly used.

Antifungals

Kennedy et al.²⁰⁷ performed a single controlled trial (1b) comparing the use of the antifungal terbinafine with placebo in patients with chronic RS with nasal polyps who showed (or did not show) positivity for fungi. The results demonstrated that terbinafine did not improve symptoms or post-operative radi-

ological findings, even in cases where the culture was positive for fungi. A number of other non-controlled trials showed conflicting results regarding the postoperative use of systemic antifungals in CRS, with some of them showing significant side effects of such medication.^{492,493,561,566} Based on current data, the use of systemic antifungals in the postoperative period of chronic RS with nasal polyps is not recommended.¹

Special aspects of rhinosinusitis in children

Epidemiology

On average, children younger than 5 years of age have between two and seven episodes of upper respiratory tract infections (URTI) per year.^{567,568} If they attend kindergarten and daycare centers, the number episodes increases to 14 per year.⁵⁶⁹ It is estimated that 4% to 7.3% of URIs develop into ABRS, occurring most often in children in their first year of life and those attending daycare.⁵⁷⁰

Paranasal sinuses in the child

Not all paranasal sinuses are developed at birth.

- Frontal sinus: its development starts at 4 years of age, with slow growth thereafter. Only 20% to 30% of children younger than 6 years have a radiographically visible frontal sinus. Over 85% will have frontal sinus pneumatization on CT by the age of 12.⁵⁷¹
- Ethmoid and maxillary sinuses: they are already developed enough at birth; these are the ones that have clinical significance in RS. The ethmoid sinuses grow rapidly until 7 years of age, and their development is complete at around 15-16 years of age. The maxillary sinus usually is pneumatized at birth and its volume is approximately 2 mL at 2 years of age, 10 mL at 9 years, and 14.8 mL at 15 years.⁵⁷² Most of the growth after 12 years of age occurs in the lower portion, with pneumatization of the alveolar process occurring after the secondary dentition. The floor of the maxillary sinus, which is higher than the nasal cavity floor level in children, will lower, and it will be approximately 4-5 mm inferior to the nasal cavity in adult life.
- Sphenoid sinus: at birth, the sphenoid sinus is a small evagination of the sphenoethmoidal recess. At age 7 years, it extends posteriorly, and at age 8, around 85% of patients have pneumatization that is visible on CT;⁵⁷¹ it reaches full development at approximately 15 years, but it can continue to grow into adulthood.

Definition and classification of ARS in children

ARS is defined and classified in children in the same way as it is in adults.

Diagnosis

The clinical diagnosis of ARS in children is not easy to establish. Many symptoms are common to other childhood diseases such as colds, flu, and allergic rhinitis. Additionally, there

are limitations and difficulties in the clinical examination of the pediatric population.

Most frequent signs and symptoms

Studies in children with ARS show that the clinical picture often includes fever (50% to 60%), rhinorrhea (71% to 80%), cough (50% to 80%), and pain (29% to 33%),³⁸ in addition to retronasal secretion and nasal obstruction.¹⁹ In children up to preschool age, the pain symptom has low prevalence, being replaced by cough, whereas in schoolchildren and adolescents, pain becomes more common.

Although there are not many studies on the subject, most physicians and guidelines recommend that the diagnosis of ABRS should be clinical, based on time of evolution (URTI symptoms lasting more than ten days), abrupt onset of marked symptoms (as early as in the first four days), or symptoms worsening after the initial period of improvement during a URTI, known as “double worsening”. High fever, abundant nasal purulent discharge, periorbital edema, and facial pain may be part of the signs and symptoms.^{1,19,573-576}

Clinical examination

In addition to the signs and symptoms mentioned above, nasal endoscopy helps in the diagnosis and differentiates between viral and bacterial cases by allowing visualization of nasal and nasopharynx secretions. When it identifies purulent secretion draining from the middle meatus it establishes the diagnosis for acute bacterial RS. However, it is not always easy to perform in children. Moreover, despite the high specificity, it has a low degree of sensitivity, as a negative examination does not exclude the diagnosis of ABRS.

Imaging study

There is practically a consensus, among all the most recently published guidelines, that the diagnosis of ARS should not be based on radiological examinations, particularly plain radiographs.^{1,573,576}

Viral processes in children often involve the paranasal sinuses. Children with symptoms of URTI for at least six days of clinical picture usually show signs of abnormalities in all sinuses: maxillary and ethmoid, sphenoid, and frontal, in order of frequency. The opacification is nonspecific and may occur in viral, bacterial, allergic processes, as well as in tumors, or simply reflect a lack of sinus development.

CT studies in children with a clinical picture suggestive of ARS demonstrated that even the most important clinical pictures show significant alteration regression after two weeks.⁵⁷⁷ Indications for CT in acute sinus pictures should, therefore, be reserved for patients who do not improve and whose symptoms persist after appropriate therapy, as well as in those with suspected complications.⁵⁷⁴

Differential diagnosis

The main differential diagnosis of ARS in children is infectious acute adenoiditis, as it might show very similar signs and symptoms, including cough and posterior secretion. There is probably a high percentage of association between

the two diseases, although this differentiation is difficult to attain in clinical practice. Studies demonstrated that, of children with symptoms for over ten days, approximately 89.2% have ARS, whereas 19.2% have associated adenoiditis. Adenoiditis alone is present in approximately 7% of the children. Younger patients (2 to 5 years old) have a higher frequency of ARS/adenoiditis association.⁵⁷⁸ In clinical practice, differential diagnosis is not always necessary, as treatment is the same for both entities.

Another less important differential diagnosis is that of nasal foreign body. In these cases, the secretion is usually fetid and almost always unilateral.

Bacteriology

The most common etiologic agents in ABRS in children are *S. pneumoniae*, *H. influenza*, *M. catarrhalis*, *S. pyogenes*, and anaerobic bacteria.^{19,579}

ARS drug treatment in children

Most are self-limited, resolving spontaneously.¹

Antibiotics

The results of a meta-analysis suggest that the rate of resolution and improvement in ARS between seven and 15 days is slightly higher when antibiotics are used.⁵⁷⁹ For this reason, it is believed that antibiotics should be reserved for more severe cases or in the presence of concomitant diseases, which could be exacerbated by ARS, such as asthma and chronic bronchitis.^{1,573,575} However, there is yet no universal consensus on the type of antibiotics to be used in ARS.

In general, amoxicillin (40 mg/kg/day or 80 mg/kg/day) is still considered a sensible initial treatment in most studies. Amoxicillin/clavulanate and cephalosporins are considered good options against beta-lactamase producers,¹ and must be indicated in case of a first treatment failure.

Similar to the recommendations for acute otitis media, in ARS there is also the option of a single dose of ceftriaxone 50 mg/kg IV (intravenous) or IM (intramuscular) for children who are vomiting, unable to tolerate oral medication.⁶²⁻⁶⁴ If there is clinical improvement in 24 hours, treatment is completed with an oral antibiotic.⁵⁷⁵

For patients allergic to penicillin, there is some controversy among the latest international guidelines. Some consider trimethoprim-sulfamethoxazole, macrolides, and clindamycin to be good options¹ in these situations. Others do not recommend the use of trimethoprim-sulfamethoxazole and macrolides due to the increasing resistance of *pneumococci* and *H. influenzae* to these drugs, suggesting a quinolone, such as levofloxacin, as an alternative, especially in older children, even considering toxicity, cost, and emerging resistance.^{580,581}

There are no reviews on the optimal treatment duration. Recommendations based on clinical observations have varied widely, from 10 to 28 days of treatment. One suggestion has been to maintain therapy for seven days after symptom resolution.⁵⁸²

Intranasal corticosteroids

Intranasal corticosteroids for three weeks combined with antibiotic therapy appears to have advantages in relation to ARS treatment in children and adolescents compared to antibiotic use alone, especially regarding cough and nasal secretion.^{85,92,95}

A single double-blinded, randomized trial in patients older than 12 years found that a double dose of intranasal corticosteroids, as the sole drug used, was more effective for ARS control than treatment with antibiotics alone.⁸⁵

Adjuvant therapy

A systematic review of the literature regarding the efficacy of oral or intranasal decongestants, antihistamines, and saline irrigation has shown no evidence of efficacy in children with ARS.¹⁰⁰

Recurrent ARS (rARS)

Most authors agree that rARS is defined by acute episodes lasting less than 30 days, with intervals of at least ten days when the patient is totally asymptomatic. According to some authors, the patient should have at least four episodes a year to meet the criteria of recurrence.⁵⁷⁵

As in chronic conditions, systemic causes should be sought and ruled out. The investigation should include allergic processes, by performing specific tests; immunoglobulin deficiencies, with quantitative determinations, particularly for IgA and IgG; CF; gastroesophageal reflux; and ciliary diseases.⁵⁸³ Pharyngeal tonsil hypertrophy, even when mild, should also be considered because of the possibility of the tonsils acting as a reservoir for pathogens. Although of little relevance in children, anatomical factors, such as concha bullosa and septal deviation should also be ruled out. In these cases, CT, nasal endoscopy and/or MRI can assist in the diagnosis of obstructive processes and malformations.

The bacteriology is the same of ARS and, therefore, the treatment of the acute phase should follow the same principles.⁵⁸⁴ Unfortunately, it must be acknowledged that several antibiotic agents taken in a short intervals of time can lead to bacterial resistance. Prophylaxis with antimicrobials should be reserved for exceptional cases, usually when underlying diseases are confirmed, particularly immunodeficiencies.

Annual vaccination for *influenza* and pneumococcal vaccine are recommended as general prophylactic measures. In cases where allergic rhinitis or gastroesophageal reflux is present at the same time, the frequency of acute events decreases when the associated disease is treated. Several studies have demonstrated that immunostimulatory medications, such as bacterial lysates, help to control recurrent viral and bacterial RTIs, and may be an adjunct treatment in rARS control.¹¹³

Particularities of chronic rhinosinusitis in children

CRS is not as frequently studied in children as it is in adults, and its prevalence has not yet been fully established. It is

believed that several factors contribute to the disease, including inflammatory and bacteriological components, and that the pharyngeal tonsil is an important consideration in this age group. Treatment is mainly medical, and surgical therapy is reserved for a minority of patients.

Definition

CRS is defined in children, similarly to adults, as inflammation of the nasal mucosa and paranasal sinuses having a duration equal to or longer than 12 weeks without improvement periods.¹

Physiopathology

Anatomical factors

It is unclear whether the anatomical abnormalities somehow contribute to the development and maintenance of CRS in children. Studies suggest that, in spite of the common occurrence of these anatomical factors (concha bullosa, concha hypertrophy, septal deviation, among others), they do not appear to be correlated with the presence of CRS or the degree of involvement.¹

Role of adenoids

Studies related to the role of adenoids in CRS are being conducted, but are still limited. They suggest a role for adenoids in patients with CRS, both from the bacteriological and immunological viewpoints. All of them confirmed the hypothesis that, regardless of the size of the pharyngeal tonsil, they can be a reservoir for bacterial sinus infections.^{585,586}

Allergic rhinitis

Apparently, children with CRS have positive radioallergen sorbent tests (RAST) for IgE, in the same proportion as the general population, suggesting that a causal relationship between CRS and allergies in children remains controversial and probably does not exist.^{587,588}

Asthma

Asthma is a disease commonly associated with CRS in pediatric patients. However, the limitations of most available studies include lack of good controls or randomization to different treatment modalities and, therefore, the association between CRS and asthma in children should be further studied.

GERD

GERD has also been associated with RS in several studies. Despite some evidence demonstrating an association between GERD and CRS, more controlled trials are needed to reinforce this association and validate it. Thus, routine antireflux treatment of children with CRS is not justified.¹

Immunodeficiency

Studies in children with rARS (recurrent acute rhinosinusitis) and CRS have shown reasonable percentage of immune dysfunction, including decreased levels of IgG3, IgA, and IgG1, with poor response to pneumococcal vaccine and low levels of immunoglobulin in response to normal vaccines. Therefore, it is recommended to evaluate immune function in children with recurrent CRS through immunoglobulin measurements and titrations of tetanus and diphtheria, as well as of pneumococcus. If responses are abnormal, examinations should be repeated after pneumococcal vaccination.¹

PCD

The diagnosis should be suspected in a child with atypical asthma, bronchiectasis, chronic productive cough, CRS, and severe otitis media (especially chronic drainage in children with tubes). Specific diagnosis requires examination of cilia by electron microscopy, which is usually available in specialized centers.¹

CF

The prevalence of CRS in these patients is high and nasal polyps occur between 7% and 50% of affected individuals.^{589,590} This is one of the few causes of NP in children and the finding is unusual; when present, it should lead to a suspicion of CF or AFRS. This also shows a fairly unique clinical picture, which includes NP and characteristic CT and MRI images.⁵⁹¹

Clinical picture and diagnosis

The clinical diagnosis of chronic RS in children is still considered a challenge, as it often overlaps with those of other common childhood illnesses, such as viral infections of the upper respiratory tract, hypertrophy of the pharyngeal tonsils/ad-enoiditis, and allergic rhinitis. The most important signs and symptoms include nasal obstruction/stiffness/congestion, rhinorrhea (anterior/posterior); less commonly facial pain/pressure, and cough. CT and endoscopic examination can show relevant changes in the nose, paranasal sinuses and mucosa.¹

Imaging tests

Studies that have assessed the incidence of abnormalities in the paranasal sinuses on CT obtained for clinical reasons unrelated to the CRS in children have shown a percentage of radiographic sinus abnormalities ranging from 18%^{2,3} to 45%, similar to those found in children with CRS symptoms. This demonstrates that the significance of imaging tests is relative and must always be considered together with the clinical picture.

Bacteriology

There are few studies on the bacteriology of CRS in children. Microorganisms identified intraoperatively or in aspirates include: *S. alpha hemolytic*, *S. aureus*, *S. pneumoniae*, *H. influenzae*, and *M. catarrhalis*, as well as anaerobic organisms such as bacteroides and Brook I fusobacteria.⁵⁹²⁻⁵⁹⁴

Treatment

Drug therapy

Existing studies demonstrate that short-term antibiotic therapy in children with CRS is not justifiable.¹ Conversely, both nasal corticosteroids and saline solution have shown to be beneficial and are considered the first-line treatment for this disease, whether with or without nasal polyps.^{595,596}

Surgical treatment

The surgical approach should always be reserved for special cases, i.e., children who have not responded to appropriate medical treatment. Studies have shown significant clinical and quality of life improvement, without negative effects in relation to facial osteoskeletal sequelae.⁵⁹⁷ Unfortunately, most studies supporting this recommendation are not prospective and randomized. In general, the surgical approach, when indicated, may consist first of an adenoidectomy⁵⁹⁷ with maxillary sinus lavage.⁵⁹⁸ The surgery can be performed with or without balloon dilation,^{599,600} followed by endoscopic paranasal sinus surgery in cases of recurrence of symptoms.⁶⁰¹ In cases of children with CF, NP, antrochoanal polyps or AFRS, endoscopic surgery is the first option. Perhaps future studies, comparing the several methods of treatment with standardized pre- and postoperative questionnaire, can guide the best therapeutic approach in patients with CRS.

References

1. Fokkens WJ, Lund VJ, Mullol J, Bachert C, Alobid I, Baroody F, et al. European position paper on rhinosinusitis 4 and nasal polyps 2012. *Rhinology Suppl.* 2012;23:1-298.
2. Kosugi EM, Chen VG, Fonseca VMGD, Cursino MMP, Mendes Neto JA, Gregorio LC. Translation, cross-cultural adaptation and validation of SinoNasal Outcome Test (SNOT): 22 to Brazilian Portuguese. *Braz J Otorhinolaryngol.* 2011;77:663-9.
3. Hopkins C. Patient reported outcome measures in rhinology. *Rhinology.* 2009;47:10-7.
4. Morley AD, Sharp H. A review of sinonasal outcome scoring systems - which is best? *Clin Otolaryngol.* 2006;31:103-9.
5. Babar-Craig H, Gupta Y, Lund VJ. British Rhinological Society audit of the role of antibiotics in complications of acute rhinosinusitis: a national prospective audit. *Rhinology.* 2010;48:344-7.
6. Neumark T, Brudin L, Engstrom S, Molstad S. Trends in number of consultations and antibiotic prescriptions for respiratory tract infections between 1999 and 2005 in primary healthcare in Kalmar County, Southern Sweden. *Scand J Prim Health Care.* 2009;27:18-24.
7. van Gageldonk-Lafeber AB, Heijnen ML, Bartelds AI, Peters MF, van der Plas SM, Wilbrink B. A case-control study of acute respiratory tract infection in general practice patients in The Netherlands. *Clin Infect Dis.* 2005;41:490-7.
8. Rank MA, Wollan P, Kita H, Yawn BP. Acute exacerbations of chronic rhinosinusitis occur in a distinct seasonal pattern. *J Allergy Clin Immunol.* 2010;126:168-9.
9. Eccles R. An explanation for the seasonality of acute upper respiratory tract viral infections. *Acta Otolaryngol.* 2002;122:183-91.

10. Suonpaa J, Antila J. Increase of acute frontal sinusitis in south-western Finland. *Scand J Infect Dis*. 1990;22:563-8.
11. Bhattacharyya N. Air quality influences the prevalence of hay fever and sinusitis. *Laryngoscope*. 2009;119:429-33.
12. Trevino RJ. Air pollution and its effect on the upper respiratory tract and on allergic rhinosinusitis. *Otolaryngol Head Neck Surg*. 1996;114:239-41.
13. Zuskin E, Mustajbegovic J, Schachter EN, Kern J, Deckovic-Vukres V, Pucarin-Cvetkovic J, et al. Respiratory findings in pharmaceutical workers. *Am J Ind Med*. 2004;46:472-9.
14. Jaakkola MS, Jaakkola JJ. Office equipment and supplies: a modern occupational health concern? *Am J Epidemiol*. 1999;150:1223-8.
15. Duclos P, Sanderson LM, Lipsett M. The 1987 forest fire disaster in California: assessment of emergency room visits. *Arch Environ Health*. 1990;45:53-8.
16. Alkire BC, Bhattacharyya N. An assessment of sinonasal anatomic variants potentially associated with recurrent acute rhinosinusitis. *Laryngoscope*. 2010;120:631-4.
17. Bomeli SR, Branstetter BFT, Ferguson BJ. Frequency of a dental source for acute maxillary sinusitis. *Laryngoscope*. 2009;119:580-4.
18. Mathew AL, Pai KM, Sholapurkar AA. Maxillary sinus findings in the elderly: a panoramic radiographic study. *J Contemp Dent Pract*. 2009;10:E041-8.
19. Lin SW, Wang YH, Lee MY, Ku MS, Sun HL, Lu KH, et al. Clinical spectrum of acute rhinosinusitis among atopic and nonatopic children in Taiwan. *Int J Pediatr Otorhinolaryngol*. 2012;76:70-5.
20. Eccles R. Mechanisms of the symptoms of rhinosinusitis. *Rhinology*. 2011;49:131-8.
21. Melvin TA, Lane AP, Nguyen MT, Lin SY. Allergic rhinitis patients with recurrent acute sinusitis have increased sinonasal epithelial cell TLR9 expression. *Otolaryngol Head Neck Surg*. 2010;142:659-64.
22. Vlastos I, Athanasopoulos I, Mastronikolis NS, Panogeorgou T, Margaritis V, Naxakis S, et al. Impaired mucociliary clearance in allergic rhinitis patients is related to a predisposition to rhinosinusitis. *Ear Nose Throat J*. 2009;88:E17-9.
23. Ulanovski D, Barenboim E, Raveh E, Grossman A, Azaria B, Shpitzer T. Sinusitis in pilots of different aircraft types: is allergic rhinitis a predisposing factor? *Am J Rhinol*. 2008;22:122-4.
24. Mbarek C, Akrouf A, Khamassi K, Ben Gamra O, Hariga I, Ben Amor M, et al. Recurrent upper respiratory tract infections in children and allergy. A crosssectional study of 100 cases. *Tunis Med*. 2008;86:358-61.
25. Schatz M, Zeiger RS, Chen W, Yang SJ, Corrao MA, Quinn VP. The burden of rhinitis in a managed care organization. *Ann Allergy Asthma Immunol*. 2008;101:240-7.
26. Ciprandi G, Tosca MA, Fasce L. Allergic children have more numerous and severe respiratory infections than non-allergic children. *Pediatr Allergy Immunol*. 2006;17:389-91.
27. Naclerio R, Blair C, Yu X, Won YS, Gabr U, Baroody FM. Allergic rhinitis augments the response to a bacterial sinus infection in mice: A review of an animal model. *Am J Rhinol*. 2006;20:524-33.
28. Blair C, Nelson M, Thompson K, Boonlayangoor S, Haney L, Gabr U, et al. Allergic inflammation enhances bacterial sinusitis in mice. *J Allergy Clin Immunol*. 2001;108:424-9.
29. Alho OP. Nasal airflow, mucociliary clearance, and sinus functioning during viral colds: effects of allergic rhinitis and susceptibility to recurrent sinusitis. *Am J Rhinol*. 2004;18:349-55.
30. Kirtsreesakul V, Blair C, Yu X, Thompson K, Naclerio RM. Desloratadine partially inhibits the augmented bacterial responses in the sinuses of allergic and infected mice. *Clin Exp Allergy*. 2004;34:1649-54.
31. Ciprandi G, Ricca V, Tosca M, Landi M, Passalacqua G, Canonica GW. Continuous antihistamine treatment controls allergic inflammation and reduces respiratory morbidity in children with mite allergy. *Allergy*. 1999;54:358-65.
32. Braun JJ, Alabert JP, Michel FB, Quiniou M, Rat C, Coughard J, et al. Adjunct effect of loratadine in the treatment of acute sinusitis in patients with allergic rhinitis. *Allergy*. 1997;52:650-5.
33. Ciprandi G, Buscaglia S, Pesce G, Villaggio B, Bagnasco M, Canonica GW. Allergic subjects express intercellular adhesion molecule 1 (ICAM-1 or CD54) on epithelial cells of conjunctiva after allergen challenge. *J Allergy Clin Immunol*. 1993;91:783-92.
34. Ruoppi P, Seppa J, Nuutinen J. Acute frontal sinusitis: etiological factors and treatment outcome. *Acta Otolaryngol*. 1993;113:201-5.
35. Savolainen S. Allergy in patients with acute maxillary sinusitis. *Allergy*. 1989;44:116-22.
36. Iseh KR, Makusidi M. Rhinosinusitis: a retrospective analysis of clinical pattern and outcome in north western Nigeria. *Ann Afr Med*. 2010;9:20-6.
37. Pant H, Ferguson BJ, Macardle PJ. The role of allergy in rhinosinusitis. *Current Opinion Otolaryngol Head Neck Surg*. 2009;17:232-8.
38. Wang DY, Wardani RS, Singh K, Thanaviratnanich S, Vicente G, Xu G, et al. A survey on the management of acute rhinosinusitis among Asian physicians. *Rhinology*. 2011;49:264-71.
39. Tamashiro E, Xiong G, Anselmo-Lima WT, Kreindler JL, Palmer JN, Cohen NA. Cigarette smoke exposure impairs respiratory epithelial ciliogenesis. *Am J Rhinol & Allergy*. 2009;23:117-22.
40. De S, Leong SC, Fenton JE, Carter SD, Clarke RW, Jones AS. The effect of passive smoking on the levels of matrix metalloproteinase 9 in nasal secretions of children. *Am J Rhinol Allergy*. 2011;25:226-30.
41. Bush A, Chodhari R, Collins N, Copeland F, Hall P, Harcourt J, et al. Primary ciliary dyskinesia: current state of the art. *Arch Dis Child*. 2007;92:1136-40.
42. Holzmann D, Felix H. Neonatal respiratory distress syndrome - a sign of primary ciliary dyskinesia? *Eur J Pediatr*. 2000;159:857-60.
43. Hossain T, Kappelman MD, Perez-Atayde AR, Young GJ, Huttner KM, Christou H. Primary ciliary dyskinesia as a cause of neonatal respiratory distress: implications for the neonatologist. *J Perinatol*. 2003;23:684-7.
44. Pedersen M, Mygind N. Rhinitis, sinusitis and otitis media in Kartagener's syndrome (primary ciliary dyskinesia). *Clin Otolaryngol Allied Sci*. 1982;7:373-80.
45. Mygind N, Pedersen M. Nose, sinus- and ear-symptoms in 27 patients with primary ciliary dyskinesia. *Eur J Respir Dis Suppl*. 1983;127:96-101.
46. Bonham GS, Wilson RW. Children's health in families with cigarette smokers. *Am J Public Health*. 1981;71:290-3.
47. Lin SY, Reh DD, Clipp S, Irani L, Navas-Acien A. Allergic rhinitis and secondhand tobacco smoke: a population-based study. *Am J Rhinol Allergy*. 2011;25:e66-71.
48. Brook I. Effects of exposure to smoking on the microbial flora of children and their parents. *Int J Pediatr Otorhinolaryngol*. 2010;74:447-50.
49. Brook I, Gober AE. Effect of smoking cessation on the microbial flora. *Arch Otolaryngol Head Neck Surg*. 2007;133:135-8.
50. Pacheco-Galvan A, Hart SP, Morice AH. Relationship between gastroesophageal reflux and airway diseases: the airway reflux paradigm. *Arch Bronconeumol*. 2011;47:195-203.
51. Flook EP, Kumar BN. Is there evidence to link acid reflux with chronic sinusitis or any nasal symptoms? A review of the evidence. *Rhinology*. 2011;49:11-6.
52. Adams TB, Wharton CM, Quilter L, Hirsch T. The association between mental health and acute infectious illness among a national sample of 18- to 24-year-old college students. *J Am Coll Health*. 2008;56:657-63.
53. Principi N, Esposito S. New insights into pediatric rhinosinusitis. *Pediatr Allergy Immunol*. 2007;18:7-9.

54. Loughlin J, Poullos N, Napalkov P, Wegmuller Y, Monto AS. A study of *influenza* and *influenza*-related complications among children in a large US health insurance plan database. *Pharmacoeconomics*. 2003;21:273-83.
55. Williams JW, Jr., Simel DL, Roberts L, Samsa GP. Clinical evaluation for sinusitis. Making the diagnosis by history and physical examination. *Ann Intern Med*. 1992;117:705-10.
56. Damm M, Quante G, Jungehuelsing M, Stennert E. Impact of functional endoscopic sinus surgery on symptoms and quality of life in chronic rhinosinusitis. *Laryngoscope*. 2002;112:310-5.
57. Spector SL, Bernstein IL, Li JT, Berger WE, Kaliner MA, Schuller DE, et al. Parameters for the diagnosis and management of sinusitis. *J Allergy Clin Immunol*. 1998;102:S107-44.
58. Rosenfeld RM, Andes D, Bhattacharyya N, Cheung D, Eisenberg S, Ganiats TG, et al. Clinical practice guideline: Adult sinusitis. *Otolaryngol Head Neck Surg*. 2007;137:S1-31.
59. Gwaltney JM Jr, Hendley JO, Simon G, Jordan WS Jr. Rhinovirus infections in an industrial population. II. Characteristics of illness and antibody response. *JAMA* 1967;202:494-500.
60. Hansen JG. Management of acute rhinosinusitis in Danish general practice: a survey. *Clin Epidemiol*. 2011;3:213-6.
61. Desrosiers M, Evans GA, Keith PK, Wright ED, Kaplan A, Bouchard J, et al. Canadian clinical practice guidelines for acute and chronic rhinosinusitis. *Allergy Asthma Clin Immunol*. 2011;7:2.
62. Lacroix JS, Ricchetti A, Lew D, Delhumeau C, Morabia A, Stalder H, et al. Symptoms and clinical and radiological signs predicting the presence of pathogenic bacteria in acute rhinosinusitis. *Acta Otolaryngol*. 2002;122:192-6.
63. Lindbaek M, Hjortdahl P, Johnsen UL. Use of symptoms, signs, and blood tests to diagnose acute sinus infections in primary care: comparison with computed tomography. *Fam Med*. 1996;28:183-8.
64. Lindbaek M, Hjortdahl. The clinical diagnosis of acute purulent sinusitis in general practice-a review. *Br J Gen Pract*. 2002;52:491-5.
65. Cain WS. Testing olfaction in a clinical setting. *Ear Nose & Throat J*. 1989;68:316, 22-8.
66. Cardesin A, Alobid I, Benitez P, Sierra E, de Haro J, Bernal-Sprekelsen M, et al. Barcelona Smell Test - 24 (BAST-24): validation and smell characteristics in the healthy Spanish population. *Rhinology*. 2006;44:83-9.
67. Fornazieri MA, Doty RL, Santos CA, Pinna FR, Bezerra TFP, Voegels RL. A new cultural adaptation of the University of Pennsylvania Smell Identification Test. *Clinics*. 2013;68:65-8.
68. Berg O, Carenfelt C. Analysis of symptoms and clinical signs in the maxillary sinus empyema. *Acta Otolaryngol*. 1988;105:343-9.
69. Hansen JG, Hojbjerg T, Rosborg J. Symptoms and signs in culture-proven acute maxillary sinusitis in a general practice population. *APMIS*. 2009;117:724-9.
70. Berger G, Berger RL. The contribution of flexible endoscopy for diagnosis of acute bacterial rhinosinusitis. *Eur Arch Otorhinolaryngol*. 2011;268:235-40.
71. Hirshoren N, Hirschenbein A, Eliashar R. Risk stratification of severe acute rhinosinusitis unresponsive to oral antibiotics. *Acta Otolaryngol*. 2010;130:1065-9.
72. Cals JW, Schot MJ, de Jong SA, Dinant GJ, Hopstaken RM. Point of care C-Reactive Protein testing and antibiotic prescribing for respiratory tract infections: a randomized controlled trial. *Ann Fam Med*. 2010;8:124-33.
73. Hansen JG, Lund E. The association between paranasal computerized tomography scans and symptoms and signs in a general practice population with acute maxillary sinusitis. *APMIS*. 2011;119:44-8.
74. Lanz MJ, Prendes S, Peyrou N, Toledo G, Ferrer CM. Nasal nitric oxide as a noninvasive marker in the antibiotic treatment of acute bacterial sinusitis. *J Allergy Clin Immunol*. 2008;121:530-1.
75. Wittkopf ML, Beddow PA, Russell PT, Duncavage JA, Becker SS. Revisiting the interpretation of positive sinus CT findings: a radiological and symptom-based review. *Otolaryngol Head Neck Surg*. 2009;140:306-11.
76. Triulzi F, Zirpoli S. Imaging techniques in the diagnosis and management of rhinosinusitis in children. *Pediatr Allergy Immunol*. 2007 Nov; 18 Suppl 18:46-9.
77. Young J, De Sutter A, Merenstein D, van Essen GA, Kaiser L, Varonen H, et al. Antibiotics for adults with clinically diagnosed acute rhinosinusitis: a meta-analysis of individual patient data. *Lancet*. 2008;371:908-14.
78. Merenstein D, Whittaker C, Chadwell T, Wegner B, D'Amico F. Are antibiotics beneficial for patients with sinusitis complaints? A randomized double-blind clinical trial. *J Fam Pract*. 2005;54:144-51.
79. Benninger MS, Sedory Holzer SE, Lau J. Diagnosis and treatment of uncomplicated acute bacterial rhinosinusitis: summary of the Agency for Health Care Policy and Research evidence-based report. *Otolaryngol Head Neck Surg*. 2000;122:1-7.
80. Meltzer EO, Bachert C, Staudinger H. Treating acute rhinosinusitis: comparing efficacy and safety of mometasone furoate nasal spray, amoxicillin, and placebo. *J Allergy Clin Immunol*. 2005;116:1289-95.
81. de Ferranti SD, Ioannidis JP, Lau J, Anninger WV, Barz M. Are amoxicillin and folate inhibitors as effective as other antibiotics for acute sinusitis? A meta-analysis. *BMJ*. 1998; 317:632-7.
82. Ip S, Fu L, Balk E, Chew P, Devine D, Lau J. Update on acute bacterial rhinosinusitis. *Evid Rep Technol Assess (Summ)*. 2005;124:1-3.
83. Tan T, Little P, Stokes T, Guideline Development Group. Antibiotic prescribing for self limiting respiratory tract infections in primary care: summary of NICE guidance. *BMJ*. 2008;337:a437.
84. Small CB, Bachert C, Lund VL, Moscatello A, Nayak AS, Berger WE. Judicious antibiotic use and intranasal corticosteroids in acute rhinosinusitis. *Am J Med*. 2007;120:289-94.
85. Barlan IB, Erkan E, Bakir M, Berrak S, Basaran M. Intranasal budesonide spray as an adjunct to oral antibiotic therapy for acute sinusitis in children. *Ann Allergy Asthma Immunol*. 1997;78:598-601.
86. Yilmaz G, Varan B, Yilmaz T, Gürakan B. Intranasal budesonide spray as an adjunct to oral antibiotic therapy for acute sinusitis in children. *Eur Arch Otorhinolaryngol*. 2000;257:256-9.
87. Meltzer EO, Charous L, Busse WW, Zinreich J, Lorber RR, Danzig MR. Added relief in the treatment of acute recurrent sinusitis with adjunctive mometasone furoate nasal spray. The Nasonex Sinusitis Group. *J Allergy Clin Immunol*. 2000;106:630-7.
88. Nayak AS, Settipane GA, Pedinoff A, Charous L, Meltzer EO, Busse WW, et al. Effective dose range of mometasone furoate nasal spray in the treatment of acute rhinosinusitis. *Ann Allergy Asthma Immunol*. 2002;89:271-8.
89. Dolor RJ, Witsell DL, Hellkamp AS, Williams Jr JW, Califf RM, Simel DL, et al. Comparison of cefuroxime with or without intranasal fluticasone for the treatment of rhinosinusitis. The CAFFS Trial: a randomized controlled trial. *JAMA*. 2001;286:3097-105.
90. Meltzer EO, Orgel A, Backhaus JW, Busse WW, Druce HM, Metzger J, et al. Intranasal flunisolide spray as an adjunct to oral antibiotics therapy for sinusitis. *J Allergy Clin Immunol*. 1993;92:812-23.
91. Gehanno P, Beauvillain C, Bobin S, Chobaut JC, Desauty A, Dubreuil C, et al. Short therapy with amoxicillin-clavulanate and corticosteroids in acute sinusitis: results of a multicentre study in adults. *Scand J Infect Dis*. e2000;32:679-84.
92. Klossek JM, Desmonts-Gohler C, Deslandes B, Coriat F, Bordure P, Dubreuil C, et al. Treatment of functional signs of acute maxillary rhinosinusitis in adults. Efficacy and tolerance of administration of oral prednisone for 3 days. *Presse Med*. 2004;33:303-9.
93. Adam P, Stiffman M, Blake RL Jr. A clinical trial of hypertonic saline nasal spray in subjects with the common cold or rhinosinusitis. *Arch Fam Med*. 1998;7:39-43.

94. Kassel JC, King D, Spurling GK. Saline nasal irrigation for acute upper respiratory tract infections. *Cochrane Database Syst Rev*. 2010;CD006821.
95. Shaikh N, Wald ER, Pi M. Decongestants, antihistamines and nasal irrigation for acute sinusitis in children. *Cochrane Database Syst Rev*. 2012;9:CD007909.
96. Tomooka LT, Murphy C, Davidson TM. Clinical study and literature review of nasal irrigation. *Laryngoscope* 2000;110:1189-93.
97. McCormick DP, John SD, Swischuk LE, Uchida T. A double-blind, placebo-controlled trial of decongestant-antihistamine for the treatment of sinusitis in children. *Clin Pediatr (Phila)*. 1996;35:457-60.
98. Caenen M, Hamels K, Deron P, Clement P. Comparison of decongestive capacity of xylometazoline and pseudoephedrine with rhinomanometry and MRI. *Rhinology*. 2005;43:205-9.
99. Graf P. Long-term use of oxy- and xylometazoline nasal sprays induces rebound swelling, tolerance, and nasal hyperreactivity. *Rhinology*. 1996;34:9-13.
100. Eccles R, Jawad MS, Jawad SS, Angello JT, Druce HM. Efficacy and safety of single and multiple doses of pseudoephedrine in the treatment of nasal congestion associated with common cold. *Am J Rhinol*. 2005;19:25-31.
101. Barnes ML, Bialosterski BT, Gray RD, Fardon TC, Lipworth BJ. Decongestant effects of nasal xylometazoline and mometasone furoate in persistent allergic rhinitis. *Rhinology*. 2005;43:291-5.
102. Jefferson T, Del Mar CB, Dooley L, Ferroni E, Al-Ansary LA, Bawazeer GA, et al. Physical interventions to interrupt or reduce the spread of respiratory viruses. *Cochrane Database Syst Rev*. 2011;CD006207.
103. Milvio C. Nimesulide for the treatment of painful inflammatory process in the ear, nose and throat areas: a double-blind controlled study with benzydamine. *J Int Mes Res*. 1984;12:327-332.
104. Devillier P. Pharmacology of non-steroidal anti-inflammatory drugs and ENT pathology. *Presse Med*. 2001;30:70-9.
105. Stoll D. Inflammation rhinosinusienne aigue. *Presse Med*. 2001;30:33-40.
106. Oliver DR. Letter: Bisolvon for acute sinusitis. *Med J Aust*. 1974;2:794-5.
107. Tarantino V, Stura M, Marengo G, Leproux GB, Cremonesi G. Advantages of treatment with bromhexine in acute sinus inflammation in children. Randomized double-blind study *versus* placebo. *Minerva Pediatr*. 1988;40:649-52.
108. Harris PG. Comparison of "bisolvomycin" and oxytetracycline in the treatment of acute infective sinusitis. *Practitioner*. 1971;207:814-7.
109. Unuvar E1, Tamay Z, Yildiz I, Toprak S, Kilic A, Aydin S, et al. Effectiveness of erdosteine, a second generation mucolytic agent, in children with acute rhinosinusitis: a randomized, placebo controlled, double-blinded clinical study. *Acta Paediatr*. 2010;99:585-9.
110. Timmer A, Günther J, Rücker G, Motschall E, Antes G, Kern WV. Pelargonium sidoides extract for acute respiratory tract infections. *Cochrane Database Syst Rev*. 2008;(3):CD006323.
111. Federspil P, Wulkow R, Zimmermann T. Effects of standardized Myrtol in therapy of acute sinusitis--results of a double-blind, randomized multicenter study compared with placebo. *Laryngorhinootologie*. 1997;76:23-7.
112. Hao Q, Lu Z, Dong BR, Huang CQ, Wu T. Probiotics for preventing acute upper respiratory tract infections. *Cochrane Database Syst Rev*. 2011;CD006895.
113. Schaad UB. OM-85 BV, an immunostimulant in pediatric recurrent respiratory tract infections: a systematic review. *World J Pediatr*. 2010;6:5-12.
114. Anselmo-Lima WT, Velasco e Cruz AA. Complicações das rinossinusites. In: Costa SS, Cruz OLM, Oliveira JAA. *Otorrinolaringologia: princípios e prática*. 2ª Ed. Porto Alegre: Artmed, 2006. p. 673-679.
115. Eviatar E, Gavriel H, Pitro K, Vaiman M, Goldman M, Kessler A. Conservative treatment in rhinosinusitis orbital complications in children aged 2 years and younger. *Rhinology*. 2008;46:334-7.
116. Neves M, Butugan O, Voegels R. Complicações das rinossinusites. In: Voegels R, Lessa M. *Rinologia e Cirurgia Endoscópica dos Seios Paranasais*. Rio de Janeiro: Revinter, 2006, p. 243-255.
117. Bayonne E, El Bakkoury W, Kania R. Complications Crâniennes et Endocrâniennes des infections rhinosinusiennes. *Oto-rhino-laryngologie*. 2007;20:445-A-10.
118. Atherino CCT, Meirelles RC. Complicações das Rinossinusites. In: *Tratado de ORL e Cirurgia Cervico-Facial*. ABORLCCF. 1ª Ed. São Paulo: Ed Roca, 2011. v. 3, p. 168-176.
119. Hansen FS, Hoffmans R, Georgalas C, Fokkens WJ. Complications of acute rhinosinusitis in The Netherlands. *Fam Pract*. 2012;29:147-53.
120. Piatt JH Jr. Intracranial suppuration complicating sinusitis among children: an epidemiological and clinical study. *J Neurosurg Pediatr*. 2011;7:567-74.
121. Stoll D, Klossek JM, Barbaza MO. Prospective study of 43 severe complications of acute rhinosinusitis. *Rev Laryngol Otol Rhinol (Bord)*. 2006;127:195-201.
122. Bayonne E, Kania R, Tran P, Huy B, Herman P. Intracranial complications of rhinosinusitis. A review, typical imaging data and algorithm of management. *Rhinology*. 2009;47:59-65.
123. Chandler JR, Langenbrunner DJ, Stevens ER. The pathogenesis of orbital complications in acute sinusitis. *The Laryngoscope*. 1970;80:1414-28.
124. Botting AM, McIntosh D, Mahadevan M. Paediatric pre and post-septal periorbital infections are different diseases. A retrospective review of 262 cases. *Int J Pediatr Otorhinolaryngol*. 2008;72:377-83.
125. Gallagher RM, Gross CW, Phillips CD. Suppurative intracranial complications of sinusitis. *Laryngoscope*. 1998;108:1635-42.
126. Mortimore S, Wormald PJ. The Groote Schuur hospital classification of the orbital complications of sinusitis. *J Laryngol Otol*. 1997;111:719-23.
127. Velasco e Cruz AA, Demarco RC, Valera FC, dos Santos AC, Anselmo-Lima WT, Marquezini RM. Orbital complications of acute rhinosinusitis: a new classification. *Braz J Otorhinolaryngol*. 2007;73:684-8.
128. Brook I. Microbiology and antimicrobial treatment of orbital and intracranial complications of sinusitis in children and their management. *Int J Pediatr Otorhinolaryngol*. 2009;73:1183-6.
129. Edmonson NE, Parikh SR. Complications of acute bacterial sinusitis in children. *Pediatr Ann*. 2008;37:680-5.
130. François M. Ethmoiditis Aigues Chez l'enfant. *Otorhinolaryngologie*. 2008. 20-440-A-10.
131. Mekhitarian Neto L, Pignatari S, Mitsuda S, Fava AS, Stamm A. Acute sinusitis in children: a retrospective study of orbital complications. *Braz J Otorhinol*. 2007;73:75-9.
132. Peña MT, Preciado D, Orestes M, Choi S. Orbital complications of acute sinusitis: changes in the post-pneumococcal vaccine era. *JAMA Otolaryngol Head Neck Surg*. 2013;139:223-7.
133. Ho CF, Huang YC, Wang CJ, Chiu CH, Lin TY. Clinical analysis of computed tomography-staged orbital cellulitis in children. *J Microbiol Immunol Infect*. 2007;40:518-24.
134. Lessner A, Stern GA. Preseptal and orbital cellulitis. *Infect Dis Clin North Am*. 1992;6:933-52.
135. Babar TF, Zaman M, Khan MN, Khan MD. Risk factors of preseptal and orbital cellulitis. *J Coll Physicians Surg Pak*. 2009;19:39-42.
136. Chaudhry IA, Shamsi FA, Elzaridi E, Al-Rashed W, Al-Amri A, Arat YO. Inpatient preseptal cellulitis: experience from a tertiary eye care centre. *Br J Ophthalmol*. 2008;92:1337-41.
137. Georgakopoulos CD, Eliopoulou MI, Stasinou S, Exarchou A, Pharakakis N, Varvarigou A. Periorbital and orbital cellulitis: a 10-year review of hospitalized children. *Eur J Ophthalmol*. 2010;20:1066-72.

138. Gonzalez MO, Durairaj VD. Understanding pediatric bacterial preseptal and orbital cellulitis. *Middle East Afr J Ophthalmol*. 2010;17:134-7.
139. Bergin DJ, Wright JE. Orbital cellulitis. *Br J Ophthalmol*. 1986;70:174-8.
140. Gungor A, Adusumilli V, Corey JP. Fungal sinusitis: progression of disease in immunosuppression--a case report. *Ear, Nose & Throat J*. 1998;77:207-10, 15.
141. Coenraad S, Buwalda J. Surgical or medical management of subperiosteal orbital abscess in children: a critical appraisal of the literature. *Rhinology*. 2009;47:18-23.
142. Jones H, Trinidade A, Jaberoo MC, Lyons M. Periorbital cellulitis, subgaleal abscess and superior sagittal sinus thrombosis: a rare combination of complications arising from unilateral frontalsinusitis. *J Laryngol Otol*. 2012;126:1281-3.
143. Leo G, Triulzi F, Incorvaia C. Sinus imaging for diagnosis of chronic rhinosinusitis in children. *Curr Allergy Asthma Rep*. 2012;12:136-43.
144. Oxford LE, McClay J. Complications of acute sinusitis in children. *Otolaryngol Head Neck Surg*. 2005;133:32-7.
145. Wenig BL, Goldstein MN, Abramson AL. Frontal sinusitis and its intracranial complications. *Int J Pediatr Otorhinolaryngol*. 1983;5:285-302.
146. Younis RT, Lazar RH, Anand VK. Intracranial complications of sinusitis: a 15-year review of 39 cases. *Ear, Nose, & Throat J*. 2002;81:636-8, 40-2, 44.
147. Park HW, Lee BJ, Chung YS. Orbital subperiosteal hematoma associated with sinus infection. *Rhinology*. 2010;48:117-22.
148. Zimmermann AP, Eivazi B, Wiegand S, Werner JA, Teymoortash A. Orbital lymphatic malformation showing the symptoms of orbital complications of acute rhinosinusitis in children: a report of 2 cases. *Int J Pediatr Otorhinolaryngol*. 2009;73:1480-3.
149. Gavriel H, Yeheskeli E, Aviram E, Yehoshua L, Eviatar E. Dimension of subperiosteal orbital abscess as an indication for surgical management in children. *Otolaryngol Head Neck Surg*. 2011;145:823-7.
150. Ketenci I, Unlü Y, Vural A, Doğan H, Sahin MI, Tuncer E. Approaches to subperiosteal orbital abscesses. *Eur Arch Otorhinolaryngol*. 2013;270:1317-27.
151. Bedwell J, Bauman NM. Management of pediatric orbital cellulitis and abscess. *Curr Opin Otolaryngol Head Neck Surg*. 2011;19:467-73.
152. Siedek V, Kremer A, Betz CS, Tschiesner U, Berghaus A, Leunig A. Management of orbital complications due to rhinosinusitis. *Eur Arch Otorhinolaryngol*. 2010;267:1881-6.
153. Hoxworth JM, Glastonbury CM. Orbital and intracranial complications of acute sinusitis. *Neuroimaging Clin N Am*. 2010;20:511-26.
154. Albu S, Tomescu E, Bassam S, Merca Z, Albu S, Tomescu E, et al. Intracranial complications of sinusitis. *Acta Otorhinolaryngol Belg*. 2001;55:265-72. 445.
155. Gavriel H, Kessler A, Eviatar E. Management implications of diagnosing orbital abscess as subperiosteal orbital abscess. *Rhinology*. 2010;48:90-4.
156. Komatsu H, Matsumoto F, Kasai M, Kurano K, Sasaki D, Ikeda K. Cavernous sinus thrombosis caused by contralateral sphenoid sinusitis: a case report. *Head Face Med*. 2013;9:9.
157. DelGaudio JM, Evans SH, Sobol SE, Parikh SL. Intracranial complications of sinusitis: what is the role of endoscopic sinus surgery in the acute setting. *Am J Otolaryngol*. 2010;31:25-8.
158. Giannoni CM, Stewart MG, Alford EL. Intracranial complications of sinusitis. *Laryngoscope*. 1997;107:863-7.
159. Kombogiorgas D, Seth R, Athwal R, Modha J, Singh J. Suppurative intracranial complications of sinusitis in adolescence. Single institute experience and review of literature. *Br J Neurosurg*. 2007;21:603-9.
160. Deutschmann MW, Livingstone D, Cho JJ, Vanderkooi OG, Brookes JT. The significance of *Streptococcus anginosus* group in intracranial complications of pediatric rhinosinusitis. *JAMA Otolaryngol Head Neck Surg*. 2013;139:157-60.
161. Herrmann BW, Chung JC, Eisenbeis JF, Forsen JW Jr. Intracranial complications of pediatric frontal rhinosinusitis. *Am J Rhinol*. 2006;20:320-4.
162. Germiller JA, Monin DL, Sparano AM, Tom LW. Intracranial complications of sinusitis in children and adolescents and their outcomes. *Arch Otolaryngol Head & Neck Surg*. 2006;132:969-76.
163. Hakim HE, Malik AC, Aronyk K, Ledi E, Bhargava R. The prevalence of intracranial complications in pediatric frontal sinusitis. *Int J Pediatr Otorhinolaryngol*. 2006;70:1383-7.
164. Ogunleye AO, Nwaorgu OG, Lasisi AO. Complications of sinusitis in Ibadan, Nigeria. *West Afr J Med*. 2001;20:98-101.
165. Butugan O, Balbani APS, Voegels R. Complicações das Rinossinusites. In: Campos CAH, Costa HOO. *Tratado de Otorrinolaringologia*. São Paulo: Roca, 2003, v. 3, 107-117.
166. Page C, Lehmann P, Jeanjean P. Abcès et empyèmes intracrâniens d'origine ORL Ann Otolaryngol Chir Cervicofac. 2005;122:120-6.
167. Mirza S, Lobo CJ, Counter P, Farrington WT. Lacrimal gland abscess: an unusual complication of rhinosinusitis. *ORL J Otorhinolaryngol Relat Spec*. 2001;63:379-81.
168. Patel N, Khalil HM, Amirfeyz R, Kaddour HS. Lacrimal gland abscess complicating acute sinusitis. *Int J Pediatr Otorhinolaryngol*. 2003;67:917-9.
169. Parvizi N, Choudhury N, Singh A. Complicated periorbital cellulitis: case report and literature review. *J Laryngol Otol*. 2012;126:94-6.
170. Pang KP, Sethi DS. Nasal septal abscess: an unusual complication of acute sphenothmoiditis. *J Laryngol Otol*. 2002;116:543-5.
171. Siberry GK, Costarantos C, Cohen BA. Destruction of the nasal septum by aspergillus infection after autologous bone marrow transplantation. *New England J Medicine*. 1997;337:275-6.
172. Wu VF, Smith TL, Poetker DM. Sinocutaneous fistula secondary to chronic frontal rhinosinusitis: case series and literature review. *Ann Otol Rhinol Laryngol*. 2008;117:759-63.
173. Laurens MB, Becker RM, Johnson JK, Wolf JS, Kotloff KL. MRSA with progression from otitis media and sphenoid sinusitis to clival osteomyelitis, pachymeningitis and abducens nerve palsy in an immunocompetent 10-year-old patient. *Int J Pediatr Otorhinolaryngol*. 2008;72:945-51.
174. Rimal D, Hashmi SM, Prinsley PR. An unusual presentation of sphenoid sinusitis with septicaemia in a healthy young adult. *Emerg Med J*. 2006;23:e36.
175. Righini CA, Bing F, Bessou P, Boubagra K, Rey E. An acute ischemic stroke secondary to sphenoid sinusitis. *Ear, Nose, & Throat J*. 2009;88:E23-8.
176. Hoffman RA, Parisier SC, Roland JT Jr. In reference to Orbital sequelae of rhinosinusitis after cochlear implantation in children. *Laryngoscope*. 2007;117:1505.
177. Rudnick EF, Chu MW, Sismanis A, Dodson KM, Mitchell RB. Orbital sequelae of rhinosinusitis after cochlear implantation in children. *Laryngoscope*. 2006;116:1368-71.
178. Bhattacharyya N. Contemporary assessment of the disease burden of sinusitis. *Am J Rhinol Allergy*. 2009;23:392-5.
179. Anand VK. Epidemiology and economic impact of rhinosinusitis. *Ann Otol Rhinol Laryngol Suppl*. 2004;193:3-5. Review.
180. Bhattacharyya N, Orlandi RR, Grebner J, Martinson M. Cost Burden of Chronic Rhinosinusitis: a Claims-Based Study. *Otolaryngol Head Neck Surg*. 2011;144:440-5.
181. Ray NF, Baraniuk JN, Thamer M, Rinehart CS, Gergen PJ, Kaliner M, et al. Healthcare expenditures for sinusitis in 1996: contributions of asthma, rhinitis, and other airway disorders. *J Allergy Clin Immunol*. 1999;103:408-14.
182. Bhattacharyya N. Incremental Health Care Utilization and Expenditures for Chronic Rhinosinusitis in the United States. *Ann Otol Rhinol Laryngol*. 2011;120:423-7.
183. Bhattacharyya N. The economic burden and symptom manifestations of chronic rhinosinusitis. *Am J Rhinol*. 2003;17:27-32.

184. Durr DG, Desrosiers MY, Dassa C. Impact of rhinosinusitis in health care delivery: the Quebec experience. *J Otolaryngol*. 2001;30:93-7.
185. Bezerra TF, Piccirillo JF, Fornazieri MA, de M Pilan RR, Abdo TR, de Rezende Pinna F, et al. Cross-Cultural Adaptation and Validation of SNOT-20 in Portuguese. *Int J Otolaryngol*. 2011;2011:306529.
186. Ware JE, Sherbourne CD. The MOS 36-item short-form health survey (SF-36). I. Conceptual framework and item selection. *Med Care*. 1992;30:473-83.
187. Gliklich RE, Metson R. The health impact of chronic sinusitis in patients seeking otolaryngologic care. *Otolaryngol Head Neck Surg*. 1995;113:104-9.
188. Fokkens W, Lund V, Mullol J, European Position Paper on Rhinosinusitis and Nasal Polyps group. European position paper on rhinosinusitis and nasal polyps 2007. *Rhinol Suppl*. 2007;1:1-136.
189. Pleis JR, Ward BW, Lucas JW. Summary health statistics for U.S. adults: National Health Interview Survey, 2009. *Vital Health Stat* 10. 2010;1:207.
190. Chen Y, Dales R, Lin M. The epidemiology of chronic rhinosinusitis in Canadians. *Laryngoscope*. 2003; 113:1199-205.
191. Kim YS, Kim NH, Seong SY, Kim KR, Lee G-B, Kim K-S. Prevalence and risk factors of chronic rhinosinusitis in Korea. *Am J Rhinol Allergy*. 2011;25:117-21.
192. Hastan D, Fokkens WJ, Bachert C, Newson RB, Bislimovska J, Bockelbrink A et al. Chronic rhinosinusitis in Europe - an underestimated disease. A GA(2)LEN study. *Allergy*. 2011;66:1216-23.
193. Tomassen P, Newson RB, Hoffmans R, Lotvall J, Cardell LO, Gunnbjornsdottir M et al. Reliability of EP30S symptom criteria and nasal endoscopy in the assessment of chronic rhinosinusitis - a GA2LEN study. *Allergy*. 2011;66:556-61.
194. Pilan RR, Pinna FR, Bezerra TF, Mori RL, Padua FG, Bento RF, et al. Prevalence of chronic rhinosinusitis in Sao Paulo. *Rhinology*. 2012;50:129-38.
195. Wood AJ, Antoszewska H, Fraser J, Douglas RG. Is chronic rhinosinusitis caused by persistent respiratory virus infection? *Int Forum Allergy Rhinol*. 2011;1:95-100.
196. Cho GS, Moon BJ, Lee BJ, Gong CH, Kim NH, Kim YS, et al. High rates of detection of respiratory viruses in the nasal washes and mucosae of patients with chronic rhinosinusitis. *J Clin Microbiol*. 2013;51:979-84.
197. Lima Jr JT. Prevalência e sazonalidade dos vírus respiratórios na rinossinusite crônica com e sem pólipos nasais e sua influência na celularidade da mucosa e dos pólipos nasais. 88p. Tese de Doutorado. Faculdade de Medicina de Ribeirão Preto. Universidade de São Paulo. 2013.
198. Gungor AA. On chronic rhinosinusitis and the prevalence of fungal sinus disease: problems of diagnostic accuracy and a proposed classification of chronic rhinosinusitis. *Am J Otolaryngol*. 2012;33:543-8.
199. de Shazo RD, Chapin K, Swain RE. Fungal sinusitis. *N Engl J Med*. 1997;337:254-9.
200. Ponikau JU, Sherris DA, Kern EB, Homburger HA, Frigas E, Gaffey TA, et al. The diagnosis and incidence of allergic fungal sinusitis. *Mayo Clin Proc*. 1999;74:877-84.
201. Shin SH, Ponikau JU, Sherris DA, Congdon D, Frigas E, Homburger HA, et al. Chronic rhinosinusitis: an enhanced immune response to ubiquitous airborne fungi. *J Allergy Clin Immunol*. 2004;114:1369-75.
202. Inoue Y, Matsuwaki Y, Shin SH, Ponikau JU, Kita H. Nonpathogenic, environmental fungi induce activation and degranulation of human eosinophils. *J Immunol*. 2005;175:5439-47.
203. Wei JL, Kita H, Sherris DA, Kern EB, Weaver A, Ponikau JU. The chemotactic behavior of eosinophils in patients with chronic rhinosinusitis. *Laryngoscope*. 2003;113:303-6.
204. Braun H, Buzina W, Freudenschuss K, Beham A, Stammberger H. Eosinophilic fungal rhinosinusitis: a common disorder in Europe? *Laryngoscope*. 2003;113:264-9.
205. Orlandi RR, Marple BF, Georgelas A, Durtschi D, Barr L. Immunologic response to fungus is not universally associated with rhinosinusitis. *Otolaryngol Head Neck Surg*. 2009;141:750-6.
206. Douglas R, Bruhn M, Tan LW, Ooi E, Psaltis A, Wormald PJ. Response of peripheral blood lymphocytes to fungal extracts and staphylococcal superantigen B in chronic rhinosinusitis. *Laryngoscope*. 2007;117:411-4.
207. Kennedy DW, Kuhn FA, Hamilos DL, Zinreich SJ, Butler D, Warsi G, et al. Treatment of chronic rhinosinusitis with high-dose oral terbinafine: a double blind, placebo-controlled study. *Laryngoscope*. 2005;115:1793-9.
208. Weschta M, Rimek D, Formanek M, Podbielski A, Riechelmann H. Effect of nasal antifungal therapy on nasal cell activation markers in chronic rhinosinusitis. *Arch Otolaryngol Head Neck Surg*. 2006;132:743-7.
209. Helbling A, Baumann A, Hänni C, Caversaccio M. Amphotericin B nasal spray has no effect on nasal polyps. *J Laryngol Otol*. 2006;120:1023-5.
210. Liang KL, Su MC, Shiao JY, Tseng HC, Hsin CH, Lin JF, et al. Amphotericin B irrigation for the treatment of chronic rhinosinusitis without nasal polyps: a randomized, placebo-controlled, double-blind study. *Am J Rhinol* 2008;22:52-8.
211. Ebbens FA, Scadding GK, Badia L, Hellings PW, Jorissen M, Mullol J, et al. Amphotericin B nasal lavages: not a solution for patients with chronic rhinosinusitis. *J Allergy Clin Immunol*. 2006;118:1149-56.
212. Ebbens FA, Georgelas C, Luiten S, van Drunen CM, Badia L, Scadding GK, et al. The effect of topical amphotericin B on inflammatory markers in patients with chronic rhinosinusitis: a multicenter randomized controlled study. *Laryngoscope*. 2009;119:401-8.
213. Isaacs S, Fakhri S, Luong A, Citardi MJ. A meta-analysis of topical amphotericin B for the treatment of chronic rhinosinusitis. *Int Forum Allergy Rhinol*. 2011:250-4.
214. Ramanathan Jr M, Lee WK, Lane AP. Increased expression of acidic mammalian chitinase in chronic rhinosinusitis with nasal polyps. *Am J Rhinol* 2006; 20:330-5.
215. Kauffman HF. Innate immune responses to environmental allergens. *Clin Rev Allergy Immunol*. 2006;30:129-40.
216. Fokkens WJ, Ebbens F, van Drunen CM. Fungus: a role in pathophysiology of chronic rhinosinusitis, disease modifier, a treatment target, or no role at all? *Immunol Allergy Clin North Am*. 2009;29:677-88.
217. Araujo E, Palombini BC, Cantarelli V, Pereira A, Mariante A. Microbiology of middle meatus in chronic rhinosinusitis. *Am J Rhinol*. 2003;17:9-15.
218. Mantovani K, Bisnha AA, Demarco RC, Tamashiro E, Martinez R, Anselmo-Lima WT. Maxillary sinuses microbiology from patients with chronic rhinosinusitis. *Braz J Otorhinol*. 2010;76:548-51.
219. Doyle PW, Woodham JD. Evaluation of the microbiology of chronic ethmoid sinusitis. *J Clin Microbiol*. 1991;29:2396-400.
220. Jiang RS, Lin JF, Hsu CY. Correlations between bacteriology of the middle meatus and ethmoid sinus in chronic sinusitis. *J Laryngol Otol*. 2002;116:443-6.
221. Kim HJ, Lee K, Yoo JB, Song JW, Yoon HJ. Bacteriological findings and antimicrobial susceptibility in chronic sinusitis with nasal polyp. *Acta Otolaryngol* 2006;126:489-97.
222. Brook I. Microbiology of sinusitis. *Proc Am Thor Soc*. 2011;8:90-100.
223. Boase S, Foreman A, Cleland E, Tan L, Melton-Kreft R, Pant H, et al. The microbiome of chronic rhinosinusitis: culture, molecular diagnostics and biofilm detection. *BMC Infectious Diseases*. 2013;13:210-8.
224. Stressmann FA, Rogers GB, Chan SW, Howarth PH, Harries PG, Bruce KD, et al. Characterization of bacterial community diversity in chronic rhinosinusitis infections using novel culture-independent techniques. *Am J Rhinol Allergy*. 2011;25:e133-40.

225. Stephenson MF, Mfunu L, Dowd SE, Wolcott RD, Barbeau J, Poisson M, et al. Molecular characterization of the polymicrobial flora in chronic rhinosinusitis. *J Otolaryngol Head Neck Surg.* 2010;39:182-7.
226. Abreu NA, Nagalingam NA, Song Y, Roediger FC, Pletcher SD, Goldberg NA, et al. Sinus microbiome diversity depletion and corynebacterium tuberculoearicum enrichment mediates rhinosinusitis. *Sci Transl Med.* 2012;4:151ra124.
227. Larson DA, Han JK. Microbiology of sinusitis: does allergy or endoscopic sinus surgery affect the microbiologic flora? *Curr Opin Otolaryngol Head Neck Surg.* 2011;19:199-203.
228. Ba L, Zhang N, Meng J, Zhang J, Lin P, Zhou P, et al. The association between bacterial colonization and inflammatory pattern in Chinese chronic rhinosinusitis patients with nasal polyps. *Allergy.* 2011;66:1296-303.
229. Hwang PH. Staph aureus has long been recognized as being more prevalent in cultures from patients with chronic rhinosinusitis (CRS) compared to those with acute rhinosinusitis. *Int Forum Allergy Rhinol.* 2013;3:81-2.
230. Guven M, Karabay O, Akidil O, Yilmaz MS, Yildirim M. Detection of staphylococcal exotoxins in antrochoanal polyps and chronic rhinosinusitis with nasal polyps. *Otolaryngol Head Neck Surg.* 2013;148:302-7.
231. Wang M, Shi P, Yue Z, Chen B, Zhang H, Zhang D, et al. Superantigens and the expression of T-cell receptor repertoire in chronic rhinosinusitis with nasal polyps. *Acta Otolaryngol.* 2008;128:901-8.
232. Conley DB, Tripathi A, Seiberling KA, Schleimer RP, Suh LA, Harris K, et al. Superantigens and chronic rhinosinusitis: skewing of T-cell receptor V beta-distributions in polyp-derived CD4+ and CD8+ T cells. *RC. Am J Rhinol.* 2006;20:534-9.
233. Gevaert P, Nouri-Aria KT, Wu H, Harper CE, Takhar P, Fear DJ, et al. Local receptor revision and class switching to IgE in chronic rhinosinusitis with nasal polyps. *Allergy.* 2013;68:55-63.
234. Cho KS, Kim CS, Lee HS, Seo SK, Park HY, Roh HJ. Role of interferon- γ -producing t cells in the pathogenesis of chronic rhinosinusitis with nasal polyps associated with staphylococcal superantigen. *J Otolaryngol Head Neck Surg.* 2010;39:600-5.
235. Seiberling KA, Conley DB, Tripathi A, Grammer LC, Shuh L, Haines GK 3rd, et al. Superantigens and chronic rhinosinusitis: detection of staphylococcal exotoxins in nasal polyps. *Laryngoscope.* 2005;115:1580-5.
236. Bernstein JM, Ballow M, Schlievert PM, Rich G, Allen C, Dryja D. A superantigen hypothesis for the pathogenesis of chronic hyperplastic sinusitis with massive nasal polyposis. *Am J Rhinol.* 2003;17:321-6.
237. Kowalski ML, Cieslak M, Perez-Novo CA, Makowska J, Bachert C. Clinical and immunological determinants of severe/refractory asthma (SRA): association with Staphylococcal superantigen - specific IgE antibodies. *Allergy.* 2011;66:32-8.
238. Bachert C, Van Steen K, Zhang N, Holtapples G, Cattaert T, Maus B, et al. Specific IgE against *Staphylococcus aureus* enterotoxins: an independent risk factor for asthma. *J Allergy Clin Immunol.* 2012;130:376-81.
239. Heymans F, Fischer A, Stow NW, Girard M, Vourexakis Z, Des Courtis A, et al. Screening for staphylococcal superantigen genes shows no correlation with the presence or the severity of chronic rhinosinusitis and nasal polyposis. *PLoS One.* 2010;5:e9525.
240. Corriveau MN, Zhang N, Bachert C. The presence of *Staphylococcus aureus* is not equivalent to an immune reaction to its enterotoxins. *Allergy.* 2009;64:959-60.
241. Cohen M, Kofonow J, Nayak JV, Palmer JN, Chiu AG, Leid JG, et al. Biofilms in chronic rhinosinusitis: a review. *Am J Rhinol Allergy.* 2009;23:255-60.
242. Bezerra TF, Padua FG, Gebrim EM, Saldiva PH, Voegels RL. Biofilms in chronic rhinosinusitis with nasal polyps. *Otolaryngol Head Neck Surg.* 2011;144:612-6.
243. Tamashiro E, Antunes MB, Palmer JN, Cohen NA, Anselmo-Lima WT. Implications of bacterial biofilms in chronic rhinosinusitis. *Braz J Infect Dis.* 2009;13:232-5.
244. Foreman A, Psaltis AJ, Tan LW, Wormald PJ. Characterization of bacterial and fungal biofilms in chronic rhinosinusitis. *Am J Rhinol Allergy.* 2009;23:556-61.
245. Psaltis AJ, Weitzel EK, Ha KR, Wormald PJ. The effect of bacterial biofilms on post-sinus surgical outcomes. *Am J Rhinol.* 2008;22:1-6.
246. Bendouah Z, Barbeau J, Hamad WA, Desrosiers M. Biofilm formation by *Staphylococcus aureus* and *Pseudomonas aeruginosa* is associated with an unfavorable evolution after surgery for chronic sinusitis and nasal polyposis. *Otolaryngol Head Neck Surg.* 2006;134:991-6.
247. Foreman A, Wormald PJ. Different biofilms, different disease? A clinical outcomes study. *Laryngoscope.* 2010;120:1701-6.
248. Singhal D, Foreman A, Jervis-Bardy J, Wormald PJ. *Staphylococcus aureus* biofilms: Nemesis of endoscopic sinus surgery. *Laryngoscope.* 2011;121:1578-83.
249. Zhang Z, Linkin DR, Finkelman BS, O'Malley BW Jr, Thaler ER, Doghramji L, et al. Asthma and biofilm-forming bacteria are independently associated with revision sinus surgeries for chronic rhinosinusitis. *J Allergy Clin Immunol.* 2011;128:221-223.
250. Hekiert AM, Kofonow JM, Doghramji L, Kennedy DW, Chiu AG, Palmer JN, et al. Biofilms correlate with TH1 inflammation in the sinonasal tissue of patients with chronic rhinosinusitis. *Otolaryngol Head Neck Surg.* 2009;141:448-53.
251. Foreman A, Holtappels G, Psaltis AJ, Jervis-Bardy J, Field J, Wormald PJ, et al. Adaptive immune responses in *Staphylococcus aureus* biofilm-associated chronic rhinosinusitis. *Allergy.* 2011;66:1449-56.
252. Arjomandi H, Gilde J, Zhu S, Delaney S, Hochstim C, Mazhar K, et al. Relationship of eosinophils and plasma cells to biofilm in chronic rhinosinusitis. *Am J Rhinol Allergy.* 2013;27:e85-90.
253. Karosi T, Csomor P, Hegyi Z, Sziklai I. The presence of CD209 expressing dendritic cells correlates with biofilm positivity in chronic rhinosinusitis with nasal polyposis. *Eur Arch Otorhinolaryngol.* 2013;270:2455-63.
254. Sun Y, Zhou B, Wang C, Huang Q, Zhang Q, Han Y, et al. Biofilm formation and Toll-like receptor 2, Toll-like receptor 4, and NF- κ B expression in sinus tissues of patients with chronic rhinosinusitis. *Am J Rhinol Allergy.* 2012;26:104-9.
255. Plouin-Gaudon I, Clement S, Huggler E, Chaponnier C, François P, Lew D, et al. Intracellular residency is frequently associated with recurrent *Staphylococcus aureus* rhinosinusitis. *Rhinology.* 2006;44:249-54.
256. Tan NC, Tran HB, Foreman A, Jardeleza C, Vreugde S, Wormald PJ. Identifying intracellular *Staphylococcus aureus* in chronic rhinosinusitis: a direct comparison of techniques. *Am J Rhinol Allergy.* 2012;26:444-9.
257. Wood AJ, Fraser JD, Swift S, Patterson-Emanuelson EA, Amirapu S, Douglas RG. Intramucosal bacterial microcolonies exist in chronic rhinosinusitis without inducing a local immune response. *Am J Rhinol Allergy.* 2012;26:265-70.
258. Tan NC, Foreman A, Jardeleza C, Douglas R, Tran H, Wormald PJ. The multiplicity of *Staphylococcus aureus* in chronic rhinosinusitis: correlating surface biofilm and intracellular residence. *Laryngoscope.* 2012;122:1655-600.
259. Askarian F, Sangvik M, Hanssen AM, Snipen L, Johannessen M. *Staphylococcus aureus* nasal isolates from healthy individuals cause highly variable host cell responses *in vitro*: The Tromsø Staph and Skin Study. *Pathog Dis.* 2014;70:158-66.
260. Akdis CA, Bachert C, Cingi C, Dykewicz MS, Hellings PW, Nalclerio RM, et al. Endotypes and phenotypes of chronic rhinosinusitis: a PRACTALL document of the European Academy of Allergy and clinical immunology and the American Academy of Allergy, Asthma & Immunology. *J Allergy Clin Immunol.* 2013;131:1479-90.
261. Van Bruene N, Bachert C. Tissue remodeling in chronic rhinosinusitis. *Curr Opin Allergy Clin Immunol.* 2011;11:8-11.

262. Van Drunen CM, Mjösberg JM, Segboer CL, Cornet ME, Fokkens WJ. Role of innate immunity in the pathogenesis of chronic rhinosinusitis: progress and new avenues. *Curr Allergy Asthma Rep.* 2012;12:120-6.
263. Li C, Shi L, Yan Y, Gordon BR, Gordon WM, Wang DY. Gene expression signatures: a new approach to understanding the pathophysiology of chronic rhinosinusitis. *Curr Allergy Asthma Rep.* 2013;13:209-17.
264. Tieu DD, Kern RC, Schleimer RP. Alterations in epithelial barrier function and host defense responses in chronic rhinosinusitis. *J Allergy Clin Immunol.* 2009;124:37-42.
265. Schleimer RP, Kato A, Peters A, Conley D, Kim J, Liu MC, et al. Epithelium, inflammation, and immunity in the upper airways of humans studies in chronic rhinosinusitis. *Proc Am Thorac Soc.* 2009;6:288-94.
266. Kern RC, Conley DB, Walsh W, Chandra R, Kato A, Tripathi-Peters A, et al. Perspectives on the etiology of chronic rhinosinusitis: an immune barrier hypothesis. *Am J Rhinol.* 2008;22:549-59.
267. Psaltis AJ, Bruhn MA, Ooi EH, Tan LW, Wormald PJ. Nasal mucosa expression of lactoferrin in patients with chronic rhinosinusitis. *Laryngoscope.* 2007;117:2030-5.
268. Tewfik MA, Latterich M, Di Falco MR, Samaha M. Proteomics of nasal mucus in chronic rhinosinusitis. *Am J Rhinol.* 2007;21:680-5.
269. Soyka MB, Wawrzyniak P, Eiwegger T, Holzmann D, Treis A, Wanke K, et al. Defective epithelial barrier in chronic rhinosinusitis: the regulation of tight junctions by IFN-gamma and IL-4. *J Allergy Clin Immunol.* 2012;130:1087-96.e10.
270. Kast JI, Wanke K, Soyka MB, Wawrzyniak P, Akdis D, Kingo K, et al. The broad spectrum of interepithelial junctions in skin and lung. *J Allergy Clin Immunol.* 2012;130:544-7.e4.
271. Dong Z, Yang Z, Wang C. Expression of TLR2 and TLR4 messenger RNA in the epithelial cells of the nasal airway. *Am J Rhinol Allergy.* 2005;19:236-9.
272. Lane AP, Truong-Tran QA, Schleimer RP. Altered expression of genes associated with innate immunity and inflammation in recalcitrant rhinosinusitis with polyps. *Am J Rhinol Allergy.* 2006;20:138-44.
273. Ramanathan Jr M, Lee WK, Dubin MG, Lin S, Spannhake EW, Lane AP. Sinonasal epithelial cell expression of toll-like receptor 9 is decreased in chronic rhinosinusitis with polyps. *Am J Rhinol.* 2007;21:110-6.
274. Casanova JL, Abel L, Quintana-Murci L. Human TLRs and IL-1Rs in host defense: natural insights from evolutionary, epidemiological and clinical genetics. *Ann Rev Immunol.* 2011;29:447-91.
275. Tesse R, Pandey C, Kabesch M. Genetic variations in toll-like receptor pathway genes influence asthma and atopy. *Allergy.* 2011;66:307-16.
276. Iwamura C, Nakayama T. Toll-like receptors in the respiratory system: their roles in inflammation. *Curr Allergy Asthma Rep.* 2008;8:7-13.
277. Kim YK, Oh SY, Jeon SG, Park HW, Lee SY, Chun EY, et al. Airway exposure levels of lipopolysaccharide determine type 1 *versus* type 2 experimental asthma. *J Immunol.* 2007;178:5375-82.
278. Valera FCP, Queiroz R, Scrideli C, Tone LG, Anselmo-Lima WT. Expression of transcription factors NF- κ B and AP-1 in nasal polyposis. *Clin Exper Allergy.* 2008;38:579-85.
279. Takeno S, Hirakawa K, Ueda T, Furukido K, Ossada R, Yajin K. Nuclear factor-kappa B activation in the nasal polyp epithelium: relationship to local cytokine gene expression. *Laryngoscope.* 2002;112:53-8.
280. Necela BM, Cidlowski JA. Mechanisms of glucocorticoid receptor action in noninflammatory and inflammatory cells. *Proc Am Thorac Soc.* 2004;1:239-46.
281. Valera FCP, Queiroz R, Scrideli C, Tone LG, Anselmo-Lima WT. NF-kappa expression predicts clinical outcome for nasal polyposis. *Rhinology.* 2010;48:408-41.
282. Chin D, Harvey RJ. Nasal polyposis: an inflammatory condition requiring effective anti-inflammatory treatment. *Curr Opin Otolaryngol Head Neck Surg.* 2013;21:23-30.
283. Calus L, Van Zele T, Derycke L, Krysko O, Dutre T, Tomassen P, et al. Local inflammation in chronic upper airway disease. *Curr Pharmac Design.* 2012;18:2336-46.
284. Reh DD, Wang Y, Ramanathan M Jr, Lane AP. Treatment-recalcitrant chronic rhinosinusitis with polyps is associated with altered epithelial cell expression of interleukin-33. *Am J Rhinol Allergy.* 2010;24:105-9.
285. Wang YH, Angkasekwinai P, Lu N, Voo KS, Arima K, Hanabuchi S, et al. IL-25 augments type 2 immune responses by enhancing the expansion and functions of TSLP-DC-activated Th2 memory cells. *J Exp Med.* 2007;204:1837-47.
286. Koyasu S, Moro K. Innate Th2-type immune responses and the natural helper cell, a newly identified lymphocyte population. *Curr Opin Allergy Clin Immunol.* 2011;11:109-14.
287. Figueiredo CR, Silva IDC, Weckx LLM. Inflammatory genes in nasal polyposis. *Curr Opin Otolaryngol Head Neck Surg.* 2008;16:18-21.
288. Cavallari FE, Valera FC, Gallego AJ, Malinsky RR, Küpper DS, Milanezi C, et al. Expression of RANTES, eotaxin-2, ICAM-1, LFA-1 and CCR-3 in chronic rhinosinusitis patients with nasal polyposis. *Acta Cir Bras.* 2012;27:645-9.
289. de Castro MC, Rocha-Silva F, Gomes LI, Zauli DA, de Moraes Mourão M, et al. Impact of mitomycin C on the mRNA expression signatures of immunological biomarkers in eosinophilic nasal polyposis. *Am J Rhinol Allergy.* 2013;27:e32-e41.
290. Otto BA, Wenzel SE. The role of cytokines in chronic rhinosinusitis with nasal polyps. *Curr Opin Otolaryngol Head Neck Surg.* 2008;16:270-4.
291. Valera FCP, Queiroz R, Scrideli C, Tone LG, Anselmo-Lima WT. Evaluating budesonide efficacy in nasal polyposis and predicting the resistance to treatment. *Clin Exper Allergy.* 2009;39:81-8.
292. Huvenne W, van Bruaene N, Zhang N, van Zele T, Patou J, Gevaert P, et al. Chronic rhinosinusitis with and without nasal polyps: what is the difference? *Curr Allergy Asthma Rep.* 2009;9:213-20.
293. Voegels RL, de Melo Pádua FG. Expression of interleukins in patients with nasal polyposis. *Otolaryngol Head Neck Surg.* 2005;132:613-6.
294. Bulek K, Swaidani S, Aronica M, Li X. Epithelium: the interplay between innate and Th2 immunity. *Immunol Cell Biol.* 2010;88:257-68.
295. Bachert C, Zhang N, Holtappels G, De Lobel L, van Cauwenberge P, Liu S, et al. Presence of IL-5 protein and IgE antibodies to staphylococcal enterotoxins in nasal polyps is associated with comorbid asthma. *J Allergy Clin Immunol.* 2010;126:962-8, e1-6.
296. Pezato R, Świerczyńska-Krępa M, Niżankowska-Mogilnicka E, Derycke L, Bachert C, Pérez-Novo CA. Role of imbalance of eicosanoid pathways and staphylococcal superantigens in chronic rhinosinusitis. *Allergy.* 2012;67:1347-56.
297. Bassiouni A, Chen PG, Wormald PJ. Mucosal remodeling and reversibility in chronic rhinosinusitis. *Curr Opin Allergy Clin Immunol.* 2013;13:4-12.
298. Zhang N, Van Zele T, Perez-Novo C, Van Bruaene N, Holtappels G, DeRuyck N, et al. Different types of T-effector cells orchestrate mucosal inflammation in chronic sinus disease. *J Allergy Clin Immunol.* 2008;122:961-8.
299. Kim YM, Munoz A, Hwang PH, Nadeau KC. Migration of regulatory T cells toward airway epithelial cells is impaired in chronic rhinosinusitis with nasal polyposis. *Clin Immunol.* 2010;137:111-21.
300. Van Bruaene N, Derycke L, Perez-Novo CA, Gevaert P, Holtappels G, De Ruyck N, et al. TGF- β signaling and collagen deposition in chronic rhinosinusitis. *J Allergy Clin Immunol.* 2009;124:253-9.e2.

301. Balsalobre L, Pezato R, Perez-Novo C, Alves MT, Santos RP, Bachert C, et al. Epithelium and stroma from nasal polyp mucosa exhibits inverse expression of TGF- β 1 as compared with healthy nasal mucosa. *J Otolaryngol Head Neck Surg*. 2013;42:29.
302. Malinsky RR, Valera FC, Cavallari FE, Küpper DS, Milaneze C, Silva JS, et al. Matrix metalloproteinases and their impact on sinus extension in chronic rhinosinusitis with nasal polyps. *Eur Arch Otorhinolaryngol*. 2013;270:1345-8.
303. Watelet JB, Bachert C, Claeys C, Van Cauwenberge P. Matrix metallo-proteinases MMP-7, MMP-9 and their tissue inhibitor TIMP-1: expression in chronic sinusitis vs nasal polyposis. *Allergy*. 2004;59:54-60.
304. Hsu J, Avila PC, Kern RC, Hayes G, Schleimer RP, Pinto JM. Genetics of chronic rhinosinusitis: state of the field and directions forward. *J Allergy Clin Immunol*. 2013;131:977-93.
305. van Drunen CM, Vrolijk AB, Rinia AB, Fokkens WJ. Considerations on the application of microarray analysis in rhinology. *Rhinology*. 2008;46:259-66.
306. Mfuna-Endam L, Zhang Y, Desrosiers MY. Genetics of rhinosinusitis. *Curr Allergy Asthma Rep*. 2011;11:236-46.
307. Pinto JM, Hayes MG, Schneider D, Naclerio RM, Ober C. A genome-wide screen for chronic rhinosinusitis genes identifies a locus on chromosome 7q. *Laryngoscope*. 2008;118:2067-72.
308. Bossé Y, Bacot F, Montpetit A, Rung J, Qu HQ, Engert JC, et al. Identification of susceptibility genes for complex diseases using pooling-based genome-wide association scans. *Hum Genet*. 2009;125:305-18.
309. Tournas A, Mfuna L, Bossé Y, Filali-Mouhim A, Gregnier JP, Desrosiers M. A pooling-based genome-wide association study implicates the p73 gene in chronic rhinosinusitis. *J Otolaryngol Head Neck Surg*. 2010;39:188-95.
310. Gröneberg H. The inheritance of a disease of the accessory nasal cavities. *J Genet*. 1934;29:367-74.
311. Cohen NA, Wideltz JS, Chiu AG, Palmer JN, Kennedy DW. Familial aggregation of sinonasal polyps correlates with severity of disease. *Otolaryngol Head Neck Surg*. 2006;134:601-4.
312. Lockey RF, Rucknagel DL, Vanselow NA. Familial occurrence of asthma, nasal polyps and aspirin intolerance. *Ann Intern Med*. 1973;78:57-63.
313. Greisner WA 3rd, Settiple GA. Hereditary factor for nasal polyps. *Allergy Asthma Proc*. 1996;17:283-6.
314. Delagrang A, Gilbert-Dussardier B, Burg S, Allano G, Gohler-Desmonts C, Lebreton JP, et al. Nasal polyposis: is there an inheritance pattern? A single family study. *Rhinology*. 2008;46:125-30.
315. Drake-Lee A. Nasal polyps in identical twins. *J Laryngol Otol*. 1992;106:1084-5.
316. Takeuchi K, Majima Y, Shimizu T, Ukai K, Sakakura Y. Analysis of HLA antigens in Japanese patients with chronic sinusitis. *Laryngoscope*. 1999;109:275-8.
317. Luxemberger W, Posch U, Berghold A, Hoffmann T, Lang-Loisdolt D. HLA patterns in patients with nasal polyposis. *Eur Arch Otorhinolaryngol*. 2000;257:137-9.
318. Keles B, Cora T, Acar H, Arbag H, Inan Z, Ozturk K, et al. Evaluation of HLA-A, -B, -Cw, and -DRB1 alleles frequency in Turkish patients with nasal polyposis. *Otolaryngol Head Neck Surg*. 2008;139:580-5.
319. Ramirez-Anguiano J, Yamamoto-Furuho JK, Barquera R, Beltrán O, Granados J. Association of HLA-DR3 and HLA-DR4 with sinonasal polyposis in Mexican Mestizos. *Otolaryngol Head Neck Surg*. 2006;135:90-3.
320. Zhai L, Sun Y, Tang L, Liu H. Polymorphism between loci for human leukocyte antigens DR and DQ in patients with nasal polyps. *Ann Otol Rhinol Laryngol*. 2007;116:66-8.
321. Sakano E, Ribeiro AF, Barth L, Condino Neto A, Ribeiro JD. Nasal and paranasal sinus endoscopy, computed tomography and microbiology of upper airways and the correlations with genotype and severity of cystic fibrosis. *Int J Pediatr Otorhinolaryngol*. 2007;71:41-50.
322. Irving RM, McMahon R, Clark R, Jones NS. Cystic fibrosis transmembrane conductance regulator gene mutations in severe nasal polyposis. *Clin Otolaryngol Allied Sci*. 1997;22:519-21.
323. Raman V, Clary R, Siegrist KL, Zehnbauser B, Chatila TA. Increased prevalence of mutations in the cystic fibrosis transmembrane conductance regulator in children with chronic rhinosinusitis. *Pediatrics*. 2002;109:E13.
324. Wang X, Kim J, McWilliams R, Cutting GR. Increased prevalence of chronic rhinosinusitis in carriers of a cystic fibrosis mutation. *Arch Otolaryngol Head Neck Surg*. 2005;131:237-40.
325. Wang X, Moylan B, Leopold DA, Kim J, Rubenstein RC, Toghias A, et al. Mutation in the gene responsible for cystic fibrosis and predisposition to chronic rhinosinusitis in the general population. *JAMA*. 2000;284:1814-9.
326. Sachse F, Becker K, Rudack C. Incidence of staphylococcal colonization and of the 753Q Toll-like receptor 2 variant in nasal polyposis. *Am J Rhinol Allergy*. 2010;24:e10-3.
327. Park CS, Cho JH, Park YJ. Toll-like receptor 2 gene polymorphisms in a Korean population: association with chronic rhinosinusitis. *Otolaryngol Head Neck Surg*. 2011;144:96-100.
328. Lee RJ, Xiong G, Kofonow JM, Chen B, Lysenko A, Juang P, et al. T2R38 taste receptor polymorphism underlie susceptibility to upper respiratory infection. *J Clin Invest*. 2012;122:4145-59.
329. Yazdani N, Amoli MM, Naraghi M, Mersaghian A, Firouzi F, Sayyehpour F, et al. Association between the functional polymorphism C-159T in the CD14 promoter gene and nasal polyposis: potential role in asthma. *J Invest Allergol Clin Immunol*. 2012;22:406-11.
330. Zhang Y, Endam LM, Filali-Mouhim A, Boussé Y, Castano R, Desrosiers M. Polymorphisms in the nitric oxide synthase 1 gene are associated with severe chronic rhinosinusitis. *Am J Rhinol Allergy*. 2011;25:e49-54.
331. Pascual M, Sanz C, Isidoro-Garcia M, Dávila I, Moreno E, Lafond E, et al. (CCTTT) $_n$ polymorphism of NOS2A in nasal polyposis and asthma: a case-control study. *J Invest Allergol Clin Immunol*. 2008;18:239-44.
332. Yea SS, Yang YI, Park SK, Jang WH, Lee SS, Seog DH, et al. Interleukin-4 C-590T polymorphism is associated with protection against nasal polyps in a Korean population. *Am J Rhinol*. 2006;20:550-3.
333. Kosugi EM, de Camargo-Kosugi CM, Weckx LL, Guerreiro-da-Silva ID, Gregório LC. Interleukin-6 -174 G/C promoter polymorphism and nasal polyposis. *Rhinology*. 2009;47:400-4.
334. Kosugi EM, de Camargo-Kosugi CM, Hirai ER, Mendes-Neto JA, Gregório LC, Guerreiro-da-Silva ID, et al. Interleukin-6 -174 G/C promoter gene polymorphism in nasal polyposis and asthma. *Rhinology*. 2013;51:70-6.
335. Palikhe NS, Kim SH, Cho BY, Choi GS, Kim JH, Ye YM, et al. IL-13 gene polymorphisms are associated with rhinosinusitis and eosinophilic inflammation in aspirin intolerant asthma. *Allergy Asthma Immunol Res*. 2010;2:134-40.
336. Buysschaert ID, Grulois V, Eloy P, Jorissen M, Rombaux P, Bertrand B, et al. Genetic evidence for a role of IL33 in nasal polyposis. *Allergy*. 2010;65:616-22.
337. Wang LF, Chien CY, Tai CF, Kuo WR, Hsi E, Juo SH. Matrix metalloproteinase-9 gene polymorphisms in nasal polyposis. *BMC Med Genet*. 2010;11:85.
338. Erbek SS, Yurtcu E, Erbek S, Sahin FI. Matrix metalloproteinase-9 promoter gene polymorphism (-1562C>T) in nasal polyposis. *Am J Rhinol Allergy*. 2009;23:568-70.
339. Kim SH, Park HS, Holloway JW, Shin HD, Park CS. Association between a TGF β 1 promoter polymorphism and rhinosinusitis in aspirin-intolerant asthmatic patients. *Respir Med*. 2007;101:490-5.
340. Kim SH, Yang EM, Lee HN, Cho BY, Ye YM, Park HS. Combined effect of IL-10 and TGF- β 1 promoter polymorphism as a risk factor for aspirin-intolerant asthma and rhinosinusitis. *Allergy*. 2009;64:1221-5.

341. de Alarcon A, Steinke JW, Caughey R, Barekzi E, Hise K, Gross CW, et al. Expression of leukotriene C4 synthase and plasminogen activator inhibitor 1 gene promoter polymorphisms in sinusitis. *Am J Rhinol*. 2006;20:545-9.
342. Benito Pescador D, Isidoro-Garcia M, Garcia-Solaesa V, Pascual de Pedro M, Sanz C, Hernandez-Hernandez L, et al. Genetic association study in nasal polyposis. *J Investig Allergol Clin Immunol*. 2012;22:331-40.
343. Zhang Y, Endam LM, Filali-Mouhim A, Zhao L, Desrosiers M, Han D, et al. Polymorphisms in RYBP and AOA genes are associated with chronic rhinosinusitis in a Chinese population: a replication study. *PLoS One*. 2012;7:e39247.
344. Marple BF, Stankiewicz JA, Baroody FM, Chow JM, Conley DB, Corey JP, et al. Diagnosis and management of chronic rhinosinusitis in adults. *Postgrad Med*. 2009;121:121-39.
345. Bhattacharyya N. Clinical and symptom criteria for the accurate diagnosis of chronic rhinosinusitis. *Laryngoscope*. 2006;116:1-22.
346. Numminen J, Ahtinen M, Huhtala H, Rautiainen M. Comparison of rhinometric measurements methods in intranasal pathology. *Rhinology*. 2003;41:65-8.
347. Hox V, Bobic S, Callebaut I, Jorissen M, Hellings PW. Nasal obstruction and smell impairment in nasal polyp disease: correlation between objective and subjective parameters. *Rhinology*. 2010;48:426-32.
348. Hughes RG, Jones NS. The role of nasal endoscopy in outpatient management. *Clin Otolaryngol Allied Sci*. 1998;23:224-6.
349. Bhattacharyya N, Lee LN. Evaluating the diagnosis of chronic rhinosinusitis based on clinical guidelines and endoscopy. *Otolaryngol Head Neck Surg*. 2010;143:147-51.
350. Lund VJ, Mackay IS. Staging in rhinosinusitis. *Rhinology*. 1993;31:183-4.
351. Araujo E, Dall C, Cantarelli V, Pereira A, Mariante AR. Microbiologia do meato médio na rinossinusite crônica. *Rev. Bras. Otorrinolaringol*. 2007;73:549-55.
352. Puchelle E, Aug F, Pham QT, Bertrand A. Comparison of three methods for measuring nasal mucociliary clearance in man. *Acta Otolaryngol*. 1981;91:297-303.
353. Jorissen M, Van der Schueren B, Van den Berghe H, Cassiman JJ. Contribution of *in vitro* culture methods for respiratory epithelial cells to the study of the physiology of the respiratory tract. *Eur Respir J*. 1991;4:210-7.
354. Colantonio D, Brouillette L, Parikh A, Scadding GK. Paradoxical low nasal nitric oxide in nasal polyposis. *Clin Exp Allergy*. 2002;32:698-701.
355. Holmstrom M, Scadding GK, Lund VJ, Darby YC. Assessment of nasal obstruction. A comparison between rhinomanometry and nasal inspiratory peak flow. *Rhinology*. 1990;28: 191-6.
356. Juto JE, Lundberg C. An optical method for determining changes in mucosal congestion in the nose in man. *Acta Otolaryngol*. 1982;94:149-56.
357. Scadding G. Diagnostic tools in Rhinology. EAACI position Paper. *Clin Transl Allergy*. 2011;1:39.
358. DeMarcantonio MA, Han JK. Nasal polyps: pathogenesis and treatment implications. *Otolaryngol Clin North Am*. 2011;44:685-95.
359. Littman DR, Pamer EG. Role of the commensal microbiota in normal and pathogenic host immune responses. *Cell Host Microbe*. 2011;10:311-23.
360. Pedersen M, Sakakura Y, Winther B, Brofeldt S, Mygind N. Nasal mucociliary transport, number of ciliated cells, and beating pattern in naturally acquired common colds. *Eur J Respir Dis Suppl*. 1983;128:355-65.
361. Duclos P, Sanderson LM, Lipsett M. The 1987 forest fire disaster in California: assessment of emergency room visits. *Arch Environ Health*. 1990;45:53-9.
362. Nachman KE, Parker JD. Exposures to fine particulate air pollution and respiratory outcomes in adults using two national datasets: a cross-sectional study. *Environ Health*. 2012;11:25.
363. Arbex MA1, Martins LC, de Oliveira RC, Pereira LA, Arbex FF, Cançado JE, et al. Air pollution from biomass burning and asthma hospital admissions in a sugar cane plantation area in Brazil. *J Epidemiol Community Health*. 2007;61:395-400.
364. Graudenz GS, Oliveira CH, Tribess A, Mendes C Jr., Latorre MR, Kalil J. Association of air-conditioning with respiratory symptoms in office workers in tropical climate. *Indoor Air*. 2005;15:62-6.
365. Fadda GL, Rosso S, Aversa S, Petrelli A, Ondolo C, Succo G. Multiparametric statistical correlations between paranasal sinus anatomic variations and chronic rhinosinusitis. *Acta Otorhinolaryngol Ital*. 2012;32:244-51.
366. Wagenmann M, Naclerio RM. Complications of sinusitis. *The Journal of allergy and clinical immunology*. 1992;90:552-4.
367. Jones NS, Strobl A, Holland I. A study of the CT findings in 100 patients with rhinosinusitis and 100 controls. *Clin Otolaryngol Allied Sci*. 1997;22:47-51.
368. Bolger WE, Butzin CA, Parsons DS. Paranasal sinus bony anatomic variations and mucosal abnormalities: CT analysis for endoscopic sinus surgery. *Laryngoscope*. 1991;101:56-64.
369. Holbrook EH, Brown CL, Lyden ER, Leopold DA. Lack of significant correlation between rhinosinusitis symptoms and specific regions of sinus computer tomography scans. *Am J Rhinol*. 2005;19:382-7.
370. Longhini AB, Branstetter BF, Ferguson BJ. Otolaryngologists' perceptions of odontogenic maxillary sinusitis. *Laryngoscope*. 2012;122:1910-4.
371. Levi ME, Eusterman VD. Oral infections and antibiotic therapy. *Otolaryngol Clin North Am*. 2011;44:57-78.
372. Adde F V, Rozov T. Teste da sacarina em crianças. *J Pneumol*. 1997;23:66-70.
373. Phipps CD, Wood WE, Gibson WS, Cochran WJ. Gastroesophageal reflux contributing to chronic sinus disease in children: a prospective analysis. *Arch Otolaryngol Head Neck Surg*. 2000;126:831-6.
374. Kaliner M. Treatment of sinusitis in the next millennium. *Allergy and asthma proceedings: the official journal of regional and state allergy societies*. 1998;19:181-4.
375. Krause HF. Allergy and chronic rhinosinusitis. *Otolaryngol Head Neck Surg*. 2003;128:14-6.
376. Jones NS, Carney AS, Davis A. The prevalence of allergic rhinosinusitis: a review. *J Laryngol Otol*. 1998;112:1019-30.
377. Bailey B. The impact of pollution on the upper alimentary and respiratory tracts. *Otolaryngol Head Neck Surg*. 1992;736-40.
378. Benninger MS. Rhinitis, sinusitis and their relationships to allergies. *Am J Rhinol*. 1992;6:37-43.
379. Emanuel IA, Shah SB. Chronic rhinosinusitis: allergy and sinus computed tomography relationships. *Otolaryngol Head Neck Surg*. 2000;123:687-91.
380. Grove R, Farrior J. Chronic hyperplastic sinusitis in allergic patients: a bacteriologic study of 200 operative cases. *J Allergy Clin Immunol*. 1990;11:271-6.
381. Karlsson G, Holmberg K. Does allergic rhinitis predispose to sinusitis? *Acta Otolaryngol Suppl*. 1994;515:26-8; discussion 9.
382. Settipane GA, Chafee FH. Nasal polyps in asthma and rhinitis. A review of 6,037 patients. *J Allergy Clin Immunol*. 1977;59:17-21.
383. Caplin I, Haynes JT, Spahn J. Are nasal polyps an allergic phenomenon? *Ann Allergy*. 1971;29:631-4.
384. Bunnag C, Pacharee P, Vipulakom P, Siriyananda C. A study of allergic factor in nasal polyp patients. *Ann Allergy*. 1983;50:126-32.
385. Blumstein GI, Tuft L. Allergy treatment in recurrent nasal polyposis: its importance and value. *Am J Med Sci*. 1957;234:269-80.
386. English G. Nasal polyposis. E G, editor. Philadelphia: Harper and Row; 1985.
387. Drake-Lee AB. Histamine and its release from nasal polyps: preliminary communication. *J R Soc Med*. 1984;77:120-4.

388. Settipane GA, Lund VJ, Bernstein JM, Tos M. Epidemiology of nasal polyps. In: Settipane GA, Lund VJ, Bernstein JM, Tos M (Eds). *Nasal Polyps: Epidemiology, Pathogenesis and Treatment*. Providence, Rhode Island: OceanSide Publications, Inc., 1997. pp. 17-24.
389. Liu CM, Shun CT, Hsu MM. Lymphocyte subsets and antigen-specific IgE antibody in nasal polyps. *Ann Allergy*. 1994;72:19-24.
390. Bachert C, Gevaert P, Holtappels G, Johansson SG, van Cauwenberge P. Total and specific IgE in nasal polyps is related to local eosinophilic inflammation. *J Allergy Clin Immunol*. 2001;107:607-14.
391. Taylor MB, Tan IT, Chan KT, Shen L, Shi L, Wang DY. A prospective study of bacterial flora in nasal cavity of patients with persistent allergic rhinitis. *Rhinology*. 2012;50:139-46.
392. Bousquet J, Van Cauwenberge P, Khaltaev N. Allergic rhinitis and its impact on asthma. *J Allergy Clin Immunol*. 2001;108:S147-334.
393. Jarvis D, Newson R, Lotvall J, Hastan D, Tomassen P, Keil T, et al. Asthma in adults and its association with chronic rhinosinusitis: the GA2LEN survey in Europe. *Allergy*. 2012;67:91-8.
394. Klossek JM, Neukirch F, Pribil C, Jankowski R, Serrano E, Chantal I, et al. Prevalence of nasal polyposis in France: a cross-sectional, case-control study. *Allergy*. 2005;60:233-7.
395. Downing E. Bronchial reactivity in patients with nasal polyposis before and after polypectomy. *J Allergy Clin Immunol*. 1982;69:102.
396. Salvin RG, Cannon RE, Friedman WH, Palitang E, Sundaram M. Sinusitis and bronchial asthma. *J Allergy Clin Immunol*. 1980;66:250-7.
397. Schwartz HJ, Thompson JS, Sher TH, Ross RJ. Occult sinus abnormalities in the asthmatic patient. *Arch Intern Med*. 1987;147:2194-6.
398. Serrano E, Neukirch F, Pribil C, Jankowski R, Klossek JM, Chantal I, et al. Nasal polyposis in France: Impact on sleep and quality of life. *J Laryngol Otol*. 2005;119:543-9.
399. Alobid I, Cardelus S, Benitez P, Guilemany JM, Roca-Ferrer J, Picado C, et al. Persistent asthma has an accumulative impact on the loss of smell in patients with nasal polyposis. *Rhinology*. 2011;49:519-24.
400. Chafee FH, Settipane GA. Aspirin intolerance. I. Frequency in an allergic population. *J Allergy Clin Immunol*. 1974:193-9.
401. Weber RW, Hoffman M, Raine DA Jr., Nelson HS. Incidence of bronchoconstriction due to aspirin, azo dyes, non-azo dyes, and preservatives in a population of perennial asthmatics. *J Allergy Clin Immunol*. 1979;64:32-7.
402. Szczeklik A, Gryglewski RJ, Czerniawska-Mysik G. Clinical patterns of hypersensitivity to nonsteroidal anti-inflammatory drugs and their pathogenesis. *J Allergy Clin Immunol*. 1977;60:276-84.
403. Spector SL, Wangaard CH, Farr RS. Aspirin and concomitant idiosyncrasies in adult asthmatic patients. *J Allergy Clin Immunol*. 1979;64:500-6.
404. Ogino S. Aspirin-induced asthma and nasal polyps. *Acta Otolaryngol Suppl*. 1986;(430):21-7.
405. Szczeklik A, Stevenson DD. Aspirin-induced asthma: advances in pathogenesis and management. *J Allergy Clin Immunol*. 1999;104:5-13.
406. May A, Wagner D, Langenbeck U, Weber A. Family study of patients with aspirin intolerance and rhinosinusitis. *HNO*. 2000;48:650-4.
407. Zhang N, Gevaert P, van Zele T, Perez-Novo C, Patou J, Holtappels G, et al. An update on the impact of *Staphylococcus aureus* enterotoxins in chronic sinusitis with nasal polyposis. *Rhinology*. 2005;43:162-8.
408. Godoy JM, Godoy AN, Ribalta G, Largo I. Bacterial pattern in chronic sinusitis and cystic fibrosis. *Otolaryngol Head Neck Surg*. 2011;145:673-6.
409. Smyth AR, Barbato A, Beydon N, Bisgaard H, de Boeck K, Brand P et al. Respiratory medicines for children: current evidence, unlicensed use and research priorities. *Eur Respir J*. 2010;35:247-65.
410. Mainz JG, Koitschev A. Management of chronic rhinosinusitis in CF. *J Cyst Fibros*. 2009;8:S10-4.
411. Diretrizes Brasileiras de Rinossinusites. *Rev Bras Otorrinolaringol*. 2008;74:6-59.
412. Dubin MG, Liu C, Lin SY, Senior BA. American Rhinologic Society member survey on "maximal medical therapy" for chronic rhinosinusitis. *Am J Rhinol*. 2007;21:483-8.
413. Pandak N, Pajić-Penavić I, Sekelj A, Tomić-Paradžik M, Cabraja I, Miklašević B. Bacterial colonization or infection in chronic sinusitis. *Wien Klin Wochenschr*. 2011;123:710-3.
414. Cleland EJ, Bassiouni A, Wormald PJ. The bacteriology of chronic rhinosinusitis and the pre-eminence of *Staphylococcus aureus* in revision patients. *Int Forum Allergy Rhinol*. 2013;3:642-6.
415. Cleland EJ, Drilling A, Bassiouni A, James C, Veugrede S, Wormald PJ. Probiotic manipulation of the chronic rhinosinusitis microbiome. *Int Forum Allergy Rhinol*. 2014;4:309-14.
416. Piroomchai P, Kasemsiri P, Laohasiriwong S, Thanaviratnanich S. Chronic rhinosinusitis and emerging treatment options. *Int J Gen Med*. 2013;6:453-64.
417. Adelson RT, Adappa ND. What is the proper role of oral antibiotics in the treatment of chronic sinusitis? *Curr Opin Otolaryngol Head Neck Surg*. 2013;21:61-8.
418. Soler ZM, Oyer SL, Kern RC, Senior BA, Kountakis SE, Marple BF, et al. Antimicrobials and chronic rhinosinusitis with or without polyposis in adults: an evidenced-based review with recommendations. *Int Forum Allergy Rhinol*. 2013;3:31-47.
419. Mandal R, Patel N, Ferguson BJ. Role of antibiotics in sinusitis. *Curr Opin Infect Dis*. 2012;25:183-92.
420. Piroomchai P, Thanaviratnanich S, Laopaiboon M. Systemic antibiotics for chronic rhinosinusitis without nasal polyps in adults. *Cochrane Database Syst Rev*. 2011;(5):CD008233.
421. Meltzer EO, Hamilos DL. Rhinosinusitis diagnosis and management for the clinician: a synopsis of recent consensus guidelines. *Mayo Clin Proc*. 2011;86:427-43.
422. Van Zele T, Gevaert P, Holtappels G, Beule A, Wormald PJ, Mayr S, et al. Oral steroids and doxycycline: two different approaches to treat nasal polyps. *J Allergy Clin Immunol*. 2010;125:1069-76.e4.
423. Ferguson BJ, Narita M, Yu VL, Wagener MM, Gwaltney JM Jr. Prospective observational study of chronic rhinosinusitis: environmental triggers and antibiotic implications. *Clin Infect Dis*. 2012;54:62-8.
424. Schalek P, Petrás P, Klement V, Hahn A. Short-term antibiotics treatment in patients with nasal polyps and enterotoxins producing *Staphylococcus aureus* strains. *Eur Arch Otorhinolaryngol*. 2009;266:1909-13.
425. Liu CM, Soldanova K, Nordstrom L, Dwan MG, Moss OL, Contente-Cuomo TL, et al. Medical therapy reduces microbiota diversity and evenness in surgically recalcitrant rhinosinusitis. *Int Forum Allergy Rhinol*. 2013;3:775-81.
426. Videler WJ, Badia L, Harvey RJ, Gane S, Georgalas C, van der Meulen FW, et al. Lack of efficacy of long term low-dose azithromycin in chronic rhinosinusitis: a randomized controlled trial. *Allergy*. 2011;66:1457-68.
427. Wallwork B, Coman W, Mackay-Sim A, Greiff L, Cervin A. A double-blind, randomized, placebo-controlled trial of macrolide in the treatment of chronic rhinosinusitis. *Laryngoscope*. 2006;116:189-93.
428. Videler WJ, van Hee K, Reinartz SM, Georgalas C, van der Meulen FW, Fokkens WJ. Long term low-dose antibiotics in recalcitrant chronic rhinosinusitis: a retrospective analysis. *Rhinology*. 2012;50:45-55.

429. Majima Y, Kurono Y, Hirakawa K, Ichimura K, Haruna S, Suzuki H, et al. Efficacy of combined treatment with S-carboxymethylcysteine (carbocisteine) and clarithromycin in chronic rhinosinusitis patients without nasal polyp or with small nasal polyp. *Auris Nasus Larynx*. 2012;39:38-47.
430. Wong KK, Marglani O, Westerberg BD, Javer AR. Systemic absorption of topical gentamicin sinus irrigation. *J Otolaryngol Head Neck Surg*. 2008;37:395-8.
431. Hilton C, Wiedmann T, St Martin M, Humphrey BM, Schieffarth R, Rimell F. Differential deposition of aerosols in the maxillary sinus of human cadáveres by particle size. *Am J Rhinol*. 2008;22:395-8.
432. Huang A, Govindaraj S. Topical therapy in the management of chronic rhinosinusitis. *Curr Opin Otolaryngol Head Neck Surg*. 2013;21:31-8.
433. Videler JW, van Drunen CM, Reitsma JB, Fokkens WJ. Nebulized bacitracin/colimycin: a treatment option in recalcitrant chronic rhinosinusitis with *Staphylococcus aureus*? A double-blind, randomized, placebo-controlled, cross-over pilot study. *Rhinology*. 2008;46:92-8.
434. Csomor P, Sziklai I, Karosi T. Effects of intranasal steroid treatment on the presence of biofilms in non-allergic patients with chronic rhinosinusitis with nasal polyposis. *Eur Arch Otorhinolaryngol*. 2013 Aug 25. [Epub ahead of print]
435. Goggin R, Jardeleza C, Wormald PJ, Vreugde S. Corticosteroids directly reduce *Staphylococcus aureus* biofilm growth: An *in vitro* study. *Laryngoscope*. 2014;124:602-7.
436. Snidvongs K, Kalish L, Sacks R, Sivasubramaniam R, Cope D, Harvey RJ. Sinus surgery and delivery method influence the effectiveness of topical corticosteroids for chronic rhinosinusitis: systematic review and meta-analysis. *Am J Rhinol Allergy*. 2013;27:221-33.
437. Wei CC, Adappa ND, Cohen NA. Use of topical nasal therapies in the management of chronic rhinosinusitis. *Laryngoscope*. 2013;123:2347-59.
438. Rudmik L, Schlosser RJ, Smith TL, Soler ZM. Impact of topical nasal steroid therapy on symptoms of nasal polyposis: a meta-analysis. *Laryngoscope*. 2012;122:1431-7.
439. Kalish L, Snidvongs K, Sivasubramaniam R, Cope D, Harvey RJ. Topical steroids for nasal polyps. *Cochrane Database Syst Rev*. 2012;12:CD006549.
440. Lal D, Hwang PH. Oral corticosteroid therapy in chronic rhinosinusitis without polyposis: a systematic review. *Int Forum Allergy Rhinol*. 2011; 136-43.
441. Poetker DM, Jakubowski LA, Lal D, Hwang PH, Wright ED, Smith TL. Oral corticosteroids in the management of adult chronic rhinosinusitis with and without nasal polyps: an evidence-based review with recommendations. *Int Forum Allergy Rhinol*. 2013;3:104-20.
442. Van Crombruggen K, Zhang N, Gevaert P, Tomassen P, Bachert C. Pathogenesis of chronic rhinosinusitis: inflammation. *J Allergy Clin Immunol*. 2011;128:728-32.
443. Roca-Ferrer J, Garcia-Garcia FJ, Pereda, Perez-Gonzalez M, Pujols L, Alobid I, et al. Reduced expression of COXs and production of prostaglandin E(2) in patients with nasal polyps with or without aspirin-intolerant asthma. *J Allergy Clin Immunol*. 2011;128:66-72.
444. Bousquet J, Khaltaev N, Cruz AA, Denburg J, Fokkens WJ, Togias A, et al. Allergic Rhinitis and its Impact on Asthma (ARIA) 2008 update (in collaboration with the World Health Organization, GA(2)LEN and AllerGen). *Allergy*. 2008;63:8-160.
445. Mullol J, Callejas FB, Méndez-Arancibia E, Fuentes M, Alobid I, Martínez-Antón A, et al. Montelukast reduces eosinophilic inflammation by inhibiting both epithelial cell cytokine secretion (GM-CSF, IL-6, IL-8) and eosinophil survival. *J Biol Regul Homeost Agents*. 2010;24:403-11.
446. Di Capite J, Nelson C, Bates G, Parekh AB. Targeting Ca2p release-activated Ca2p channel channels and leukotriene receptors provides a novel combination strategy for treating nasal polyposis. *J Allergy Clin Immunol*. 2009;124:1014-21.e1-3.
447. Guilemany JM, Alobid I, Mullol J. Controversies in the treatment of chronic rhinosinusitis. *Expert Rev Respir Med*. 2010;4:463-77.
448. Nayak A, Langdon RB. Montelukast in the treatment of allergic rhinitis. *Drugs*. 2007;67:887-901.
449. Brozek JL, Bousquet J, Baena-Cagnani CE, Bonini S, Canonica GW, Casale TB, et al. Allergic Rhinitis and its Impact on Asthma (ARIA) guidelines: 2010 revision. *J Allergy Clin Immunol*. 2010;126:466-76.
450. Ragab S, Parikh A, Darby YC, Scadding GK. An open audit of montelukast, a leukotriene receptor antagonist, in nasal polyposis associated with asthma. *Clin Exp Allergy*. 2001;31:1385-91.
451. Kieff DA, Busaba NY. Efficacy of montelukast in the treatment of nasal polyposis. *Ann Otol Rhinol Laryngol*. 2005;114:941-5.
452. Dahlén B, Nizankowska E, Szczeklik A, Zetterström O, Bochenek G, Kumlin M, et al. Benefits from adding the 5-lipoxygenase inhibitor zileuton to conventional therapy in aspirin-intolerant asthmatics. *Am J Respir Crit Care Med*. 1998;157:1187-94.
453. Parnes SM, Chuma AV. Acute effects of antileukotrienes on sinonasal polyposis and sinusitis. *Ear Nose Throat J*. 2000;79:18-20, 24-25.
454. Nonaka M, Sakanushi A, Kusama K, Ogiwara N, Yagi T. One-year evaluation of combined treatment with an intranasal corticosteroid and montelukast for chronic rhinosinusitis associated with asthma. *J Nippon Med Sch*. 2010;77:21-8.
455. Pauli C, Fintelmann R, Klemens C, Hilgert E, Jund F, Rasp G, et al. Polyposis nasi-improvement in quality of life by the influence of leukotriene receptor antagonists. *Laryngorhinotologie*. 2007;86:282-6.
456. Stewart RA, Ram B, Hamilton G, Weiner J, Kane KJ. Montelukast as an adjunct to oral and inhaled steroid therapy in chronic nasal polyposis. *Otolaryngol Head Neck Surg*. 2008;139:682-7.
457. Mostafa BE, Abdel H, Mohammed HE, Yamani M. Role of leukotriene inhibitors in the postoperative management of nasal polyps. *ORL J Otorhinolaryngol Relat Spec*. 2005;67:148-53.
458. Dahlén SE, Nizankowska E, Dahlén B. The Swedish-Polish treatment study with the 5-lipoxygenase inhibitor Zileuton in aspirin-intolerant asthmatics. *Am J Resp Crit Care Med*. 1995;151:370-6.
459. Ferguson BJ, Otto BA, Pant H. When surgery, antibiotics, and steroids fail to resolve chronic rhinosinusitis. *Immunol Allergy Clin North Am*. 2009;29:719-32.
460. Vuralcan E, Saka C, Akin I, Hucumenoglu S, Unal B. U, Kuran G et al. Comparison of montelukast and mometasone furoate in the prevention of recurrent nasal polyps. *Ther Adv Respir Dis*. 2012;6:5-10.
461. Alobid I, Mullol J. Role of medical therapy in the management of nasal polyps. *Curr Allergy Asthma Rep*. 2012;12:144-53.
462. Scadding GW, Scadding GK. Recent advances in antileukotriene therapy. *Curr Opin Allergy Clin Immunol*. 2010;10:370-6.
463. Graefe H, Roebke C, Schäfer D, Meyer JE. Aspirin sensitivity and chronic rhinosinusitis with polyps: a fatal combination. *J Allergy (Cairo)*. 2012;2012:817-910.
464. Rizk H. Role of aspirin desensitization in the management of chronic rhinosinusitis. *Curr Opin Otolaryngol Head Neck Surg*. 2011;19:210-7.
465. Kutlu A, Salihoglu M, Haholu A, Cesmeçi E, Cincik H, Ozturk S. Short-term Beneficial Effect of Aspirin in Patient with Chronic Rhinosinusitis and Tolerant to Acetylsalicylic Acid. *Iran J Allergy Asthma Immunol*. 2013;12:400-3.
466. Valada DB, Motta AA. Reações adversas aos anti-inflamatórios não esteroidais. *Rev Bras Alerg Immunopatol*. 2009;32:27-33.
467. Xu JJ, Sowerby L, Rotenberg BW. Aspirin desensitization for aspirin-exacerbated respiratory disease (Samter's Triad): a systematic review of the literature. *Int Forum Allergy Rhinol*. 2013;3:915-20.

468. Garcia Cruz ML, Jimenez-Chobillon MA, Teran LM. Rhinosinusitis and aspirin-exacerbated respiratory disease. *J Allergy (Cairo)*. 2012;2012:273-752.
469. Miller B, Mirakian R, Gane S, Larco J, Sannah AA, Darby Y et al. Nasal lysine aspirin challenge in the diagnosis of aspirin-exacerbated respiratory disease: asthma and rhinitis. *Clin Exp Allergy*. 2013;43:874-80.
470. Klimek L, Pfaar O. Aspirin Intolerance: Does desensitization alter the course of the disease? *Immunol Allergy Clin North Am*. 2009;29:669-75.
471. Lee R, White AA, Ding D, Dursun AB, Woessner KM, Simon RA et al. Use of intranasal ketorolac and modified oral aspirin challenge for desensitization of aspirin-exacerbated respiratory disease. *Ann Allergy Asthma Immunol*. 2010;105:130-5.
472. Chang JE, Chin W, Simon R. Aspirin-sensitive asthma and upper airway diseases. *Am J Rhinol Allergy*. 2012;26:27-30.
473. Palikhe NS, Kim JH, Park HS. Update on Recent Advances in the Management of Aspirin Exacerbated Respiratory Disease. *Yonsei Med J*. 2009;50:744-50.
474. Choi GS, Kim JH, Shin YM, Ye Kim SH, Park HS. Eosinophil activation and novel mediators in the aspirin-induced nasal response in AERD. *Clin Exp Allergy*. 2013;43:730-40.
475. Burnett T, Katial R, Alam R. Mechanisms of aspirin desensitization. *Immunol Allergy Clin North Am*. 2013;33:223-36.
476. Rachel U, Lee RU, Stevenson DD. Aspirin-exacerbated respiratory disease: evaluation and management. *Allergy Asthma Immunol Res*. 2011;3:3-10.
477. Ponikau JU, Sherris DA, Kita H, Kern EB. Intranasal antifungal treatment in patients with chronic rhinosinusitis. *J Allergy Clin Immunol*. 2002;110:862-6.
478. Kern EB, Sherris D, Stergiou AM, Katz LM, Rosenblatt LC, Ponikau J. Diagnosis and treatment of chronic rhinosinusitis: focus on intranasal Amphotericin B. *Ther Clin Risk Manag*. 2007;3:19-25.
479. Corradini C, Del Ninno M, Buonomo A, Nucera E, Paludetti G, Alonzi C, et al. Amphotericin B and lysine acetylsalicylate in the combined treatment of nasal polyposis associated with mycotic infection. *J Investig Allergol Clin Immunol*. 2006;16:188-93.
480. Gerlinger I, Fittler A, Fónai F, Patzkó A, Mayer A, Botz L. Post-operative application of amphotericin B nasal spray in chronic rhinosinusitis with nasal polyposis, with a review of the antifungal therapy. *Eur Arch Otorhinolaryngol*. 2009;266:847-55.
481. Helbing A, Baumann A, Hanni C, Caversaccio M. Amphotericin B nasal spray has no effect on nasal polyps. *J Laryngol Otol*. 2006;120:1023-5.
482. Weschta M, Rimek D, Formanek M, Polzehl D, Podbielski A, Riechelmann H. Topical antifungal treatment of chronic rhinosinusitis with nasal polyps: a randomized, double-blind clinical trial. *J Allergy Clin Immunol*. 2004;113:1122-8.
483. Montone KT. Role of fungi in the pathophysiology of chronic rhinosinusitis: an update. *Curr Allergy Asthma Rep*. 2013;13:224-8.
484. Khalil Y, Tharwat A, Abdou AG, Essa E, Elsayy AH, Elnakib O, et al. The role of antifungal therapy in the prevention of recurrent allergic fungal rhinosinusitis after functional endoscopic sinus surgery: A randomized, controlled study. *Ear Nose Throat J*. 2011;90:E1-7.
485. Sacks PL 4th, Harvey RJ, Rimmer J, Gallagher RM, Sacks R. Antifungal therapy in the treatment of chronic rhinosinusitis: a meta-analysis. *Am J Rhinol Allergy*. 2012;26:141-7.
486. Sacks PL, Harvey RJ, Rimmer J, Gallagher RM, Sacks R. Topical and systemic antifungal therapy for the symptomatic treatment of chronic rhinosinusitis. *Cochrane Database Syst Rev*. 2011;(8):CD008263.
487. Stankiewicz JA, Musgrave BK, Scianna JM. Nasal amphotericin irrigation in chronic rhinosinusitis. *Curr Opin Otolaryngol Head Neck Surg*. 2008;16:44-6.
488. Murr AH, Goldberg AN, Pletcher SD, Dillehay K, Wymer LJ, Vesper SJ. Some chronic rhinosinusitis patients have elevated populations of fungi in their sinuses. *Laryngoscope*. 2012;122:1438-45.
489. Ricchetti A1, Landis BN, Maffioli A, Giger R, Zeng C, Lacroix JS. Effect of antifungal nasal lavage with amphotericin B on nasal polyposis. *J Laryngol Otol*. 2002;116:261-3.
490. Jornot L, Rochat T, Lacroix JS. Nasal polyps and middle turbinates epithelial cells sensitivity to amphotericin B. *Rhinology*. 2003;41:201-5.
491. Javer AR, Chan KO. Itraconazole in the treatment of refractory allergic fungal rhinosinusitis. *Otolaryngol Head Neck Surg*. 2004;131:P54.
492. Chan KO, Genoway KA, Javer AR. Effectiveness of itraconazole in the management of refractory allergic fungal rhinosinusitis. *J Otolaryngol Head Neck Surg*. 2008;37:870-4.
493. Rains BM III, Mineck CW. Treatment of allergic fungal sinusitis with high-dose itraconazole. *Am J Rhinol*. 2003;17:1-8.
494. Jen A, Kacker A, Huang C, Anand V. Fluconazole nasal spray in the treatment of allergic fungal sinusitis: A pilot study. *Ear Nose Throat J*. 2004;83:692, 694-5.
495. Ottoline ACX, Tomita S, Marques MPC, Felix F, Ferraioli PN, Laurindo RSS. Antibiotic prophylaxis in otolaryngologic surgery. *Int. Arch. Otorhinolaryngol*. 2013;17:85-91.
496. Portela RA, Hootnick J, McGinn J. Perioperative care in functional endoscopic sinus surgery: a survey study. *Int Forum Allergy Rhinol*. 2012;2:27-33.
497. Tysome J, Sharp H. Current trends in pre and postoperative management of functional endoscopic sinus surgery. *IJORL*. 5(2). Disponível em: <http://ispub.com/IJORL/5/2/12413>. Acessado em 20/09/2013.
498. Hwang PH, Nayak JV, Wang JY. Endoscopic Sinus Surgery: A Patient's Guide. Disponível em: http://med.stanford.edu/ohns/patient_care/sinus_guide.html. Acessado em 20/09/2013.
499. Preparing for Endoscopic Sinus Surgery. Disponível em: http://www.hopkinsmedicine.org/sinus/patient_information/preparing_for_endoscopic_sinus_surgery.html. Acessado em 20/09/2013.
500. Cirurgia endoscópica dos seios paranasais. Disponível em: http://www.otorrinousp.org.br/imageBank/seminarios/seminario_76.pdf. Acessado em 20/09/2013.
501. Maier W, Strutz J. Perioperative single dose prevention with cephalosporins in the ENT area. A prospective randomized study. *Laryngorhinootologie*. 1992;71:365-9.
502. Scottish Intercollegiate Guidelines Network. Antibiotic prophylaxis in surgery. A national clinical guideline. Edinburgh, Scotland: Scottish Intercollegiate Guidelines Network; 2008, 67p.
503. Bratzler DW, Dellinger EP, Olsen KM, Perl TM, Auwaerter PG, Bolon MK, et al. Clinical practice guidelines for antimicrobial prophylaxis in surgery. *Surg Infect (Larchmt)*. 2013;14:73-156.
504. Quintero GA, Sefair C, Ferraz EM, Ferraina P, Robledo F, Hartman C. Manual Latino-americano de Guias Baseadas na Evidência - SHEA. Estratégias para a Prevenção da Infecção Associada ao Atendimento na Saúde - ESPIAAS. 2009. 184p. Disponível em: www.shea-online.org. Acessado em 20/09/2013.
505. Albert Stein - Sociedade Beneficente Israelita Brasileira. Profilaxia antimicrobiana em cirurgia. Manual Farmacêutico. Disponível em www.einstein.br. Acessado em 20/09/2013.
506. Protocolo de antibioticoprofilaxia no paciente cirúrgico. 2014. Disponível em: www.hospitalsiriolibanes.org.br/.../protocolo-antibioticoprofilaxia.pdf. Acessado em 20/09/2013.
507. Wright ED, Agrawal S. Impact of perioperative systemic steroids on surgical outcomes in patients with chronic rhinosinusitis with polyposis: evaluation with the novel Perioperative Sinus Endoscopy (POSE) scoring system. *Laryngoscope*. 2007;117:1-28.

508. Atighechi S, Azimi MR, Mirvakili SA, Baradaranfar MH, Dadgarnia MH. Evaluation of intraoperative bleeding during an endoscopic surgery of nasal polyposis after a pre-operative single dose *versus* a 5-day course of corticosteroid. *Eur Arch Otorhinolaryngol*. 2013;270:2451-4.
509. Albu S, Gocea A, Mitre I. Preoperative treatment with topical corticoids and bleeding during primary endoscopic sinus surgery. *Otolaryngol Head Neck Surg*. 2010;143:573-8.
510. Dalgorf DM, Sacks R, Wormald PJ, Naidoo Y, Panizza B, Uren B, et al. Image-guided surgery influences perioperative from ESS: a systematic review and meta-analysis. *Otolaryngol Head Neck Surg*. 2013;149:17-29.
511. Ahmed J, Pal S, Hopkins C, Jayaraj S. Functional endoscopic balloon dilation of sinus ostia for chronic rhinosinusitis. *Cochrane Database Syst Rev*. 2011 Jul 6;(7):CD008515.
512. Naidoo Y, Bassiouni A, Keen M, Wormald PJ. Long-term outcomes for the endoscopic modified Lothrop/Draf III procedure: a 10-year review. *Laryngoscope*. 2014;124:43-9.
513. Kennedy DW, Zinreich SJ, Rosenbaum AE, Johns ME. Functional endoscopic sinus surgery: theory and diagnosis. *Arch Otolaryngol*. 1985;111:576-82.
514. Stammberger H. Endoscopic endonasal surgery - concepts in treatment of recurring rhinosinusitis. Part II. Surgical technique. *Otolaryngol Head Neck Surg*. 1986;94:147-56.
515. Fellip A. Nasal centripetal endoscopic sinus surgery. *Ann Otol Rhinol Laryngol*. 2011;120:581-5.
516. Catalano PJ, Strouch M. The minimally invasive sinus technique: theory and practice. *Otolaryngol Clin North Am*. 2004;37:401-9, viii.
517. Setliff RC 3rd. Minimally invasive sinus surgery: the rationale and the technique. *Otolaryngol Clin North Am*. 1996;29:115-24.
518. Jankowski R, Pigret D, Decroocq F, Blum A, Gillet P. Comparison of radical (nasalization) and functional ethmoidectomy in patients with severe sinonasal polyposis. A retrospective study. *Rev Laryngol Otol Rhinol (Bord)*. 2006;127:131-40.
519. Masterson L, Tanweer F, Bueser T, Leong P. Extensive endoscopic sinus surgery: does this reduce the revision rate for nasal polyposis? *Eur Arch Otorhinolaryngol*. 2010;267:1557-61.
520. Wu AW, Ting JY, Platt MP, Tierney HT, Metson R. Factors affecting time to revision sinus surgery for nasal polyps: a 25-year experience. *Laryngoscope*. 2014;124:29-33.
521. Smith TL, Batra PS, Seiden AM, Hannley M. Evidence supporting endoscopic sinus surgery in the management of adult chronic rhinosinusitis: a systematic review. *Am J Rhinol*. 2005;19:537-43.
522. Chester AC, Antisdell JL, Sindwani R. Symptom-specific outcomes of endoscopic sinus surgery: a systematic review. *Otolaryngol Head Neck Surg*. 2009;140:633-9.
523. Dalziel K, Stein K, Round A, Garside R, Royle P. Endoscopic sinus surgery for the excision of nasal polyposis: a systematic review of safety and effectiveness. *Am J Rhinol*. 2006;20:506-19.
524. Mendelsohn D, Jeremic G, Wright ED, Rotenberg BW. Revision rates after endoscopic sinus surgery: a recurrence analysis. *Ann Otol Rhinol Laryngol*. 2011;120:162-6.
525. Bassiouni A, Naidoo Y, Wormald PJ. When FESS fails: the inflammatory load hypothesis in refractory chronic rhinosinusitis. *Laryngoscope*. 2012;122:460-6.
526. Snidvongs K, Chin D, Sacks R, Earls P, Harvey RJ. Eosinophilic rhinosinusitis is not a disease of ostiomeatal occlusion. *Laryngoscope*. 2013;123:1070-4.
527. Lee JM, Chiu AG. Role of maximal endoscopic sinus surgery techniques in chronic rhinosinusitis. *Otolaryngol Clin N Am*. 2010;43:579-89, ix.
528. Cho D, Hwang PH. Results of endoscopic maxillary mega-anthroscopy in recalcitrant maxillary sinusitis. *Am J Rhinol*. 2008;22:658-62.
529. Anderson P, Sindwani R. Safety and efficacy of the endoscopic modified Lothrop procedure: a systematic review and meta-analyses. *Laryngoscope*. 2009;119:1828-33.
530. Cornet ME, Reinartz SM, Georgalas C, van Spronsen E, Fokkens WJ. The microdebrider, a step forward or an expensive gadget? *Rhinology*. 2012;50:191-8.
531. Kacker A, Tabaei A, Anand V. Computer-assisted surgical navigation in revision endoscopic sinus surgery. *Otolaryngol Clin North Am*. 2005;38:473-82, vi.
532. Tomazic PV, Stammberger H, Braun H, Habermann W, Schmid C, Hammer GP, et al. Feasibility of balloon sinuplasty in patients with chronic rhinosinusitis: the Gratz experience. *Rhinology*. 2013;51:120-7.
533. Koskinen A, Penttilä M, Myller J, Hammarén-Malmi S, Silvola J, Haahtela T, et al. Endoscopic sinus surgery might reduce exacerbations and symptoms more than balloon sinuplasty. *Am J Rhinol Allergy*. 2012;26:150-56.
534. Plaza G, Eisenberg G, Montojo J, Onrubia T, Urbasos M, O'Connor C. Balloon dilation of the frontal recess: a randomized clinical trial. *Ann Otol Rhinol Laryngol*. 2011;120:511-8.
535. Welch KC, Stankiewicz JA. A contemporary review of endoscopic sinus surgery: techniques, tools and outcomes. *Laryngoscope*. 2009;119:2258-68.
536. Harvey RJ, Psaltis A, Schlosser RJ, Witterick IJ. Current concepts in topical therapy for chronic sinonasal disease. *J Otolaryngol Head Neck Surg*. 2010;39:217-31.
537. Moller W, Schuschnig U, Celik G, Munzings W, Bartenstein P, Haussinger P, et al. Topical Drug delivery in chronic rhinosinusitis patients before and after sinus surgery using pulsating aerosols. *PLoS One*. 2013;6:e74991.
538. Harvey RJ, Goddard JC, Wise SK, Schlosser RJ. Effects of endoscopic sinus surgery and delivery device on cadavers in us irrigation. *Otolaryngol Head Neck Surg*. 2008;139:137-42.
539. Snidvongs K, Chaowanapanja P, Aumjaturapat S, Chusakul S, Praweswararat P. Does nasal irrigation enter paranasal sinuses in chronic rhinosinusitis? *Am J Rhinol*. 2008;22:483-6.
540. Grobler A, Weitzel EK, Buele A, Jardeleza C, Cheong YC, Field J, et al. Pre- and postoperative sinus penetration of nasal irrigation. *Laryngoscope*. 2008;118:2078-81.
541. Rowe-Jones JM1, Medcalf M, Durham SR, Richards DH, Mackay IS. Functional endoscopic sinus surgery: 5 year follow up and results of a prospective, randomised, stratified, double-blind, placebo controlled study of postoperative fluticasone propionate aqueous nasal spray. *Rhinology*. 2005;43:2-10.
542. Jorissen M, Bachert C. Effect of corticosteroids on wound healing after endoscopic sinus surgery. *Rhinology*. 2009;47:280-6.
543. Stjerne P, Olsson P, Alenius M. Use of mometasone furoate to prevent polyp relapse after endoscopic sinus surgery. *Arch Otolaryngol Head Neck Surg*. 2009;135:296-302.
544. Dijkstra MD, Ebbens FA, Poulblon RM, Fokkens WJ. F Fluticasone propionate aqueous nasal spray does not influence the recurrence rate of chronic rhinosinusitis and nasal polyps 1 year after functional endoscopic sinus surgery. *Clin Exp Allergy*. 2004;34:1395-400.
545. Baradaranfar MH, Ahmadi ZS, Dadgarnia MH, Bermanian MH, Atighechi S, Karimi G, et al. Comparison of effect of endoscopic sinus surgery *versus* medical therapy on olfaction in nasal polyposis. *Eur Arch Otorhinolaryngol*. 2014;271:311-6.
546. Snidvongs K, Kalish L, Sacks R, Craig JC, Harvey RJ. Topical steroid for chronic rhinosinusitis without polyps. *Cochrane Database Syst Rev*. 2011;(8):CD009274.
547. Fandiño M, Macdonald KI, Lee J, Witterick IJ. The use of post-operative topical corticosteroids in chronic rhinosinusitis with nasal polyps: a systematic review and meta-analysis. *Am J Rhinol Allergy*. 2013;27:e146-57.
548. Adappa ND, Wei CC, Palmer JN. Nasal irrigation with or without drugs: the evidence. *Curr Opin Otolaryngol Head Neck Surg*. 2012;20:53-7.

549. Wormald PJ, Cain T, Oates L, Hawke L, Wong I. A comparative study of three methods of nasal irrigation. *Laryngoscope*. 2004;114:2224-7.
550. Freeman SR, Sivayoham ES, Jepson K, de Carpentier J. A preliminary randomised controlled trial evaluating the efficacy of saline douching following endoscopic sinus surgery. *Clin Otolaryngol*. 2008;33:462-5.
551. Cain R, Lal D. Update on the management of chronic rhinosinusitis. *Infect Drug Resist*. 2013;6:1-14.
552. Rudmik L, Soler ZM, Orlandi RR, Stewart MG, Bhattacharyya N, Kennedy DW, et al. Early postoperative care following endoscopic sinus surgery: an evidence-based review with recommendations. *Int Forum Allergy Rhinol*. 2011;1:417-30.
553. Liang KL, Su MC, Tseng HC, Jiang RS. Impact of pulsatile nasal irrigation on the prognosis of functional endoscopic sinus surgery. *J Otolaryngol Head Neck Surg*. 2008;37:148-53.
554. Chiu AG, Palmer JN, Woodworth BA, Doghramji L, Cohen MB, Prince A, et al. Baby shampoo nasal irrigations for the symptomatic post-functional endoscopic sinus surgery patient. *Am J Rhinol*. 2008;22:34-7.
555. Farag AA, Deal AM, McKinney KA, Thorp BD, Senior BA, Ebert CS Jr, et al. Single-blind randomized controlled trial of surfactant vs. hypertonic saline irrigation following endoscopic endonasal surgery. *Int Forum Allergy Rhinol*. 2013;3:276-80.
556. Rudmik L, Smith TL. Evidence-based practice: postoperative care in endoscopic sinus surgery. *Otolaryngol Clin North Am*. 2012;45:1019-32.
557. Orlandi RR, Hwang PH. Perioperative care for advanced rhinology procedures. *Otolaryngol Clin North Am*. 2006;39:463-73, viii.
558. Kupferberg SB, Bent JP 3rd, Kuhn FA. Prognosis for allergic fungal sinusitis. *Otolaryngol Head Neck Surg*. 1997;117:35-41.
559. Schubert MS. Allergic fungal sinusitis: pathogenesis and management strategies. *Drugs*. 2004;64:363-74.
560. Schubert MS, Goetz DW. Evaluation and treatment of allergic fungal sinusitis. II. Treatment and follow-up. *J Allergy Clin Immunol*. 1998;102:395-402.
561. Rupa V, Jacob M, Mathews MS, Seshadri MS. A prospective, randomised, placebo-controlled trial of postoperative oral steroid in allergic fungal sinusitis. *Eur Arch Otorhinolaryngol*. 2010;267:233-8.
562. Saleh AM, Torres KM, Murad MH, Erwin PJ, Driscoll CL. Prophylactic perioperative antibiotic use in endoscopic sinus surgery: a systematic review and meta-analysis. *Otolaryngol Head Neck Surg*. 2012;146:533-8.
563. Albu S, Lucaci R. Prophylactic antibiotics in endoscopic sinus surgery: a short follow-up study. *Am J Rhinol Allergy*. 2010;24:306-9.
564. Annys E, Jorissen M. Short term effects of antibiotics (Zinnat) after endoscopic sinus surgery. *Acta Otorhinolaryngol Belg*. 2000;54:23-8.
565. Moriyama H, Yanagi K, Ohtori N, Fukami M. Evaluation of endoscopic sinus surgery for chronic sinusitis: post-operative erythromycin therapy. *Rhinology*. 1995;33:166-70.
566. Seiberling K, Wormald PJ. The role of itraconazole in recalcitrant fungal sinusitis. *Am J Rhinol Allergy*. 2009;23:303-6.
567. Monto AS, Ullman BM. Acute respiratory illness in an American community. The Tecumseh study. *JAMA*. 1974;227:164-9.
568. Fox JP, Hall CE, Cooney MK, Luce RE, Kronmal RA. The Seattle virus watch. II. Objectives, study population and its observation, data processing and summary of illnesses. *Am J Epidemiol*. 1972;96:270-85.
569. Stahlberg MR. Effect of the type of day care on the occurrence of acute respiratory tract infections among young children. *Duodecim*. 1981;97:1394-403.
570. Revai K, Dobbs LA, Nair S, Patel JA, Grady JJ, Chonmaitree T. Incidence of acute otitis media and sinusitis complicating upper respiratory tract infection: the effect of age. *Pediatrics*. 2007;119:e1408-12.
571. Spaeth J, Krugenstein U, Schlondorff G. The paranasal sinuses in CT-imaging: development from birth to age 25. *Int J Pediatr Otorhinolaryngol*. 1997;39:25-40.
572. Park IH, Song JS, Choi H, Kim TH, Hoon S, Lee SH, et al. Volumetric study in the development of paranasal sinuses by CT imaging in Asian: a pilot study. *Int J Pediatr Otorhinolaryngol*. 2010;74:1347-50.
573. Chow AW, Benninger MS, Brook I, Brozek JL, Goldstein EJ, Hicks LA, et al. IDSA clinical practice guideline for acute bacterial rhinosinusitis in children and adults. *Clin Infect Dis*. 2012;54:e72-e112.
574. Wald ER. Beginning antibiotics for acute rhinosinusitis and choosing the right treatment. *Clin Rev Allergy Immunol*. 2006;30:143-52.
575. Wald ER, Applegate KE, Bordley C, Darrow DH, Glode MP, Marcy SM, et al. Clinical practice guideline for the diagnosis and management of acute bacterial sinusitis in children aged 1 to 18 years. *Pediatrics*. 2013;132:e262-80.
576. Kristo A, Uhari M, Luotonen J, Koivunen P, Ilkko E, Tapiainen T, et al. Paranasal sinus findings in children during respiratory infection evaluated with magnetic resonance imaging. *Pediatrics*. 2003;111:e586-9.
577. Marseglia GL, Pagella F, Klersy C, Barberi S, Licari A, Ciprandi G. The 10-day mark is a good way to diagnose not only acute rhinosinusitis but also adenoiditis, as confirmed by endoscopy. *Int J Pediatr Otorhinolaryngol*. 2007;71:581-3.
578. Wald ER, Milmoie GJ, Bowen A, Ledesma-Medina J, Salamon N, Bluestone CD. Acute maxillary sinusitis in children. *N Engl J Med*. 1981;304:749-54.
579. Falagas ME, Giannopoulos KP, Vardakas KZ, Dimopoulos G, Karageorgopoulos DE. Comparison of antibiotics with placebo for treatment of acute sinusitis: a meta-analysis of randomised controlled trials. *Lancet Infect Dis*. 2008;8:543-52.
580. Critchley IA, Jacobs MR, Brown SD, Traczewski MM, Tillotson GS, Janjic N. Prevalence of serotype 19A *Streptococcus pneumoniae* among isolates from U.S. children in 2005-2006 and activity of far-openem. *Antimicrob Agents Chemother*. 2008;52:2639-2643.
581. Jacobs MR, Good CE, Windau AR, Bajaksouzian S, Biek D, Critchley IA, et al. Activity of ceftaroline against recent emerging serotypes of *Streptococcus pneumoniae* in the United States. *Antimicrob Agents Chemother*. 2010;54:2716-9.
582. American Academy of Pediatrics, Subcommittee on Management of Sinusitis and Committee on Quality Improvement. Clinical practice guideline: management of sinusitis. *Pediatrics*. 2001;108:798-808.
583. Shapiro GG, Virant FS, Furukawa CT, Pierson WE, Bierman CW. Immunologic defects in patients with refractory sinusitis. *Pediatrics*. 1991;87:311-316.
584. Brook I, Gober AE. Antimicrobial resistance in the nasopharyngeal flora of children with acute maxillary sinusitis and maxillary sinusitis recurring after amoxicillin therapy. *J Antimicrob Chemother*. 2004;53:399-402.
585. Elwany S, El-Dine AN, El-Medany A, Omran A, Mandour Z, El-Salam AA. Relationship between bacteriology of the adenoid core and middle meatus in children with sinusitis. *J Laryngol Otol*. 2011;125:279-81.
586. Shin KS, Cho SH, Kim KR, Tae K, Lee SH, Park CW, et al. The role of adenoids in pediatric rhinosinusitis. *Int J Pediatr Otorhinolaryngol*. 2008;72:1643-50.
587. Nguyen KL, Corbett ML, Garcia DP, Eberly SM, Massey EN, Le HT, et al. Chronic sinusitis among pediatric patients with chronic respiratory complaints. *J Allergy Clin Immunol*. 1993;92:824-30.
588. Leo G, Piacentini E, Incorvaia C, Consonni D, Frati F. Chronic rhinosinusitis and allergy. *Pediatr Allergy Immunol*. 2007;18:19-21.
589. Babinski D, Trawinska-Bartnicka M. Rhinosinusitis in cystic fibrosis: not a simple story. *Int J Pediatr Otorhinolaryngol*. 2008;72:619-24.

-
590. Gysin C, Alothman GA, Papsin BC. Sinonasal disease in cystic fibrosis: clinical characteristics, diagnosis, and management. *Pediatr Pulmonol.* 2000;30:481-9.
591. Manning SC, Merkel M, Kriesel K, Vuitch F, Marple B. Computed tomography and magnetic resonance diagnosis of allergic fungal sinusitis. *Laryngoscope.* 1997;107:170-6.
592. Brook I. Bacteriology of acute and chronic ethmoid sinusitis. *J Clin Microbiol.* 2005;43:3479-80.
593. Muntz HR, Lusk RP. Bacteriology of the ethmoid bullae in children with chronic sinusitis. *Arch Otolaryngol Head Neck Surg.* 1991;117:179-81.
594. Hsin CH, Su MC, Tsao CH, Chuang CY, Liu CM. Bacteriology and antimicrobial susceptibility of pediatric chronic rhinosinusitis: a 6-year result of maxillary sinus punctures. *Am J Otolaryngol.* 2010;31:145-9.
595. Harvey R, Hannan SA, Badia L, Scadding G. Nasal saline irrigations for the symptoms of chronic rhinosinusitis. *Cochrane Database Syst Rev.* 2007;(3):CD006394.
596. Ozturk F, Bakirtas A, Ileri F, Turktas I. Efficacy and tolerability of systemic methylprednisolone in children and adolescents with chronic rhinosinusitis: a double-blind, placebo-controlled randomized trial. *J Allergy Clin Immunol.* 2011;128:348-52.
597. Brietzke SE, Brigger MT. Adenoidectomy outcomes in pediatric rhinosinusitis: a meta-analysis. *Int J Pediatr Otorhinolaryngol.* 2008;72:1541-5.
598. Criddle MW, Stinson A, Savliwala M, Coticchia J. Pediatric chronic rhinosinusitis: a retrospective review. *Am J Otolaryngol.* 2008;29:372-8.
599. Ramadan HH, Cost JL. Outcome of adenoidectomy *versus* adenoidectomy with maxillary sinus wash for chronic rhinosinusitis in children. *Laryngoscope.* 2008;118:871-3.
600. Ramadan HH, Terrell AM. Balloon catheter sinuplasty and adenoidectomy in children with chronic rhinosinusitis. *Ann Otol Rhinol Laryngol.* 2010;119:578-82.
601. Hebert RL 2nd, Bent JP 3rd. Meta-analysis of outcomes of pediatric functional endoscopic sinus surgery. *Laryngoscope.* 1998;108:796-9.

ERRATUM

Coordination

Wilma T. Anselmo-Lima and Eulalia Sakano

In the consensus “Rhinosinusitis: evidence and experience” (Braz J Otorhinolaryngol. 2015;81(1 Suppl. 1): S1–S49), which reads:

Participants

André Alencar, Atílio Fernandes, Edwin Tamashiro, Elizabeth Araújo, Érica Ortiz, Fabiana Cardoso Pereira Valera, Fábio Pinna, Fabrizio Romano, Francini Padua, João Mello Jr., João Teles Jr., José E.L. Dolci, Leonardo Balsalobre, Macoto Kosugi, Marcelo H. Sampaio, Márcio Nakanishi, Marco César, Nilvano Andrade, Olavo Mion, Otávio Piltcher, Reginaldo Fujita, Renato Roithmann, Richard Voegels, Roberto E. Guimarães, Roberto Meireles, Shirley Pignatari, Victor Nakajima

For the purpose of citation

Wilma Terezinha Anselmo Lima, Eulalia Sakano, Edwin Tamashiro, Elizabeth Araújo, Érica Ortiz, Fábio Pinna, Fabrizio Romano, Francini Padua, João Mello Jr., João Teles Jr., José E.L. Dolci, Leonardo Balsalobre, Macoto Kosugi, Marcelo H. Sampaio, Márcio Nakanishi, Marco César, Nilvano Andrade, Olavo Mion, Otávio Piltcher, Reginaldo Fujita, Renato Roithmann, Richard Voegels, Roberto E. Guimarães, Roberto Meireles, Victor Nakajima, Fabiana Cardoso Pereira Valera, Shirley Pignatari

It should read:

Participants

André Alencar Araripe Nunes, Atílio Maximino Fernandes, Edwin Tamashiro, Elizabeth Araújo Pereira, Érica Ortiz, Fabiana Cardoso Pereira Valera, Fábio de Rezende Pinna, Fabrizio Ricci Romano, Francini Grecco de Melo Padua, João Ferreira de Mello Junior, João Teles Junior, José Eduardo Lutaif Dolci, Leonardo Lopes Balsalobre Filho, Eduardo Macoto Kosugi, Marcelo Hamilton Sampaio, Márcio Nakanishi, Marco César Jorge dos Santos, Nilvano Alves de Andrade, Olavo de Godoy Mion, Otávio Bejzman Piltcher, Reginaldo Raimundo Fujita, Renato Roithmann, Richard Louis Voegels, Roberto Eustaquio Santos Guimarães, Roberto Campos Meirelles, Rodrigo de Paula Santos, Shirley Shizue Nagata Pignatari, Victor Nakajima

For the purpose of citation

Wilma T. Anselmo-Lima, Eulália Sakano, Edwin Tamashiro, André Alencar Araripe Nunes, Atílio Maximino Fernandes, Elizabeth Araújo Pereira, Érica Ortiz, Fábio de Rezende Pinna, Fabrizio Ricci Romano, Francini Grecco de Melo Padua, João Ferreira de Mello Junior, João Teles Junior, José Eduardo Lutaif Dolci, Leonardo Lopes Balsalobre Filho, Eduardo Macoto Kosugi, Marcelo Hamilton Sampaio, Márcio Nakanishi, Marco César Jorge dos Santos, Nilvano Alves de Andrade, Olavo de Godoy Mion, Otávio Bejzman Piltcher, Reginaldo Raimundo Fujita, Renato Roithmann, Richard Louis Voegels, Roberto Eustaquio Santos Guimarães, Roberto Campos Meirelles, Rodrigo de Paula Santos, Victor Nakajima, Fabiana Cardoso Pereira Valera, Shirley Shizue Nagata Pignatari

