

Gastric lesions associated with the presence of *Anisakis* spp. Dujardin, 1845 (Nematoda: Anisakidae) in Cetaceans stranded on the coast of Ceara, Brazil

Monica Regina Alves Motta^{1,4}, Diana Célia Sousa Nunes Pinheiro^{1,2}, Vitor Luz Carvalho²,

Daniel de Araújo Viana², Ana Carolina Paulo Vicente³ & Alena Mayo Iñiguez³

¹Programa de Pós Graduação em Ciências Veterinárias – PPGCV, Universidade Estadual do Ceará – UECE, Av. Paranjana, 1700, CEP 60740-000, Fortaleza, CE, Brazil

²Faculdade de Veterinária – FAVET, Universidade Estadual do Ceará – UECE, Av. Paranjana, 1700, CEP 60740-000, Fortaleza, CE, Brazil, e-mail: diana@uece.br

³Departamento de Genética do Instituto Oswaldo Cruz – FIOCRUZ, Av. Brasil, 4365, CEP 21045-900, Mangueiras, RJ, Brazil, e-mail: alena@ioc.fiocruz.br

⁴Corresponding author: Monica Regina Alves Motta, e-mail: mottavet@gmail.com

MOTTA, M.R.A., PINHEIRO, D.C.S.N., CARVALHO, V.L., VIANA, D.A., VICENTE, A.C.P. & IÑIGUEZ, A.M. 2008. Gastric lesions associated with the presence of *Anisakis* spp. Dujardin, 1845 (Nematoda: Anisakidae) in Cetaceans stranded on the coast of Ceara, Brazil. Biota Neotrop. 8(2): <http://www.biotaneotropica.org.br/v8n2/en/abstract?article+bn01608022008>.

Abstract: The gastric compartments of ten cetaceans stranded on the coast of Ceará State, Northeast Brazil were analyzed in this study. Gastric *Anisakis* spp. was diagnosed in all individuals involved in this study. Parasites and tissue samples were collected during necropsy. The presence of *Anisakis* parasites showed similar distribution across the three gastric compartments and the majority was free within the gastric lumen. Macroscopically, the lesions were predominantly characterized by the presence of ulcers (60%, 6/10) within the gastric mucosa, occasionally associated with edema and hemorrhage (30%, 3/10). Eight cetaceans (8/10 - 80%) presented gastric microscopic alterations and in 75% (6/8) of these animals, chronic lymphoplasmocytic gastritis was observed with varying degrees of distribution and severity. Additionally, eosinophilic and granulomatous inflammation with giant cells, hemosiderosis, fibrosis and areas of necrosis were associated with location of parasites within the gastric mucosa. In this study, it was shown that the majority of cetaceans with the presence of *Anisakis* parasites presented macro and microscopic gastric alterations. These nematodes are probably associated with the development of these alterations; however, more pathological approaches are still required.

Keywords: *Anisakis* sp, nematodes, ulcers, pathology, marine mammals, cetaceans, stranding.

MOTTA, M.R.A., PINHEIRO, D.C.S.N., CARVALHO, V.L., VIANA, D.A., VICENTE, A.C.P. & IÑIGUEZ, A.M. 2008. Lesões gástricas associadas à presença de *Anisakis* spp. Dujardin, 1845 (Nematoda: Anisakidae) em Cetáceos encalhados no litoral do Ceará, Brasil. Biota Neotrop. 8(2): <http://www.biotaneotropica.org.br/v8n2/pt/abstract?article+bn01608022008>.

Resumo: Neste estudo, foram analisados os compartimentos gástricos de dez cetáceos encalhados na costa do Ceará, região nordeste do Brasil. Parasitos do gênero *Anisakis* foram diagnosticados em todos os indivíduos estudados. As amostras parasitárias e teciduais foram coletadas durante o procedimento de necropsia. A presença de *Anisakis* demonstrou distribuição similar nos três compartimentos gástricos, estando a maior parte dos parasitos livre na mucosa gástrica. Macroscopicamente, as lesões se caracterizaram principalmente pela presença de úlceras (60%, 6/10) gástricas, associadas ocasionalmente a edema e hemorragia (30%, 3/10). Oito cetáceos (8/10 - 80%) apresentaram alterações gástricas microscópicas e em 75% (6/8) destes animais, foi observada uma gastrite crônica linfoplasmocitária com vários graus de distribuição e severidade. Foram constatados ainda, focos de inflamação granulomatosa com a presença de eosinófilos, células gigantes e a formação de hemossiderose, fibrose e de necrose em torno dos parasitos. Neste estudo, a maioria dos cetáceos com a presença de parasitos do gênero *Anisakis* apresentaram alterações gástricas macro e microscópicas. Estes nematóides estão provavelmente associados ao desenvolvimento destas alterações, entretanto, mais estudos são ainda necessários.

Palavras-chave: *Anisakis* sp, nematóides, úlceras, patologia, mamíferos marinhos, cetáceos, encalhe.

Introduction

Amongst the nematodes, the Anisakidae family, composed of the *Anisakis*, *Contracaecum* and *Pseudoterranova* genus, is one of the most successful in terms of the potential colonization of the hosts in a broad range of environments (Raga et al. 2002). This species is the most common parasite found in marine mammals (Dailey 2001) and uses cetaceans as a definitive host (Mattiucci et al. 2004). Adult stages are found in the stomach compartments of marine mammals (Dailey et al. 1972) within the lumen or attached to the mucosa (Geraci & St. Aubin 1987), and can produce ulcers and cause hemorrhages (Raga et al. 2002).

According to Silva & Cousin (2004), in Brazil there is a lack of histopathological information on injury caused by helminthes in marine mammals. These abnormalities are directly associated with the parasite or with a secondary opportunistic infection and can give important signs of the systematic and tissue condition of the animal. Such abnormalities may indeed be related to the cause of death.

The objective of this research was to describe, macroscopically and microscopically, the gastric lesions associated with the presence of *Anisakis* spp. in cetaceans stranded on the coast of Ceará State in Brazil.

Materials and Methods

The cetacean species used in this study were stranded in Ceará State (05° 00' S and 40° 00' W), Northeast Brazil, and were rescued by the Research and Conservation Association of Aquatic Ecosystems/AQUASIS, an institution licensed by the State to manipulate the biological material from these animals.

All the gastric compartments infected by *Anisakis* spp. were studied. The macroscopic description of lesions and collection of parasites and tissue fragments were carried out during necropsy (Geraci & Lounsbury 1993). The stomach tissue was fixed and maintained in formaldehyde 10%, submitted to conventional methods of histological slide preparation, stained with hematoxylin-eosin (H&E) and evaluated by optic microscopy. The parasites were stored in alcohol 70% or alcohol/formaldehyde/acetic acid (AFA). Identification was based on morphological characteristics (Davey 1971, Mattiucci et al. 2005) and confirmed through DNA extraction, Polymerase Chain Reaction (PCR) and sequence analysis. The 5' end of 18S rRNA gene (Dorris & Blaxter 2000) and ITS-1 region, between the 18S and 5.8S rRNA genes (Zhu et al. 1999) from the nematode genome were amplified, and their products were directly sequenced on both strands using the Big Dye Terminator v3.1 Cycle Sequencing Kit, in an ABI PRISM® 3100 Genetic Analyzer Sequencer (Applied Biosystems-Perkin Elmer). Chromas version 1.45 (School of Health Science, Griffith University, Queensland, Australia), Bio Edit version 5.0.9 (Department of Microbiology, North Carolina State University), and BLASTN/NCBI programs were used for the sequences analysis.

Results

1. Hosts

Ten cetaceans, six females and four males, were studied: *Peponocephala electra* (n = 3, identifications O2C1512/79, O2C1512/145 and O2C1512/273), *Kogia breviceps* (n = 2, identifications O2C0521/149 and O2C0521/279), *Stenella clymene* (n = 2, identifications O2C1152/219 and O2C1151/242), *Stenella longirostris* (n = 2, identifications O2C1132/221 and O2C1131/225), *Steno bredanensis* (n = 1, identification O2C1212/70). The length of the specimens was between 160 to 262 cm, all of them considered to be adults according to the minimum length for sexual maturity of each species (Perrin et al. 2002). Three of these animals presented consider-

able body shape alteration, characterized by the loss of adipose tissue (Gulland et al 2001, Geraci & Lounsbury 2005). All the carcasses were well-preserved (code 2, Geraci & Lounsbury 1993).

2. Parasites

Morphologically, all specimens collected were identified as *Anisakis* genus, considering the presence of three typical lips; a long and muscular esophagus; a long ventricle, sigmoid or in the shape of a violin; unequal spicules; and the presence of various pairs of tail papilla (Davey 1971). The *A. typica* (Figure 1), were the predominant species found. In the confirmatory molecular analysis, the sequence comparison with GenBank database revealed that the partial 18S rRNA sequences belong to *Anisakis* sp. and the ITS-1 sequences had 98% similarity with the *A. typica* sequence (AY826724).

Anisakis spp. specimens were found in one or two stomach compartments, predominantly free within the gastric lumen. In three animals (3/10 - 30%), there were *Anisakis* spp. specimens embedded in the gastric mucosa: *Stenella clymene* (O2C1152/219) with parasites embedded in the main stomach wall, *Stenella clymene* (O2C1151/242) with parasites embedded in the pyloric stomach wall and *Peponocephala electra* (O2C1512/273) with parasites embedded at the forestomach and pyloric walls.

3. Macroscopic gastric alterations

Of the ten cetaceans with the presence of *Anisakis* spp., seven (7/10 - 70%) had gastric macroscopic alterations. The gastric lesions were characterized mainly by the presence of ulcers in the mucosa (85.7%, 6/7): *Stenella clymene* (O2C1152/219 and O2C1151/242) had ulcers located exclusively in the forestomach; *Peponocephala electra* (O2C1512/79) and *Kogia breviceps* (O2C0521/279) had ulcers located exclusively in the main stomach; *Peponocephala electra* (O2C1512/273) ulcers were located exclusively in the pyloric stomach; and *Stenella longirostris* (O2C1131/225) showed ulcers located concomitantly in the forestomach and pyloric stomach. The gross appearance of the

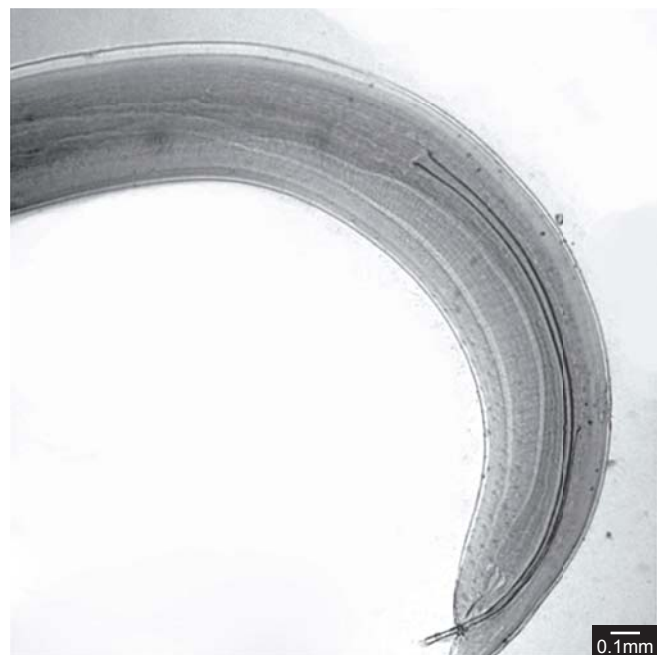


Figure 1. Posterior end of *Anisakis typica* parasite found in stomach of a *Stenella clymene* specimen (4X, Scale 0.1 millimeter).

Figura 1. Extremidade posterior de um parasito *Anisakis typica* encontrado no estômago de um espécime de *Stenella clymene* (4X, escala 0,1 mm).

ulcers varied in shape (round, oval and rectangular); size (0.5 to 2.5 cm in diameter or 0.25 to 1.0 cm width x 1.0 a 3.0 cm in length); color (grayish to dark, pinkish to burgundy); depth (superficial to deep) and number (1 to 6 per compartment). All the ulcers observed presented well-defined, round borders. In 42.9% of the animals (3/7) the gastric mucosa presented edema and/or hyperemia with hemorrhage areas: *Stenella clymene* (02C1152/219) with hemorrhage areas in the main stomach, *Stenella longirostris* (02C1131/225) and *Peponocephala electra* (02C1512/273) both with edema and hemorrhage areas in the pyloric stomach. In Figure 2, it is possible to observe the pyloric stomach mucosa of a *Peponocephala electra* specimen (02C1512/273) which presented edema, hyperemia and four ulcers varying from 1.0 to 1.5 cm in diameter, with extremely salient borders, containing necrotic tissue and *Anisakis* spp. specimens embedded.

4. Microscopic gastric alterations

Of the ten cetaceans with the presence of *Anisakis* spp., eight (8/10 - 80%) presented microscopic gastric alterations. In 75% of these animals (6/8), chronic lymphoplasmocytic gastritis was observed (Figure 3): *S. clymene* (02C1152/219) presented a severe diffuse gastritis in the forestomach; *P. electra* (02C1512/79) a discrete focal gastritis in the main stomach; *K. breviceps* (02C0521/149) moderate focal gastritis in the main stomach; *P. electra* (02C1512/273) a severe diffuse gastritis in pyloric stomach; *K. breviceps* (02C0521/279) a discrete multifocal gastritis in the main and the pyloric stomachs; *S. longirostris* (02C1131/225) moderate diffuse gastritis in the forestomach and severe diffuse gastritis in pyloric stomach. Of the six animals that presented chronic gastritis, two specimens, *S. clymene* (02C1152/219) and *S. longirostris* (02C1131/225), had a predominance of neutrophils with lymphocytes, plasmocytes, and macrophages; and two animals, *P. electra* (02C1512/273) and *S. longirostris* (02C1131/225) presented some granulomatous reaction with the presence of eosinophils and giant cells around the parasite (Figure 3). In one animal (1/8 - 12.5%), *S. clymene* (02C1151/242), a discrete vacuolar degeneration in the basal layer of the epithelium located in the forestomach was observed. One animal (1/8 - 12.5%) of the *P. electra* (02C1512/79) species presented a discrete spongiosis of

the epithelial tissue in the forestomach. Large areas of hemosiderosis were found in 37.5% of the animals (3/8): *S. clymene* (02C1152/219) in the main stomach, *S. longirostris* (02C1131/225) and *P. electra* (02C1512/273) in the pyloric stomach. Fibrosis (confirmed through Masson's Trichromic color method) and necrosis was observed in the pyloric stomach of the one *P. electra* specimen (02C1512/273) (1/8 - 12,5%) (Figure 3).

Discussion

The Anisakine parasites have a wide variety of hosts in a vast range of environments (Raga et al. 2002). In the present study, *A. typica* was the predominant species found in the animals' stomachs. This species was identified in all five species of cetaceans examined. Studies held in southeast Brazil reported that the main occurrences of *A. typica* was in *S. guianensis*, *Pontoporia blainvillei*, *S. coeruleoalba* and *K. simus* (Marigo 2003). It has also been demonstrated that this nematode is able to utilize several definitive host species, depending on the specific location, apparently having a very low level of host specificity.

The cetacean stomach is a diverticulate composite stomach, consisting of regions of stratified squamous epithelium, fundic mucosa, and pyloric mucosa (Mead 2002). Ulceration and inflammation of the stomach can be attributed to parasitic and non-parasitic causes.

Most reports of ulceration in marine mammals directly associate the ulcers with parasitism by nematodes, e.g. *Anisakis* sp., *Contracaecum osculatum*, *Pholeter gastrophilus* and *Phocanema decipiens*. Parasite-induced ulcers are typically shallow and have the anterior end of the worm embedded in the ulcer bed, but in some cases there may be numerous adult and larval Anisakine parasites free within the lumen (Geraci & St. Aubin 1987). In this study, from the ten animals that had parasitic infection by *Anisakis* spp., seven showed gastric alterations and only three of these presented visible parasites embedded in the ulcerous regions. Moeller (2001) believe that these

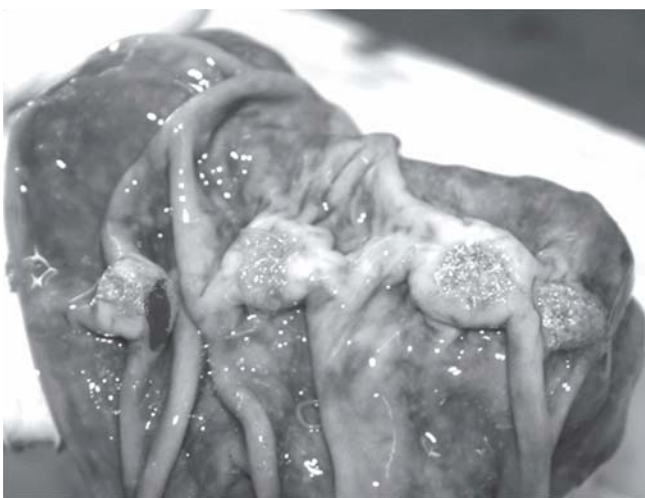

Figure 2. Pyloric stomach mucosa of a *Peponocephala electra* specimen, with edema, hyperemia, and four ulcers (from 1.0 to 1.5 cm in diameter) containing necrotic tissue and *Anisakis* spp. specimens embedded.

Figura 2. Estômago pilórico de um espécime de *Peponocephala electra*: mucosa edemaciada, hiperêmica, com 4 úlceras (1,0 a 1,5cm de diâmetro) contendo tecido necrosado e *Anisakis* spp. aderidos.

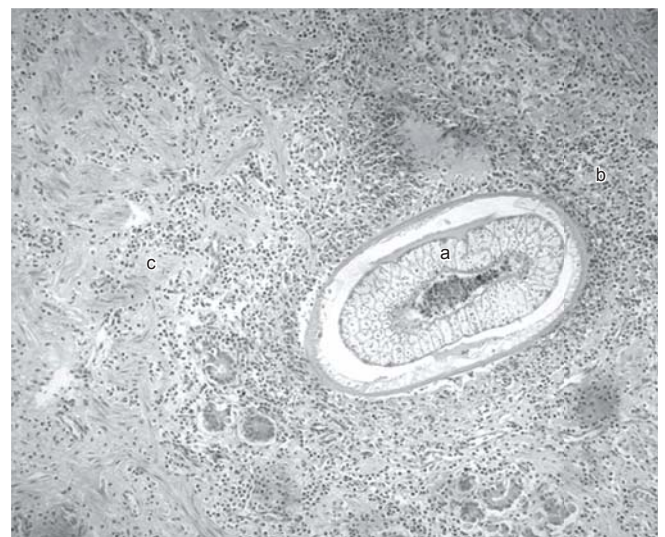

Figure 3. Microscopic view (H.E., 100X) of pyloric stomach of *Peponocephala electra* specimen. a) Cross cut of *Anisakis typica* parasite. b) Granulomatous reaction with the presence of eosinophils and giant cells around the parasite. c) Chronic lymphoplasmocytic gastritis with fibrosis and necrosis.

Figura 3. Microscopia (H.E., 100X) do estômago pilórico de um espécime de *Peponocephala electra*. a) Corte transversal do parasito *Anisakis typica*. b) Reação granulomatosa com a presença de eosinófilos e células gigantes ao redor do parasito. c) Gastrite crônica linfoplasmocitária com formação de fibrose e áreas de necrose.

parasites cause ulceration of the gastric mucosa and submucosa during migration. Cattán et al. (1976) suggest that the gastric ulcers were predisposed by larval nematodes penetrating the mucosa. Once embedded, the mechanical and destructive action of worms triggers an intense gastritis, followed by an ulcer. According to the authors, such ulceration would be complicated by an accumulation of excretory debris from the parasites, as well as by the invasion of bacteria into the depths of the lesions. Schoroeder & Wegeforth (1935) suggested that although an association between nematodes and gastric lesions has been demonstrated in some cases, the nematodes have not yet been shown to be the initial cause of the pathological condition; that is, they may only have invaded the ulcers that were already present and further exacerbated the host reaction. The authors considered that ulcers were initiated by abrasion of the gastric mucosa by swallowed volcanic rock and that ulcers were subsequently invaded and aggravated by nematodes. However, Young & Lowe (1969) observed and demonstrated the development of gastric lesions in laboratory rats after force-feeding with larvae of *Anisakis* sp.

Non-parasitic ulceration in captive cetaceans can be attributed to histamine toxicosis (Geraci & St. Aubin 1987) where high concentrations of histamine, as part of a herring diet, may cause excessive gastric acid secretion. According to Geraci & Lounsbury (1993), the excess of undiluted acid may produce ulcers in all chambers, particularly the first. Alternatively, starvation, stress and trauma have been proposed as causes of gastric ulcers (Sweeney & Ridgway 1975, Duignan et al. 2003). Recent isolation of *Helicobacter* sp. from gastric mucosa of dead dolphins suggests an infectious etiology for gastric ulcers in marine mammals (Harper et al. 2000).

Ulcers may be acute and hemorrhagic, or chronic with healing by fibrosis and granulation. In severe infections, perforations of the stomach wall may occur, causing peritonitis and death (Geraci & St. Aubin 1987). In this study, the gross appearance of the ulcers varied, some being fresh and hemorrhagic, others in various stages of healing. None of the examined stomachs had perforations. However, deep ulcers extended beyond the submucosa were found in some cases. According to Howard & collaborators (1983), the fibrotic host response prevents most ulcers from perforating, but occasionally there is transmural gastritis with secondary peritonitis. According to Howard et al. (1983) and Moeller (2001), in odontocete cetaceans, Anisakine parasites are located in the first and third chambers of the stomach. However, this study showed a similar predominance to the *Anisakis* sp. infection in the three stomach compartments (forestomach, main and pyloric) associated with macroscopic and microscopic lesions. The microscopic characteristics found, that is massive infiltration of mononuclear inflammatory cells such as lymphocytes, plasmocytes and macrophages, tissue destruction, and the substitution of damage tissue for a fibrous conjunctive tissue, corroborated with a chronic inflammatory lesion definition given by Ringler (1997) and Collins (2000) and with the findings of other studies that researched infection by *Anisakis* sp. in mammals (Young & Lowe 1969) and also in humans (Ruitenbergh 1970, Germano & Germano 1998). Cross sections of nematodes were found in the necrotic granulomas characterized by central areas of degenerating eosinophils that were surrounded by a wide zone of epithelioid granulation tissue followed by fibrous tissue which, according to Dailey & Stroud (1978), are characteristics of this infection. The main role of granulomatous reaction is that of defending the host against persistent irritants (Ringler 1997). In this sense, the parasites, which are insoluble, persistent, and not easily degradable by macrophages, are typical stimuli that incite a granulomatous response.

In this study, it was shown that the majority of cetaceans with *Anisakis* parasites presented macro and microscopic gastric alterations.

These nematodes are probably associated with the development of this pathology. However, more pathological approaches are still required.

Acknowledgments

The authors would like to thank the CNPq (National Council for Technological and Scientific Development), FIOCRUZ (Oswaldo Cruz Institute) and FAPERJ (Research Supporting Foundation from Rio de Janeiro State) who sponsored this study; AQUASIS (Research and Conservation Association of Aquatic Ecosystems) and the REMANE (Brazilian Northeast Aquatic Mammal Stranding Network) for providing the samples of the biological material to carry out the present study. Thanks are also due to Miss Daniela Leles and Koko Otsuki (FIOCRUZ) for technical assistance; Mr. Salvatore Siciliano (FIOCRUZ), Mr. Zacarias Silva Renato (Federal University of Rio Grande), and Miss Juliana Marigo (BioPesca Project / FIOCRUZ) for literary-scientific support; Mr. Cláudio Cabral Campello and Mrs. Maria Verônica Moraes Campello (State University of Ceará) for permitting the utilization of their facilities and resources; and to Thiago Cartaxo and Mrs. Virginia Girão for their contribution to preparation of photos.

References

- CATTAN, P.E., BABERO, B.B. & TORRES, D. 1976. The helminth fauna of Chile: iv. Nematodes of the genera *Anisakis* Dujardin, 1845 and *Phocanema* Myers, 1954 in relation with gastric ulcers in a south american sea lion, *Otaria byroni*tm. J. Wildl. Dis. 12(4): 511-515.
- COLLINS, T. 2000. Inflamação aguda e crônica. In Patologia Estrutural e Funcional (R.S. Cotran, V. Kumar & T. Collins, eds.). Guanabara Koogan, Rio de Janeiro, Brazil, p. 44-78.
- DAILEY, M.D. 2001. Parasitic Diseases. In CRC Handbook of Marine Mammal Medicine (L.A. Dierauf, & F.M.D. Gulland, eds.). CRC Press, Florida, EUA, p. 767-778.
- DAILEY, M.D. & BROWELL Jr., R. 1972. A checklist of marine mammal parasites. In Mammals of the Sea: Biology and Medicine (S.H. Ridgway, ed.). Charles C. Thomas Publisher, Florida, EUA, p. 529-589.
- DAILEY, M. & STROUD, R. 1978. Parasites and associated pathology observed in cetaceans stranded along the Oregon coast. J. Wildl. Dis. 14(4): 503-511.
- DAVEY, J.T. 1971. A revision of the genus *Anisakis* Dujardin, 1845 (Nematoda: Ascaridida). J. Helminthol. 45(1): 51-72.
- DORRIS, M. & BLAXTER, M. 2000. The small subunit ribosomal RNA sequence of *Strongyloides stercoralis*. Int. J. Parasitol. 30(8): 939-941.
- DUIGNAN, P.J., GIBBS, N.J. & JONES, G.W. 2003. Autopsy of cetaceans incidentally caught in fishing operations 1997/98, 1999/2000, and 2000/01. Doc Science Internal Series 119. New Zealand Department of Conservation, New Zealand, 60p.
- GERACI, J.R. & LOUNSBURY, V.L. 1993. Specimen and data collection. In Marine Mammals Ashore: A Field Guide for Strandings (J.R. Geraci, & V.J. Lounsbury, eds.). Texas A & M Sea Grant College Program, Galveston, Texas, EUA, 309p.
- GERACI, J.R. & LOUNSBURY, V.J. 2005. Decisions on the beach. In Marine Mammals Ashore: A Field Guide for Strandings (J.R. Geraci, & V.J. Lounsbury, eds.). 2nd Edition. National Aquarium in Baltimore, Baltimore, Maryland, 371p.
- GERACI, J.R. & AUBIN, D.J.S.T. 1987. Effects of parasites on marine mammals. Int. J. Parasitol. 17(2): 407-414.
- GERMANO, P.M.L. & GERMANO, M.I.S. 1998. Anisakiase: zoonose parasitária emergente no Brasil? Hig. Alim. 12(54): 26-35.
- GULLAND, F.M.D., LOWENSTINE, L.J. & SPRAKER, T.R. 2001. Noninfectious Diseases. In CRC Handbook of Marine Mammals Medicine (L.A. Dierauf & F.M.D. Gulland, eds.). CRC Press, Florida, EUA, p. 521-547.
- HARPER, C.M.G., DANGLER, C.A., XU, S., FENG, Y., SHEN, Z., SHEPPARD, B., STAMPER, A., DEWHIRST, F.E., PASTER, B.J. &

Gastric lesions in Cetaceans

- FOX, J.G. 2000. Isolation and characterization of a *Helicobacter* sp. from the gastric mucosa of dolphins, *Lagenorhynchus acutus* and *Delphinus delphis*. Appl. Environ. Microbiol. 66: 4751-4757.
- HOWARD, E.B., BRITT JR., J.O. & MATSUMOTO, G. 1983. Parasitic diseases. In Pathobiology of Marine Mammal Diseases (E.B. Howard, ed.). CRC Press, Florida, EUA, p. 119-133.
- MARIGO, J. 2003. Patologia comparada das principais enfermidades parasitárias de mamíferos marinhos encontrados na costa sudeste e sul do Brasil. Ph.D. Dissertation, Faculdade de Medicina Veterinária e Zootecnia, São Paulo, Brazil, 150p.
- MATTIUCCI, S., ABAUNZA, P., RAMADORI, L. & NASCETTI, G. 2004. Genetic identification of *Anisakis* larvae in European hake from Atlantic and Mediterranean waters for stock recognition. J. Fish Biol. 65(4): 495-510.
- MATTIUCCI, S., NASCETTI, G., DAILEY, M., WEBB, S.C., BARROS, N.B., CIANCHI, R. & BULLINI, L. 2005. Evidence for a new species of *Anisakis* Dujardin, 1845: morphological description and genetic relationships between congeners (Nematoda: Anisakidae). Syst. Parasitol. 61(3): 157-171.
- MEAD, J.G. 2002. Gastrointestinal Tract. In Encyclopedia of Marine Mammals (W.F. Perrin, B. Würsig, and H.G.M. Thewissen, eds.). Academic Press, San Diego, California, EUA, p. 490-492.
- MOELLER, R.B. 2001. Diseases of Marine Mammals. California Animal Health and Food Safety Laboratory System, California, EUA, 34p.
- PERRIN, W.F., WURSIG, B. & THEWISSEN, J.G.M. 2002. Encyclopedia of Marine Mammals. Academic Press, San Diego, California, EUA, 1414p.
- RAGA, J.A., FERNÁNDEZ, M., BALBUENA, J.A. & AZNAR, J. 2002. Parasites. In Encyclopedia of Marine Mammals (W.F. Perrin, B. Würsig, and H.G.M. Thewissen, eds.). Academic Press, San Diego, California, EUA, p. 867-876.
- RINGLER, D.J. 1997. Inflamação e reparo. In Patologia Veterinária (T.C. Jones, R.D. Hunt, N.W. King, eds.). Malone Ltda, São Paulo, Brazil, p.119-166.
- RUINTERBERG, E.J. 1970. Anisakiasis: pathogenesis, serodiagnosis and prevention. Drukkerij Elinkwijk, Utrecht, Germany, 138p.
- SCHROEDER, C.R. & WEGWFORTH, H.M. 1935. The occurrence of gastric ulcers in sea mammals of the California coast, their etiology and pathology. J. Amer. Vet. Med. Ass. 40(2): 333-342.
- SILVA, R.Z. & COUSIN, J.C.B. 2004. Anormalidade gástrica parasitária em *Pontoporia blainvillei* (Cetacea, Platanistoidea, Pontoporiidae) da região litorânea de Rio Grande, RS, Brasil. Biociências 12(2): 99-113.
- SWEENEY, J. & RIDGWAY, S.H. 1975. Common diseases of small cetaceans. J. Amer. Vet. Med. Ass. 167(7): 533-540.
- YOUNG, P.C. & LOWE, D. 1969. Larval nematodes from fish of the subfamily Anisakinae and gastro-intestinal lesions in mammals. J. Comp. Path. 79(3): 301-312.
- ZHU, X., CHILTON, N.B., JACOBS, D.E., BOES, J. & GASSER, R.B. 1999. Characterisation of *Ascaris* from human and pig hosts by nuclear ribosomal DNA sequences. Int. J. Parasitol. 29(3): 469-478.

Data Received 09/05/07

Revised 10/01/08

Accepted 12/05/08