







## Tributaries of the hepatic vein in the ostrich (*Struthio camelus*)

### Afluentes da veia porta-hepática no avestruz (*Struthio camelus*)

Nalva Fatima Ferreira<sup>1\*</sup> , Roberto Gameiro de Carvalho<sup>1</sup> , Wilson Machado de Souza<sup>1</sup> , Nair Trevizan Machado de Souza<sup>1</sup> , Alan Peres Ferraz de Melo<sup>2</sup> , Rosangela Felipe Rodrigues<sup>1</sup> 

<sup>1</sup>Faculdade de Medicina Veterinária de Araçatuba, Universidade Estadual Paulista “Júlio de Mesquita Filho” (Unesp), Araçatuba, São Paulo, Brazil.

<sup>2</sup>Faculdade de Engenharia de Ilha Solteira, Universidade Estadual Paulista “Júlio de Mesquita Filho” (Unesp), Ilha Solteira, São Paulo, Brazil.

Correspondent - [nalvafatima@hotmail.com](mailto:nalvafatima@hotmail.com)

#### Abstract

The ostrich (*Struthio camelus*, Linnaeus 1758) is the largest bird in the world. It is of great economic importance in Africa and is found across several countries. With developments in breeding systems, morphological studies that facilitate the application of the knowledge are necessary, considering the species has unique anatomical features. The objective of the present study was to describe the major tributaries of the hepatic vein in the species. Ten viscera of adult individuals of both sexes, which were injected with Neoprene latex through the hepatic vein, were used to visualize their tributaries. After the vascular repletion, the tissues were fixed and conserved in 10% formaldehyde aqueous solution. The hepatic carrier system was dissected and photo-documented. The left hepatic vein receives blood from the proventricle and gastric ventricle, while the right hepatic vein is responsible for the drainage of blood into the following organs: spleen, through the proventriculosplenic vein; pancreas, through the pancreaticoduodenal vein; jejunum, through the jejunum trunk; and the colon, which forms the cranial mesenteric vein.

**Keywords:** Hematous vein; Venous drainage; *Struthio camelus*.

Section: Medicina Veterinária

Received  
February 7, 2019.  
Accepted  
March 03, 2020.  
Published  
May 16, 2020.

[www.revistas.ufg.br/vet](http://www.revistas.ufg.br/vet)  
visit the website to get the  
how to cite in the article page.

#### Resumo

O avestruz (*Struthio camelus*, Linnaeus 1758) é a maior ave do mundo, com uma importância comercial acentuada na África e expandindo-se para diversos países. Assim, com o desenvolvimento dos sistemas de criação, tornam-se necessários estudos morfológicos que subsidiem as áreas aplicadas, pois a espécie apresenta características anatômicas próprias. O objetivo deste estudo foi a descrição dos principais afluentes da veia porta-hepática nesta espécie. Para a realização do presente trabalho, foram utilizadas dez vísceras de animais adultos, de ambos os sexos, que foram injetados com Neoprene látex por meio da veia porta-hepática para evidenciar os seus afluentes. Após a repleção vascular, os animais foram fixados e conservados em solução aquosa de formaldeído a 10%. O sistema porta-hepático foi dissecado e fotodocumentado. Observou-se que a veia porta-hepática esquerda recebe sangue da região do proventrículo

e ventrículo gástrico. A veia porta-hepática direita é a responsável pela drenagem do sangue nos seguintes órgãos: baço, por meio da veia proventriculoesplênica, pâncreas, pela veia pancreaticoduonais, jejuno, por meio do tronco jejunal, e o cólon, que forma a veia mesentérica cranial.

**Palavras-chave:** Veia porta-hepática; Drenagem venosa; *Struthio camelus*.

---

## Introduction

The ostrich (*Struthio camelus*, L. 1758) is considered an herbivore <sup>(1,2,3)</sup> with a gastrointestinal tract that is different from those of domestic birds<sup>(1)</sup>. In addition, the absence of flight in ratites such as ostriches could have led to a distinction in their digestive tracts <sup>(4)</sup>. Ostrich, *rhea* (*Rhea americana*) and emu (*Dromaius novaehollandiae*) have different gastrointestinal system anatomies. The ostrich has a well-developed, large, saccular caecum, and a long, partially sacular colon <sup>(5,6)</sup>. The emu has a small colon, while in the emu, the caecum and colon are small <sup>(4,7,8)</sup>.

The ostrich diet consists of a variety of succulent plants, grasses, and bushes <sup>(1,9)</sup>, which allows a morphophysiological adaptation common in herbivorous and granivorous birds; a muscular gizzard full of sand to facilitate the reduction of the sizes of ingested particles <sup>(4,10,11)</sup>.

Liver blood drainage has implications in various fields of study and has been investigated extensively. In birds, the blood liver drainage systems has been described in ducks (*Cairina moschata*)<sup>(13)</sup>, geese (*Anser domestica*)<sup>(14)</sup>, domestic pigeons (*Columba livia domestica*) <sup>(15)</sup>, egrets (*Bubulcus ibis*)<sup>(16)</sup> and *Gallus gallus* <sup>(17, 18,19,26)</sup>, considering the hepatic system in birds differs from that in mammals. In addition, in birds, the system is anastomous to the renal system <sup>(12)</sup>. The renal portal system has already been described in ostriches. However, to date, this is the first study on the tributaries of the hepatic portal system in the species.

## Material and Methods

Ten (10) viscera of adult ostriches, five males and five females, collected at Frigorífico Aravestruz, in the municipality of Araçatuba -SP, were used. After the collection, the viscera were sent to the Animal Morphology Laboratory at the Faculdade de Medicina Veterinária de Araçatuba, UNESP (Faculty of Veterinary Medicine, Araçatuba, Sao Paulo State University). This study was approved by the Ethics Committee on the Use of Animals of the School of Dentistry of Araçatuba/UNESP under the FOA protocol: 00602-2017. In the laboratory, the viscera were washed in running water to remove

blood from the veins. Subsequently, the hepatic vein was identified for the injection of Neoprene latex, which has a blue pigment, to fill its tributaries. After the injection, the viscera were submerged in an aqueous solution of 10% formaldehyde for a 48 hours to fix the tissues and solidify the Neoprene latex<sup>(20)</sup>. After fixation, the visceral block was washed in running water for 24 hours to remove the fixator, and then dissected and photo documented.

The anatomical terms are in accordance with the Anatomical Nomenclature of Birds, *Nomina Anatomica Avium*<sup>(21)</sup>.

## Results

### ***Hepatic vein***

A common hepatic vein, located on the visceral face of the liver between the right and left lobes, originated from the union of the right and left hepatic veins.

### ***Left hepatic vein***

Two vessels, the ventral proventricular vein and the left proventricular vein, join to form the hepatic vein. Both vessels continue cranioventrally to join the gastric veins.

### ***Right hepatic vein***

Much more vessels contributed to the formation of the right hepatic vein than the left hepatic vein. The right hepatic vein was formed by the confluence of the following veins: proventriculosplenic, gastro pancreaticoduodenal, and cranial mesenteric vein. (Figures 1A-B).

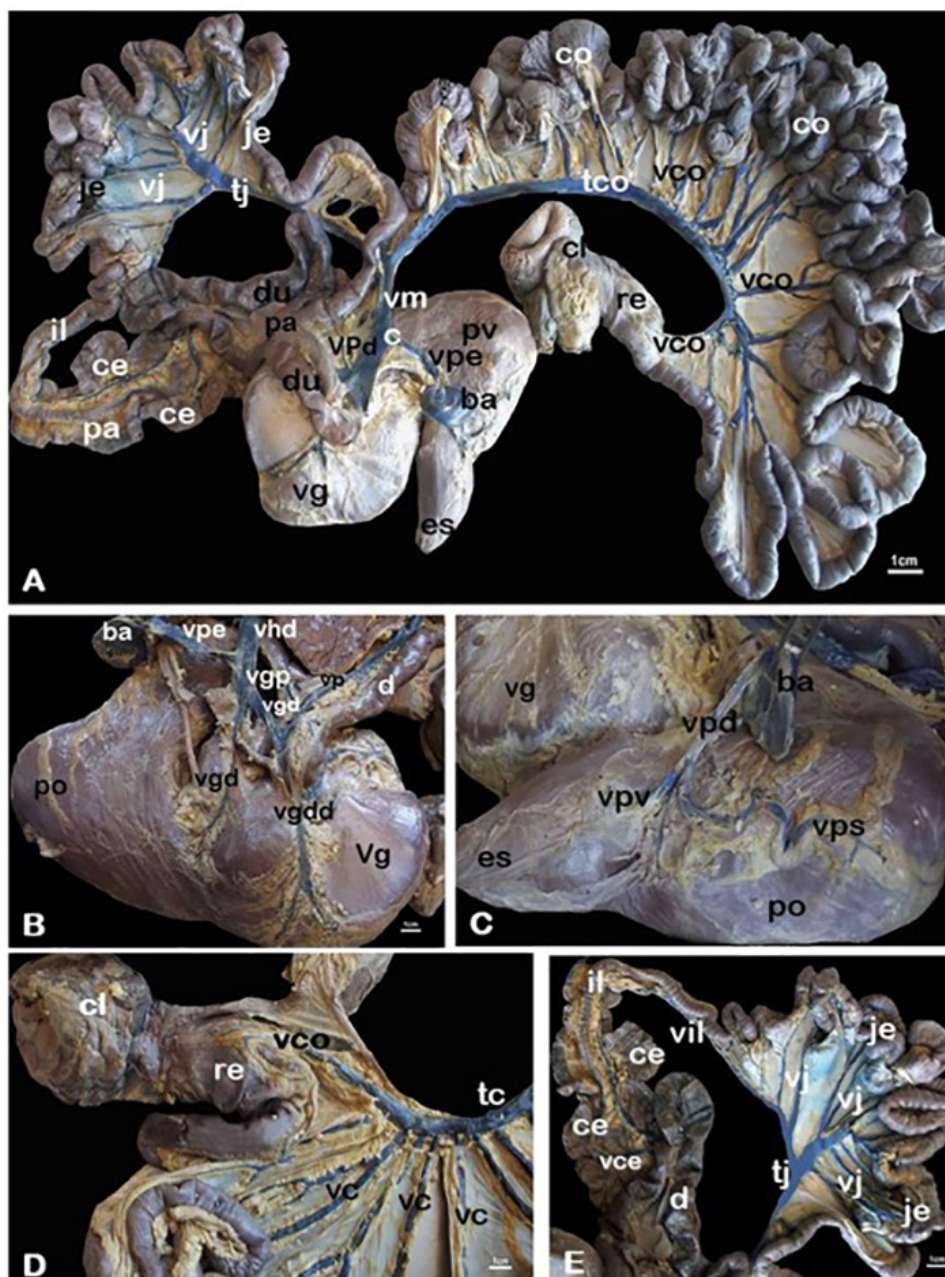
The proventriculosplenic vein arises from the confluence of two important veins, the right proventricular vein and the splenic vein, with the latter originating from the ventromedial surface of the spleen (Figures 1B-C).

The gastro pancreaticoduodenal vein is the union of the right and left gastric veins with the pancreaticoduodenal vein. The right gastric vein received branches of the right dorsal and ventral gastric veins at its origin on the right side of the gastric ventricle (Figures 1A-E).

The cranial mesenteric vein was formed by two distinct trunks: the colic trunk and the jejunal trunk, formed by veins that flow from the duodenal, iliac, cecal, and colic regions (Figures 1A).

The jejunal trunk was derived from the duodenal veins, originating from the descending and ascending duodenum; from the ileocecal veins responsible for the drainage of the caecum and ileum (Figures 1A and 1E).

The colic trunk originated from the colic veins, coccigeomesenteric veins, and rectal vein; all originating from the colon and cloaca (Figures 1A and 1D). It is discernible that the configuration of the veins in *S. camelus* differs from other species, particularly in the colic trunk.



**Figures 1 (A-E).** Photomicrograph of the tributary veins of the hepatic vein in the ostrich (*Struthio camelus*). The configuration of the veins in *species. camelus* differs from the others, particularly in the colic trunk (tco) and the jejunal trunk (tje) that converge with the cranial mesenteric vein (vmc). The anatomical structures are: esophagus (Es); gastric ventricle (vg); proventricle (pv); spleen (ba); pancreas (pa); duodenum (du); jejunum (je); ileum (il); cecum (ce); colon (co); rectum (re), and cloaca. The veins are: jejunal trunk (tj); colic trunk (tco); colic veins (vco); coccigeomesenteric vein (vcc); cecal veins (vce); ileal vein (vil); right hepatic vein (vhd); cranial mesenteric vein (vm); splenic proventricular vein (vpe); gastro pancreaticoduodenal vein (vgp); right gastric vein (vgd); right ventral gastric vein (vgv); right dorsal gastric vein (vgdd); pancreaticoduodenal vein (vp); right proventricular vein (VPd); ventral proventricular vein (vpv) and left proventricular vein (vps).

## Discussion

The hepatic carrier system in ostriches (*S. camelus*) is formed by the union of the right and left hepatic vein, similar to the case in *G. gallus*<sup>(17,18,19)</sup>, in ducks (*C. moschata*)<sup>(13,14)</sup>, in geese (*A. domestica*)<sup>(13)</sup>, in domestic pigeons (*C. livia domestica*)<sup>(13,15,26)</sup>, in egret (*B. ibis*)<sup>(16)</sup>, in duck (*Anas anas domestica*) and domestic goose (*Anser anser domestica*)<sup>(22)</sup>. However, in geese (*A. domestica*) and ducks (*C. moschata*)<sup>(23)</sup> the hepatic carrier system is formed by two left and one right hepatic carrier veins.

In the ostrich, the left hepatic vein drains the proventricle through the ventral and left proventriculosplenic veins and part of the gastric ventricle through the gastric veins as in *G. gallus*<sup>(17,18,19)</sup>, in the egret (*B. ibis*)<sup>(16)</sup> and in domestic pigeons (*C. livia domestica*)<sup>(13,15)</sup>. In *G. gallus*<sup>(17,18,19,26)</sup>, the left hepatic vein is formed by the ventral and left gastric veins and by the proventricular veins<sup>(13)</sup>. Conversely, in ducks, the left hepatic vein is formed by one or two left gastric veins that drain blood from the ventral margin of the gastric ventricle, in addition to the pyloric and caudal proventricular veins<sup>(19)</sup>.

The right hepatic vein in ostrich is formed by the confluence of proventriculosplenic, gastro pancreaticoduodenal and cranial mesenteric veins, similar to the descriptions in the chicken (*G. gallus domestica*)<sup>(24,26)</sup> and in heron *B. ibis*<sup>(15)</sup>. However, in the domestic duck (*C. moschata*)<sup>(13)</sup>, in domestic birds (*G. gallus*)<sup>(17,18,19)</sup> and in the chicken (*G. gallus domestica*)<sup>(24,26)</sup>, the right hepatic vein is formed by the cranial gastro pancreaticoduodenal and mesenteric veins.

The proventriculosplenic vein was formed by the confluence of two important veins: the right proventricular vein and the splenic vein, both merging into the right hepatic vein, which are consistent with the patterns observed in heron (*B. ibis*)<sup>(16)</sup>. In the present study, the right proventricular vein received the confluence of the cranial and medial branches draining the cranial and medial third of the proventriculus.

In the ostrich, the spleen is drained by the splenic vein and the proventriculoesplenic vein joining the hepatic vein. In the domestic duck (*C. moschata*)<sup>(13)</sup>, the spleen is drained by the splenic vein and the protrichulosplenic vein, which is formed by the union of the splenic and dorsal protrichular veins<sup>(17)</sup>. In the chicken (*G. gallus domestica*)<sup>(24)</sup>, the right and protrichuloesplenic veins join the right hepatic vein via a common trunk, called the protrichulosplenic vein, while in the duck (*A. anas domestica*) and goose (*A. anser domestica*)<sup>(22)</sup> have been described as two splenic protrichuloesplenic veins and one right protrichulus vein, which join the right hepatic vein separately.

The gastro pancreaticoduodenal vein was formed by the confluence of right and pancreaticoduodenal gastric veins, which joined ventrally to the right hepatic vein, as reported in *G. gallus*<sup>(17)</sup> and the heron (*B. ibis*)<sup>(16)</sup>. In the ostrich, a trend similar to that in the domestic duck (*C. moschata*) was observed<sup>(13)</sup>, in which the corresponding gastro pancreaticoduodenal vein is formed by the pancreaticoduodenal vein and the two gastric veins and their tributaries<sup>(17,19)</sup>.

The duodenal veins drained the fasting veins in the fasting trunk and the ileocecal veins, responsible for the regions of the two caeca and the ileum, also flowed into the

fasting veins in the ostrich. The cecal vein is formed by the union of branches from the pancreaticoduodenal vein and the pancreatic vein, which differs from the one observed in the egret (*B. ibis*)<sup>(16)</sup>, in which the ileal veins converge on the ileocecal vein and end at the caudal mesenteric vein<sup>(15)</sup>. Another difference observed in relation to the anatomical pattern of the egret (*B. ibis*)<sup>(16)</sup> and domestic pigeons (*C. livia domestica*)<sup>(13,15)</sup> is that instead of the ostrich's fasting veins draining into the cranial mesenteric vein, they converge into the fasting trunk. In ostriches and other species, the presence of duodenojejunal veins such as those found in ducks (*A. anas domesticus*) and geese (*A. anser domesticus*) is not observed<sup>(22)</sup>.

According to Bezuidenhout<sup>(25)</sup>, the average total length of the intestine in an adult ostrich is 2390 cm, while that of the colon is 1640 cm, which are very long when compared to the lengths in other ratites such as the rhea and emu. Because the ostrich colon is so extensive, the cranial mesenteric vein is formed from two distinct veins: the jejunal trunk and the colonic trunk. Such confluence of the cranial mesenteric vein differs from that observed in poultry (*G. gallus*)<sup>(17,18,19,26)</sup>, duck (*C. moschata*)<sup>(13,14,22)</sup>, goose (*A. domestica*)<sup>(13)</sup>, domestic pigeon (*C. livia domestica*)<sup>(13,15)</sup>, egret (*B. ibis*)<sup>(16)</sup> and domestic goose (*A. anser domesticus*)<sup>(22,23)</sup>. According to the results of the present study, the tributaries of the hepatic vein in ostriches reveal an extension of the jejunum and caecum intestinal structures, revealing unique venous vessels that suggest species-specific angioarchitecture.

## References

- 1 Williams JB, Siegfried WR, Milton SJ, Adams NJ, Dean WRJ, du Plessis MA, Jackson S. Field metabolism, water requirements, and foraging behavior of wild ostriches in the Namib. *Ecology*. 1993; 74(2): 390-404.
- 2 Cooper SM, Palmer T. Observations on the dietary choice of free-ranging juvenile ostriches. *Ostrich*. 1994; 65(3-4), 251-255.
- 3 Milton SJ, Dean WRJ, Siegfried WR. Food selection by ostrich in Southern Africa. *Journal of Wildlife Management*. 1994; 58:234-248.
- 4 Frei S, Ortman S, Reutlinger C, Kreuzer M, Hatt JM, Clauss M. Comparative digesta retention patterns in ratites. *The Auk: Ornithological Advances*. 2015;132(1): 119-131.
- 5 Skadhauge E, Warüi CN, Kamau JMZ, Maloiy GMO. Function of the lower intestine and osmoregulation in the ostrich: preliminary anatomical and physiological observations. *Quarterly Journal of Experimental Physiology: Translation and Integration*. 1984; 69(4): 809-818.
- 6 Hongo A, Ishii Y, Suzuta H, Enkhee D, Toukura Y, Hanada M, Hidaka S, Miyoshi S. Position and rate of intestinal fermentation in adult ostrich evaluated by volatile fatty acid. *Research Bulletin of Obihiro University*. 2006; 27(9):93-97.
- 7 Cho P, Brown R, Anderson M. Comparative gross anatomy of ratites. *Zoo Biology*. 1984; 3 (2):133-144
- 8 Herd RM & Dawson TJ. Fiber digestion in the emu, *Dromaius novaehollandiae*, a large bird with a simple gut and high rates of passage. *Physiological Zoology*. 1984; 57(1):70-84.
9. Jamroz D. The digestion of the structural substances in Ratitae and in other species of poultry. *Proceedings International Ostrich Symposium, Current Problems in Ostrich Keeping, 29-30 September 2000*, pp. 39-41. Polish Academy of Sciences, Mrokow.

- 10 Moore SJ. Food breakdown in an avian herbivore: Who needs teeth? Australian Journal of Zoology. 1999; 47(6):625-632.
- 11 Fritz J, Hummel J, Kienzle E, Wings O, Streich WJ, Clauss M. Gizzard vs. teeth, it's a tie: food-processing efficiency in herbivorous birds and mammals and implications for dinosaur feeding strategies. Paleobiology. 2011; 37(4), 577-586.
- 12 Pavaux CL & Jolly A. Note on the vasculo-canalicular structure of the liver of domestic birds. Revue Med. 1968; 119(5):445-466.
- 13 Pinto MRA, Ribeiro AACM, Souza WM, Miglino MA, Machado MRF. Study of the liver portal system in the domestic duck (*Cairina moschata*). Brazilian Journal of Veterinary Research and Animal Science. 1999; 36(4): 173-177.
- 14 Santos TC, Ferrari CC, Menconi A, Maia MO, Bombonato PP, Pereira CCH Veins from hepatic portal vein system in domestic geese. Pesquisa Veterinária Brasileira. 2009; 29(4):327-332.
- 15 Tolba AR. Gross anatomical study on the hepatic portal vein tributaries in the common domestic pigeon (*Columba livia domestica*). International Journal of Veterinary Science. 2015; 4(2): 63-68.
- 16 Khalifa EF, Daghash SM Gross anatomical study on the tributaries of the hepatic portal vein in cattle egret (*Bubulcus ibis*). Veterinary Medical Journal-Giza (VMJG). 2014; 60(2): 75-90.
- 17 Oliveira D. Heart and blood vessels of birds. In: Getty, R. Sisson/ Grossman. Anatomy of Domestic Animals. 6th ed. Rio de Janeiro: Guanabara Koogan; 1959, p.1842-1880.
- 18 Malinovsky L. A contribution to the comparative anatomy of vessels in the abdominal part of the body cavity in birds. I. Blood supply to stomachs and adjacent organs in buzzard (*Buteo buteo* L.). Folia morfológica. 1965; 13, 191-201.
- 19 Nickel R, Schummer A, Seiferle E. Anatomy of the domestic birds. 1st ed. Berlin: Verlag Paul Parey. 1977; p. 96-99; 101-103.
- 20 Cury FS, Censoni JB, Ambrose EC. Anatomical techniques in teaching the practice of animal anatomy. Pesquisa Veterinária Brasileira. 2013; 33(5): 688-696.
- 21 Baumel JJ, King AS, Lucas AM, Breazile JE, Evans HE Nomina Anatomica Avium: An annotated anatomical dictionary of birds. Academic Press, London. 1979.
- 22 El karmoty AF. Macromorphological study on the digestive system of geese and ducks with special reference to its blood supply. Ph.D. Thesis. Faculty of Veterinary Medicine, Cairo University, 2014.
- 23 Jiaji C. The hepatic portal venous system of fowl. Chinese journal of veterinary science. 1997; 16: 01-06.
- 24 Nishida T, Paik YK, Yasuda M. Blood vascular supply of the glandular stomach (*ventriculus glandularis*) and the muscular stomach (*ventriculus muscularis*). Nihon Juigaku Zasshi, 1969; 31: 51-70.
25. Bezuidenhout AJ. The topography of the thoraco-abdominal viscera in the ostrich (*Struthio camelus*). Onderstepoort Journal of Veterinary Research. 1986; 53 (2): 111-117.
26. Maher MA. Descriptive anatomy of hepatic and portal veins with special reference to biliary duct system in broiler chickens (*Gallus gallus domesticus*): A Recent Illustration. Brazilian Journal of Poultry Science, 2019; 21 (2): 2019.