






## Canine transmissible venereal tumor with spontaneous remission: case study with emphasis on clinical and cytopathological exams to monitor tumor evolution

*Tumor venéreo transmissível canino com remissão espontânea: estudo de caso com ênfase aos exames clínico e citopatológico para monitoramento da evolução tumoral*

Thiago Souza Costa<sup>1</sup> , Felipe Noleto de Paiva<sup>1\*</sup> , Bruna Sampaio Martins Land Manier<sup>1</sup> , Monica Yamile Padilla Barreto<sup>1</sup> , Julio Israel Fernandes<sup>1</sup> 

<sup>1</sup> Universidade Federal Rural do Rio de Janeiro, Seropédica, Rio de Janeiro, Brazil

\*Correspondent: [n-paiva@hotmail.com](mailto:n-paiva@hotmail.com)

### Abstract

The canine transmissible venereal tumor (TVTC) is a neoplasm transmitted mainly through copulation and with a high incidence in stray dogs in Brazil. In the process of tumor evolution of TVTC, the progression, stationary and regression phases are recognized. The host immunity is related to the disease's biological behavior, however, spontaneous regression observation in cases of naturally occurring TVTC is uncommon. A canine patient was attended, after being rescued from the street, due to an ulcerated mass in the external genitalia and tick infestation. Cytopathological examination, which diagnosed TVTC, and laboratory tests that showed mild anemia and severe thrombocytopenia were performed. In view of the impossibility of carrying out other exams, it was made the presumptive diagnosis of canine monocytic ehrlichiosis (CME), and treatment was instituted. During follow-up it was observed quick improvement in clinical signs and laboratory changes, as well as a reduction in tumor mass. A new cytopathological evaluation was carried out, and was verified increase in mature lymphocytes and plasmocytes in the midst of the tumor cells, finding compatible with the stationary phase of the disease. From that moment on, it was decided to perform only clinical and cytopathological follow-up. In the following evaluations, continuous clinical remission and cytopathological findings compatible with those described in the regression phase were observed, until its complete remission. It is considered that the improvement in the general health of the patient after the treatment of CME is related to the spontaneous regression of TVTC, and that simultaneous performance of serial clinical and cytopathological exams may be feasible and useful for monitoring the stages of evolution of TVTC.

**Keywords:** cytopatology; dogs; erlichiosis; neoplasia; round cell.

### Resumo

O tumor venéreo transmissível canino (TVTC) é uma neoplasia transmitida principalmente através da cópula, com elevada incidência em cães errantes no Brasil. No processo de evolução tumoral do TVTC, são reconhecidas as fases de progressão, estacionária e de regressão. O estado imunológico do hospedeiro está relacionado ao comportamento biológico da doença, contudo, a observação de regressão espontânea em casos de TVTC de ocorrência natural é incomum. Foi atendida uma paciente canina, resgatada da rua, por apresentar massa ulcerada na genitália externa e infestação por carrapatos. Foram realizados exame citopatológico, que diagnosticou TVTC, e exames laboratoriais que evidenciaram anemia discreta e grave trombocitopenia. Com isso e diante da impossibilidade de realizar outros exames, foi também estabelecido o diagnóstico presuntivo de erlichiose monocítica canina (EMC) e instituído tratamento para a hemoparasitose. Durante o acompanhamento, foi observada rápida melhora dos sinais clínicos e das alterações laboratoriais, bem como a redução espontânea da massa tumoral. Em sequência, foi realizada nova avaliação citopatológica do TVTC e verificado o aumento quantitativo de linfócitos maduros e plasmócitos, em meio as células tumorais, achado compatível com a fase estacionária da doença. A partir desse momento, optou-se por realizar apenas acompanhamento clínico e avaliação citopatológica da neoplasia. Foram observados contínua remissão clínica e achados microscópicos compatíveis com a fase de regressão do tumor, até sua remissão completa. Pondera-se que a melhora na saúde geral da paciente após o tratamento da EMC esteja relacionada à regressão espontânea do TVTC, e que realização simultânea de exames clínico e citopatológico seriados pode ser viável e útil ao acompanhamento das fases de evolução do TVTC.

**Palavras-chave:** cães; células redondas; citopatologia; ehrlichiose; neoplasia.

Received: May 9, 2022. Accepted: July 12, 2022. Published: July 29, 2022.



## Introduction

Canine transmissible venereal tumor (CTVT) is one of the rare transmissible neoplasms of clonal origin and naturally occurring. Its transmission occurs through transplantation of viable tumor cells, mainly during mating<sup>(1,2,3)</sup>. This cell transplantation occurs as an allograft, and somatic tumor cells initially activate mechanisms to evade recognition barriers by the major histocompatibility complex (MHC) of the new host<sup>(4,5)</sup>. Tumor growth, as well as its biological behavior, depends on factors such as the number of viable cells transplanted, evasion of the immune system, target tissue permissive to transplantation, and the immune status of the affected animal<sup>(6)</sup>.

Three distinct phases of disease progression are recognized, which are clinically well established in experimentally transplanted CTVTs. However, it is believed that similar evolution can occur in naturally occurring cases<sup>(2,7)</sup>. After installation and initial cell replication in the tissue, the progression phase (P) begins, at which cells multiply rapidly, with consequent tumor growth. The rapid growth of lesions is related to mechanisms of evasion of immunological recognition through regulation of expression of MHC class I and II molecules, reducing the action of dendritic cells and T-cytotoxic response. This phase tends to last between three to six months in adult and immunocompetent dogs<sup>(2,3,5,8,9)</sup>. TVCT tends to be more aggressive in older dogs, puppies, and immunosuppressed dogs, with progressive or disseminated disease. Moreover, regional or distant metastatic foci may occur, not progressing to the next phases in dogs with a good immune response<sup>(3,7,10,11)</sup>.

The stationary phase (S) can last for months or even years and is characterized by a reduction in lesion growth speed due to a lower replicative rate of tumor cells. When performed at this phase of neoplasia, histopathological examination shows lower quantification of mitotic figures and increased inflammatory cell infiltrate, mainly lymphocytic<sup>(12)</sup>. After the S phase, the regression phase (R) begins, usually after three months of the onset of lesions in adult animals. This phase is immunologically characterized by the reversal of immunoinhibitory mechanisms that occurred in phase P. Mechanisms by which upregulation of MHC class I and II antigen expression and restore the cytotoxic activity of natural killer (NK) cells are not well established. Thus, histologically, there is a massive infiltration of inflammatory cells and collapse of the tumor stroma, with collagen deposition<sup>(13,14,15)</sup>.

A cytopathological examination is routinely used to diagnose CTVT, especially in genitals, as it is fast, easy to perform, and has high sensitivity and specificity for this neoplasm. Outcomes are commonly characterized by hypercellular samples composed of round cells with round to oval nuclei, aggregated chromatin, and

vacuolated cytoplasm, which ranges from scanty to abundant<sup>(12,16,17,18,19)</sup>. Although the phases of the disease are well characterized clinically and histologically in animals with experimentally induced CTVT, cases of spontaneous regression of CTVT are uncommon in dogs with naturally occurring neoplasia<sup>(2,5)</sup>. Studies evaluating the evolution phases of CTVT through cytopathological examination and its applicability in clinical routine are still scarce. In this context, the objective of this description is to present a case of CTVT with spontaneous remission, approaching clinical and cytopathological exams as a tool for monitoring the evolution of neoplasia.

## Case report

An adult female dog, rescued two months ago from the street, with serosanguineous vaginal secretion was treated. In the anamnesis, apathy and inappetence were reported and, during physical examination, an increase in ulcerated volume was observed in the external genital region, measuring 4 cm in diameter, and draining serosanguineous secretion. In addition to an increased volume, slightly pale oral and ocular mucosa, moderate splenomegaly on abdominal palpation, and ectoparasites (fleas and ticks) were observed. The day of the first appointment was considered moment zero regarding the evolution of the clinical picture. Blood count, serum biochemistry (urea, creatinine, alanine aminotransferase [ALT], alkaline phosphatase [AF], total proteins, and fractions) were performed, and a sample from the genital lesion was collected using the fine-needle puncture technique for cytopathological analysis.

The blood count showed mild normocytic normochromic nonregenerative anemia (hematocrit 26%, hemoglobin 8.2 g/dL, and red blood cells 4.0 x 10<sup>6</sup> cells/ $\mu$ L) and severe thrombocytopenia (20,000 cells/ $\mu$ L). The serum biochemistry analysis showed an increased protein total (9.0 g/dL), with a reduction in albumin concentration (1.6 g/dL) and an increase in globulins (7.4 g/dL). The other biochemical analyses showed no changes. Given the clinical and laboratory findings, serology was requested for the investigation of anti-*Ehrlichia canis* and *Anaplasma platys*, and PCR for the research of *Ehrlichia canis*; however, the tutor chose not to perform these exams. Cytopathological analysis of the genital lesion showed a monomorphic population of round cells with a large and round central nucleus, aggregated chromatin, and eccentric nucleoli, in addition to abundant and vacuolated cytoplasm. These findings are consistent with CTVT.

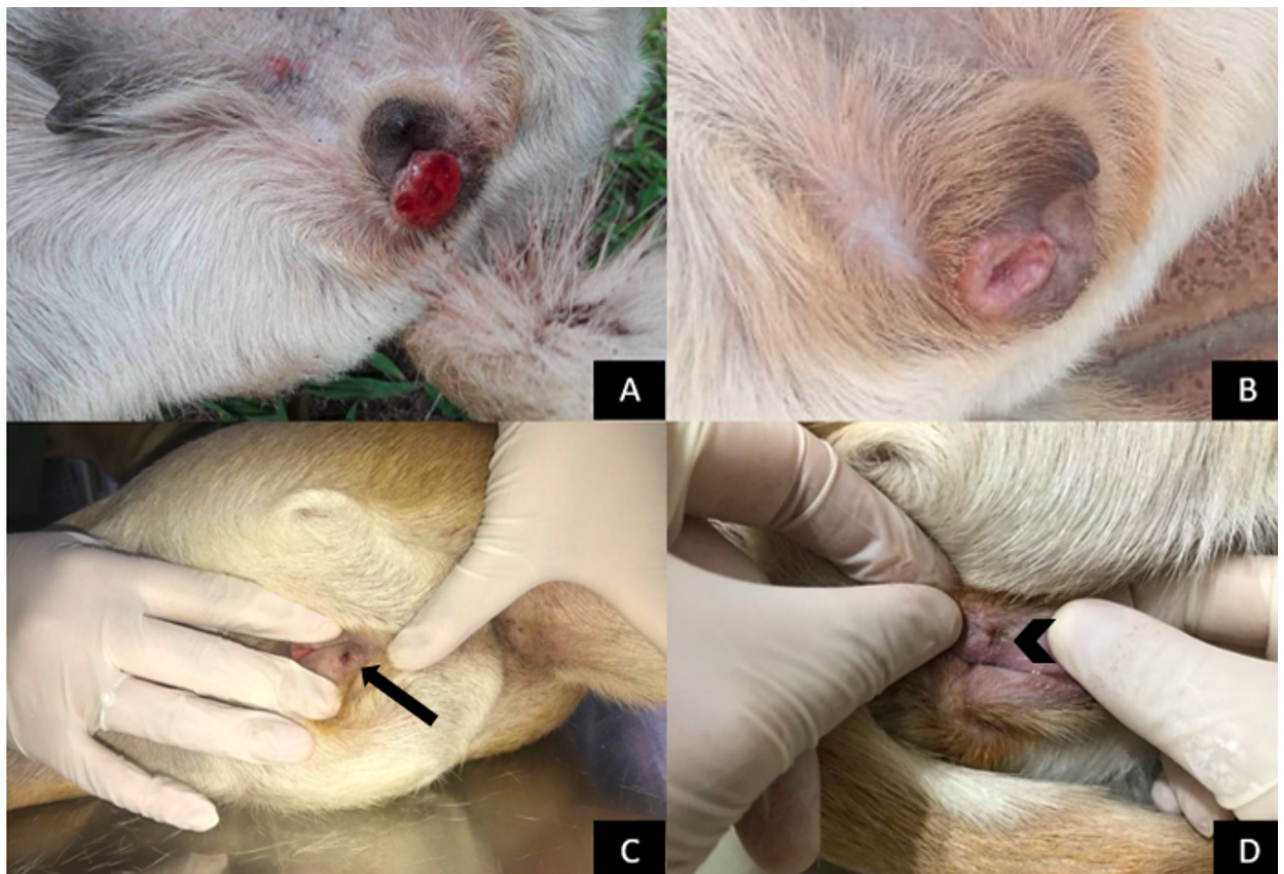
Based on the results of clinical and laboratory analysis, a diagnosis of genital CTVT and a presumptive diagnosis of canine monocytic ehrlichiosis (CME) were established. A therapeutic protocol aimed at CME was initiated, with oral administration of doxycycline at 5

mg/kg every 12 hours for 28 days. In addition, afoxolaner was prescribed monthly as a treatment and prevention of ectoparasite reinfestations. Due to the impossibility of treating comorbidities concomitantly, weekly monitoring of the patient and performance of new laboratory tests were recommended to start chemotherapy for CTVT with vincristine sulfate.

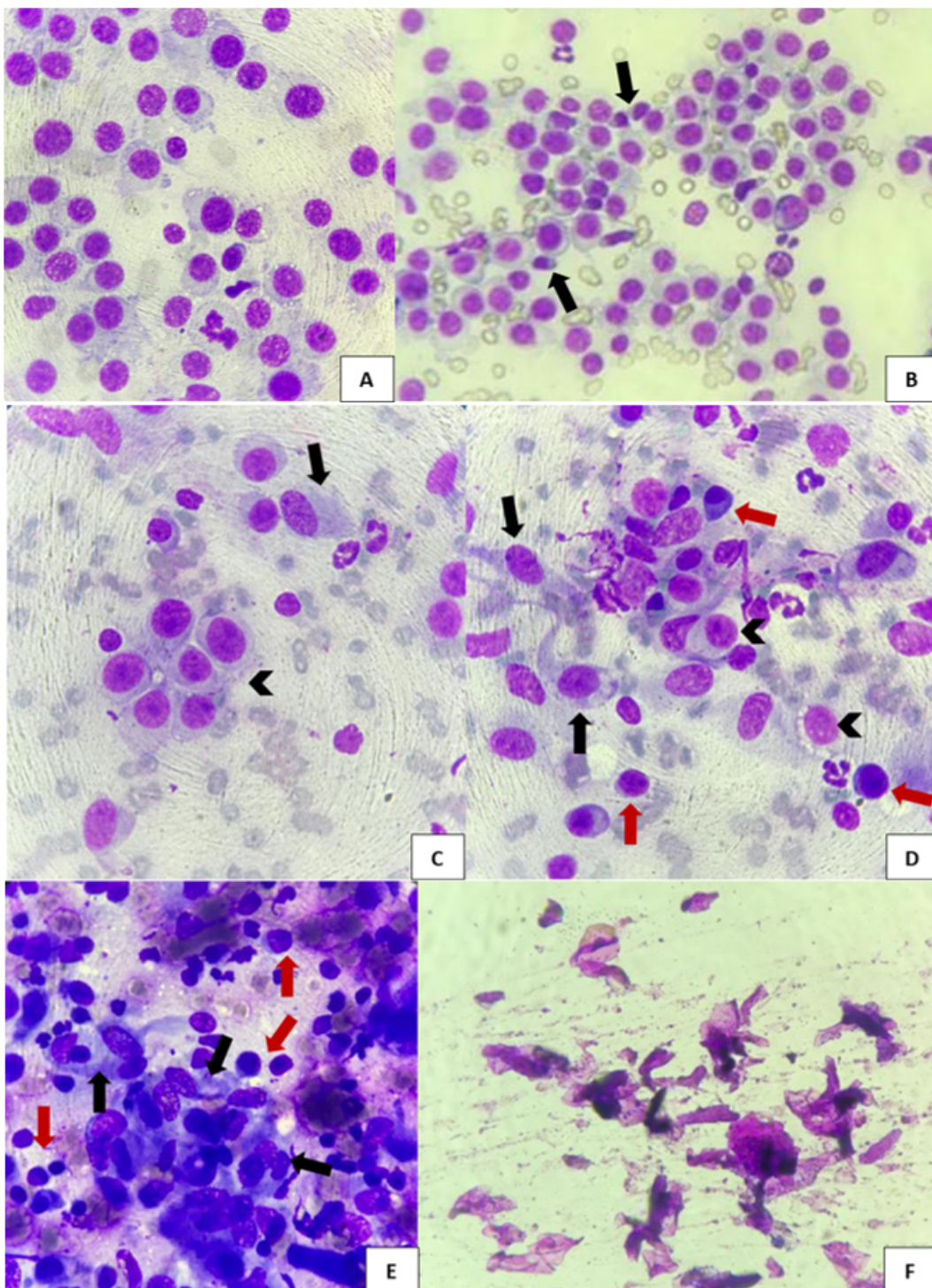
After 15 days of antibiotic therapy initiation (day +15), the patient showed significant clinical improvement. Hematological parameters returned to normal except for the serum level of globulins, which remained high (6.0 g/dL). Upon inspecting the genital lesion, a partial reduction of the tumor mass and inflammatory signs, including erythema and serosanguineous secretion, were observed. A new cytopathological analysis of the neoplasm showed that, besides the characteristic cells of CTVT, there was a large

number of mature lymphocytes together with tumor cells. After 28 days and the end of antibiotic therapy, the patient was reassessed to start CTVT treatment again. However, initial swelling was restricted to an erythematous punctate lesion in the center of the scar (day +30).

The planned chemotherapy was suspended and a new evaluation was performed after 15 days. In this last, only a scar area was observed at the site of the primary genital lesion (day +45). A new cytopathological analysis was performed, by local exfoliation, and desquamation of epithelial cells was observed. Given the absence of macroscopic lesions and tumor cells, spontaneous regression of CTVT was established, and the patient was discharged from the clinic. Figures 1 and 2 illustrate the neoplasm clinical evolution in the external genitalia and cytopathological aspects during the course of the neoplasm, respectively.



**Figure 1.** Evolution of the clinical picture of CTVT. A) Day 0. Increase in the ulcerated area on the external genitalia (4 cm in diameter). B) Day +15. Reductions in swelling and signs of inflammation and secretion. C) Day +30. Small punctate lesion on the external genitalia (black arrow). D) Day +45. Scarring in the tumor bed on the external genitalia (arrowhead).



**Figure 2.** CTVT photomicrographs at each clinical evolution phase. A) Day 0. The monomorphic population of round cells with a large, round central nucleus, aggregated chromatin, and evident nucleoli, in addition to abundant and vacuolated cytoplasm. Diff-Quick, 40x. B) Day 0. Mature lymphocytes (arrows) amid CTVT cells. Diff-Quick, 40x. C and D) Day +15. Hypocellular tumor sample (arrowheads), with lymphocytes, plasma cells (red arrows), and fibroblasts (black arrows). Diff-Quick, 40x. E) Day +30. Increase in the number of lymphoid cells (red arrows) and fibroblasts (black arrows), as well as the absence of neoplastic cells. Diff-Quick, 100x. F) Day +45. Keratin fragments and absence of tumor and inflammatory cells. Diff-Quick, 40x.

## Discussion

CTVT is a neoplasm transmissible by tumor cell transplantation, mainly via mating. Therefore, stray dogs or dogs with free access to the street are more predisposed to developing this disease<sup>(1,2,18,19)</sup>. The patient evaluated in this case study was rescued from the street a few months before diagnosis, which certainly favored contact with other animals and transmission of the neoplasia. Cancer patients must be thoroughly clinically evaluated to understand their general state of health and establish an appropriate diagnosis and therapeutic approach to each case<sup>(3,12)</sup>. Regarding stray animals with unknown clinical history, such detailing is even more important to diagnose and treat potential comorbidities and establish treatment priorities. In this context, a global-scale study by Strakova and Murchison (2014)<sup>(20)</sup> indicated that 17% of dogs affected by CTVT have some comorbidity.

On day 0, an increase in the erythematous and ulcerated lesion was observed on the external genitalia, in addition to the pallor of the oral and ocular mucosa, moderate splenomegaly on abdominal palpation, and infestation by fleas and ticks. Macroscopic increase in the genital volume and free-living history favored a presumptive diagnosis of CTVT<sup>(3,12,18)</sup>. However, other clinical signs observed were generic and likely to be associated with several diseases, especially those of an infectious and/or neoplastic nature. Laboratory alterations of normocytic normochromic nonregenerative anemia and severe thrombocytopenia are often associated with infectious diseases<sup>(21,22)</sup> and are also observed as paraneoplastic syndromes, including in cases of CTVT<sup>(12,23)</sup>. On the other hand, tick infestation added to hyperglobulinemia and splenomegaly constituted strong indications of disease transmitted by this vector<sup>(22)</sup>.

CME is a disease caused by the bacterium *Ehrlichia canis*, which is transmitted by tick vectors and is considered endemic in the region of Rio de Janeiro<sup>(24)</sup>. Presumptive diagnosis is established by clinical signs and laboratory alterations related to the presence of the etiologic agent and immune-mediated reactions<sup>(25,26)</sup>. Diagnosis can be confirmed by observation of agent morulae in infected cells or by specific antibody and/or antigen detection tests<sup>(22)</sup>. In the current case, serological tests were requested for investigation of anti-*Ehrlichia canis* and *Anaplasma platys*, in addition to PCR for investigation of *Ehrlichia canis*. However, due to financial restrictions, the tutor chose to continue the care and therapy after the presumptive diagnosis.

Concomitant use of different treatment protocols for diverse nature diseases can be challenging and must consider disease severity, potential drug-related adverse effects, and the patient's general condition. In the present case, CME was initially treated since its clinical and laboratory alterations were of greater significance than those triggered by CTVT, which was restricted to the

genitalia. Thus, at first, antineoplastic chemotherapy for CTVT was assumed to induce myelotoxicity and worsen the immunosuppression state in which the animal already found itself, thus limiting CME treatment response.

After initiation of CME treatment, clinical signs and hematological parameters improved rapidly, and CTVT was partially reduced. Although CTVT may have spontaneous regression in naturally occurring cases, this form of evolution is considered uncommon and has not been fully elucidated<sup>(23,27,28,29)</sup>. The new cytopathological examination of the lesion allowed the observation of an increase in the population of mature lymphocytes and plasma cells amid neoplastic cells, and this finding corresponds to the stationary phase from the histopathological evaluation<sup>(30)</sup>. The sequential performance of cytopathological tests allowed the observation of a gradual replacement of neoplastic cells with lymphoid cells and fibroblasts, which histologically characterize the regression phase<sup>(28,30,31)</sup>. After complete clinical regression of the neoplasm, the last cytopathological examination showed only keratinized cell remains, concluding that it was a case of CTVT spontaneous regression and cure.

A cytopathological analysis is the test of choice for genital CTVT diagnosis<sup>(3,14,18)</sup>. Understanding the microscopic nuances of each phase of the clinical evolution of the disease can help the clinician in deciding whether to institute treatment in each patient. However, further studies are needed to confirm and validate whether, through cytopathology, it is possible and reliable to determine the stationary or regression phase of CTVT using a low-invasive, low-cost, and highly sensitive and specific technique for diagnosis of neoplasia. This would allow to efficiently monitor the clinical evolution of CTVT.

Biological behavior of CTVT, as well as the course of its phases, seems to be linked to the immunological status of the host<sup>(3,29)</sup>. Thus, very young, elderly, or immunocompromised animals tend to present more aggressive clinical manifestations, while adult dogs in good health may present a favorable clinical course<sup>(3,7,10,11)</sup>. In this context, CME treatment and control of ectoparasite infestations, as well as the fact that the animal was collected from the street and subjected to suitable nutritional management, may have positively influenced the spontaneous regression of the neoplasm.

## Conclusion

This case study of CTVT indicates that the improvement in the general health of the patient after CME treatment is due to CTVT spontaneous regression and that simultaneous performance of serial clinical and cytopathological exams may be feasible and useful for monitoring the phases of CTVT evolution. However, it is

worth highlighting the importance of additional larger-scale studies to confirm and validate these findings.

### Conflict of interest declaration

The authors declare no conflict of interest of any kind.

### Author contributions

*Conceptualization:* R T. S. Costa, F. N. de Paiva, and J. I. Fernandes. *Research:* R T. S. Costa, F. N. de Paiva, B. S. M. L. Manier, and M. Y. P. Barreto. *Methodology:* R T. S. Costa, F. N. de Paiva, B. S. M. L. Manier, and M. Y. P. Barreto. *Supervision:* J. I. Fernandes. *Writing (original sketch):* R T. S. Costa, F. N. de Paiva, and J. I. Fernandes. *Writing (proofreading and editing):* R T. S. Costa, F. N. de Paiva, B. S. M. L. Manier, M. Y. P. Barreto, and J. I. Fernandes.

### Acknowledgments

The current study was supported by the Coordination for Improvement of Higher Education Personnel - Brazil (CAPES) - Financing Code 001.

### References

- Murchison EP, Wedge DC, Alexandrov LB, Fu B, Martincoarena I, Ning Z, Tubio JMC, Werner EI, Allen J, De Nardi AB, Donelan EM, Marino G, Fassati A, Campbell PJ, Yang F, Burt A, Weiss RA, Stratton MR. Transmissible dog cancer genome reveals the origin and history of an ancient cell lineage. *Science*. 2014;343(6169):437-440. doi: <https://doi.org/10.1126/science.1247167>
- Abeka YT. Review on Canine Transmissible Venereal Tumor (CTVT). *Cancer therapy and Oncology International Journal*. 2019;14(4):1-9. doi: <https://doi.org/10.19080/CTOIJ.2019.14.555895>
- Woods JP. Canine Transmissible Venereal Tumor. In: Vail D, Thamm DH, Liptak JM. *Withrow & MacEwen's Small Animal Clinical Oncology*. 6 ed. St. Louis, Missouri: Elsevier; 2020. p.781-784.
- Ostrander A, Davis BW, Ostrander GK. Transmissible tumors: Breaking the Cancer Paradigm. *Trends in Genetics*. 2016;32(1):1-15. doi: <https://doi.org/10.1016/j.tig.2015.10.001>
- Cell-mediated immunity and expression of MHC class I and class II molecules in dogs naturally infected by canine transmissible venereal tumor: Is there complete spontaneous regression outside the experimental CTVT? *Research in Veterinary Science*. 2022;145:193-204. doi: <https://doi.org/10.1016/j.rvsc.2022.02.020>
- Ujvari B, Gatenby RA, Thomas F. The evolutionary ecology of transmissible cancers. *Infection, Genetics and Evolution*. 2016;39:293-303. doi: <https://doi.org/10.1016/j.meegid.2016.02.005>
- Ganguly B, Das U, Das AK. Canine Transmissible Venereal Tumour: a Review. *Veterinary Comparative Oncology*. 2013;14(1):1-12. doi: <https://doi.org/10.1111/vco.12060>
- Hsiao Y, Liao KW, Hung SW, Chu RM. Tumor-infiltrating lymphocyte secretion of IL-6 antagonizes tumor-derived TGF- $\beta$ 1 and restores the lymphokine-activated killing activity. *The Journal of Immunology*. 2014;172(3):1508-1514. doi: <https://doi.org/10.4049/jimmunol.172.3.1508>
- Liu CC, Wang YS, Lin CY, Chuang TF, Liao KW, Chi KH, Chen MF, Chiang HC, Chu RM. Transient downregulation of monocyte-derived dendritic-cell differentiation, function, and survival during tumoral progression and regression in an in vivo canine model of transmissible venereal tumor. *Cancer Immunology, Immunotherapy*. 2008;57(4):479-491. doi: <https://doi.org/10.1007/s00262-007-0386-0>
- Siddle HV, Kaufman J. Immunology of naturally transmissible tumours. *Immunology*. 2015;144(1):11-20. doi: <https://doi.org/10.1111/imm.12377>
- Costa TS, Paiva FN, Gonzaga GM, Berutti BM, Veiga CCP, Spindola BF, Alonso LS, Fernandes JI. Canine Transmissible Venereal Tumor in the Larynx with Pulmonary Metastasis. *Acta Scientiae Veterinariae*. 2022; 50(Suppl 1): 764. doi: <https://doi.org/10.22456/1679-9216.120292>.
- Costa MT, Castro KF. Tumor venéreo transmissível. In: Daleck CR, De Nardi AB. *Oncologia em cães e gatos*. 2 ed. São Paulo: Editora Roca; 2016. p. 991-1013.
- Hsiao YW, Liao KW, Chung TF, Liu CH, Hsu CD, Chu RM. Interactions of host IL-6 and IFN- $\gamma$  and cancer-derived TGF- $\beta$ 1 on MHC molecule expression during tumor spontaneous regression. *Cancer Immunology, Immunotherapy*. 2008;57(7):1091-1104. doi: <https://doi.org/10.1007/s00262-007-0446-5>
- Agnew DW, MacLachlan NJ. Tumors of genital system. In: Meuten DJ. *Tumors in domestic animals*. 5 ed. Ames: Wiley Blackwell; 2017. p.689-722.
- Ballesterio FH, Montoya FL, Yamatogi RS, Duzanski AP, Araújo JP, Oliveira RA, Rocha NS. Does the tumour microenvironment alter tumorigenesis and clinical response in transmissible venereal tumour in dogs? *Veterinary and Comparative Oncology*. 2018;16(3):370-378. doi: <https://doi.org/10.1111/vco.12388>
- Amaral AS, Silva SB, Ferreira I, Fonseca LS, Andrade FHEA, Gaspar LFJ, Rocha NS. Cytomorphological characterization of transmissible canine venereal tumor. *Revista Portuguesa de ciências veterinárias*. 2007;102(563-564):253-260. Disponível em: [http://www.fmv.ulisboa.pt/spcv/12\\_2007.htm](http://www.fmv.ulisboa.pt/spcv/12_2007.htm)
- Lima CRO, Rabelo RE, Vulciani VAS, Furtado AP, Helrigel PA, Brito LAB, Moura VMBD. Morphological patterns and malignancy criteria of transmissible venereal tumor in cytopathological and histopathological exams. *Brazilian Journal of Veterinary Research and Animal Science*. 2013;50(3):238-246. doi: <https://doi.org/10.11606/issn.1678-4456.v50i3p238-246>
- Pimentel PA, Oliveira CS, Horta RS. Epidemiological study of canine transmissible venereal tumor (CTVT) in Brazil, 2000–2020. *Preventive veterinary medicine*. 2021;197:105526. doi: <https://doi.org/10.1016/j.prevetmed.2021.105526>.
- Huppés RR, Silva CG, Uscategui RAR, De Nardi AB, Souza FW, Tinucci-Costa M, Amorim RL, Pazzini JM, Faria JML. Venereal Transmissible Tumor (TVT): Retrospective Study of 144 Cases. *Ars Veterinaria*. 2014;30(1):13-18. doi: <http://dx.doi.org/10.15361/2175-0106.2014v30n1p13-18>
- Strakova A, Murchison EP. The changing global distribution and prevalence of canine transmissible venereal tumour. *BMC veterinary research*. 2014;10(1):1-11. doi: <https://doi.org/10.1186/s12917-014-0168-9>
- Solano-Gallego L, Miró G, Koutinas A, Cardoso L, Pennisi MG, Ferrer L, Bourdeau P, Oliva G, Baneth G. LeishVet guidelines for the practical management of canine leishmaniasis. *Parasites & vectors*. 2011;4(1):1-16. doi: <https://doi.org/10.1186/1756-3305-4-86>
- Sainz A, Roura X, Miró G, Estrada-Peña A, Kohn B, Harrus

- S, Solano-Gallego L. Guideline for veterinary practitioners on canine ehrlichiosis and anaplasmosis in Europe. *Parasites & vectors*. 2015;8(1):1-20. doi: <https://doi.org/10.1186/s13071-015-0649-0>
23. Birhan G, Chanie M. A review on canine transmissible venereal tumor: from morphologic to biochemical and molecular diagnosis. *Academic Journal of Animal Diseases*. 2015;4(3):185-195. doi: <https://doi.org/10.5829/idosi.ajad.2015.4.3.95245>
24. Silva MVM, Fernandes RA, Nogueira JL, Ambrósio CE. Erliquiose canina: revisão de literatura. *Arquivos de Ciências Veterinárias e Zoologia da UNIPAR*. 2011;14(2):139-143. Disponível em: <https://revistas.unipar.br/index.php/veterinaria/article/view/4149>
25. Sousa VRF, Almeida ABPF, Barros LA, Sales KG, Justino CHS, Dalcin L, Bomfim TCB. Avaliação clínica e molecular de cães com erliquiose. *Ciência Rural*. 2010;40(6):1309-1313. doi: <https://doi.org/10.1590/S0103-84782010000600011>
26. Das Neves EC, De Souza SF, De Carvalho YK, Ribeiro VMF, Medeiros LS. Erliquiose Monocítica Canina: Uma zoonose em ascensão e suas limitações diagnósticas no Brasil. *Medvep - Revista Científica de Medicina Veterinária - Pequenos Animais e Animais de Estimação*. 2014;12(40):1-7. Available from: <https://medvep.com.br/erliquiose-monocitica-canina-uma-zoonose-em-ascensao-e-suas-limitacoes-diagnosticas-no-brasil/>
27. Arcila-Villa A, Dussán-Lubert C, Pedraza-Ordoñez F. Distribution and prevalence of transmissible venereal tumor in the Colombian canine population. *Revista Colombiana de Ciencias Pecuarias*. 2018;31(3):180-187. doi: <https://doi.org/10.17533/udea.rccp.v31n3a02>
28. Frampton D, Schwenzer H, Marino G, Butcher LM, Pollara G, Kriston-Vizi J, Venturini C, Austin R, De Castro KF, Ketteler R, Chain B, Goldstein RA, Weiss RA, Beck S, Fassati A. Molecular signatures of regression of the canine transmissible venereal tumor. *Cancer Cell*. 2018;33:620-633. doi: <https://doi.org/10.1016/j.ccell.2018.03.003>
29. Alzate JM, Montoya-Florez LM, Pérez JE, Rocha NS, Pedraza-Ordóñez FJ. The role of the multi-drug resistance 1, p53, b cell lymphoma 2, and bcl 2-associated X genes in the biologic behavior and chemotherapeutic resistance of canine transmissible venereal tumors. *Veterinary clinical pathology*. 2019;48(4):730-739. doi: <https://doi.org/10.1111/vcp.12805>
30. Stockmann D, Ferrari HF, Andrade AL, Lopes RA, Cardoso TC, Luvizotto MCR. Canine transmissible venereal tumors: aspects related to programmed cell death. *Brazilian Journal of Veterinary Pathology*. 2011;4(1):67-75. Available from: <http://hdl.handle.net/11449/72386>
31. Santos FGA, Vasconcelos AC, Nunes JES, Cassali GD, Paixão TA, Martins AS, Silva SS, Martins RF, Moro L. Apoptosis in the transplanted canine transmissible venereal tumor during growth and regression phases. *Arquivo Brasileiro de Medicina Veterinária e Zootecnia*. 2008;60(3):607-612. doi: <https://doi.org/10.1590/S0102-09352008000300013>