

## CLINICAL SCIENCE

# Fallopian tube origin of supposed ovarian high-grade serous carcinomas

Patricia Martini Diniz,<sup>I</sup> Jesus Paula Carvalho,<sup>II</sup> Edmund Chada Baracat,<sup>II</sup> Filomena M. Carvalho<sup>III</sup>

<sup>I</sup>Faculdade de Medicina da Universidade de São Paulo; CNPq Initiation Scientific Scholarship – (PIBIC 119637/2009-0). <sup>II</sup>Department of Obstetrics and Gynecology, Faculdade de Medicina da Universidade de São Paulo, São Paulo, Brazil. <sup>III</sup>Department of Pathology, Faculdade de Medicina da Universidade de São Paulo, São Paulo, Brazil.

**INTRODUCTION:** Serous carcinomas are the most frequent histologic type of ovarian and peritoneal cancers, and can also be detected in the endometrium and fallopian tubes. Serous carcinomas are usually high-grade neoplasms when diagnosed, yet the identification of an associated precursor lesion remains challenging. Pathological examination of specimens obtained from prophylactic bilateral salpingo-oophorectomies that were performed for patients harboring *BRCA1/2* mutations suggests that high-grade serous carcinomas may arise in the fallopian tubes rather than in the ovaries.

**OBJECTIVE:** To investigate the presence and extent of fallopian tube involvement in cases of serous pelvic carcinomas.

**METHODS:** Thirty-four cases of serous pelvic carcinoma with clinical presentations suggesting an ovarian origin were analyzed retrospectively. Histologic samples of fallopian tube tissues were available for these cases and were analyzed. Probable primary site, type of tubal involvement, tissues involved in the neoplasia and vascular involvement were evaluated.

**RESULTS:** Fallopian tube involvement was observed in 24/34 (70.6%) cases. In 4 (11.8%) of these cases, an intraepithelial neoplasia was present, and therefore these cases were hypothesized to be primary from fallopian tubes. For an additional 7/34 (20.6%) cases, a fallopian tube origin was considered a possible primary.

**CONCLUSIONS:** Fallopian tubes can be the primary site for a subset of pelvic high-grade serous carcinomas.

**KEYWORDS:** Serous carcinoma; Ovarian cancer; Fallopian tube carcinoma; Peritoneal cancer; *BRCA1*; *BRCA2*.

Diniz PM, Carvalho JP, Baracat EC, Carvalho FM. Fallopian tube origin of supposed ovarian high-grade serous carcinomas. Clinics. 2011;66(1):73-76.

Received for publication on September 23, 2010; First review completed on October 15, 2010; Accepted for publication on October 15, 2010

E-mail: carvalhojp@uol.com.br

Tel.: 55 11 3255-5544

## INTRODUCTION

Ovarian cancer is the eighth most common malignancy diagnosed in women, the fifth leading cause of death from cancer in women and the leading cause of death among gynecologic cancers. Approximately 75% of all ovarian cancer cases are in an advanced stage at the time of diagnosis. Furthermore, the median overall survival period for advanced ovarian cancer is 15–23 months, with a 5-year survival rate of only 20%.<sup>1,2</sup> Unfortunately, there are no effective prevention or screening programs currently in place that have been shown to improve patient survival for this disease.

For most women, the lifetime risk of developing ovarian cancer is ~1.7%. However, for women carrying *BRCA1* or *BRCA2* gene mutations, that risk increases to 56% and 27%

respectively.<sup>3</sup> Therefore, the need for prevention and screening programs is even more significant for this population of women.

The most frequent histologic type diagnosed for ovarian cancers is serous carcinoma, which corresponds to ~80% of ovarian cancer cases in developed countries.<sup>4</sup> Serous carcinomas are classified as low grade or high grade,<sup>5–7</sup> and develop from two different pathogenetic pathways.<sup>7,8,13–15</sup> Low-grade serous carcinomas harbor mutations in *k-ras* and *braf*,<sup>7–13</sup> whereas high-grade serous carcinomas present mutations in the *TP53* gene.<sup>11,12</sup>

One of the significant aspects of ovarian carcinogenesis that remains unclear is the precursor lesion responsible for this disease. For almost all epithelial gynecological cancers, whether they arise from the vulva, vagina, cervix or endometrium, they arise via a sequence of events that begins in normal epithelium, then passes through non-obligatory precursor lesions to become invasive neoplasias. For ovarian cancer, as it is usually diagnosed in its advanced stages, ovarian precursor lesions have not been identified. However, in the last few years, increasing evidence has indicated that tubal fimbria lesions are candidates to be

precursor lesions of ovarian high-grade serous carcinomas.<sup>14</sup>

Studies of surgical specimens derived from prophylactic salpingo-oophorectomies performed on women carrying *BRCA* gene mutations have been associated with a 2.3% rate of occult carcinomas. In almost all cases, the neoplasias involved the fallopian tubes instead of the ovaries, and intraepithelial tubal neoplasias were present in the fimbria region. When the end of the terminal fimbriae were systematically processed and examined, the incidence of fimbrial intraepithelial neoplasias increased to as much as 17%.<sup>15</sup>

Surprisingly, most of the cancers detected in their early stages in women carrying *BRCA* mutations arise in the fallopian tube. Additional studies have further pinpointed the distal fimbrial portion of the fallopian tube as the most common site of origin.<sup>15-17</sup> However, other studies have found a high frequency of early-stage cancer in the fimbriae of women who do not carry *BRCA* mutations, yet have been diagnosed with ovarian and peritoneal serous carcinomas. In combination, these results suggest that a significant proportion of serous carcinomas have a fimbrial origin, independent of *BRCA* mutations.<sup>17,18</sup>

Based on the uncertain identity of the precursor lesions associated with ovarian serous carcinomas, and the hypothesis that the fallopian tubes are the primary site of these malignancies, this retrospective study was conducted to evaluate the frequency and patterns of involvement of the uterine tubes in a cohort of high-grade pelvic serous carcinomas.

## MATERIAL AND METHODS

This study was approved by the Department of Obstetrics and Gynecology and by the Department of Pathology scientific committees of the Faculdade de Medicina da Universidade de São Paulo (Brazil), as well as by the ethics committee for research projects of the Hospital das Clinicas da Faculdade de Medicina da Universidade de São Paulo (Brazil) (Comissão de Ética para Análise de Pesquisa – CAPPesq) (under no. 0283/09).

This retrospective study included 34 consecutive cases of patients presenting with pelvic tumors that were clinically suspicious for an ovarian origin. These cases were diagnosed between January 1, 2005 and July 1, 2010, and were processed and diagnosed by the same pathologist (FMC). Only cases with at least three histological sections of fallopian tube tissue, with representative areas of fimbriae, were analyzed. Furthermore, all cases were classified according to: (a) primary tumor site; (b) fallopian tube involvement; (c) involvement of other organs; and (d) lymphatic vascular involvement.

To define the primary tumor site, the following characteristics were evaluated: tumor volume, distribution of tumor in the ovaries (diffuse or partial) and the presence of intraepithelial carcinoma (for tubal and endometrial origins). Partial involvement of ovaries was associated with larger tumors in the peritoneum, and these were considered to be peritoneal in origin. Diffuse involvement of the ovaries was also suggestive of an ovarian origin. The presence of intraepithelial serous carcinoma in the fallopian tubes was indicative of a tubal origin. Endometrial origin was considered in cases with an in situ component associated with the endometrium and minimal to absent ovarian involvement. Cases involving multiple organs without a clear site of origin were classified as having an indeterminate site.

Tubal involvement was accessed in all cases and, when it was present, it was classified as: intraepithelial neoplasia, serosa involvement, intraluminal neoplasia (not connected to the mucosa) or wall invasion.

## RESULTS

For the 34 cases examined, patient age ranged from 24 to 68 years, with a median age of 51 years and a mean age of  $52.3 \pm 11.32$  years. The main surgical-pathological findings are listed in Table 1, and ovarian involvement was frequently observed (91.2%). However, in 12/31 (38.7%) cases, the ovarian parenchyma was partially involved, with neoplasias only detected on the surface and the superficial cortical stroma. The largest tumor among these cases was

**Table 1 - Surgical and pathological findings in 34 pelvic serous carcinoma cases.**

Surgical-pathological features		N (%)
Surgical procedure	Complete staging* with lymph node samples	16 (47%)
	Complete staging without lymph node samples	11 (32.3%)
	Hysterectomy with bilateral salpingo-oophorectomy	2 (5.9%)
	Bilateral salpingo-oophorectomy	3 (8.8%)
	Unilateral salpingo-oophorectomy with peritoneal biopsy	1 (2.9%)
	Salpingectomy with peritoneal biopsy	1 (2.9%)
Ovarian involvement	Absent	2 (5.9%)
	Bilateral, partial involvement	10 (29.4%)
	Bilateral, diffuse involvement	17 (50%)
	Unilateral, partial involvement	2 (5.9%)
	Unilateral, partial involvement	2 (5.9%)
	Unknown†	1 (2.9%)
Peritoneal involvement	Absent	4 (11.8%)
	Present	30 (88.2%)
Vascular embolization	Absent	19 (55.9%)
	Present	15 (44.1%)
Lymph node metastasis‡	Absent	12 (75%)
	Present	4 (25%)

\*Total hysterectomy with bilateral salpingo-oophorectomy, omentectomy and multiple peritoneal biopsy.

†Patient submitted to unilateral salpingectomy.

‡Available for 16 cases.

**Table 2** - Summary of pathology data from 34 cases of pelvic serous carcinoma.

Primary origin site	N (%)	Fallopian tube involvement
Peritoneum	11 (32.3%)	6 (54.5%)
Ovary	9 (26.5%)	6 (66.7%)
Fallopian tubes	4 (11.8%)	4 (100%)
Endometrium*	2 (5.9%)	0 (0)
Undetermined	8 (23.5%)	8 (100%) <sup>†</sup>
Total	34 (100%)	24 (70.6%)

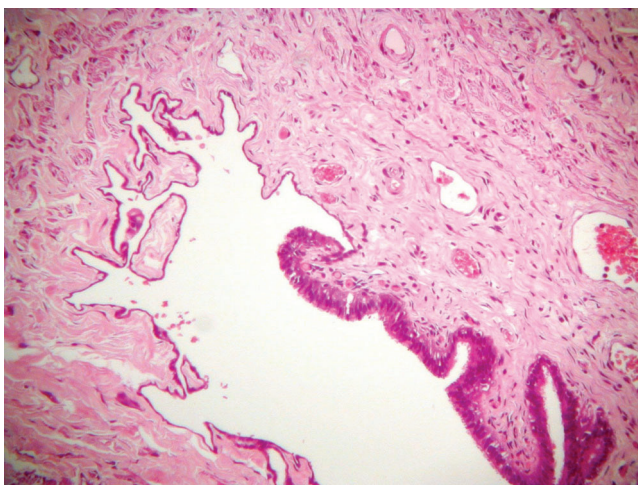
\*Serous endometrial carcinoma with peritoneal involvement.

<sup>†</sup>In 7 of these cases, the fallopian tube was considered as the possible primary site.

1.1 cm along its greatest diameter, and bilateral involvement was more frequent than unilateral involvement (27/31, 87.1% vs. 4/31, 12.9% respectively).

Peritumoral neoplastic vascular involvement was observed in 15/34 (44.1%) cases. Moreover, 2 (13.3%) of these cases involved lymph node metastasis, 5 (33.3%) cases had negative lymph nodes and, in 8 (53.3%) cases, the lymph nodes were not examined. The 8 cases without lymph node samples available were endometrial carcinoma associated with peritoneal carcinomatosis (n=2), ovarian carcinoma (n=3), tubal carcinoma (n=2) and peritoneal carcinoma (n=1). Lymph node metastasis was also detected in 2 cases without vascular neoplastic embolization, and both were associated with primary tumors in the peritoneum without tubal involvement.

The distribution of cases according to primary tumor site and tubal involvement is presented in Table 2. Fallopian tube involvement was identified in 24/34 (70.6%) cases, and tubal serosa was involved in 23/24 cases. Furthermore, in 4/24 (16.7%) cases, the intraepithelial serous carcinoma could be identified (Figure 1). For the other 20 cases, serous neoplasia was associated with infiltration of the fallopian tube wall (n=17), exclusive serous involvement (n=2) and intraluminal neoplasia without an observable connection to the tubal wall (n=1). In addition, there were 2 cases where the origin of the neoplasia was clearly localized to the fimbriae and, in 4 cases, the intraepithelial neoplasia



**Figure 1** - Fimbria region of the fallopian tube showing abrupt transition between mesothelial lining and intraepithelial neoplasia. Hematoxylin-eosin. Original magnification 100 $\times$ .

characterized the origin in the fallopian tube. Seven other cases had tubal involvement associated with either the peritoneum (n=5) or the ovary plus the peritoneum (n=2). However, these cases were classified as indeterminate, although there was a high probability that these neoplasias were associated with a primary tubal tumor. Furthermore, in 2 of these cases, involvement of the fimbriae region was evident.

## DISCUSSION

High-grade serous carcinomas involving pelvic organs are usually classified as ovarian carcinomas. Moreover, up until the late 1990s, primary fallopian tube carcinoma was considered one of the less common malignancies of the female genital tract, representing less than 1% of all gynecologic malignancies.<sup>19</sup> Unfortunately, despite significant efforts worldwide to improve the prevention, screening and early diagnosis of ovarian cancer, little or no progress has been made in improving patient survival. In the United States, the estimated number of new ovarian cancer cases in 2010 is 21,880, while the number of anticipated deaths is 13,850.<sup>2</sup> These high mortality rates require that efforts be improved to reduce the risk of diagnosing ovarian cancer in its advanced stages, particularly for women with *BRCA* mutations. In the latter case, a bilateral salpingo-oophorectomy at the age of 35–40 years, or when childbearing is complete, is the strategy currently advocated to reduce the risk of ovarian cancer in patients with *BRCA* mutations.<sup>20</sup> However, emerging evidence indicates that the fallopian tube origin of some high-grade ovarian serous carcinomas may necessitate that the strategies for prevention and early detection be modified further.<sup>14,16,21,22</sup>

The findings of this study were consistent with the hypothesis that most pelvic high-grade serous carcinomas have a fallopian tube origin that was previously more commonly attributed to the ovaries. In this study, all the cases examined had a preoperative diagnosis of a probable ovarian carcinoma, and some were diagnosed pathologically as serous ovarian carcinomas. Furthermore, pathological examinations indicated that an ovarian neoplasia was present in 31/34 cases. However, in 12 (39%) of these cases, the ovarian involvement was partial, suggesting secondary involvement.

Fallopian tube involvement was identified in more than 70% of the cases examined, and this is consistent with the results of Kindelberger et al.<sup>23</sup> Moreover, the fallopian tubes were the clear primary site of origin in 4 (17%) of the cases reviewed in the present study, which was confirmed by the identification of an intraepithelial carcinoma present in the fallopian tubes for each case. In another 7 (29.1%) cases, the fallopian tubes were predicted to be the primary site. Furthermore, in two of these cases, the tumor was closely related to the fimbriae, which is the anatomic site of origin for tubal carcinomas according to recent studies.<sup>14,15,17,23</sup> Even among the cases classified as ovarian carcinomas, fallopian tube involvement was very common (6/9, 66.7%), thereby suggesting that primary fallopian tube neoplasia may be involved. Correspondingly, it has previously been hypothesized by Kurman and Shih<sup>7</sup> that serous carcinomas can originate in the fimbriae, then shed on to the peritoneal or ovarian surfaces to grow and manifest clinically.

One of the limitations of this study was the small number of cases examined. However, an additional limitation was

that not all the cases analyzed had the fimbriae region included in its entirety for histological studies, as recommended by the SEE-Fim (Sectioning and Extensively Examining the FIMbria) protocol.<sup>15</sup> If additional histological sections of fimbriae had been available, it is possible that more cases of primary tubal origin would have been identified, especially as precursor lesions present in the fimbriae, the so-called p53 signature, can be very tiny as a nest of approximately 13 cells that express p53.<sup>24</sup>

Chronic inflammation has been shown to be a carcinogenic factor for many sites, including the cervix, cardia and liver. It has also been considered to be a possible factor in the development of tubal carcinogenesis.<sup>21,25</sup> In addition, the fallopian tube is a site that is regularly exposed to a variety of inflammatory agents. For example, *Chlamydia trachomatis* is a very common biologic agent that infects the fallopian tubes. Although it is present as an asymptomatic disease most of the time, the role of *Chlamydia trachomatis* in fallopian tube carcinogenesis remains to be evaluated.<sup>25</sup>

As the fallopian tubes emerge as a potential site of origin for some ovarian serous high-grade carcinomas, additional aspects need to be considered. For example, what should be the prophylactic surgery prescribed for high-risk women? How should screening and early diagnosis strategies be modified according to this new perspective? What are the cofactors related to fimbriae carcinogenesis?

In conclusion, fallopian tubes were identified as a primary site for a subset of pelvic serous carcinomas. Additional studies of larger cohorts will be needed to confirm these results. However, these initial studies provide valuable insight into the identification of potential primary tumor sites for ovarian carcinomas that have previously proved elusive in many cases.

## REFERENCES

1. Winter WE 3rd, Maxwell GL, Tian C, Sundborg MJ, Rose GS, Rose PG, et al. Tumor residual after surgical cytoreduction in prediction of clinical outcome in stage IV epithelial ovarian cancer: a Gynecologic Oncology Group Study. *J Clin Oncol.* 2008;26:83-9, doi: 10.1200/JCO.2007.13.1953.
2. Jemal A, Siegel R, Xu J, Ward E. Cancer statistics, 2010. *CA Cancer J Clin.* 2010;60, doi: 10.3322/caac.20073.
3. Sogaard M, Kjaer SK, Gayther S. Ovarian cancer and genetic susceptibility in relation to the BRCA1 and BRCA2 genes. Occurrence, clinical importance and intervention. *Acta Obstet Gynecol Scand.* 2006;85:93-105, doi: 10.1080/00016340500324621.
4. Seidman JD, Horkayne-Szakaly I, Haiba M, Boice CR, Kurman RJ, Ronnett BM. The histologic type and stage distribution of ovarian carcinomas of surface epithelial origin. *Int J Gynecol Pathol.* 2004;23:41-4, doi: 10.1097/01.pgp.0000101080.35393.16.
5. Vang R, Shih Ie M, Kurman RJ. Ovarian low-grade and high-grade serous carcinoma: pathogenesis, clinicopathologic and molecular biologic features, and diagnostic problems. *Adv Anat Pathol.* 2009;16:267-82, doi: 10.1097/PAP.0b013e3181b4fffa.
6. Gershenson DM, Sun CC, Lu KH, Coleman RL, Sood AK, Malpica A, et al. Clinical behavior of stage II-IV low-grade serous carcinoma of the ovary. *Obstet Gynecol.* 2006;108:361-8, doi: 10.1097/01.AOG.0000227787.24587.d1.
7. Kurman RJ, Shih Ie M. The origin and pathogenesis of epithelial ovarian cancer: a proposed unifying theory. *Am J Surg Pathol.* 2010;34:433-43, doi: 10.1097/PAS.0b013e3181cf3d79.
8. Shih M, Kurman RJ. Ovarian tumorigenesis: a proposed model based on morphological and molecular genetic analysis. *Am J Pathol.* 2004;164:1511-18.
9. Singer G, Oldt R 3rd, Cohen Y, Wang BG, Sidransky D, Kurman RJ, et al. Mutations in BRAF and KRAS characterize the development of low-grade ovarian serous carcinoma. *J Natl Cancer Inst.* 2003;95:484-6, doi: 10.1093/jnci/95.6.484.
10. Singer G, Stohr R, Cope L, Dehari R, Hartmann A, Cao DF, et al. Patterns of p53 mutations separate ovarian serous borderline tumors and low- and high-grade carcinomas and provide support for a new model of ovarian carcinogenesis: a mutational analysis with immunohistochemical correlation. *Am J Surg Pathol.* 2005;29:218-24, doi: 10.1097/01.pas.0000146025.91953.8d.
11. Singer G, Kurman RJ, Chang HW, Cho SK, Shih Ie M. Diverse tumorigenic pathways in ovarian serous carcinoma. *Am J Pathol.* 2002;160:1223-8.
12. Sieben NL, Macropoulos P, Roemen GM, Kolkman-Uljee SM, Jan Fleuren G, Houmadi R, et al. In ovarian neoplasms, BRAF, but not KRAS, mutations are restricted to low-grade serous tumours. *J Pathol.* 2004;202:336-40, doi: 10.1002/path.1521.
13. Folkins AK, Jarboe EA, Roh MH, Crum CP. Precursors to pelvic serous carcinoma and their clinical implications. *Gynecol Oncol.* 2009;113:391-6, doi: 10.1016/j.ygyno.2009.01.013.
14. Lee Y, Miron A, Drapkin R, Nucci MR, Medeiros F, Saleemuddin A, et al. A candidate precursor to serous carcinoma that originates in the distal fallopian tube. *J Pathol.* 2007;211:26-35, doi: 10.1002/path.2091.
15. Medeiros F, Muto MG, Lee Y, Elvin JA, Callahan MJ, Feltmate C, et al. The tubal fimbria is a preferred site for early adenocarcinoma in women with familial ovarian cancer syndrome. *Am J Surg Pathol.* 2006;30:230-6, doi: 10.1097/01.pas.0000180854.28831.77.
16. Crum CP, Drapkin R, Miron A, Ince TA, Muto M, Kindelberger DW, et al. The distal fallopian tube: a new model for pelvic serous carcinogenesis. *Curr Opin Obstet Gynecol.* 2007;19:3-9, doi: 10.1097/GCO.0b013e328011a21f.
17. Crum CP, Drapkin R, Kindelberger D, Medeiros F, Miron A, Lee Y. Lessons from BRCA: the tubal fimbria emerges as an origin for pelvic serous cancer. *Clin Med Res.* 2007;5:35-44, doi: 10.3121/cm.2007.702.
18. Crum CP, Xian W. Bringing the p53 signature into focus. *Cancer.* 2010;116:5119-21.
19. Nikrui N, Duska LR. Fallopian tube carcinoma. *Surg Oncol Clin N Am.* 1998;7:363-73.
20. Gadducci A, Biglia N, Cosio S, Sismondi P, Genazzani AR. Gynaecologic challenge issues in the management of BRCA mutation carriers: oral contraceptives, prophylactic salpingo-oophorectomy and hormone replacement therapy. *Gynecol Endocrinol.* 2010;26:568-77, doi: 10.3109/09513590.2010.487609.
21. Salvador S, Gilks B, Kobel M, Huntsman D, Rosen B, Miller D. The fallopian tube: primary site of most pelvic high-grade serous carcinomas. *Int J Gynecol Cancer.* 2009;19:58-64, doi: 10.1111/IGC.0b013e318199009c.
22. Carlson JW, Miron A, Jarboe EA, Parast MM, Hirsch MS, Lee Y, et al. Serous tubal intraepithelial carcinoma: its potential role in primary peritoneal serous carcinoma and serous cancer prevention. *J Clin Oncol.* 2008;26:4160-5, doi: 10.1200/JCO.2008.16.4814.
23. Kindelberger DW, Lee Y, Miron A, Hirsch MS, Feltmate C, Medeiros F, et al. Intraepithelial carcinoma of the fimbria and pelvic serous carcinoma: Evidence for a causal relationship. *Am J Surg Pathol.* 2007;31:161-9, doi: 10.1097/01.pas.0000213335.40358.47.
24. Mehrad M, Ning G, Chen EY, Mehra KK, Crum CP. A pathologist's road map to benign, precancerous, and malignant intraepithelial proliferations in the fallopian tube. *Adv Anat Pathol.* 2010;17:293-302, doi: 10.1097/PAP.0b013e3181ecdee1.
25. Carvalho JP, Carvalho FM. Is Chlamydia-infected tubal fimbria the origin of ovarian cancer? *Med Hyp.* 2008;71:690-3, doi: 10.1016/j.mehy.2008.06.028.