

# Effectiveness of Limberg and Karydakís flap in recurrent pilonidal sinus disease

Ilhan Bali,<sup>1</sup> Mehmet Aziret,<sup>1,\*</sup> Selim Sözen,<sup>1</sup> Seyfi Emir,<sup>1</sup> Hasan Erdem,<sup>111</sup> Süleyman Çetinküner,<sup>111</sup> Oktay İrkörücü<sup>111</sup>

<sup>1</sup>Nađnik Kemal University, Department of General Surgery, Tekirdađ, Turkey. <sup>111</sup>Kars State Hospital General Surgery, Kars, Merkez, Turkey. <sup>111</sup>Adana Training and Research Hospital, Department of General Surgery, Adana, Turkey.

**OBJECTIVE:** Sacrococcygeal pilonidal sinus is common in young men and may recur over time after surgery. We investigated whether a factor exists that can aid in the determination of the preferred technique between the early Limberg flap and Karydakís flap techniques for treating recurrent pilonidal sinus.

**MATERIALS AND METHODS:** This prospective and randomized study enrolled 71 patients with recurrent pilonidal sinus in whom the Limberg flap or Karydakís flap techniques were applied for reconstruction after excision. Patients were divided into two groups as follows: 37 patients were treated with the Limberg flap technique and 34 patients were treated with the Karydakís flap technique. Fluid collection, wound infection, flap edema, hematoma, partial wound separation, return to daily activities, pain score, complete healing time, painless seating and patient satisfaction were compared between the groups. **ClinicalTrial.gov:** NCT02287935.

**RESULTS:** The development rates of total fluid collection, wound infection, flap edema, hematoma, and partial wound separation were 9.8%, 16%, 7%, 15% and 4.2%, respectively; total flap necrosis was not observed in any patient ( $p < 0.001$ ). During the average follow-up of 28 months, no patients (0%) developed recurrent disease. The two groups differed with respect to early surgical complications ( $p < 0.001$ ).

**CONCLUSION:** In this study, use of the Limberg flap was associated with lower complication rates, shorter length of hospital stay, early return to work, low pain score, high patient satisfaction and better complete healing duration. Therefore, we recommend the Limberg flap for treatment of recurrent pilonidal sinus.

**KEYWORDS:** Karydakís flap; Limberg technique; Recurrent pilonidal sinus.

Bali İ, Aziret M, Sözen S, Emir S, Erdem H, Çetinküner S, et al. Effectiveness of Limberg and Karydakís flap in recurrent pilonidal sinus disease. *Clinics*. 2015;70(5):350-355

Received for publication on November 10, 2014; First review completed on January 27, 2015; Accepted for publication on February 13, 2015

E-mail: mhmtaziret@gmail.com

\*Corresponding author

## ■ INTRODUCTION

Pilonidal sinus (PS) is a common disease of the natal cleft in the sacrococcygeal region with weak hair accumulation occurring in the hair follicles, which can be chronic and undergo acute exacerbation (1,2). The incidence of PS is approximately 26/100,000; it is a benign disease that occurs in young men (3,4).

The etiology and pathogenesis of PS are not clear, although the disease is thought to be related to the accumulation of weak and lifeless hair in the intergluteal region. Over time, foreign body reaction occurs, causing abscess and sinus formation. Obesity, trauma, local irritation and a sedentary lifestyle are usually associated with PS (2,5).

Although pilonidal sinus can be treated using several defined conservative and surgical methods, recurrence rates remain high (6). Complete removal of the pilonidal sinus or sinuses and appropriate reconstruction can lead to successful recovery (7). However, collection of the lifeless hair depends on the anatomy of the intergluteal area, and accompanying risk factors can lead to inadequate surgery and subsequent recurrence (6,8).

Our aim in this study was to prospectively compare early results in patients with recurrent pilonidal sinus treated with either the Karydakís flap (KF) procedure or Limberg flap rotation (LF).

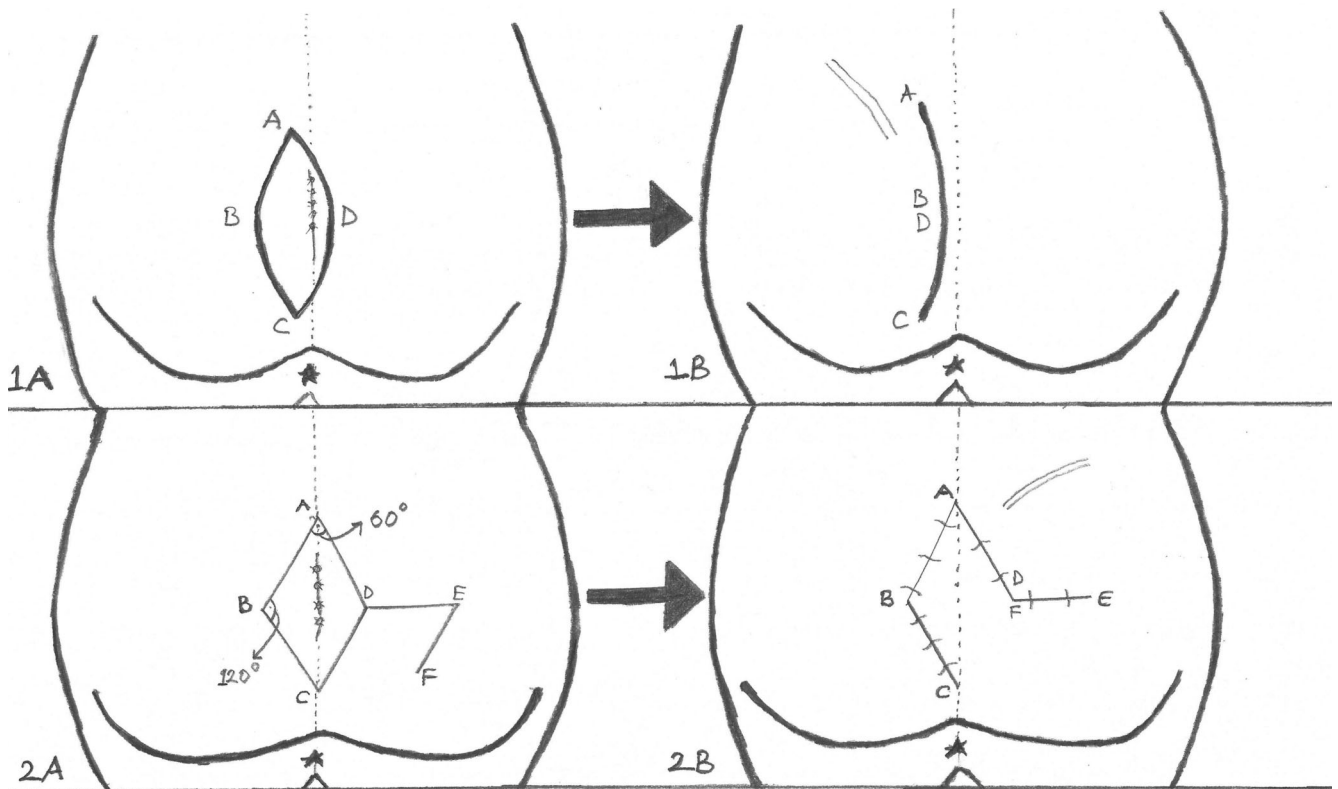
## ■ MATERIALS AND METODS

This study was conducted at the surgery departments at Elazi, Kayseri and Adana Numune Training and Research Hospitals from January 2009 to December 2013. Seventy-one patients who were treated only for recurrent pilonidal disease were eligible for the study. Patients with previous surgical procedures, including primary closure (71 cases) were considered to have recurrent disease. The 71 patients who had been treated with midline closure were divided into the following two treatment groups: the LF group

**Copyright** © 2015 CLINICS – This is an Open Access article distributed under the terms of the Creative Commons Attribution Non-Commercial License (<http://creativecommons.org/licenses/by-nc/3.0/>) which permits unrestricted non-commercial use, distribution, and reproduction in any medium, provided the original work is properly cited.

No potential conflict of interest was reported.

**DOI:** 10.6061/clinics/2015(05)08



**Figure 1 - Asymmetric elliptical excision (1A). Closure of the cavity with Karydakís flap (1B). Rhomboid excision (2A). Limberg flap and construction after rhomboid excision (2B).**

(Limberg flap) and KF group (Karydakís flap). All patients were prospectively evaluated in terms of gender and age, location of sinus pits, postoperative length of hospital stay, postoperative complications (wound dehiscence, infection, hematoma, seroma and cosmetics) and recurrence. The Ethical Committee of our center approved the study protocol.

### Surgical procedure

**Limberg flap method:** All patients were operated on under spinal anesthesia in the operating room. After anesthesia, the patients were placed in the prone, jack-knife position, with the buttocks strapped apart using wide adhesive tape. Methylene blue was injected in the sinus tract using a 6-Fr feeding tube. The excision was carried down to the fascia overlying the sacrum and laterally to the fascia of the gluteus maximus muscle. Dissection was performed with electrocautery. A Limberg flap was prepared from the right or left gluteal region. A suction drain (B-VAK Wound Drainage System™, 10 Ch, Ref. 17110211, BiCakCilar, Istanbul, Turkey) was placed through a separate incision that was located 2 cm lateral from the initial incision and maintained in place until the drainage decreased to less than 10 ml/day (Figures 1 and 2).

**Karydakís flap procedure:** Operations were performed under spinal anesthesia with the patient in the prone position with the buttocks strapped apart. No patient was given prophylactic antibiotics. The surgical site was shaved immediately before the operation, and the skin was prepared

with povidone-iodine solution. Methylene blue was infused through the sinus to delineate the fistula tract in patients with open orifices. A Karydakís flap was created as described previously (2,4) (Figures 1 and 3). A suction drain (B-VAK Wound Drainage System™, 10 Ch, Ref. 17110211, BiCakCilar, Istanbul, Turkey) was placed through a separate incision that was located 2 cm lateral from the initial incision in 17 (50 percent) patients (Group 1) and was maintained in place until the drainage decreased to less than 10 ml/day. The remaining 17 patients underwent surgery without any drain placement (Group 2). All incisions were dressed under pressure using several gauze packs and tight bandages (Figures 1 and 3).

### Inclusion criteria

1. Patients willing to give written informed consent.
2. Presence of recurrent pilonidal sinus.
3. Adult (over 16 years of age) undergoing surgery for recurrent pilonidal sinus.
4. International normalizing ratio (INR) of less than 1.5.
5. Prothrombin time (PT) of less than 15 s.
6. Partial thromboplastin (PTT) time near normal.
7. Platelet count greater than 50,000 per  $\text{mm}^3$  to limit the risk of bleeding.
8. No infection at time of surgery.

### Exclusion criteria

1. Patients not willing to give informed consent.
2. Age less than 16 years.

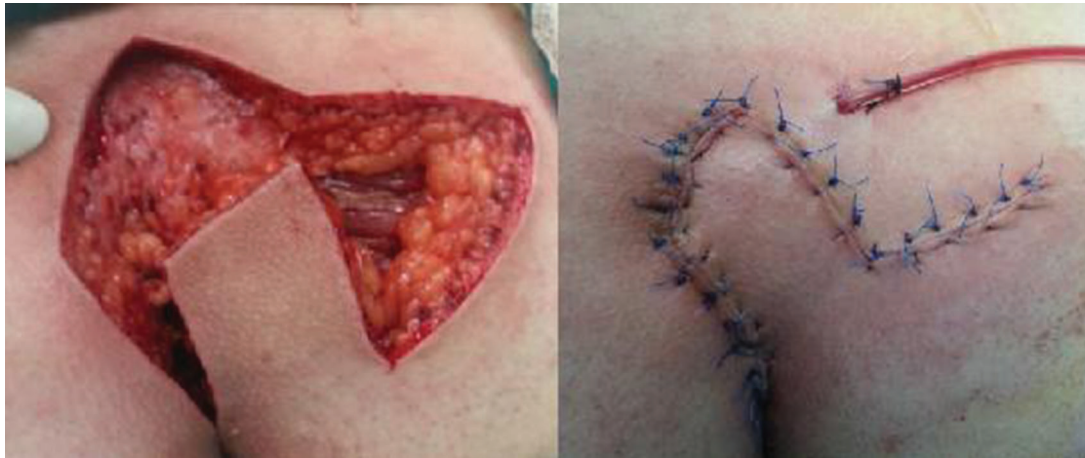

Figure 2 - Limberg flap technique.

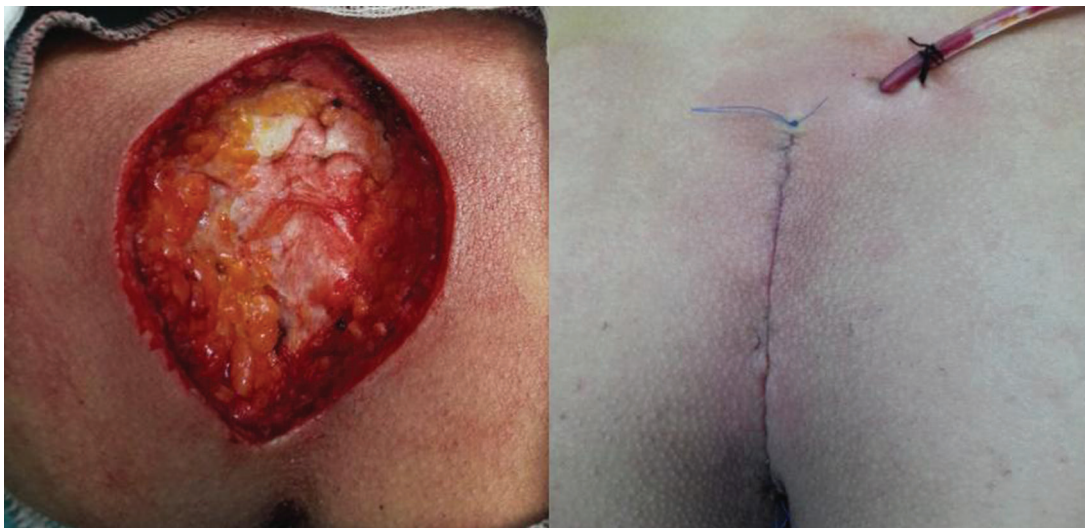

Figure 3 - Karydakis flap rotation.

3. Patient presenting with different conditions mimicking pilonidal sinus.

4. Chronic medical conditions, such as diabetes mellitus, renal failure, or immunosuppression.

#### Randomization criteria

In this study, patients with recurrent pilonidal sinus were accepted who were between 16-40 years of age and were without pilonidal sinus abscess or infection.

#### Statistical analysis

Statistical analyses were performed using SPSS (Statistical Package for the Social Sciences ver. 10.0, SPSS Inc, Chicago, Illinois, USA) computer software. Student's *t* test was used to compare age between the groups. Complications were analyzed using the  $\chi^2$  test. Parametric variables that did not exhibit normal distribution between groups were compared using the Mann-Whitney U test. Chi-square and Fisher's exact tests were used to compare categorical variables. For all statistical analyses,  $p < 0.05$  was considered significant.

#### RESULTS

In this study, 71 patients with recurrent pilonidal disease were enrolled, of whom 37 were treated using the standard Limberg flap procedure and 34 were treated using the Karydakis flap procedure (Table 1). The two groups did not differ in age or body mass index. Similarly, the two groups did not differ significantly in terms of sinus pit location or the presence of single or multiple pits ( $p > 0.05$ ). The operative time was longer in the LF group. Hospitalization time was also significantly higher in the LF group than in the KF group. Most patients in the LF group were mobilized on the first postoperative day, and the median time to first mobilization was earlier in the LF group than in KF group [1 (1-1) vs. 2 (1-3) days, respectively;  $p < 0.001$ ]. The median duration of incapacity for work was 17 (14-20) days in KF group and 8 (6-12) days in the LF group ( $p < 0.001$ ) (Table 2). In KF group, eight patients had infection and four had seroma. Total wound dehiscence and flap necrosis did not occur in any patient. Seven patients had seroma with negative culture in all studied patients. Flap edema occurred in four patients in the LF group. Wound infection



**Table 1** - Clinical comparison, operative characteristics and complications between groups.

Variable	Limberg Flap	Karydakís Flap	p-value
Gender (M/F)	32/5	32/2	0.650
Age (years)	25	23.5	0.21
Location			
Midline single	18	22	0.55
Midline multiple	14	10	
Hirsute Nature	24	22	0.831
History of Smoking	14	12	0.54
Duration of preoperative complaints (months)	14.32 ± 10.12	12.66 ± 4.43	0.08
Length of hospital stay (days)	1.44 (1-3)	3 (3-6)	0.001
Obesity			
Overweight (BMI 25-29.9)	22	18	0.455
Obese (BMI 30-39.9)	13	14	
Morbidly obese (BMI ≥ 40)	3	2	
Follow up (months)	28.2 ± 7.65	27.6 ± 8.32	0.750
Fluid collection	3	4	0.82
Wound infection	4	8	0.001
Flap edema	4	1	0.017
Hematoma	8	3	0.004
Partial wound dehiscence	1	2	0.590
Recurrence	0	0	

**Table 2** - Operative and postoperative outcomes.

Variable	Limberg Flap group	Karydakís Flap group	p-value
Duration of operation (min)	54 (50-70)	48 (40-60)	0.001
Time to first mobilization (days)	1 (1-1)	2 (1-3)	<0.001
Duration of incapacity for work	8 (6-12)	17 (14-20)	<0.001
Pain VAS score	2 (1-3)	4 (2-6)	<0.001
Complete healing time (days)	22.12 ± 8.69	24.08 ± 6.59	0.017
Painless toilet seating (days)	1 (1-2)	2 (1-3)	0.001
Patient satisfaction	2.88 ± 0.16	1.43 ± 0.44	<0.001

occurred in four patients in the LF group (Table 1). The mean time for complete healing of the wound after rhomboid excision and Limberg flap was 22.12 ± 8.69 days. The median VAS pain score was significantly lower in the LF group ( $p < 0.001$ ). No recurrence occurred in any of the patients during the follow-up period. When patient satisfaction was compared, the LF group received 2.88 ± 0.16 points and KF group received 1.43 ± 0.44; the patients in the LF group were more satisfied in terms of aesthetics ( $p < 0.001$ ).

## DISCUSSION

Pilonidal sinus was first described by Anderson in 1847 and is often seen in the intergluteal region. This chronic disease is characterized by acute exacerbations (1-3,9). PS usually occurs in healthy young men (Male/Female = 4-5/1), has a negative cosmetic appearance, and can cause loss of worktime (2-4). Gurer et al. (14) reported a mean patient age of 25.5 and a gender balance of 95% males in a series detailing the Karydakís flap procedure. In our series, the mean age was 24, and more than 95% of the patients were male.

The etiology and pathogenesis of PS is frequently associated with both congenital and acquired factors. It has been suggested that PS starts as a chronic process involving the accumulation of lifeless hairs and subcutaneous hair deposition in the intergluteal region that leads to inflammation and infection (3-5).

Several treatment procedures have been described in the literature, ranging from simple incision and drainage to the use of complex plastic flaps for cleft obliteration. The ideal technique for the treatment of sacrococcygeal PS disease is controversial (2,5). Medical treatment methods include alcohol, phenol and silver nitrate injection into the cavity. Surgical treatment methods include curettage after fistulotomy, leaving an open or marsupialized wound after cystectomy, Bascom surgery, primary excision and closure, the Karydakís flap procedure (KF), or sinus excision and skin graft and flap methods, such as Limberg flap rotation (LF). Surgical treatment is often preferred (8,11).

Ideally, the goals of treatment for this disease should be reliable wound healing with a low risk of recurrence, a short period of hospitalization, minimal inconvenience to the patient, and low morbidity with few wound-management problems (6,8,21).

Recurrence is the main problem in the treatment of pilonidal sinus. In 1970, Foss (26) reported a collective series of 1,129 pilonidal sinus patients treated with excision and primary closure by different investigators. The failure rate of primary healing was 16%, the length of hospitalization averaged 21.7 days, and the recurrence rate was 16%. Several flap techniques have been described with recurrence rates ranging between zero and 6-8% (6-8,10-13).

The Karydakís flap procedure was first described by George Karydakís (8) in 1973 and has frequently been used to treat sacrococcygeal PS. The KF achieves symmetric closure of the pilonidal wounds by avoiding placement of



the wound in the midline at the depth of the natal cleft and also flattens the cleft, thereby reducing hair accumulation and mechanical irritation and decreasing recurrence (8,9,30).

Karydakís (8) reported a recurrence rate of 1%, a complication rate of 8%, and a length of hospital stay of 3 days. Can et al. (15) reported a recurrence rate of 4.6% and a complication rate of 8.9%, and Sakr et al. (16) determined recurrence rates of 2.4% and a complication rate of 10% in their KF series. In a similar study, Sözen et al. (17) reported a recurrence rate of 1.5% and a complication rate of 6%. In our series, no recurrence was observed in either group. In the KF group, the complication rate was 10%, and the mean duration of hospital stay was 3 days.

Wound infection, fluid collection, edema, hematoma and wound separation can occur after use of the Karydakís flap procedure and other surgical techniques. The use of drains after surgery can be used to prevent fluid accumulation, edema and hematoma formation in such cases (14,17). Gurer et al. (14) reported that fluid accumulation is reduced after the routine use of post-operative drains. Bessa (18) determined that the percentage of cases with fluid retention after drain placement was 2.4%. In our KF group, 5.6% of patients experienced fluid collection, 11% experienced wound infection, and 1.4% experienced hematoma. In contrast, in the LF group, 4.2% of patients experienced fluid collection, 5.6% experienced wound infection, and 11% experienced hematoma.

The LF and KF procedures not only cover the wound but also, in theory, flatten the natal cleft and decrease hair accumulation, mechanical irritation and the risk of recurrence (2,11).

Limberg flap rotation is clearly preferred for safety reasons given its low recurrence and complication rates (19). In patients with recurrence and multiple sinuses, lateral flap rotations are implemented by removing the midline (6,19).

Mentes et al. (20), Ersoy et al. (21), and Campbell et al. (22) reported that modified Limberg flaps presented lower recurrence and complication rates than KF in their respective series. The reported recurrence rate for Limberg flap varies from 0.8 to 2.7% (21). Topgul et al. (27) operated on 200 patients, and the recurrence rate was found to be 2.5%. Daphan et al. (28) operated on 147 patients with a median follow-up time of 13.1 months, and recurrence was noted in 4.8% of patients.

Ertan et al. (23) reported that a Limberg flap recurrence rate of 2% compared to 12% in a primary closure group. Conversely, Ateş et al. (24) reported lower recurrence and complication rates for the KF technique than for the LF technique. The mean duration of hospital discharge after Limberg flap procedure reported by Urhan et al. (6) was 3.7 days, and Kapan et al. (19) reported a duration of 5.3 days.

In our study, recurrence was not observed in either group; in addition, time to discharge from hospital and complication rates were similar to values reported in the literature. The Limberg flap group had lower mean time to hospital discharge (LF/KF=3/1, 4 days) ( $p=0.001$ ) and lower wound infection rates ( $p=0.001$ ) than the KF group. In addition, comparison of the two groups showed a difference in terms of flap edema and hematoma ( $p=0.017$  and  $p=0.004$ , respectively).

A Cochrane overview has been performed to provide evidence-based guidance for surgical treatment (3). The review concluded that off-midline closure (including rhomboid, Karydakís and Bascom flaps) is the best choice if the

sinus is to be excised and sutured, and this closure is associated with shorter hospital stay and the lowest recurrence rates (29).

Other important points in the treatment of pilonidal sinus surgery are return to daily activities and work, postoperative pain score (VAS), duration of operation, time sitting on the toilet, and patient aesthetic satisfaction. In patients with recurrence and large defects, undergoing flap procedures can reduce aesthetic satisfaction. Akinci et al. (4) reported that return to daily activities after the Karydakís flap procedure was 12.4 to 20 days and that postoperative patient satisfaction was high.

Can et al. (15) reported 70% patient satisfaction after the Karydakís flap procedure, and a recent study reported satisfaction as high as 91%. Can et al. (15) and Ersoy et al. (21) determined that patients undergoing the Karydakís flap procedure and LF experience similar durations of hospital stay and return to work times. Karaca et al. (25) reported that the Limberg Flap group provided better postoperative pain score (visual analogue scale: VAS), complication rate, time to discontinuation of analgesics, and painless sitting than the KF group, and Ersoy et al. (21) found similar results. Can et al. (15) showed that mean operation time for the Karydakís flap procedure was  $49 \pm 7$  minutes, compared with  $52 \pm 5$  minutes for the Limberg flap procedure. In our study, the LF group exhibited a lower VAS score (2/4), higher patient satisfaction (2.8/1.43), earlier first mobilization (1/2 days) and more painless toilet sitting. (1/2 day). These patients also had shorter complete healing time (22/24 day) than the KF group ( $p \leq 0.001$ ). On the other hand, the KF group had a shorter operation time than the LF group (48 and 54 minutes, respectively) ( $p=0.001$ ).

The Limberg flap procedure is a safe choice for the surgical treatment of sacrococcygeal recurrent pilonidal sinus disease due to its low complication rate, short length of hospital stay, early return work, low VAS score, high patient satisfaction and shorter complete healing duration. Therefore, we recommend the Limberg flap procedure for the treatment of recurrent pilonidal sinus disease.

## AUTHOR CONTRIBUTIONS

Bali İ participated in the project design and execution, experimental practical work, data collection, transcription and coordination. Aziret M participated in the project design and execution, experimental practical work and data collection. Sözen S and Çetinkünar S participated in the project design, execution and experimental work. Emir S and Erdem H collected the data and performed the statistical analysis. İrkörücü O participated in the project design and data collection.

## REFERENCES

1. Petersen S, Aumann, Kramer A, Doll D, Sailer M, Hellmich G. Short-term results of Karydakís flap for pilonidal sinus disease. *Tech Coloproctol.* 2007;11(3):235-40, <http://dx.doi.org/10.1007/s10151-007-0357-7>.
2. Sondanaa K, Andersen E, Nesvik I, Søreide JA. Patient characteristics and symptoms in chronic pilonidal sinus disease. *Int J Colorectal Dis.* 1995; 10(1):39-42, <http://dx.doi.org/10.1007/BF00337585>.
3. McCallum IJ, King PM, Bruce J. Healing by primary closure versus open healing after surgery for pilonidal sinus: systematic review and meta-analysis. *BMJ.* 2008;336(7649):868-71, <http://dx.doi.org/10.1136/bmj.39517.808160.BE>.
4. Akinci O F, Kurt M, Terzi A, Atak I, Subasi IE, Akbilgic O. Natal Cleft Deeper in Patients with Pilonidal Sinus: Implications for Choice of Surgical Procedure. *Dis Colon Rectum.* 2009;52(5):1000-2, <http://dx.doi.org/10.1007/DCR.0b013e31819f6189>.
5. Kosaka M, Kida M, Mori M, Kamiishi H. Pilonidal cyst of the scalp due to single minor trauma. *Dermatol Surg.* 2007;33(4):505-7.



6. Urhan MK, Kücükel F, Topgul K, Ozer I, Sari S. Rhomboid excision and Limberg flap for managing pilonidal sinus: results of 102 cases. *Dis Colon Rectum* 2002;45(5):656-9, <http://dx.doi.org/10.1007/s10350-004-6263-4>.
7. Yildiz M K, Ozkan E, Odaba M, Kaya B, Eriş C, Abuolu HH, et al. Karydakís Flap Procedure in Patients with Sacrococcygeal Pilonidal Sinus Disease: Experience of a Single Centre in Istanbul. *ScientificWorldJournal*. 2013;807027.
8. Karydakís GE. Easy and successful treatment of pilonidal sinus after explanation of its causative process. *Aust N Z J Surg*. 1992;62(5):385-9, <http://dx.doi.org/10.1111/ans.1992.62.issue-5>.
9. Anderson AW. Hair extracted from an ulcer. *Boston Med Surg J*. 1847;36:76.
10. Spychala A, Murawa D. The limberg flap procedure in the treatment of pilonidal cyst disease of the sacrum - initial report. *Pol Przegł Chir*. 2014;86(6):257-62.
11. Bascom J. Surgical treatment of pilonidal disease. *BMJ*. 2008;336(7649):842-3, <http://dx.doi.org/10.1136/bmj.39535.397292.BE>.
12. Sozen S, Emir S, Guzel K, and Ozdemir CS. "Are postoperative drains necessary with the Karydakís flap for treatment of pilonidal sinus? (Can fibrin glue be replaced to drains?) A prospective randomized trial. *Ir J Med Sci*. 2011;180(2):479-82, <http://dx.doi.org/10.1007/s11845-010-0549-4>.
13. Sit M, Aktas G, Yilmaz EE. Comparison of the three surgical flap techniques in pilonidal sinus surgery. *Am Surg*. 2013;79(12):1263-8.
14. Gurer A, Gomceli I, Ozdogan M, Ozlem N, Sozen S, Aydin R. "Is routine cavity drainage necessary in Karydakís flap operation? A prospective, randomized trial. *Dis Colon Rectum*. 2005;48(9):1797-9, <http://dx.doi.org/10.1007/s10350-005-0108-7>.
15. Can MF, Sevinc MM, Yilmaz M. Comparison of Karydakís flap reconstruction versus primary midline closure in sacrococcygeal pilonidal disease: results of 200 military service members. *Surg Today*. 2009;39(7):580-6, <http://dx.doi.org/10.1007/s00595-008-3926-0>.
16. Sakr M, El-Hammadi H, Moussa M, Arafa S, Rasheed M. The effect of obesity on the results of Karydakís technique for the management of chronic pilonidal sinus. *Int J Colorectal Dis*. 2003;18(1):36-9, <http://dx.doi.org/10.1007/s00384-002-0407-6>.
17. Sozen S, Topuz O, Donder Y, Emir S, Özdemir CŞ, Keçeli M, et al. Comparison between Karydakís flap repair and Limberg flap for surgical treatment of sacrococcygeal pilonidal sinus (short term results). *Turk J Surg*. 2010;26(3):153-6, <http://dx.doi.org/10.5097/1300-0705.UCD.609-10.01>.
18. Bessa SS. Results of the lateral advancing flap operation (modified Karydakís procedure) for the management of pilonidal sinus disease. *Dis Colon Rectum*. 2007;50(11):1935-40, <http://dx.doi.org/10.1007/s10350-007-9049-7>.
19. Kapan M, Kapan S, Pekmezci S, Durgun V. Sacrococcygeal pilonidal sinus disease with Limberg flap repair. *Tech Coloproctol*. 2002;6(1):27-32, <http://dx.doi.org/10.1007/s101510200005>.
20. Mentés BB, Leventoglu S, Cihan A, Tatlicioglu E, Akin M, Oguz M. Modified Limberg transposition flap for sacrococcygeal pilonidal sinus. *Surg Today*. 2004;34(5):419-23, <http://dx.doi.org/10.1007/s00595-003-2725-x>.
21. Ersoy E, Devay AO, Aktimur R, Doganay B, Ozdo an M, Gündo du RH. Comparison of the short-term results after Limberg and Karydakís procedures for pilonidal disease: randomized prospective analysis of 100 patients. *Colorectal Dis*. 2009;11(7):705-10, <http://dx.doi.org/10.1111/cdi.2009.11.issue-7>.
22. Can MF, Sevinc MM, Hancerliogullari O, Yilmaz M, Yagci G. Multicenter prospective randomized trial comparing modified Limberg flap transposition and Karydakís flap reconstruction in patients with sacrococcygeal pilonidal disease. *Am J Surg*. 2010;200(3):318-27, <http://dx.doi.org/10.1016/j.amjsurg.2009.08.042>.
23. Ertan T, Koc M, Goemen E, Aslar AK, Keskek M, Kilic M. Does technique alter quality of life after pilonidal sinus surgery? *Am J Surg*. 2005;190(3):388-92, <http://dx.doi.org/10.1016/j.amjsurg.2004.08.068>.
24. Ates M, Dirican A, Sarac M, Aslan A, Colak C. Short and long-term results of the Karydakís flap versus the Limberg flap for treating pilonidal sinus disease: a prospective randomized study. *Am J Surg*. 2011;202(5):568-73, <http://dx.doi.org/10.1016/j.amjsurg.2010.10.021>.
25. Karaca T, Yoldaş O, Bilgin BC, Ozer S, Yoldaş S, Karaca NG. Comparison of short-term results of modified Karydakís flap and modified Limberg flap for pilonidal sinus surgery. *Int S Surg*. 2012;10(10):601-6, <http://dx.doi.org/10.1016/j.ijssu.2012.10.001>.
26. Foss MV. Pilonidal sinus excision and closure. *Proc R Soc Med*. 1970;63(8):752-8.
27. Topgul K, Ozdemir E, Kilic K, Gokbayir H, Ferahkose Z. Long-term results of limberg flap procedure for treatment of pilonidal sinus: A report of 200 cases. *Dis Colon Rectum*. 2003;46(11):1545-8, <http://dx.doi.org/10.1007/s10350-004-6811-y>.
28. Daphan C, Tekelioglu MH, Sayilgan C. Limberg flap repair for pilonidal sinus disease. *Dis Colon Rectum*. 2004;47(2):233-7, <http://dx.doi.org/10.1007/s10350-003-0037-2>.
29. Petersen S, Koch R, Stelzner S, Wendlandt TP, Ludwig K. Primary closure techniques in chronic pilonidal sinus: a survey of the - results of different surgical approaches. *Dis Colon Rectum* 2002;45(11):1458-67, <http://dx.doi.org/10.1007/s10350-004-6451-2>.
30. Varnalidis I, Ioannidis O, Paraskevas G, Papapostolou D, Malakozis SG, Gatzos S, et al. Pilonidal sinus: a comparative study of treatment methods. *J Med Life*. 2014;7(1):27-30.