

Dental anomalies in children submitted to antineoplastic therapy

Camila Merida Carrillo,^I Fernanda Nahás Pires Corrêa,^{II} Nilza Nelly Fontana Lopes,^{III} Marcelo Fava,^{I,IV} Vicente Odone Filho^V

^IHospital das Clínicas da Faculdade de Medicina da Universidade de São Paulo, Instituto da Criança ITACI, Hemato-oncology Service, Dentistry Department, São Paulo/SP, Brazil. ^{II}São Leopoldo Mandic Campinas, School of Dentistry, Campinas/SP, Brazil. ^{III}Universidade Federal de São Paulo (UNIFESP), School of Medicine, Pediatric Oncology Institute, GRAACC-IOP, Department of Dentistry, São Paulo/SP, Brazil. ^{IV}Universidade Estadual Paulista "Júlio de Mesquita Filho" (UNESP), Instituto de Ciência e Tecnologia (<http://www.fosjc.unesp.br/>), São José dos Campos/SP, Brazil. ^VFaculdade de Medicina da Universidade de São Paulo, Department of Pediatric, São Paulo/SP, Brazil.

Cancer is the third most frequent cause of death in children in Brazil. Early diagnosis and medical advances have significantly improved treatment outcomes, which has resulted in higher survival rates and the management of late side effects has become increasingly important in caring for these patients. Dental abnormalities are commonly observed as late effects of antineoplastic therapy in the oral cavity. The incidence and severity of the dental abnormalities depend on the child's age at diagnosis and the type of chemotherapeutic agent used, as well as the irradiation dose and area. The treatment duration and aggressivity should also be considered. Disturbances in dental development are characterized by changes in shape, number and root development. Enamel anomalies, such as discoloration, opacities and hypoplasia are also observed in these patients. When severe, these abnormalities can cause functional and esthetic sequelae that have an impact on the children's and adolescents' quality of life. General dentists and pediatric dentists should understand these dental abnormalities and how to identify them aiming for early diagnosis and appropriate treatment.

KEYWORDS: Tooth Abnormalities; Drug/Radiotherapy; Cancer; Child.

Carrillo CM, Corrêa FN, Lopes NN, Fava M, Filho VO. Dental anomalies in children submitted to antineoplastic therapy. *Clinics*. 2014;69(6):433-437.

Received for publication on November 6, 2013; Accepted for publication on November 26, 2013

E-mail: marcelo.fava@uol.com.br

Tel.: 55 11 2661-8880

INTRODUCTION

Cancer is the third most frequent cause of death in children in Brazil, after accidents and violence (1). The survival rates of childhood cancer have significantly increased due to early diagnosis and advances in medicine, so attention has become focused on the late effects of antineoplastic therapy.

Dental anomalies are among the most common long-term side effects of childhood cancer therapy in the oral cavity. They may lead to anatomic, functional and aesthetic sequelae, and severe abnormalities can cause malocclusion, affect facial development and impact the quality of life (2).

The incidence and severity of dental abnormalities depend on the age at the diagnosis and the type of chemotherapeutic agent used, as well as the irradiation dose and area (3,4). The duration and severity of antineoplastic treatment should also be considered. Dental

development disturbances are characterized by changes in shape, size, number and root development.

General dentists and pediatric dentists provide oral care to childhood cancer survivors. Therefore, it is imperative that they familiarize themselves with the adverse effects of cancer therapy.

Epidemiology of childhood cancer

More than 9,000 new childhood cancers are diagnosed annually in Brazil. Cancer is the third leading cause of death in the 1- to 19-year-old age group, behind accidents and violence.

Childhood cancer requires special care for not only the psychological and social effects but also because of the high costs involved in diagnosis, treatment and long-term follow-up (5). The types of cancers that affect children younger than 15 years old are distinct from those that affect adults. The most prevalent childhood cancers are leukemias, lymphomas, central nervous system tumors, rhabdomyosarcoma, Wilms' tumor, retinoblastoma and bone tumors; while in adults, lung, stomach, intestine, prostate and breast cancer predominate (6). The literature reports that during childhood, acute lymphocytic leukemia (ALL) is the most common malignancy, representing 24% of all childhood malignant neoplasias (7-9) and 75% of all childhood leukemias (10). The 0- to 4-year-old age group is cited as

Copyright © 2014 CLINICS – This is an Open Access article distributed under the terms of the Creative Commons Attribution Non-Commercial License (<http://creativecommons.org/licenses/by-nc/3.0/>) which permits unrestricted non-commercial use, distribution, and reproduction in any medium, provided the original work is properly cited.

No potential conflict of interest was reported.

DOI: 10.6061/clinics/2014/06/11



the age group most frequently affected by cancers; however, lymphomas, carcinomas and bone tumors are the most prevalent cancers in the 10-14-year-old age group (11,12). In Brazil, leukemia predominates in the 1- to 4-year-old age group (31.6%); lymphoma is dominant in the 15- to 18-year-old age group (35.6%), and central nervous system tumors have a similar prevalence (26%) in all patients younger than 14 years old (1 to 4, 5 to 9, and 10 to 14 years old)(1). With regard to gender, related studies agree that general tumors, leukemias, lymphomas and central nervous system tumors are more prevalent in males than in females (5).

Late effects of childhood cancer therapy

With the increasing number of childhood cancer survivors comes a high incidence of adverse effects because of more aggressive treatments protocols. Therefore, increasing focus has been directed toward the late sequelae of treatment modalities.

The combination of surgery, chemotherapy and radiotherapy is extremely effective not only in prolonging life but also in obtaining significant cure rates in many types of childhood cancer (13). In Brazil, the survival rates range from 70 to 80% in some types of childhood cancer, such as ALL (1).According to Dickerman (2007)(14), the number of long-term survivors of childhood cancer continues to increase and approximately 75% will have a chronic health problem resulting from the cancer therapy, whereas 40% will experience a severe, disabling, or life-threatening condition or death caused by a chronic condition.

A variety of late effects of childhood cancer therapy can be noted as malignant late effects (secondary cancer) and

nonmalignant late effects, in which many organs can be affected, including the oral cavity (13,14)(Table 1).

Late effects of treatment in the oral cavity

Complications resulting from the cancer itself and from its treatment frequently affect the mouth. Chemotherapy and head and neck radiotherapy mainly affect developing tissues, such as teeth and oral soft tissues (15). Generally, many therapeutic modalities are used to treat childhood cancer. Chemotherapy and radiotherapy are often combined, making it difficult to later distinguish which treatment modality causes which effects (16). Oral late effects of cancer therapy are clinically significant because of the sequelae they can cause, which may interfere with the quality of life. The most commonly observed late effects of head and neck radiotherapy therapy include xerostomia, trismus, bone alterations that can cause osteoradionecrosis and craniofacial and dental anomalies (17-19). Dental anomalies are also caused by chemotherapy; the main late effects of this therapy are in the mouth (3,16,20).

Dental anomalies in children submitted to antineoplastic therapy

Antineoplastic therapy can cause disturbances in tooth eruption and development. The exact molecular mechanisms of antineoplastic therapy that result in dental anomalies remain unknown (21,22).

The lack of specificity of both chemotherapeutic agents and radiation therapy in terms of differentiating neoplastic cells from metabolically active normal cells might result in dental and facial development abnormalities (3). The

Table 1 - Prevalence of dental anomalies in childhood cancer survivors.

Authors	N	Diagnosis	Gender F M	Mean age	Dental anomalies					
					Hypoplasia	Microdontia	Hypodontia	Taurodontia	Tapered roots	Blunted roots
Rosenberg et al. 1987	17	ALL	--	7.2	-	-	-	-	13 76%	5 29%
Pajari et al. 1988	34	Various tumors	19 18	5.7	32 94%	-	-	-	-	-
Dahllof et al. 1988	16	BMT	7 9	7.1	4 25%	3 19%	-	-	14 88%	5 31%
Sonis et al. 1990	97	ALL	61 36	-	27 28%	21 22%	5 5%	-	85 88%	60 62%
Nunn et al. 1991	52	ALL+lympho-ma	30 22	6.7	14 27%	14 27%	8 15%	14 27%	14 27%	14 27%
Pajari et al. 1995	45	ALL	25 20	5.4	40 95%	-	-	-	-	-
Kaste et al. 1995	22	Rhabdomyo-sarcoma	12 10	5.1	-	5 23%	11 50%	-	-	13 59%
Kaste et al. 1997	426	ALL	204 259	4.8	-	80 19%	36 9%	25 6%	-	103 24%
Nasmann et al. 1997	16	BMT+TBI	9 7	6.3	7 44%	12 75%	9 56%	-	15 94%	11 69%
	52	BMT no TBI	23 29	5.1	7 13%	7 13%	11 21%	-	10 19%	4 8%
Kaste et al. 1998	52	Neuroblastoma	9 33	0.0	9 17%	20 38%	9 17%	-	-	9 17%
Aspalan et al. 1999	30	Lymphoma	7 23	-	14 47%	-	15 50%	-	9 30%	2 7%
Minicucci et al. 2003	76	ALL	33 43	5.1	25 39%	28 44%	-	-	-	-
Lopes et al. 2006	137	Various tumors	79 58	5.6	-	9 7%	8 6%	19 14%	2 2%	5 4%



severity of these effects on dentofacial structures was found to be related to the stage of tooth histogenesis, age at diagnosis, type of treatment performed and irradiation dose area (3,21). Studies (3,4,16,23-26) have shown a direct relationship between the severity and prevalence of dental anomalies and age at diagnosis, which is related to odontogenesis stage. Children treated before 5 years of age had the most severe dental defects, suggesting that immature teeth were at greater risk for developmental disturbances than mature teeth (3). With the increased life expectancy of patients younger than 5 years old, it is important to study late dental effects in children who undergo cancer treatment at such an early age (16). Radiotherapy can cause disturbances in dental development in children; however, the minimal radiation dose necessary to cause changes in dental development is unknown. According to Carpenter (27) and Dury (28), 1,000 cGy is sufficient to cause permanent damage to mature ameloblasts and 3,000 cGy is sufficient to arrest dental development. However, Fromm et al. (29) and Goho (2) identified alterations in dental development after 400 cGy dose.

Many authors (16,23,24,30) have reported a higher prevalence of (and more severe) dental anomalies in children submitted to head and neck radiotherapy and total body irradiation combined with chemotherapy compared to children submitted to only chemotherapy. Raney et al. (31) and Paulino et al. (32) reported that 75-100% of patients submitted to radiotherapy presented light to mild hard and soft tissue damage resulting from irradiation.

The extent and severity of the defects is related to the radiation type and dose, the age of the patient, irradiation area, degree of tissue hypovascularity and hypocellularity, reparative capacity of epithelial cells and associated chemotherapy (31,33-35). Animal studies (36,37) have shown dental development disturbances induced by vincristine, vinblastine, doxorubicin and cyclophosphamide. The extent of dental abnormalities attributed to chemotherapy depends on many factors, such as the type of chemotherapeutic agent used, half-life of the drug and number of cells in susceptible phases of the cell cycle (37). In addition, the combination of several agents in chemotherapy protocols, often combined with radiation therapy, makes it difficult to attribute anomalies in odontogenesis

to any single agent or therapy in these cases and to determine how they interfere in cellular physiology (37).

Depending on the odontogenesis stage, certain types of anomalies can be observed (38). Therefore, detailed knowledge of tooth development by dental professionals is fundamental in interpreting the timing and nature of dental developmental anomalies and consequently correlating them to the age at which the event occurred. In patients submitted to antineoplastic therapy, this correlation is easily observed, reinforcing the premise that dental development represents a real biological milestone in health and illness as well as in the relationship between the mouth and many diseases and their manifestations and treatments.

Antineoplastic therapies that affect the cells involved in odontogenesis may cause changes in tooth enamel and root development, premature apex closure, dental development delay or retained teeth (3,16,21,24,26). Dental anomalies of shape (microdontia, macrodontia and taurodontia) and number (hypodontia), enamel defects (discolorations and hypoplasia) and root formation disturbances (blunted root, tapered root and root development delay) have been described in many studies (3,16,24,26,39). Other anomalies, such as supernumerary teeth, have also been detected (24,26). Developmental defects of the enamel organ are well documented in the scientific literature. Enamel hypoplasias and discolorations are the most frequent dental defects from cytotoxic drugs (29,30,37,40). Children treated for ALL seem to be more severely affected and this result may be reflected in the longer duration of therapy, which leads to a greater risk of affecting the developing ameloblasts (24,41,42). Disturbances in dental morphology induced by high-dose chemotherapy and total body irradiation in patients have been shown in many histologic studies. These studies have also shown that radiation therapy induces both quantitative and qualitative changes in enamel and dentin during tooth formation, whereas chemotherapy induces mostly qualitative disturbances (24,42). Microdontia is frequently detected in long-term childhood cancer survivors. Several studies have reported a prevalence of microdontia ranging from 22-78% in this population (3,43,44). Clinically, hypodontia and microdontia have great importance because they can cause spacing and movement of teeth, resulting in poor dental

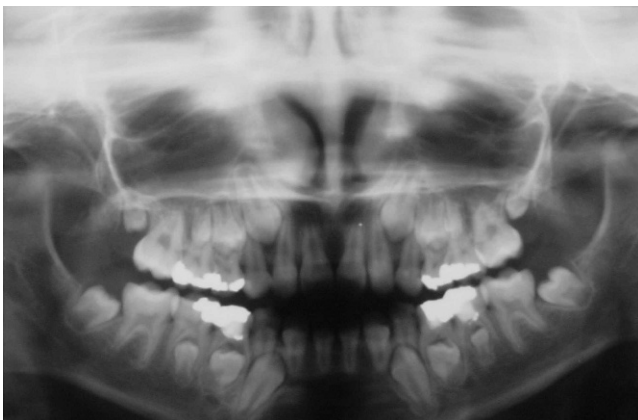


Figure 1 - Panoramic radiograph of a 2-year-old patient at diagnosis who was submitted to chemotherapy and 1,800 cGy irradiation. Note microdontia of the lower left premolars and second permanent molar.

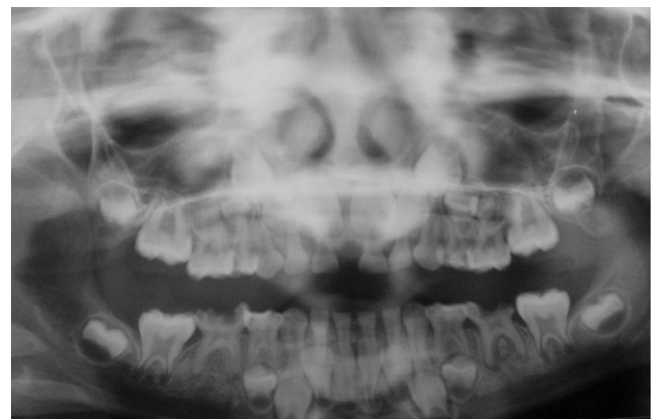

Figure 2 - Panoramic radiograph of a 7-year-old patient at diagnosis who was submitted to chemotherapy and 2,100 cGy irradiation. Note agenesi of the lower right second premolar, taurodontism of the first permanent molars and microdontia of the upper and lower left premolars.

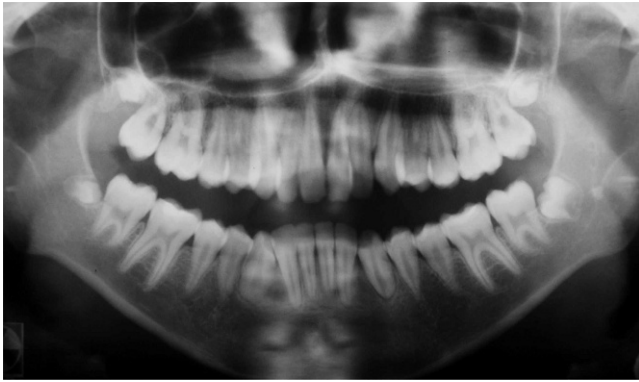


Figure 3 - Panoramic radiograph of a 6-year-old patient at diagnosis who was submitted to chemotherapy and 6,750 cGy irradiation. Note blunted and shortened V-shaped roots of the upper and lower premolars and second molars.

alignment and malocclusion (45) (Figure 1). Intensive and repetitive chemotherapy during initial hard tissue formation can cause hypodontia (39,42), which consists of the absence of one or more teeth. It is caused by disturbances in the first periods of the tooth vital cycle because of the failure of the dental lamina and tooth bud development processes or because of impairment of the cellular multiplication that promotes the development of these buds (proliferation stage)(38).

For antineoplastic therapy to result in dental agenesis, it must destroy the cells programmed to form a tooth or to affect the signaling systems between the tissues in a tooth bud and prevent calcification (43). Some studies have reported a prevalence of hypodontia associated with anticancer therapy ranging from 6 to 44% (16,23,25,44). The effects of cancer treatment in the later stages of tooth formation are characterized by disturbed root development (43). The first signs of root development in permanent teeth are observed on panoramic radiographs beginning approximately at age 3 years (central incisors and permanent first molars) to age 7.5 years (permanent second molars) (43) and root formation is completed after the tooth has erupted into the oral cavity (46). Changes in odontoblast activity caused by abnormal secretory functioning of the dentin microtubules and complex changes in inter- and intracellular relationships can produce shortened, tapered and blunted roots (42) (Figure 3).

Root development disturbances, such as arrested root development with short V-shaped roots, arrested root development with premature apical closure, blunted roots and anomalies in root number have been reported in patients treated with high-dose chemotherapy and radiotherapy (3). Repeated high-dose chemotherapy can result in root agenesis (42).

Another dental anomaly that is frequently detected in these patients is taurodontia (Figure 2), which is characterized by an enlarged pulp chamber, apical displacement of the pulpal floor and no constriction at the level of the cemento-enamel junction (47), which is caused by the failure of Hertwig's epithelial sheath diaphragm to invaginate at the proper horizontal level (48). This abnormality usually affects permanent molar teeth, but it can also be observed in premolars and primary molar teeth and can become a challenge when endodontic treatment is needed, particularly because of its anatomy (45). In the dental literature, its

prevalence in children treated for childhood cancer varies from 6% to 26% (16,45,46).

Many studies have shown differences in the prevalence of dental anomalies in long-term survivors of childhood cancer, most likely because of the type of tumor studied, the chemotherapy protocol used and the age of the study population, as well as associated body and/or head and neck irradiation and different assessment methodologies.

Unfortunately, few studies in the scientific literature that have described the prevalence of dental anomalies in healthy children in the Brazilian population. These studies are essential as a comparative measure not only for children submitted to antineoplastic therapy but also for children who present other chronic diseases that affect dental development. However, several studies have demonstrated a high prevalence of dental anomalies in children submitted to cancer therapy compared to healthy children (16,23-26,45,49).

Children submitted to antineoplastic treatment present several late effects in many organs and systems, including the oral cavity; these effects are caused by anticancer treatments. Dental abnormalities are the most frequent sequelae of therapy for childhood cancer; these abnormalities include microdontia, hypodontia and enamel and root development disturbances. These abnormalities can cause malocclusion and affect facial development, consequently impacting quality of life. Children who are treated at young ages appear to be more severely affected than children who are treated later; additionally, radiotherapy seems to cause more extensive and severe dental defects compared to chemotherapy. Considering these factors, general and pediatric dentists should become familiarize themselves with these late effects, aiming for early diagnosis, proper dental care and, consequently, improved quality of life for this increasingly large group of children.

■ AUTHOR CONTRIBUTIONS

Carrillo CM was responsible for literature review and manuscript writing. Corrêa FN was responsible for the first manuscript revision. Lopes NN was responsible for the images and manuscript review. Fava M was responsible for literature review and manuscript evaluation. Odone Filho V was responsible for final revision.

■ REFERENCES

1. Instituto Nacional do Câncer- INCA. www.inca.gov.br. Acesso em maio/2011.
2. Goho C. Chemoradiation therapy: effect on dental development. *Pediatr Dent*. 1993;15(1):6-12.
3. Sonis AL, Tarbell N, Valachovic RW, Gelber R, Schwenn M, Sallan S. Dentofacial development in long-term survivors of acute lymphoblastic leukemia. A comparison of three treatment modalities. *Cancer*. 1990;66(12):2645-52. [http://dx.doi.org/10.1002/1097-0142\(19901215\)66:12<2645::AID-CNCR2820661230>3.0.CO;2-S](http://dx.doi.org/10.1002/1097-0142(19901215)66:12<2645::AID-CNCR2820661230>3.0.CO;2-S).
4. Minicucci EM, Lopes LF, Crocchi AJ. Dental abnormalities in children after chemotherapy treatment for acute lymphoid leukemia. *Leuk Res*. 2003;27(1):45-50. [http://dx.doi.org/10.1016/S0145-2126\(02\)00080-2](http://dx.doi.org/10.1016/S0145-2126(02)00080-2).
5. Mirra AP, Latorre MRO, Veneziano DB. Incidência, mortalidade e sobrevivência do câncer da infância no município de São Paulo, 2004. Registro de Câncer de São Paulo. Faculdade de Saúde Pública da Universidade de São Paulo.
6. Braga PE, Latorre MRDO, Curado MP. Câncer na Infância: Análise Comparativa da Incidência, Mortalidade e Sobrevida em Goiânia (Brasil) e outros países. *Cad. Saúde Pública*, Rio de Janeiro. 2002;8:33-44. <http://dx.doi.org/10.1590/S0102-311X2002000100004>.
7. Ministério da Saúde. Instituto Nacional de Câncer. Coordenação de Programas de Controle do Câncer. "O Problema do Câncer no Brasil", quarta edição revisada e atualizada. Rio de Janeiro, 1997.



8. Smith MA, Ries LAG. Childhood cancer: incidence, survival, and mortality. In: Pizzo PA, Poplack DG, ed. Philadelphia: Lippincott Williams & Wilkins; 2002:1-12.
9. Balis FM, Holcenberg JS, Blaney SM. General principles of chemotherapy. In: Pizzo PA, Poplack DG, ed. Philadelphia: Lippincott Williams & Wilkins; 2002:237-308.
10. Margolin JF, Steuber CP, Poplack DG. Acute lymphoblastic leukemia. In: Pizzo PA, Poplack DG, ed. Philadelphia: Lippincott Williams & Wilkins; 2002:489-544.
11. Mirra AP, Latorre MRO, Veneziano DB. Incidência, mortalidade e sobrevida do câncer da infância no município de São Paulo, 2004. Registro de Cancer de São Paulo. Faculdade de Saúde Pública da Universidade de São Paulo.
12. Hong CH, da Fonseca M. Considerations in the pediatric population with cancer. *Dent Clin North Am.* 2008;52(1):155-81, ix, <http://dx.doi.org/10.1016/j.cden.2007.10.001>.
13. Neglia JP, Nesbit ME Jr. Care and treatment of long-term survivors of childhood cancer. *Cancer.* 1993;71(10 Suppl):3386-91, [http://dx.doi.org/10.1002/1097-0142\(19930515\)71:10+<3386::AID-CNCR2820711742>3.0.CO;2-7](http://dx.doi.org/10.1002/1097-0142(19930515)71:10+<3386::AID-CNCR2820711742>3.0.CO;2-7).
14. Dickerman JD. The late effects of childhood cancer therapy. *Pediatrics.* 2007;119(3):554-68. Erratum in: *Pediatrics.* 2007;119(5):1045, <http://dx.doi.org/10.1542/peds.2006-2826>.
15. Ayers KM, Colquhoun AN. Leukaemia in children. Part II—Dental care of the leukaemic child, including management of oral side effects of cancer treatment. *N Z Dent J.* 2000;96(426):141-6.
16. Lopes NN, Petrilli AS, Caran EM, França CM, Chilvarquer I, Lederman H. Dental abnormalities in children submitted to antineoplastic therapy. *J Dent Child (Chic).* 2006;73(3):140-5.
17. Sonis ST, Fey EG. Oral complications of cancer therapy. *Oncology (Williston Park).* 2002;16(5):680-6; discussion 686, 691-2,695.
18. Otmani N. Oral and maxillofacial side effects of radiation therapy on children. *J Can Dent Assoc.* 2007;73(3):257-61.
19. Jones DL, Rankin KV. Management of the oral sequelae of cancer therapy. *Tex Dent J.* 2012;129(5):461-8.
20. Maguire A, Welbury RR. Long-term effects of antineoplastic chemotherapy and radiotherapy on dental development. *Dent Update.* 1996;23(5):188-94. Erratum in: *Dent Update* 1996;23(6):238.
21. Jaffe N, Toth BB, Hoar RE, Ried HL, Sullivan MP, McNeese MD. Dental and maxillofacial abnormalities in long-term survivors of childhood cancer: effects of treatment with chemotherapy and radiation to the head and neck. *Pediatrics.* 1984;73(6):816-23.
22. Zarina RS, Nik-Hussein NN. Dental abnormalities of a long-term survivor of a childhood hematological malignancy: literature review and report of a case. *J Clin Pediatr Dent.* 2005 Winter;29(2):167-74.
23. Kaste SC, Hopkins KP, Bowman LC, Santana VM. Dental abnormalities in children treated for neuroblastoma. *Med Pediatr Oncol.* 1998;30(1):22-7, [http://dx.doi.org/10.1002/\(SICI\)1096-911X\(199801\)30:1<22::AID-MPO8>3.0.CO;2-2](http://dx.doi.org/10.1002/(SICI)1096-911X(199801)30:1<22::AID-MPO8>3.0.CO;2-2).
24. Minicucci EM, Lopes LF, Crocci AJ. Dental abnormalities in children after chemotherapy treatment for acute lymphoid leukemia. *Leuk Res.* 2003;27(1):45-50, [http://dx.doi.org/10.1016/S0145-2126\(02\)00080-2](http://dx.doi.org/10.1016/S0145-2126(02)00080-2).
25. Oğuz A, Cetiner S, Karadeniz C, Alpaslan G, Alpaslan C, Pinarli G. Long-term effects of chemotherapy on orodental structures in children with non-Hodgkin's lymphoma. *Eur J Oral Sci.* 2004;112(1):8-11.
26. Maciel JC, de Castro CG Jr, Brunetto AL, Di Leone LP, da Silveira HE. Oral health and dental anomalies in patients treated for leukemia in childhood and adolescence. *Pediatr Blood Cancer.* 2009;53(3):361-5, <http://dx.doi.org/10.1002/psc.22108>.
27. Carpenter JS. Dental care for children who have received head and neck therapeutic radiation. *J Endod.* 1978;3(1):36-48.
28. Dury DC, Roberts MW, Miser JS, Folio J. Dental root agenesis secondary to irradiation therapy in a case of rhabdomyosarcoma of the middle ear. *Oral Surg Oral Med Oral Pathol.* 1984;57(6):595-9, [http://dx.doi.org/10.1016/0030-4220\(84\)90278-0](http://dx.doi.org/10.1016/0030-4220(84)90278-0).
29. Fromm M, Littman P, Raney RB, Nelson L, Handler S, Diamond G, et al. Late effects after treatment of twenty children with soft tissue sarcomas of the head and neck. Experience at a single institution with a review of the literature. *Cancer.* 1986;57(10):2070-6, [http://dx.doi.org/10.1002/1097-0142\(19860515\)57:10<2070::AID-CNCR2820571032>3.0.CO;2-G](http://dx.doi.org/10.1002/1097-0142(19860515)57:10<2070::AID-CNCR2820571032>3.0.CO;2-G).
30. Dahllöf G, Barr M, Bolme P, Modéer T, Lönnqvist B, Ringdén O, et al. Disturbances in dental development after total body irradiation in bone marrow transplant recipients. *Oral Surg Oral Med Oral Pathol.* 1988;65(1):41-4, [http://dx.doi.org/10.1016/0030-4220\(88\)90189-2](http://dx.doi.org/10.1016/0030-4220(88)90189-2).
31. Raney RB, Anderson JR, Kollath J, Vassilopoulou-Sellin R, Klein MJ, Heyn R, et al. Late effects of therapy in 94 patients with localized rhabdomyosarcoma of the orbit: Report from the Intergroup Rhabdomyosarcoma Study (IRS)-III, 1984-1991. *Med Pediatr Oncol.* 2000;34(6):413-20, [http://dx.doi.org/10.1002/\(SICI\)1096-911X\(200006\)34:6<413::AID-MPO6>3.0.CO;2-4](http://dx.doi.org/10.1002/(SICI)1096-911X(200006)34:6<413::AID-MPO6>3.0.CO;2-4).
32. Paulino AC, Simon JH, Zhen W, Wen BC. Long-term effects in children treated with radiotherapy for head and neck rhabdomyosarcoma. *Int J Radiat Oncol Biol Phys.* 2000;48(5):1489-95, [http://dx.doi.org/10.1016/S0360-3016\(00\)00799-9](http://dx.doi.org/10.1016/S0360-3016(00)00799-9).
33. Meadows AT, Silber J. Delayed consequences of therapy for childhood cancer. *CA Cancer J Clin.* 1985;35(5):271-86, <http://dx.doi.org/10.3322/canjclin.35.5.271>.
34. Dörr W, Hamilton CS, Boyd T, Reed B, Denham JW. Radiation-induced changes in cellularity and proliferation in human oral mucosa. *Int J Radiat Oncol Biol Phys.* 2002;52(4):911-7, [http://dx.doi.org/10.1016/S0360-3016\(01\)02721-3](http://dx.doi.org/10.1016/S0360-3016(01)02721-3).
35. Prott FJ, Handschel J, Micke O, Sunderkötter C, Meyer U, Piffko J. Long-term alterations of oral mucosa in radiotherapy patients. *Int J Radiat Oncol Biol Phys.* 2002;54(1):203-10, [http://dx.doi.org/10.1016/S0360-3016\(02\)02867-5](http://dx.doi.org/10.1016/S0360-3016(02)02867-5).
36. Näsman M, Hammarström L. Influence of the antineoplastic agent cyclophosphamide on dental development in rat molars. *Acta Odontol Scand.* 1996;54(5):287-94, <http://dx.doi.org/10.3109/00016359609003540>.
37. Nasman M, Forsberg CM, Dahllöf FG. Disturbances in dental development in long-term survivors after pediatric malignant diseases. *Eur J Orthod.* 1997;19(2):151-9.
38. Campos V, Cruz RA, Mello HSA. Diagnóstico e Tratamento das Anomalias Dentárias da Odontogênese. São Paulo: Santos, 2004.
39. Dahllöf G, Borgström B, Forsberg CM. The effect of growth hormone treatment in children treated with total body irradiation and bone marrow transplantation. *Acta Paediatr.* 1994;83(11):1165-9, <http://dx.doi.org/10.1111/j.1651-2227.1994.tb18274.x>.
40. Pajari U, Lanning M, Larmas M. Prevalence and location of enamel opacities in children after anti-neoplastic therapy. *Community Dent Oral Epidemiol.* 1988;16(4):222-6, <http://dx.doi.org/10.1111/j.1600-0528.1988.tb01759.x>.
41. Maguire A, Craft AW, Evans RG, Amineddine H, Kernahan J, Macleod RI, et al. The long-term effects of treatment on the dental condition of children surviving malignant disease. *Cancer.* 1987;60(10):2570-5, [http://dx.doi.org/10.1002/1097-0142\(19871115\)60:10<2570::AID-CNCR2820601037>3.0.CO;2-Q](http://dx.doi.org/10.1002/1097-0142(19871115)60:10<2570::AID-CNCR2820601037>3.0.CO;2-Q).
42. Dahllöf G, Rozell B, Forsberg CM, Borgström B. Histologic changes in dental morphology induced by high dose chemotherapy and total body irradiation. *Oral Surg Oral Med Oral Pathol.* 1994;77(1):56-60, [http://dx.doi.org/10.1016/S0030-4220\(06\)80107-6](http://dx.doi.org/10.1016/S0030-4220(06)80107-6).
43. Hölttä P, Alaluusua S, Saarinen-Pihkala UM, Wolf J, Nyström M, Hovi L. Long-term adverse effects on dentition in children with poor-risk neuroblastoma treated with high-dose chemotherapy and autologous stem cell transplantation with or without total body irradiation. *Bone Marrow Transplant.* 2002;29(2):121-7, <http://dx.doi.org/10.1038/sj.bmt.1703330>.
44. Hölttä P, Alaluusua S, Saarinen-Pihkala UM, Peltola J, Hovi L. Agenesis and microdontia of permanent teeth as late adverse effects after stem cell transplantation in young children. *Cancer.* 2005;103(1):181-90, <http://dx.doi.org/10.1002/cncr.20762>.
45. Kaste SC, Hopkins KP, Jones D, Crom D, Greenwald CA, Santana VM, et al. Dental abnormalities in children treated for acute lymphoblastic leukemia. *Leukemia* 1997;11(6):792-6, <http://dx.doi.org/10.1038/sj.leu.2400670>.
46. van der Pas-van Voskuilen IG, Veerkamp JS, Raber-Durlacher JE, Bresters D, van Wijk AJ, Barasch A, et al. Long-term adverse effects of hematopoietic stem cell transplantation on dental development in children. *Support Care Cancer.* 2009;17(9):1169-75, <http://dx.doi.org/10.1007/s00520-008-0567-1>.
47. Ackerman JL, Acherman LA, Ackerman BA. Taurodont, pyramidal, and fused molar roots associated with other anomalies in a kindred. *Am J Phys Anthropol.* 1973;38(3):681-94.
48. Jafarzadeh H, Azarpazhooh A, Mayhall JT. Taurodontism: a review of the condition and endodontic treatment challenges. *Int Endod J.* 2008;41(5):375-88, <http://dx.doi.org/10.1111/j.1365-2591.2008.01388.x>.
49. Nunn JH, Welbury RR, Gordon PH, Kernahan J, Craft AW. Dental caries and dental anomalies in children treated by chemotherapy for malignant disease: A study in the north of England. *Int J Pediatr Dent.* 1991;1:131(3)-5.