

# Treatment of a Class III growing patient with mandibular prognathism and severe anterior crossbite\*

Ricardo Machado Cruz<sup>1</sup>

The treatment of growing patients with Class III skeletal pattern represents one of the greatest clinical challenges for the orthodontist. Several treatment protocols have been proposed, almost all involving rapid maxillary expansion and maxillary protraction. However, there are cases where the maxilla is properly positioned in the anteroposterior direction and there is no transverse discrepancy, featuring only a mandibular prognathism. In such cases, when there is a set of favorable factors such as lack of laterognathism and lower mandibular plane angle, a viable option and which could prove quite interesting is the use of orthodontic chin cup during the night, aiming at trying to redirect the forward growth of the mandible. To have success, it is necessary that this procedure involves pubertal growth spurt and is extended to full skeletal maturation. This case was presented to the board of the Brazilian Board of Orthodontics and Dentofacial Orthopedics (BBO) as part of the requirements to become a BBO Diplomate.

**Keywords:** Class III. Chin cup. Anterior crossbite. Mandibular prognathism.

## INTRODUCTION

Caucasian male patient, 13 years old, in full pubertal growth spurt, with a chief complaint of anterior crossbite and very unsatisfied with his smile appearance.

Family history showed the presence of relatives with mandibular prognathism on the mother's family side. The other dental and medical history data reported in the anamnesis did not show any clinical importance.

\* Case report approved by the Brazilian Board of Orthodontics and Dentofacial Orthopedics (BBO).

<sup>1</sup> PhD in Animal Biology / Genetics, UNB. MSc in Orthodontics, UFRJ. Professor of Orthodontics, UNIP, Brasília campus. President of the Brazilian Association of Orthodontics and Dentofacial Orthopedics (ABOR). President of the College of Graduates BBO. Diplomate Brazilian Board of Orthodontics and Dentofacial Orthopedics (BBO).

**How to cite this article:** Cruz RM. Treatment of a Class III growing patient with mandibular prognathism and severe anterior crossbite. *Dental Press J Orthod.* 2012 July-Aug;17(4):148-59.

**Submitted:** May 28, 2012 - **Revised and accepted:** July 4, 2012

» The author reports no commercial, proprietary or financial interest in the products or companies described in this article.

» Patients displayed in this article previously approved the use of their facial and intraoral photographs.

**Contact address:** Ricardo Machado Cruz  
Rua Shis, Q19/11 bloco L, sala 101 - Lago Sul, Brasília/DF - Brazil  
CEP: 71.625-210 - E-mail: ricardomcruz@uol.com.br

# Tratamento de paciente Classe III em crescimento com prognatismo mandibular e severa mordida cruzada anterior\*

Ricardo Machado Cruz<sup>1</sup>

O tratamento de pacientes em crescimento com padrão esquelético de Classe III representa um dos maiores desafios clínicos para o ortodontista. Vários protocolos de tratamento têm sido propostos, quase todos envolvendo expansão rápida da maxila e protração maxilar. Porém, existem casos onde a maxila está corretamente posicionada no sentido anteroposterior e não há discrepância transversa, caracterizando apenas um prognatismo mandibular. Nesses casos, quando há um conjunto de fatores favoráveis, tais como ausência de laterognatismo e menor ângulo do plano mandibular, uma opção viável e que pode se mostrar bastante interessante é o uso noturno da mentoneira, com o objetivo de tentar redirecionar o crescimento anterior da mandíbula. Para que haja sucesso, é necessário que esse procedimento envolva o surto de crescimento da puberdade e seja estendido até a completa maturação esquelética. O presente caso clínico foi apresentado à diretoria do Board Brasileiro de Ortodontia e Ortopedia Facial (BBO), como parte dos requisitos para a obtenção do título de Diplomado pelo BBO.

**Palavras-chave:** Classe III. Mentoneira. Mordida cruzada anterior. Prognatismo mandibular.

\* Relato de caso clínico aprovado pelo Board Brasileiro de Ortodontia e Ortopedia Facial (BBO).

<sup>1</sup> Doutor em Biologia Animal/Genética pela UnB. Mestre em Ortodontia pela UFRJ. Professor Titular de Ortodontia da UNIP, campus Brasília. Presidente da Associação Brasileira de Ortodontia e Ortopedia Facial (ABOR). Presidente do Colégio de Diplomados pelo BBO. Diplomado pelo Board Brasileiro de Ortodontia e Ortopedia Facial (BBO).

**Como citar este artigo:** Cruz RM. Treatment of a Class III growing patient with mandibular prognathism and severe anterior crossbite. *Dental Press J Orthod*. 2012 July-Aug;17(4):148-59.

**Enviado em:** 28 de maio de 2012 - **Revisado e aceito:** 4 de julho de 2012

» O autor declara não ter interesses associativos, comerciais, de propriedade ou financeiros que representem conflito de interesse nos produtos e companhias descritos nesse artigo.

» O paciente que aparece no presente artigo autorizou previamente a publicação de suas fotografias faciais e intrabucais.

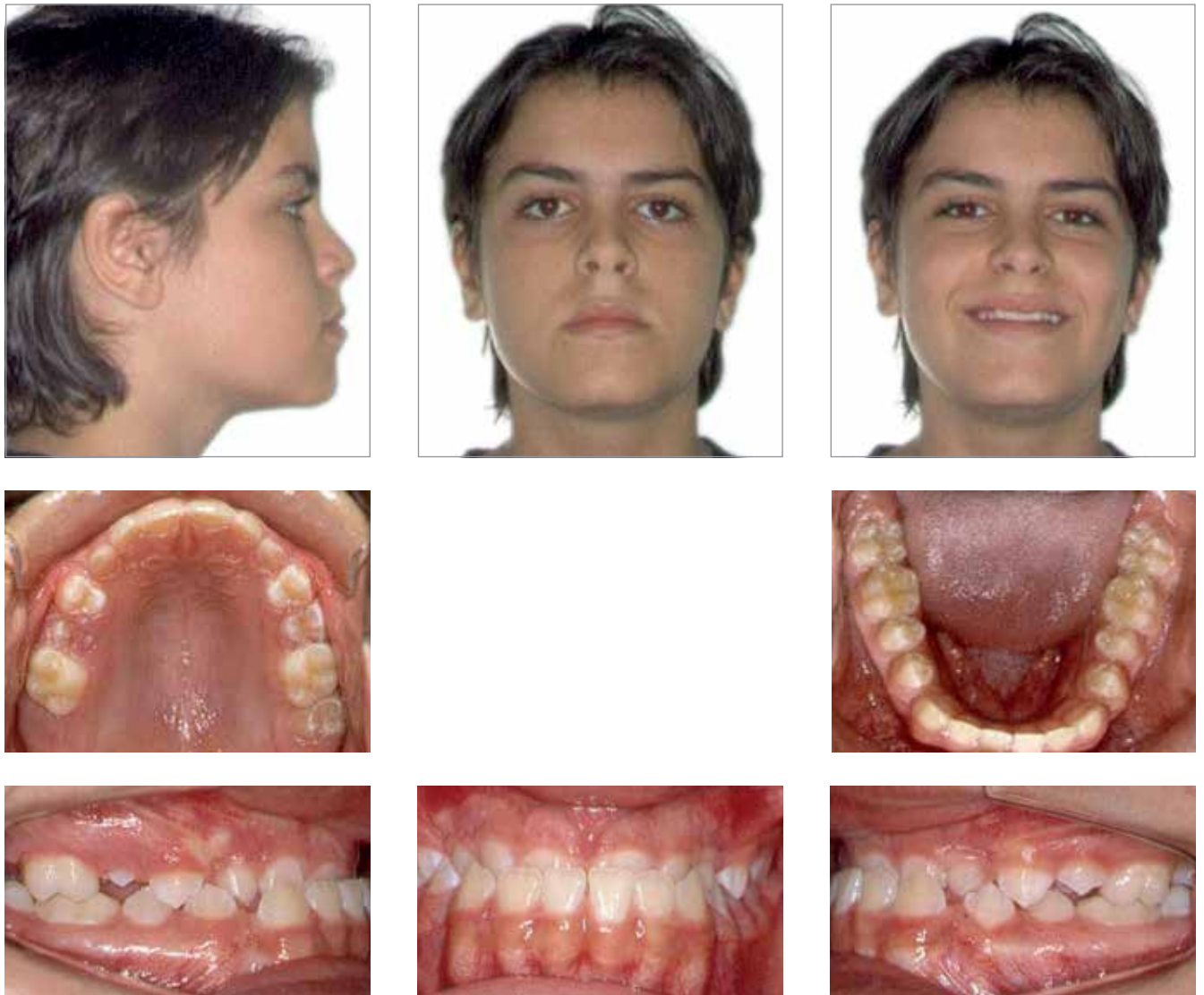
**Endereço para correspondência:** Ricardo Machado Cruz  
Rua Shis, Q19/11 bloco L, sala 101 – Lago Sul, Brasília/DF – CEP: 71.625-210  
E-mail: ricardomacruz@uol.com.br

## DIAGNOSIS

The patient had a slightly concave facial profile, with no obvious asymmetry, with a slight projection of the lower lip and unsatisfactory smile line, exposing mostly the lower anterior teeth and very little of the upper anterior teeth. He presented a good nasolabial angle, although slightly obtuse, and proper maxillary position in the anteroposterior direction (Fig 1).

In intraoral terms, he had a good dental and periodontal health, with the exception of the buccal surfaces of the upper incisors, which had wear facets,

resulting from the dental crossbite. In addition, the maxillary central incisors were in over-eruption. He was in the late mixed dentition, with prolonged retention of deciduous canines and with permanent canines successors still included. The second premolars and second molars were erupting. He also presented an Angle Class I malocclusion, with coincident dental midlines. He had a few diastemas in the lower arch and severe total crossbite in the anterior region (main complaint). All third molars were still included, but the lower right, absent by agenesis (Figs 1, 2, 3).



**Figure 1** - Initial facial and intraoral photographs.

Cephalometrically, the patient had a low mandibular plane angle and a tendency for predominant horizontal mandibular growth, in the counterclockwise direction (SNGoGn = 21° and FMA= 18°). He was diagnosed with a Class III skeletal pattern, due to excessive mandibular growth (ANB = -5°, SNA= 83° and SNB = 88°). The upper incisors were slightly buccal (I-NA = 26) and lower were retroclined (I-NB = 15°), seeking a natural dental compensation for the skeletal deficiency (Fig 4, Table 1).

### TREATMENT OBJECTIVES

Considering the patient's main complaint about the total anterior crossbite and the parent's concern about the family history of mandibular prognathism, the main treatment goal was to try to redirect mandibular growth, reducing, if possible, the SNB angle and at the same time, to maintain good maxillary anteroposterior position, because he had a satisfying nasolabial angle.

In the vertical and transverse aspects, the objective was to maintain the dimensions and growth pattern. For this reason, rapid maxillary expansion and protraction using a face mask were not indicated. In dental terms, the basic objective was to perform treatment without extractions, since the patient had no arch perimeter deficiency, and there was concern in aligning, leveling and monitoring the eruption of the teeth which had not erupted, especially the canines. In the incisor region, the objective was to correct their compensatory inclinations in both arches, and to close the lower diastema by means of retraction of anterior teeth, correcting the anterior crossbite.

Since he presented molars in key of occlusion, no movement of these teeth was planned in the antero-posterior direction. With these objectives in mind, improvement of facial and smile esthetics and the functional aspects of occlusion was expected, with control of mandibular growth to reduce the prognathism.

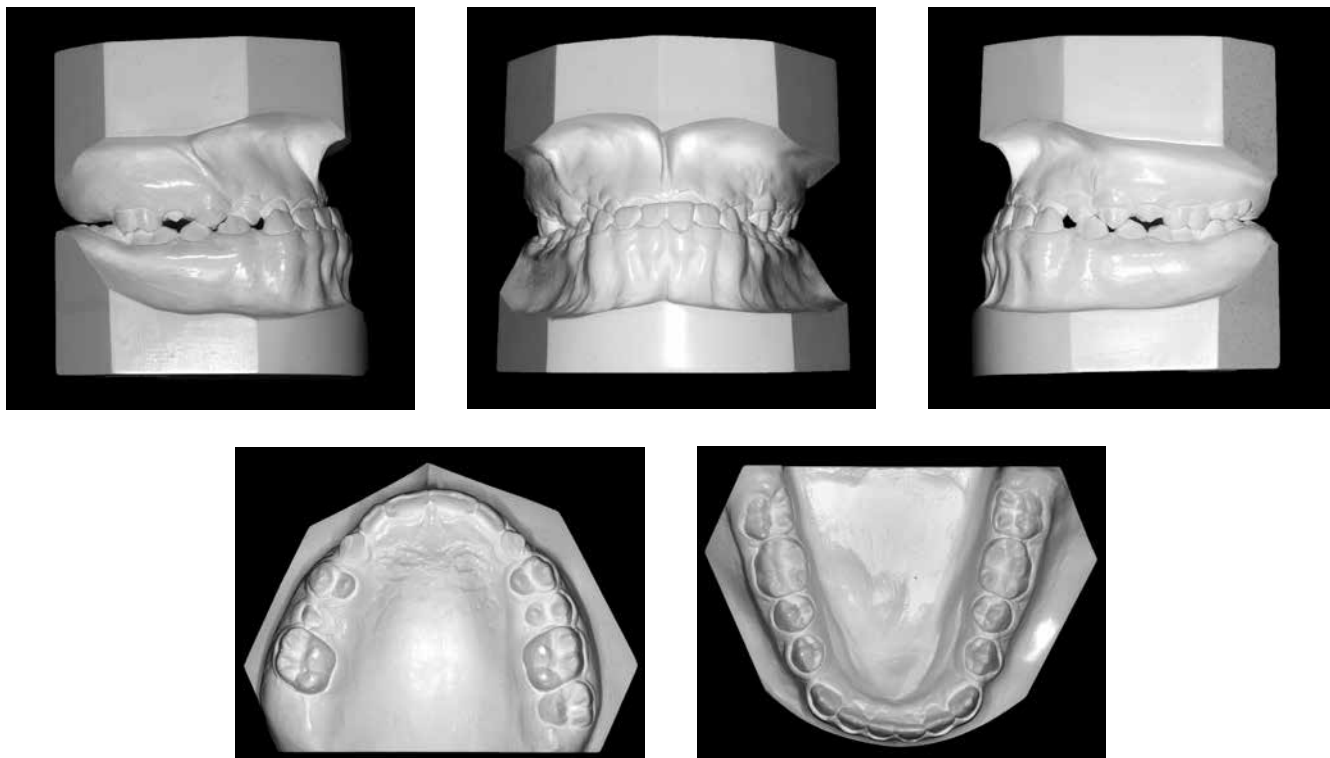
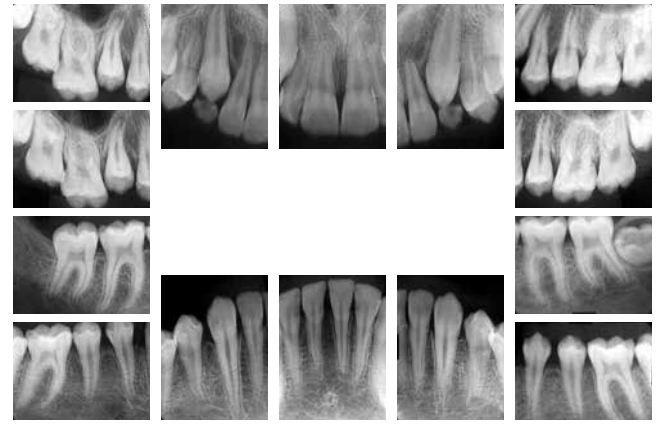
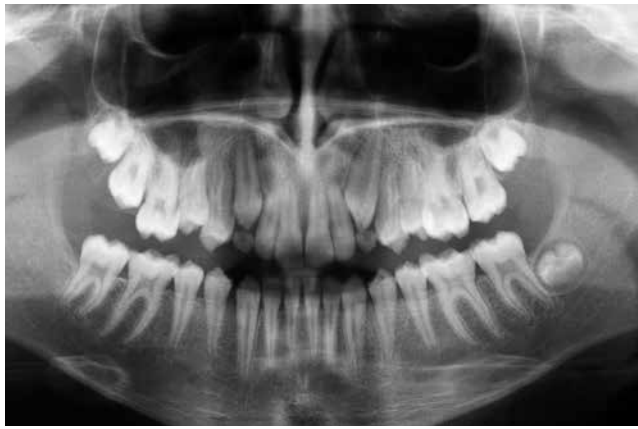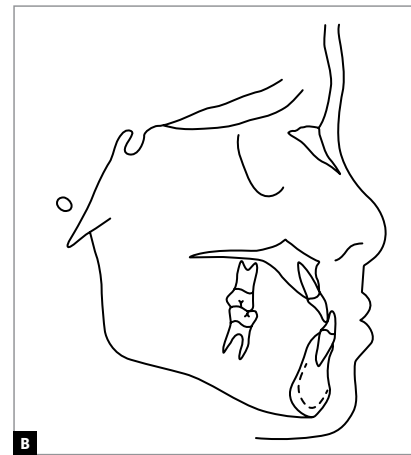

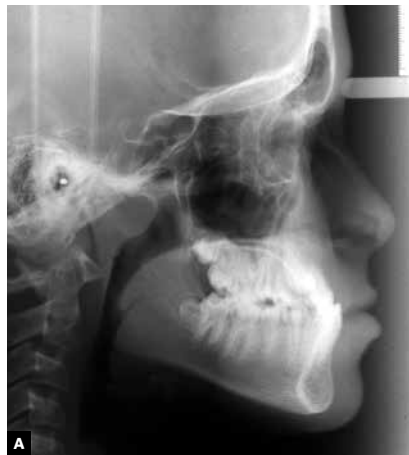
Figure 2 - Initial casts.



**Figure 3** - Initial panoramic and periapical radiographs.



**Figure 4** - Initial lateral cephalometric radiograph and cephalometric tracing.

## TREATMENT PLAN

A complete corrective Orthodontics a treatment with braces placed on both arches (metal brackets, slot 0.022 x 0.028-in, Straight-Wire system with Roth prescription) was proposed. In the lower arch, anchorage was planned to allow diastema closure with retraction of the anterior teeth, without simultaneous mesial movement of the posterior teeth. The anchorage proposal would use tip back bends on the posterior teeth associated, if necessary, with Class III elastics. The placement of braces would be made, initially, only in the lower arch, due to the impossibility to place orthodontic attachments on the buccal surfaces of upper anterior teeth. Leveling and aligning would be performed in the lower arch, starting from the 0.0175-in coaxial archwire, followed by 0.012-in 0.014-in and 0.016-in NiTi archwires and 0.016-in, 0.018-in and

0.020-in stainless steel archwires. After this phase, the braces are placed on the upper arch. This process in the upper arch is different, starting to place the appliances only in the posterior teeth and two central incisors. A utility TMA 0.019 x 0.025-in arch will be used for small intrusion of the central incisors, with torque control in order to minimize buccal inclination. Next, the lateral incisors would be included in the utility arch. If necessary, bite stops would be installed to enable placement of the upper appliance and correction of the anterior crossbite. Canine eruption would be followed up for complete placement of the upper appliance. Leveling and aligning would be performed in the upper arch with the same sequence used in the lower arch. Then lower canine distalization, to begin diastema closure, with the use of 0.019 x 0.025-in rectangular stainless steel archwires and elastic chains.

Final space closure would be done with rectangular 0.019 x 0.025-in stainless steel archwires with T loops for incisor retraction. At this stage, anterior crossbite correction will be completed. The case would be finished with 0.019 x 0.025-in stainless steel rectangular archwires with individual bends and torques. If necessary, Class III intermaxillary elastics would be used. Throughout treatment, to control mandibular growth, a chin cup with 500 g force was planned, only at night. As retention, in the upper arch, a wrap-around removable type plate would be used, and the lower intercanine fixed retainer, made with coaxial 0.0215-in wire. At the end, extraction of all three unerupted third molars would be indicated. The patient would have to continue to use the chin cup at night until full skeletal maturation.

### TREATMENT PROGRESS

Orthodontic bands were installed on the first four molars, with welded accessories (triple tubes in the upper teeth and double tubes in the lower teeth, all convertible). The chin cup was installed with 500 g of force for night use, and was custom made, after impression of the chin. Thanks to patient cooperation with the chin cup use, after aligning and leveling of the upper and lower arches, the bite was already edge to edge in the anterior region. Then, the retraction of the lower canines, and later, of the incisors was performed. During the entire space closure phase, posterior anchorage was performed by means of tip back bends on the lower molars and wire ligatures in tie-together posteriorly from the distal of the lower canines. At the end of this phase, the patient had normal overjet and overbite. On completion, for the first time, intermaxillary Class III elastics were used in order to improve the intercuspidation, especially in the canine region. Appliance removal occurred as planned. It was recommended that in addition to the removable upper retention plate, chin cup was to be used every night to sleep, until the end of growth, which would be assessed at 18 years of age, by carpal radiography.

At the end of treatment, extraction of third molars was suggested and referral to an expert in Restorative Esthetic Dentistry, to improve the appearance of the buccal surfaces of maxillary incisors – worn after several years in crossbite – as well as for clinical evaluation of demineralization white lesions.

### RESULTS

The main treatment objectives were achieved, with correction of severe anterior crossbite and improvement of the Class III skeletal pattern. The aesthetic and functional results were quite satisfactory (Figs 5-8). The treatment time was of approximately three years, and relatively short for the complexity of the case. The decision of not performing rapid maxillary expansion, since there was no transverse deficiency on the perimeter, and maxillary protraction, since it was well positioned in the anteroposterior direction, was correct. Cephalometric superimpositions (Fig 13) showed that there was a mandibular growth redirection, which was predominantly horizontal, to the vertical direction. Significant reduction of the SNB angle, possibly resulting from mandibular clockwise rotation, which increased the mandibular plane angle from 21° to 24°. These changes were the result of disciplined night use of the chin cup. As a final result the ANB angle went from -5° to -1°, a significant reduction (Tab 1).

Regarding the face, there was a significant improvement in all tested parameters, including the smile line was much pleasing with adequate exposure of the upper teeth, and there was an improvement of the profile, with a reduction in the projection of the lower lip (Fig 5, 8). From the dental point of view, molar key of occlusion was kept bilaterally, as planned. The major problem (chief complaint), which was the anterior crossbite, was completely corrected, achieving in the end, good overjet and overbite. The desired buccal inclination of mandibular incisors (dental decompensation) was achieved, but there was also an undesirable buccal inclination of maxillary incisors, which only returned to normal in the evaluation two years post-treatment (Fig 12, 13B and Tab 1). Both arches were properly leveled, especially the lower, whose leveling was by molar extrusion. This fact must also have contributed to the opening of the mandibular plane. In the upper arch, the intermolar distance was maintained and the intercanine width increased of 3.4 mm, due to the exchange of deciduous to permanent canines. In the lower arch, there was a decrease in the intercanine and intermolar distance (respectively 1.6 mm and 1.3 mm) (Figs 5, 6, Tab 2).

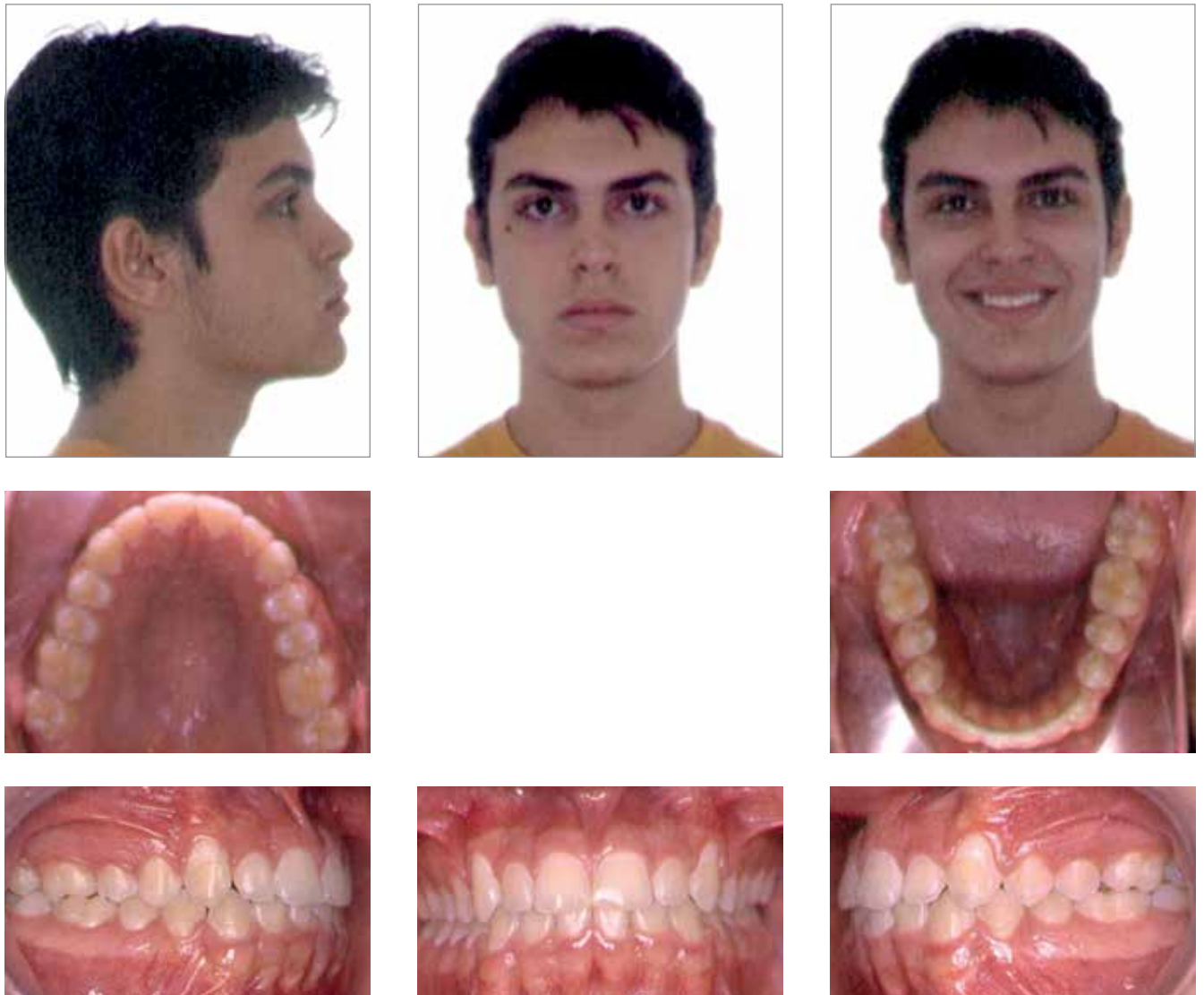
The evaluation of periapical and panoramic final radiographs shows good root parallelism and discrete apical rounding of the upper incisors, consistent with the orthodontic movement (Fig 7).

Due to the family history of mandibular prognathism, the periodic follow-ups were strictly observed in the phase of retention to assess the stability of the occlusion, the end of growth, the development and

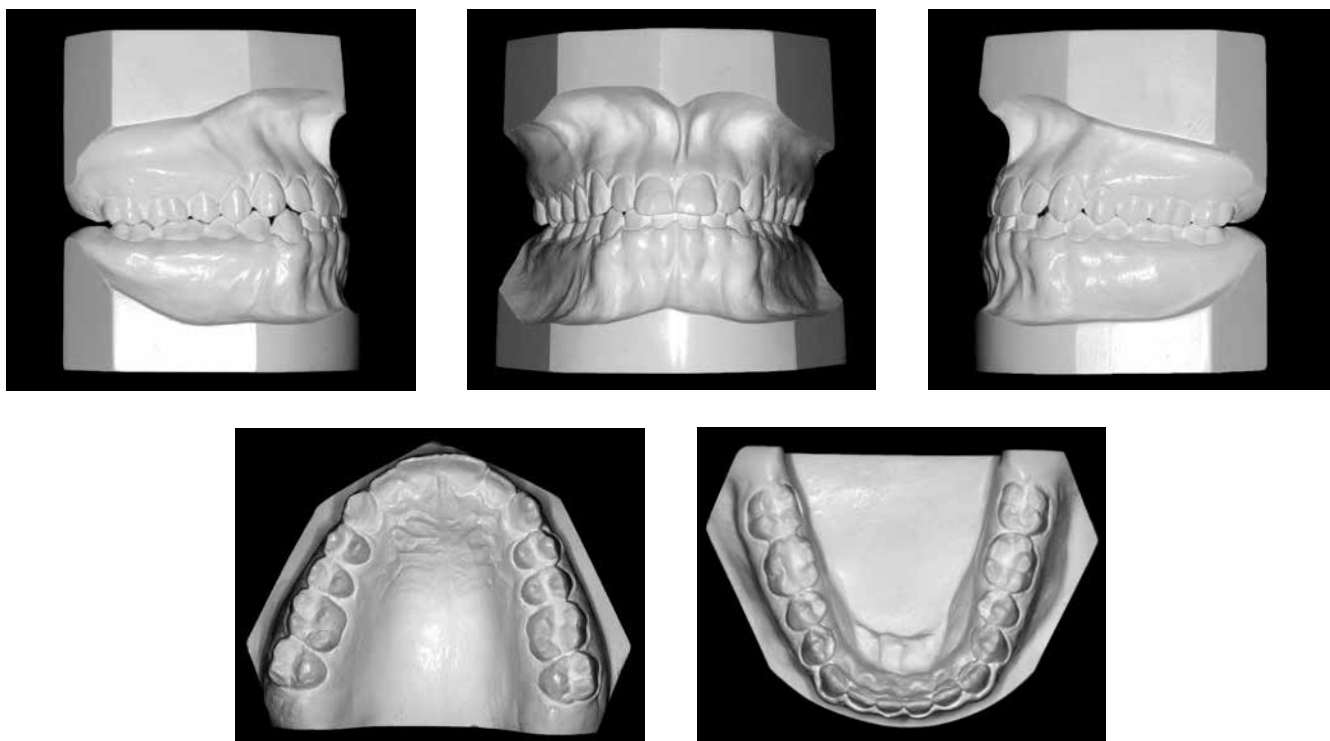
eruption of third molars, and a possible relapse due to mandibular residual growth.

New follow up records, 26 months after the end of treatment, when the patient was eighteen years and two months old, was requested.

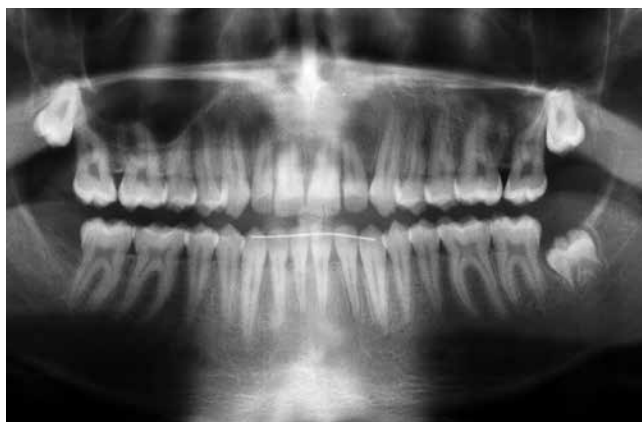The occlusal situation remained stable and satisfactory, providing functional balance and excursive mandibular movements without interference,



**Figure 5** - Final facial and intraoral photographs.



**Figure 6** - Final casts.



**Figure 7** - Final panoramic and periapical radiographs.

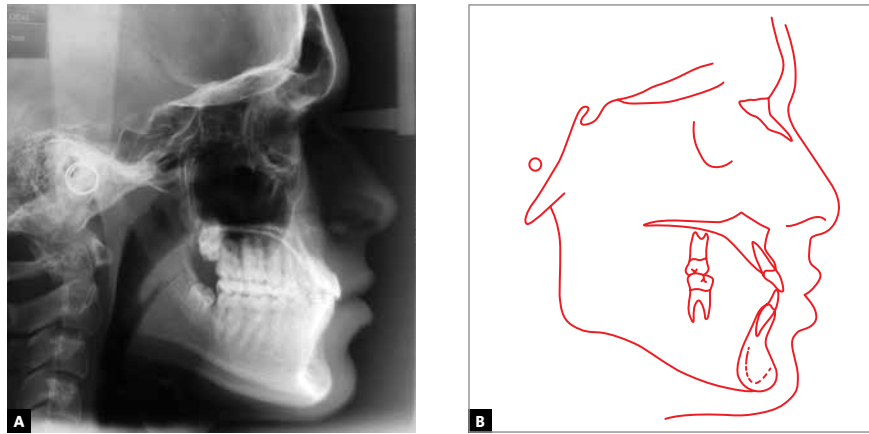
and good health of periodontal tissues (Figs 9, 10). Similarly, esthetic and facial smile remained appropriate (Fig 9). The comparison of cephalometric measurements (Tab 1) showed the improvement of some parameters to values closer to normality, as the SNB angle, which decreased  $1^\circ$ , generating an ANB with  $0^\circ$ ; the inclination of upper incisors, which decreased  $6^\circ$  and returned to its value from the beginning of treatment without compromising the final occlusion; the inclination of the lower incisors, which reduced  $3^\circ$ ,

also approaching the initial value, and the facial profile, where there was greater reduction in the projection of the lower lip (Figs 12, 13 and Tab 1).

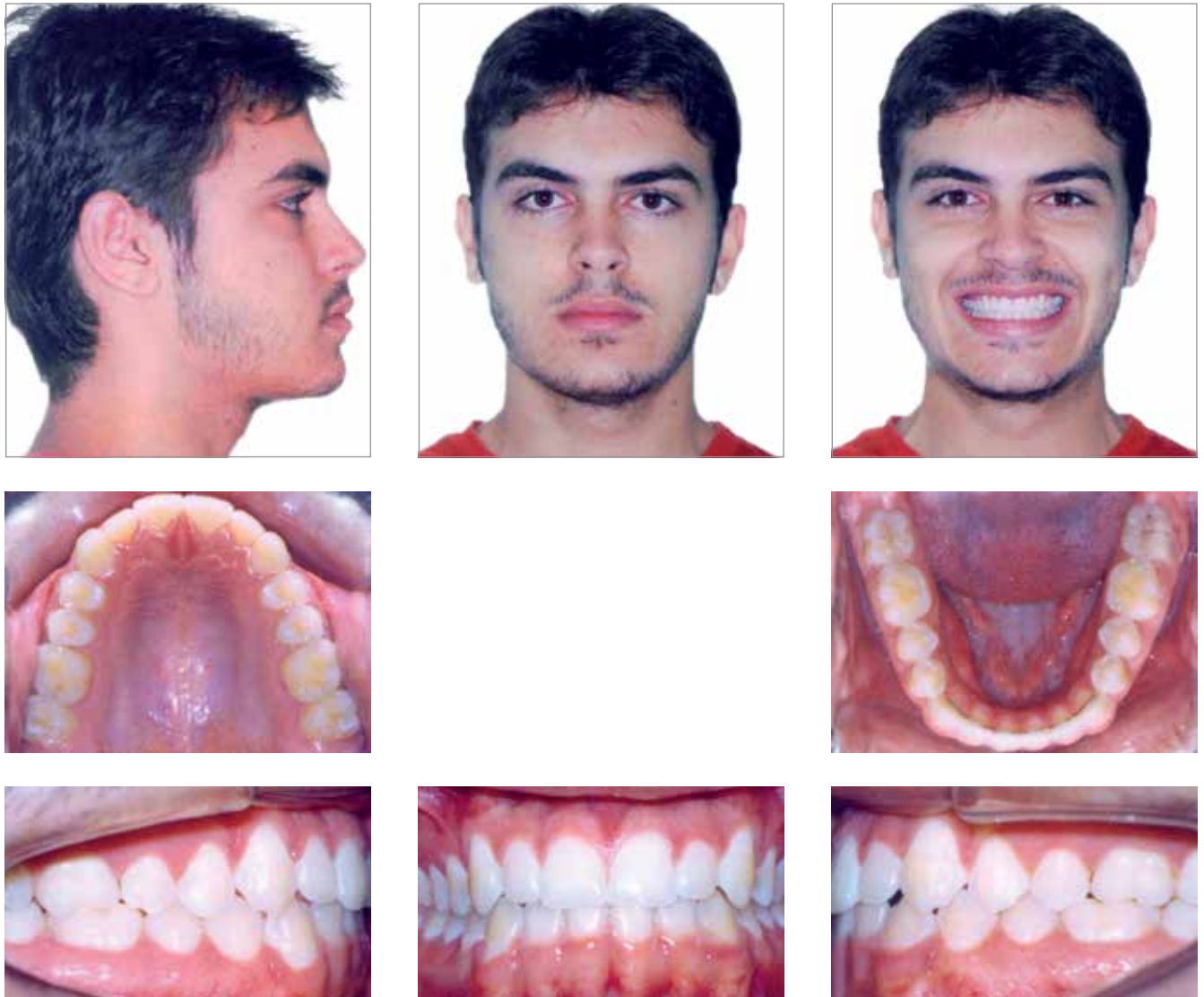The removable upper retention was used day and night for two years and intercanine fixed retainer remained, with suggestion of indefinite use.

The night use of the chin cup continued for two years after removal of the appliance, until the patient completed eighteen years of age, and skeletal maturation was confirmed by carpal X-ray (Fig 11).

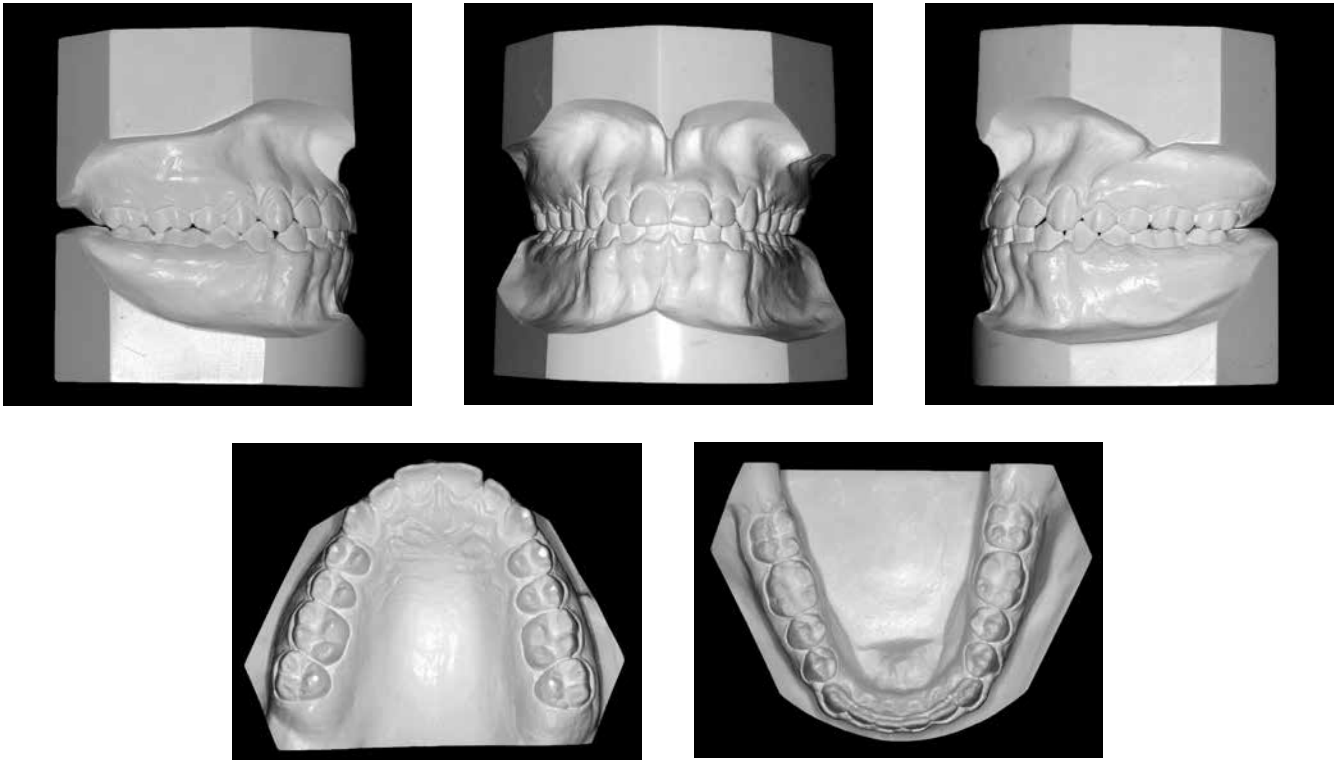




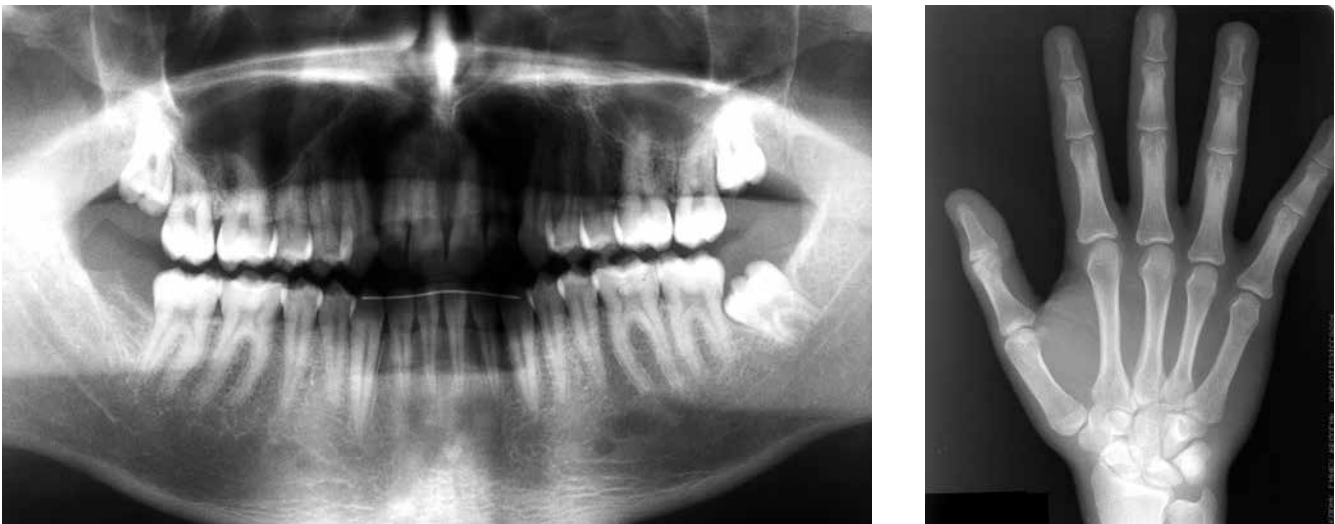**Figure 8** - Final lateral cephalometric radiograph and final cephalometric tracing.



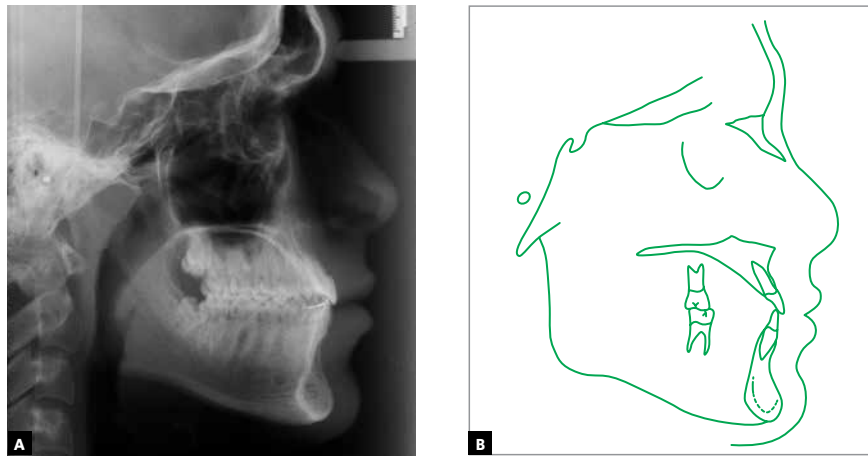
**Figure 9** - Two years and two months post-treatment facial and intraoral photographs.



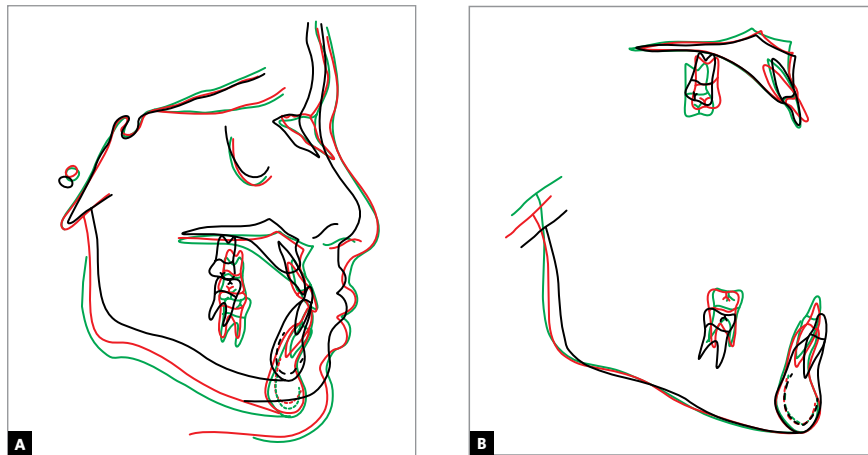
**Figure 10** - Two years and two months post-treatment casts.



**Figure 11** - Two years and two months post-treatment panoramic and hand and wrist radiographs.



**Figure 12** - Two years and two months post-treatment lateral cephalometric radiograph and cephalometric tracing.



**Figure 13** - Total (A) and partial (B) superimpositions of initial cephalometric tracing (black), final (red) and two years and two months post-treatment (green).

This disciplined use of the chin cup, even after the end of active orthodontic treatment was important to control the residual growth of the mandible. Despite the orientation, the patient did not carry out the procedures for esthetic wear on the buccal surfaces of upper anterior teeth or removal of third molars (Figs 9 to 11).

Despite the family history of mandibular prognathism, it is believed that the case is stable.

However, the patient remains under control, with periodic annual reassessments.

### FINAL CONSIDERATIONS

Class III malocclusion treatment is one of the biggest challenges for the orthodontist in his daily clinical routine. Although mandibular growth being mainly under genetic control, the chin cup can change

**Table 1** - Summary of cephalometric measurements.

	Measures		Normal	A	B	A/B Difference	C
<b>Skeletal pattern</b>	SNA	(Steiner)	82°	83°	82°	1	82°
	SNB	(Steiner)	80°	88°	83°	5	82°
	ANB	(Steiner)	2°	-5°	-1°	4	0°
	Convexity angle	(Downs)	0°	-8°	-6°	2	-6°
	Y axis	(Downs)	59°	60°	62°	2	63°
	Facial angle	(Downs)	87°	89°	85°	4	88°
	Sn-GoGn	(Steiner)	32°	21°	24°	3	23°
	FMA	(Tweed)	25°	18°	17°	1	15°
<b>Dental pattern</b>	IMPA	(Tweed)	90°	86°	92°	6	93°
	1-NA (degrees)	(Steiner)	22°	26°	32°	6	26°
	1-NA (mm)	(Steiner)	4 mm	5 mm	9 mm	4	7 mm
	1-NB (degrees)	(Steiner)	25°	15°	21°	6	18°
	1-NB (mm)	(Steiner)	4 mm	2 mm	4 mm	2	3 mm
	1-1 - Interincisal angle	(Downs)	130°	142°	129°	13	137°
	1-APo (mm)	(Ricketts)	1 mm	5 mm	1 mm	4	2 mm
<b>Profile</b>	Upper lip - S line	(Steiner)	0 mm	0 mm	0 mm	0	0 mm
	Lower lip - S line	(Steiner)	0 mm	+3 mm	+2 mm	1	0 mm

growth and morphology of the mandible itself.<sup>1</sup> Studies have shown that the force of the chin cup can change the shape of the jaw, slow condylar growth, improve the position of the chin in the anteroposterior direction and inhibit some maxillary vertical development.<sup>1,5,6,8,9,11</sup> For this to occur, a minimum of two years of therapy with night use is necessary, because the condyles should be at rest when the compressive force is applied.<sup>5,6</sup> The daytime use could lead to a risk of articular disk displacement.<sup>5,6,11</sup> It is recommended that previous records of temporomandibular disorders are performed and that, at the appearance of any sign of joint dysfunction, forces and amount of hours are decreased or even suspend chin cup use.<sup>9</sup>

Results of previous studies have shown that the use of chin cups applying a force of 500 to 600 g,<sup>11,12</sup> hours, on average, can lead to significant changes in mandibular growth patterns during puberty. However, the force duration can vary from 6 to 15 hours/day, and it would not interfere much in the amount of growth that would be inhibited or redirected. The different responses found are mainly due to individual differences to the effects of orthopedic applied forces.<sup>6,11</sup>

**Table 2** - Inter canine and intermolar distances (mm).

	Initial	Final	Post-treatment
Upper intercanine distance	33.0	36.4	36.4
Lower intercanine distance	29.6	28.0	33.0
Upper intermolar distance	55.2	54.6	54.0
Lower intermolar distance	47.8	46.5	47.0

However, the changes achieved in the jaw will not be maintained if the use of the chin cup is interrupted before skeletal maturity.<sup>5</sup> Condylar growth is really slowed during the first two years of therapy, but once the force is removed, there is still growth potential in the condylar cartilage, there seems to be an acceleration in condylar growth and a recovery in growth to the initial level. The degree of recovery depends on how much change has already been achieved in the chin cup therapy and how much growth potential is still left.<sup>1,8,9,11</sup>

There is no consensus in the literature regarding the best time to start orthodontic/orthopedic treatment of Class III subjects, but all agree that this

should involve pubertal growth spurt.<sup>3</sup> There seems to be no difference between the final skeletal profiles of individuals who started treatment early, around 7 years old, and those who left to start treatment later in the early pubertal growth spurt.<sup>3,8</sup> When planning such treatment, the clinician must take into account the likely duration of the growth spurt, to establish the time of use of orthopedic mechanics. A recent study showed that, in Class III, the duration of the growth peak is on average longer than five months in the Class I. This difference is statistically significant and, according to the authors, it could explain the greater increase in mandibular length in Class III individuals.<sup>4</sup> In any event, the recommendation is

that the use of chin cup should not be less than 12 months.<sup>11</sup> However, after the end of the growth spurt, there seems to be no difference between the growth pattern of a patient with mandibular prognathism and a normal individual.<sup>7</sup>

The choice of using the chin cup in the case reported in this work seemed the best option and, finally, the desired functional and esthetic objectives were achieved. But it should be always taken into consideration that the individual growth responses are not predictable. Not surprisingly, the same orthodontic/orthopedic treatment does not produce the same response in all individuals, since the subjects do not grow in the same manner.

## REFERENCES

1. Abu Alhaja ES, Richardson A. Long-term effect of the chin cup on hard and soft tissues. *Eur J Orthod.* 1999 Jun;21(3):291-8.
2. Baccetti T, Franchi L, McNamara JA. Cephalometric variables predicting the long-term successor failure of combined rapid maxillary expansion and facial mask therapy. *Am J Orthod Dentofacial Orthop.* 2004;126:16-22.
3. Franchi L, Baccetti T, McNamara JA. Postpubertal assessment of treatment timing for maxillary expansion and protraction therapy followed by fixed appliances. *Am J Orthod Dentofacial Orthop.* 2004;126:555-68.
4. Malgorzata K, Baccetti T. Duration of the pubertal peak in skeletal Class I and Class III subjects. *Angle Orthod.* 2010 Jan;80(1):54-57.
5. Mitani H. Early application of chin cup therapy to skeletal Class III malocclusion. *Am J Orthod Dentofacial Orthop.* 2002;121(6):584-5.
6. Mitani H, Fukazawa H. Effects of chin cup force on the timing and amount of mandibular growth associated with anterior reversed occlusion (Class III malocclusion) during puberty. *Am J Orthod Dentofacial Orthop.* 1986 Dec;90(6):454-63.
7. Mitani H, Sato K, Sugawara J. Growth of mandibular prognathism after pubertal growth peak. *Am J Orthod Dentofacial Orthop.* 1993 Oct;104(4):330-6.
8. Sugawara J, Asano T, Endo N, Mitani H. Long-term effects of chin cup therapy on skeletal profile in mandibular prognathism. *Am J Orthod Dentofacial Orthop.* 1990;98(2):127-33.
9. Sugawara J, Mitani H. Facial growth of skeletal Class III malocclusion and the effects, limitations and long-term dentofacial adaptations to chin cup therapy. *Semin Orthod.* 1997;3(4):244-54. Review.
10. Uçüncü N, Uçem TT, Yüksel S. A comparison of chin cup and maxillary protraction appliances in the treatment of skeletal Class III malocclusions. *Eur J Orthod.* 2000;22(1):43-51.
11. Uner O, Yüksel S, Uçüncü N. Long-term evaluation after chin cup treatment. *Eur J Orthod.* 1995;17(2):135-41.