

Comparison between cavum and lateral cephalometric radiographs for the evaluation of the nasopharynx and adenoids by otorhinolaryngologists

Rhita Cristina Cunha Almeida*, Flavia Artese**, Felipe de Assis Ribeiro Carvalho*, Rachel Dias Cunha***, Marco Antonio de Oliveira Almeida****

Abstract

Introduction: The lateral cephalometric, as well as the cavum radiograph, allow the evaluation of the nasopharyngeal airway (NAW). Otorhinolaryngologists routinely use the cavum radiograph, even when the patient already has a lateral cephalometric headfilm. **Objectives:** The aim of this study was to (a) acknowledge which exams otorhinolaryngologists use for the evaluation and measurement of the NAW; (b) evaluate if the otorhinolaryngologists are acquainted to the cephalometric method; (c) compare both radiographs to see which one is preferred to visualize the NAW and adenoids and (d) correlate the visual analysis to the measuring method of Schulhof. **Methods:** For this purpose, the cephalometric and the cavum radiographs of 15 mouth-breathing children were taken on the same day. These radiographs were masked leaving only the NAW and the adenoids visible, and were blindly presented to 12 otorhinolaryngologists. They received the radiographs together with a questionnaire asking about their familiarity with the lateral cephalometric radiograph, which exams are used for NAW and adenoid evaluation and if they use any method for measuring the NAW obstruction level. They were also asked to visually classify the NAW and the adenoids according to their sizes into small, medium and large. **Results:** The results demonstrated that all otorhinolaryngologists in the sample use the cavum radiograph. Only one uses the cephalometric radiograph and two are familiar with this technique. The cephalometric radiograph was preferred by 49.4% of the otorhinolaryngologists, the cavum by 22.8% and 27.8% did not see any difference between both methods. There was low correlation between the visual method and the Schulhof measuring method.

Keywords: Orthodontics. Otorhinolaryngology. Cavum radiograph. Cephalometric radiograph.

* MSc in Orthodontics, State University of Rio de Janeiro (UERJ). Specialist in Orthodontics, UERJ.

** Associate Professor, Department of Orthodontics, UERJ.

*** Specialist in Otorhinolaryngology.

**** Head Professor, Department of Orthodontics, UERJ.

INTRODUCTION

Mouth breathing is a functional problem considered relatively common. Eighty-five percent of children present some degree of nasal insufficiency, as demonstrated by functional tests, and 20% are total mouth breathers.²⁰ A child can become a mouth breather because of any obstructive factor or because of oral habits, such as thumb sucking, and it can cause changes in the normal craniofacial growth and development.²⁶ Among the obstructive factors, the adenoid is the most described in the literature.^{9,18,25,27}

Because the mouth breather patient has both functional and occlusal changes, treatment requires a multidisciplinary interaction, involving a speech therapist, an otorhinolaryngologist and an orthodontist, so that the primary causes of malocclusion can be removed avoiding treatment relapses.¹³

The orthodontist in daily routine uses the lateral cephalometric radiograph described by Broadbent⁴ to define the patient's treatment plan. This radiograph is obtained in a standard manner with the same head position and with the same distance from the radiation cone, allowing the professional to make measurements and compare those measurements in different treatment periods. This radiograph is considered by many authors as a simple exam, practical and with good results to diagnose the size of the nasopharyngeal airway.²⁷ Nevertheless, most of the otorhinolaryngologists use the cavum radiograph to evaluate the nasopharyngeal airway³, which is also a lateral cranium radiograph such as the lateral cephalometric radiograph, but without any standardized patterns, offering the doctor an adequate image for nasopharyngeal airway evaluation, but inadequate for orthodontic treatment planning.

Because of a poor relationship between both specialties and the absence of scientific researches comparing these two radiographic

techniques, professionals still don't know which image would provide the best view of the nasopharyngeal airway and which measurement technique would be more precise, submitting the patient to both radiographic exams.

Gurgel et al¹⁰ described that the mouth breather diagnosis should be performed using specialized exams, like the oropharynx clinical exam, anterior rhinoscopy, nasofibroscopy and otoscopy, and by complementary exams, like blood tests, radiographs and patient clinical history. The radiographic exam described by the authors was the cavum radiograph.

Holmberg and Linder-Aronson¹⁴ studied if the lateral and frontal cephalometric radiographs would be useful to evaluate the nasal respiratory function and concluded that the lateral radiograph would offer good results on the nasopharyngeal dimensions and the frontal radiograph would offer good information on the capacity of the nasal airways.

In a systematic review on diagnosis of adenoid hypertrophy and nasopharyngeal airway obstruction using the cephalometric radiograph, Major et al²¹ concluded that there is a good correlation on the size of the adenoid, but the ability to diagnose a small nasopharyngeal airway is not that good. The authors attribute these findings to the fact that the adenoid is a simpler anatomic structure than the nasopharynx and loses less information when transformed into a bidimensional image.

Some researches have done comparing the cephalometric radiograph with the nasopharyngeal endoscopies. Ianni Filho et al¹⁵ compared both methods and concluded that the radiographic exam is important for the initial diagnosis of nasopharyngeal obstruction, but it gives very limited information. The endoscopy gives more information, but would be harder to be obtained. Vilella et al²⁹ found very similar results regarding the anteroposterior size of the nasopharynx using both methods and suggested

that when evaluating the child respiratory pattern, not only a clinical exam should be done, but also cephalometric measurements of the nasopharyngeal space.

The computerized tomography can also be used for the diagnosis of nasopharyngeal obstruction, being a more precise exam but also more expensive. Montgomery et al²³ described that after evaluating the results obtained with the tomography, it becomes clear how the radiographic exam is poor in information. The authors suggest that the tomography should be used as a gold pattern, but the cephalometric exam should be used as a tool to determine if a more detailed exam is needed or not, having in mind that this is a bidimensional exam, and, therefore, is very limited.²¹

Besides being the first complementary exam doctors ask for patients with suspected mouth breathing patterns, the radiographic evaluation stands with the clinical exam as the most used method to evaluate adenoid hypertrophy¹ and changes in the nasopharyngeal space⁷. The correct radiograph technique should always be followed to minimize possible adversities such as patient bad positioning or movement¹. The child should always be calm, with his back straight, mouth closed, breathing by the nose and with the head oriented in the horizontal plane and lateral to the x-ray.^{1,24,25}

Araújo Neto et al¹ affirmed that because of the variety and the complexity of the measurement methods for the radiographic diagnosis of adenoids, several radiologists prefer to use the subjective analyses. In this way, the visual analysis of the cavum radiograph gives, most of the times, an imprecise diagnosis.

There are several methods described to evaluate nasopharyngeal radiographs and interpretation when adenoids should be considered bigger than normal varies from author to author. The most used methods to measure adenoids in the cavum radiograph are those described by Johan-

nesson,¹⁶ Fujioka et al,⁸ Crepeau et al⁶ and Cohen and Konak.⁵ And when using the cephalometric radiograph, there are two methods described in the literature, McNamara's²² and Schulhof's.²⁶

Since mouth breathing is a multidisciplinary problem treated by the orthodontist and the otorhinolaryngologist and both specialists use lateral cranium radiographs, it becomes necessary to compare the lateral cephalometric and the cavum radiographs to try to establish which exam should be indicated, so that the patient has to be submitted to only one radiograph instead of two, minimizing expenses and radiation exposure.

With this in mind, this paper aimed to evaluate: (a) Which exams the otorhinolaryngologists routinely ask for to evaluate and measure the nasopharyngeal airway; (b) the percentage of otorhinolaryngologists that are familiar with the lateral cephalometric radiograph; (c) nasopharyngeal airway and adenoid visualization, by the otorhinolaryngologist, in cavum and lateral cephalometric radiographs of mouth breathing patients; and (d) the correlation between the nasopharyngeal airway and adenoid visual method analysis and the measuring method according to Schulhof.²⁶

MATERIAL AND METHODS

For this study, a sample of radiographs of mouth breathing children was used. To obtain this sample, 150 children between 6 and 12 years old were evaluated in the city of Recife (Brazil). All children were submitted to a clinical anamnesis performed by the same evaluator based on the inclusion criteria which were: no orthodontic appliance usage, no treatment with medication, adenoids should be present, no congenital anomalies and had to be a mouth breather.

Only 38 of the 150 children could be included in the sample. The parents signed a consent term allowing the children to participate in the study. Two children did not have parental

approval, resulting in 36 children.

The sample was submitted to clinical exams by the orthodontist and a speech evaluation by the speech therapist to certify that all of them were mouth breathers.

The speech evaluation consisted in questions about the masticatory function and the ability to swallow, which kind of food the patient preferred eating during meals, time spent in meals and if there were any stomach pain and liquid ingestion; if the patient had sleeping problems, if the patient snored, if there were any oral habits, state of general health, if there was any respiratory disease (asthma, rhinitis, sinusitis, bronchitis), any nasal obstruction, congenital disease (cleft lip and palate, syndromes), pain in the temporomandibular joint, any history of face trauma and if the patient had being submitted to any surgery.

A clinical exam was also performed observing lips, tongue, cheeks, and speech test, breathing test, masticatory test and swallowing test.

After anamnesis, the patients were submitted to two different radiographic exams in the same day: lateral cephalometric radiograph (Fig 1A) and cavum radiograph (Fig 1B). If any child presented a cold in the day scheduled for the exam, it was postponed to when the child felt better.

The same operator, with more than five years experience, took the cephalometric radiographs. To evaluate the operator method error a Kappa test was used, demonstrating an excellent agreement. The radiographs were obtained as described by Broadbent⁴ in 1931.

The same operator took the cavum radiographs. The radiographs were obtained as described by Bontrager³, in 2003, with some adaptations for the patient breathing, the area sub-

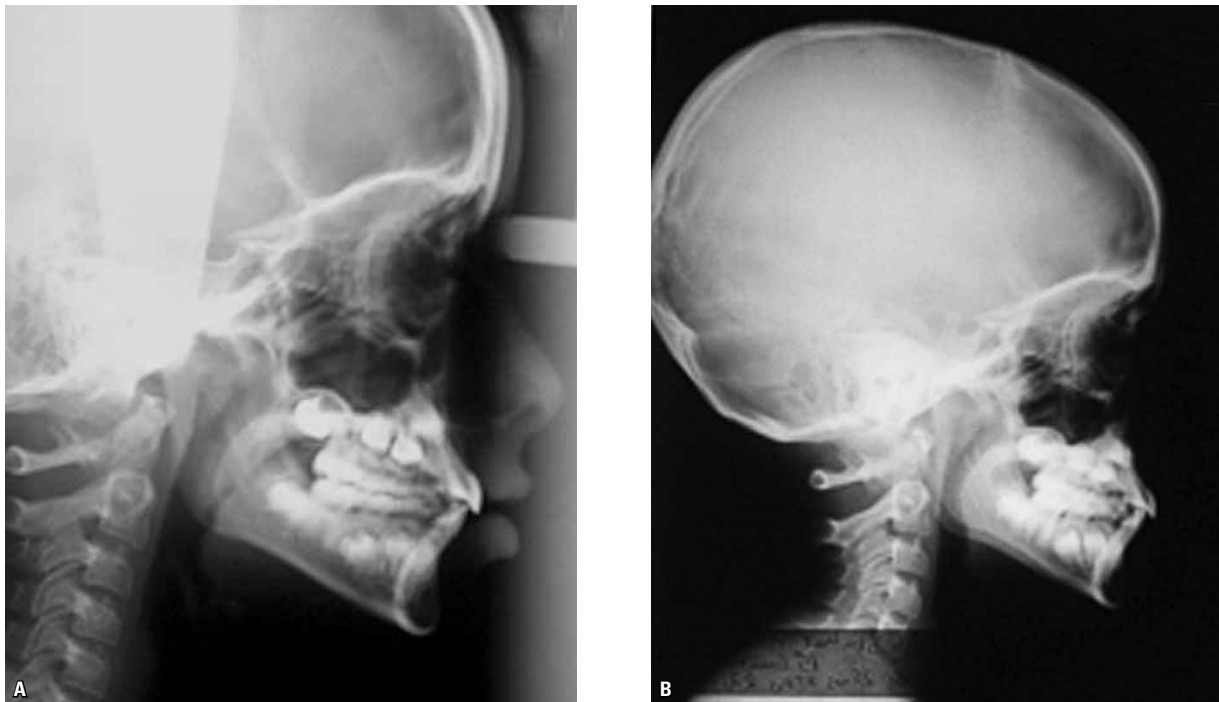


FIGURE 1 - Lateral cephalometric radiograph (A) and cavum radiograph (B) obtained from the same mouth breathing patient, in the same day.

mitted to radiation and the focal distance to the radiograph apparatus.

Fifteen patients were selected with ages closer to 10 years and with different sizes of the nasopharyngeal airway, classified as small, medium and large according to the Schulhof²⁶ analysis (Fig 2) resulting in a total of 30 radiographs. This selection was performed to reduce the time spent by the otorhinolaryngologists that participated in this study, aiming for more cooperation of the group.

These radiographs were placed in thick black paper envelopes and the area covering the nasopharyngeal space and the adenoids was removed, so that this was the only area that could be seen in the radiograph. This was done so that the examiners could not identify which radiograph they were evaluating, avoiding any tendency of picking the image they were more used to analyzing. The radiographs were named radiograph A (cavum) and radiograph B (cephalometric). It was asked for 12 otorhinolaryngologists of the city of Rio de Janeiro with at least two years of clinical experience to compare both radiographs and to answer the questionnaires.

The examiner received the radiographs with a presentation letter, one general questionnaire and a questionnaire elaborated to evaluate each pair of radiographs. In the general questionnaire there were questions on the familiarity of the doctor with the cephalometric radiograph, on which exams the doctor usually indicates to visualize nasopharyngeal airways and adenoids, and if he used any type of measurement of the airways. This questionnaire intended to evaluate the study sample. In the questionnaire used to evaluate the radiographs there were questions about which one had the best quality in visualizing the adenoids and nasopharyngeal airways and they were asked to classify the size of the adenoids and nasopharyngeal airways as small, medium or large, using the visual method.

For the statistical treatment a binomial dis-

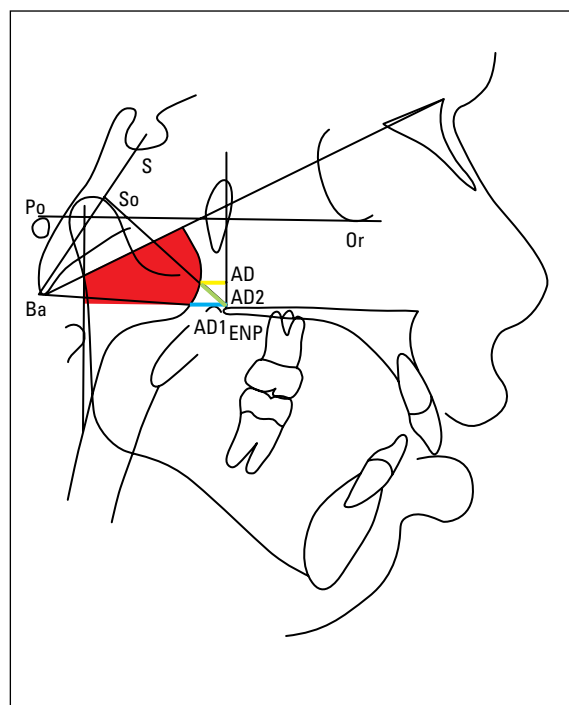


FIGURE 2 - Diagram describing the Schulhof analysis. The first factor, in red, corresponds to the percentage of the airway occupied by the adenoid tissue in the Handelman and Osborne nasopharyngeal area; the second factor, in blue, is the distance of point AD1 to the posterior nasal spine described by Linder-Aronson and Henrikson; the third factor, in green, is the linear distance of point AD2 to the posterior nasal spine, described by Linder-Aronson and Henrikson; and the fourth factor, in yellow, corresponds to the linear distance of point AD to a point from the pterigid vertical line, 5 mm above the posterior nasal spine, described by Ricketts.²⁶

tribution was used to see which radiograph was preferred by the otorhinolaryngologists to visualize adenoids and nasopharyngeal airways with absolute and relative frequencies of preferences. To evaluate the correlation between the results of the visual method and the Schulhof measuring method the values of percentage of agreements and kappa were calculated.

RESULTS

The first part of the questionnaire had the purpose of (a) presenting which exams the otorhinolaryngologists pertaining to this sample usually ask to visualize nasopharyngeal airways

and adenoids; (b) if they use or not any measuring method and (c) if they are familiar with the cephalometric radiograph.

This questionnaire demonstrated that the cavum radiograph is the most prescribed method (100%), followed by endoscopy (83%) and the cephalometric radiograph was only used by one of the doctors in this sample. Only one of them used any type of measurement to evaluate the degree of obstruction of the nasopharyngeal airway, while only two of them were familiar with the cephalometric technique as a method of diagnosing obstruction.

The sample preference in visualizing adenoids and nasopharyngeal airway are described in Tables 2 and 3. They show the absolute and relative frequencies of the preferences related to the cavum and cephalometric radiographs. Table 1 shows the preference in visualizing the adenoids, where 49.4% preferred technique B (cephalometric), 22.8% preferred A (cavum) and 27.8% didn't observe any difference between both methods. As for the naso-

pharyngeal airway, 48.9% preferred technique B (cephalometric), 23.9% preferred A (cavum) and 27.2% didn't observe any difference between them (Table 2).

Table 3 shows agreement values between the visual analysis done by the otorhinolaryngologists when analyzing the radiographs and the values found using Schulhof's method. A low correlation was found between both methods.

DISCUSSION

Considering the controversies in accepting only the clinical signs to confirm the diagnosis of mouth breathing, medical and dental professionals use complementary exams to help in this diagnosis.

Despite limitations, radiographic exams are the most used, and the first to be asked for, when trying to make a diagnosis. After analyzing a radiograph the doctor will decide if any other exams are necessary.^{1,5,7,24,25}

The use of a radiographic technique to evaluate nasopharyngeal airway has been

TABLE 1 - Absolute and relative frequencies of the preference of the otorhinolaryngologists (n=12) to visualize adenoids in mouth breathing children (n=15) in the cavum radiograph (technique A) and the lateral cephalometric (technique B).

Preference	N	%	Confidence Interval 95%	
			Inferior limit	Superior limit
Technique A	41	22.8	16.9%	29.6%
Technique B	89	49.4	41.9%	57.0%
Both	50	27.8	21.4%	34.9%
Total	180	100		

TABLE 2 - Absolute and relative frequencies of the preference of the otorhinolaryngologists (n=12) to visualize nasopharyngeal airways in mouth breathing children (n=15) in the cavum radiograph (technique A) and the lateral cephalometric (technique B).

Preference	N	%	Confidence Interval 95%	
			Inferior limit	Superior limit
Technique A	43	23.9	17.9%	30.8%
Technique B	88	48.9	41.4%	56.4%
Both	49	27.2	20.9%	34.3%
Total	180	100		

TABLE 3 - Percentage of agreement values and Kappa between the visual method and the Schulhof measuring method to evaluate the size of adenoids and nasopharyngeal airways (NAW) of mouth breathing children (n=15).

	Comparison	Observed agreement	Expected agreement	Kappa	P-value
Adenoid	Schulhof X Visual Cavum	62.78%	60.19%	0.06	0.1756
	Schulhof X Visual Ceph	57.22%	59.81%	-0.06	0.8194
NAW	Schulhof X Visual Cavum	36.67%	44.81%	-0.14	0.9927
	Schulhof X Visual Ceph	37.78%	45.19%	-0.13	0.9862

questioned because of its bidimensional visualization and static view in order to evaluate a tridimensional and dynamic structure. Several researches have demonstrated a significant correlation between the results obtained in the radiographic evaluation and the clinical evaluation,¹⁴ in the direct observation during the surgical procedure, in the posterior rhinoscopy^{18,19} and in the nasal endoscopy.^{15,29} Holmberg and Linder-Aronson¹⁴ concluded that the lateral cephalometric radiograph would give satisfactory results on the dimensions of the nasopharynx, although Vig²⁸ sent a letter to the author questioning this result and saying that the cephalometric radiograph was not adequate to evaluate nasopharyngeal airways. However, the research of those authors had a sample of 162 children, which is considered a relatively large sample and they found adenoid size values very close to the clinical findings after a posterior rhinoscopy, which is a very interesting result.

Apart from radiographic evaluation being the diagnostic exam mostly used in the medical literature to evaluate adenoid hypertrophy, it is also the most used method in planning orthodontic treatment. But doctors usually ask for cavum radiographs, while the orthodontists ask for lateral cephalometric radiographs. Both of them are lateral cranium radiographs, but the cephalometric x-ray is obtained by a standard method using the cephalostat to hold the patient's head in position. When obtaining the cavum radiograph, the absence of a head positioner allows the patient to move his head, and that requires more attention from the radiologist technician. According to Oliveira, Anselmo-Lima and Souza²⁵ small changes in head position at the moment the x-ray is being taken can result in important changes in the structures involved in the analysis of the degree of obstruction of the nasopharyngeal airways. Being so, this lack of standardization makes it im-

possible for the orthodontist to use the cavum radiograph, because the measurement analyses wouldn't be precise.

However, the results of the present study shows that the otorhinolaryngologists are not familiar with the cephalometric technique, since only two of the 12 involved doctors were familiar to this radiographic method. It is important to notice that when both radiographs were compared, most of them picked as the best view of the nasopharyngeal airways and adenoids the cephalometric radiograph (49.4% and 48.9%) and approximately one forth didn't see any difference in both of them (27.8% and 27.2%). This shows that the otorhinolaryngologists could use the same radiograph as the orthodontists, and the patient would not need to be submitted to two radiographs, since the major part of treatments involving mouth breathers are multidisciplinary.

Araújo Neto et al¹ affirmed that because of the variety and complexity of the measurement methods indicated for adenoid radiographic diagnosis many radiologists prefer to use the subjective analysis. However, the present study showed that the subjective analysis had a low correlation with the measurement analysis, demonstrating that the subjective analysis is not precise. A large divergence was found among the doctors when classifying the size of the nasopharyngeal airways and adenoids by the visual method. This suggests that the same radiograph could have different diagnoses depending on who is analyzing it. The diagnosis would be more precise if professionals used any measuring method in their routine.

In this study, the nasopharyngeal analysis was based in the work of Schulhof²⁶, because this method combines four different measurements of different researchers. The computerized result of the analyses of the nasopharyngeal airway was used, since this doesn't exclude the basic knowledge of anatomic structures, besides

diminishing the probabilities of errors, as observed by David and Castilho.⁷ To evaluate the method error Kappa indices were used, which demonstrated excellent correlation. This result was already expected because the professional was specialist in radiology with more than 5 years of clinical experience.

Regarding the results on the nasopharyngeal airway, the findings were included in the patterns of mouth breathers according to Handelman and Osborn¹², Linder-Aronson¹⁸ and Schulhof.²⁶ But the main objective of this study was not to verify the presence or not of adenoid hypertrophy, these measurements were only performed so they could be compared with the visual method used by the doctors.

There are several other measurement meth-

ods described in the literature, that the professional may use, according to which one he finds easier to learn or has the best quality. Wormand and Prescott³⁰ compared the methods most used when using the cavum radiograph, which are the Johanneson, Fujioka and Crepeau, and Cohen and Konak, and they found that the method of Cohen and Konak had the best results and the best efficiency, although the lack of standardization of the cavum radiograph may compromise the measurements.

If the cephalometric radiograph is used, there is the McNamara's²² and the Schulhof's²⁶ technique. Papers evaluating those methods are ambiguous. Kluemper, Vig and Vig¹⁷ concluded that both analyses are weak indicators of nasal obstruction when compared to clinical results,

but they didn't compare these methods with computerized tomography, which would be the ideal golden pattern.

It would be interesting that the otorhinolaryngologists started using the measurement methods that already exists and from there started to develop other methods better elaborated, more precise and easy to use, that could turn the diagnosis of nasopharyngeal airways and adenoids more precise.

Having in mind that the otorhinolaryngologists chose the cephalometric radiograph over the cavum, they should consider starting using this technique so they could ask for the same exam as the orthodontists. This would facilitate the dialog between both of them and diminish the cost and radiation for the patient.

CONCLUSION

The present study concluded that, according to the sample used, the otorhinolaryngologists are not familiar with the cephalometric radiograph and have the habit of diagnosing nasopharyngeal airway obstruction using the cavum radiograph with no measurement technique.

When both techniques were evaluated in a blind manner, most doctors chose the lateral cephalometric radiograph as the best one.

When the visual and the Schulhof measurement method were compared it could be seen that there was low correlation between them.

REFERENCES

1. Araújo Neto AS, Queiroz SM, Baracat ECE, Pereira IMR. A avaliação radiográfica da adenóide em crianças: métodos de mensuração e parâmetros da normalidade. *Radiol Bras*. 2004;37(6):445-8.
2. Balbani APS, Weber SAT, Montovani LC. Atualização em síndrome da apnéia obstrutiva do sono na infância. *Rev Bras Otorrinolaringol*. 2005 jan-fev;71(1):74-80.
3. Bontrager KL. Crânio e ossos do crânio. In: Bontrager KL. *Textbook of radiographic positioning and related anatomy*. 5ª ed. Rio de Janeiro: Guanabara Koogan; 2003. cap.12, p. 353-76.
4. Broadbent BH. A new X-ray technique and its application to orthodontic. *Angle Orthod*. 1931 Apr;1(2):45-66.
5. Cohen D, Konak S. The evaluation of radiographs of the nasopharynx. *Clin Otolaryngol Allied Sci*. 1985 Apr;10(2):73-8.
6. Crepeau J, Patriquin HB, Poliquin JF, Tetreault L. Radiographic evaluation of the symptom-producing adenoid. *Otolaryngol Head Neck Surg*. 1982 Sep-Oct;90(5):548-54.
7. David AF, Castilho JCM. Estudo comparativo entre os traçados manual e computadorizado da análise do espaço aéreo nasofaríngeo em radiografias cefalométricas laterais. *Ortodontia*. 1999 maio-ago;32(2):88-93.
8. Fujioka M, Young LW, Girdany BR. Radiographic evaluation of adenoidal size in children: adenoidal-nasopharyngeal ratio. *Am J Roentgenol*. 1979 Sep;133(3):401-4.
9. Gonçalves M, Haiter Neto F, Gonçalves A, Almeida SM. Avaliação radiográfica da cavidade nasofaríngea em indivíduos com idades entre quatro e dezoito anos. *Rev Odontol Univ São Paulo*. 1996 jan-mar;10(1):1-7.
10. Gurgel JA, Almeida RR, Dell'Aringa AR, Marino VCC. A terapia multidisciplinar no tratamento da respiração bucal e do hábito prolongado de sucção digital ou de chupeta. *Rev Dental Press Ortod Ortop Facial*. 2003 maio-jun;8(3):81-91.
11. Gurley WH, Vig PS. A technique for the simultaneous measurement of nasal and oral respiration. *Am J Orthod*. 1982 Jul;82(1):33-41.
12. Handelman CS, Osborne G. Growth of the nasopharynx and adenoid development from one to eighteen years. *Angle Orthod* 1976;46:243-59.
13. Harvold EP, Tomer BS, Vargervik K, Chierici G. Primate experiments on oral respiration. *Am J Orthod*. 1981 Apr;79(4):359-72.
14. Holmberg H, Linder-Aronson S. Cephalometric radiographs as a means of evaluating the capacity of the nasal and nasopharyngeal airway. *Am J Orthod*. 1979 Nov;76(5):479-90.

15. Ianni Filho D, Ravelli DB, Loffredo LCM, Gandini Júnior LG. Comparação entre endoscopia nasofaríngea e telerradiografia cefalométrica lateral no diagnóstico da obstrução do espaço aéreo nasofaríngeano. *Rev Dental Press Ortod Ortop Facial*. 2003 mar-abr;8(2):95-100.
16. Jóhannesson S. Roentgenologic investigation of the nasopharyngeal in children of different ages. *Acta Radiol Diagn (Stockh)*. 1968 Jul;7(4):299-304.
17. Klumper GT, Vig PS, Vig KW. Nasorespiratory characteristics and craniofacial morphology. *Eur J Orthod*. 1995 Dec;17(6):491-5.
18. Linder-Aronson S. Adenoids their effect on mode of breathing and nasal airflow and their relationship to characteristics of the facial skeleton and dentition. *Acta Otolaryngol Suppl*. 1970;265:1-132.
19. Linder-Aronson S, Henrikson CO. Radiocephalometric analysis of anteroposterior nasopharyngeal dimensions in 6 to 12 year-old mouth breathers compared with nose breathers. *ORL J Otorhinolaryngol Relat Spec*. 1973;35(1):19-29.
20. Lusvargui L. Identificando o respirador bucal. *Rev Assoc Paul Cir Dent*. 1999 jul-ago;53(4):265-74.
21. Major MP, Flores-Mir C, Major PW. Assessment of lateral cephalometric diagnosis of adenoid hypertrophy and posterior upper airway obstruction: a systematic review. *Am J Orthod Dentofacial Orthop*. 2006 Dec;130(6):700-8.
22. McNamara JA. Influence of respiratory pattern on craniofacial growth. *Angle Orthod*. 1981 Oct;51(4):269-300.
23. Montgomery WM, Vig PS, Staab EV, Matteson SR. Computed tomography: a three-dimensional study of the nasal air way. *Am J Orthod*. 1979 Oct;76(4):363-75.
24. Nascimento J. Técnica radiológica do cavum. In: Nascimento J. *Temas de técnicas radiológicas*. 2ª ed. Rio de Janeiro: Companhia Brasileira de Filmes Sakura; 1984. cap. 8, p. 91-3.
25. Oliveira RC, Anselmo-Lima WT, Souza BB. A importância da nasofibroscopia na presença do RX Cavum normal para diagnóstico da hiperplasia adenoideana. *Rev Bras Otorrinolaringol*. 2001 jul-ago;67(4):499-505.
26. Schulhof RJ. Consideration of airway in Orthodontics. *J Clin Orthod*. 1978 Jun;12(6):440-4.
27. Subtelny JD. The significance of adenoid tissue in orthodontia. *Angle Orthod*. 1954 Apr; 24(2):59-69.
28. Vig PS. Letter to the editor. *Am J Orthod*. 1975 Feb;67(2):139-58.
29. Vilella OV, Vilella BS, Karsten A, Ianni Filho D, Monteiro AA, Koch HA, et al. Evaluation of the nasopharyngeal free airway space based on lateral cephalometric radiographs and endoscopy. *Orthodontics*. 2004;1(3):215-23.
30. Wormald PJ, Prescott CAJ. Adenoids: comparison of radiological assessment methods with clinical and endoscopic findings. *J Laryngol Otol*. 1992 Apr;106(4):342-4.

Submitted: July 2008
Revised and accepted: September 2008

Contact address

Rhita Cristina Cunha Almeida
Av. das Américas, 3434 bl. 5 sala 223 - Barra da Tijuca
CEP: 22.640-102 - Rio de Janeiro / RJ, Brazil
E-mail: rhita.almeida@gmail.com

Comparison between cavum and lateral cephalometric radiographs for the evaluation of the nasopharynx and adenoids by otorhinolaryngologists

Rhita Cristina Cunha Almeida**, Flavia Artese***, Felipe de Assis Ribeiro Carvalho**, Rachel Dias Cunha****, Marco Antonio de Oliveira Almeida*****

Abstract

Introduction: The lateral cephalometric, as well as the cavum radiograph, allow the evaluation of the nasopharyngeal airway (NAW). Otorhinolaryngologists routinely use the cavum radiograph, even when the patient already has a lateral cephalometric headfilm. **Objectives:** The aim of this study was to (a) acknowledge which exams otorhinolaryngologists use for the evaluation and measurement of the NAW; (b) evaluate if the otorhinolaryngologists are acquainted to the cephalometric method; (c) compare both radiographs to see which one is preferred to visualize the NAW and adenoids and (d) correlate the visual analysis to the measuring method of Schulhof. **Methods:** For this purpose, cephalometric and cavum radiographs of 15 mouth-breathing children were taken on the same day. These radiographs were masked leaving only the NAW and the adenoids visible, and were blindly presented to 12 otorhinolaryngologists. They received the radiographs together with a questionnaire asking about their familiarity with the lateral cephalometric radiograph, which exams are used for NAW and adenoid evaluation and if they use any method for measuring the NAW obstruction level. They were also asked to visually classify the NAW and the adenoids according to their sizes into small, medium and large. **Results:** The results demonstrated that all otorhinolaryngologists in the sample use the cavum radiograph. Only one uses the cephalometric radiograph and two are familiar with this technique. The cephalometric radiograph was preferred by 49.4% of the otorhinolaryngologists, the cavum by 22.8%, and 27.8% did not see any difference between both methods. There was low correlation between the visual method and the Schulhof measuring method.

Keywords: Orthodontics. Otorhinolaryngology. Cavum radiograph. Cephalometric radiograph.

* Access www.dentalpress.com.br/journal to read the full article.

** MSc in Orthodontics, State University of Rio de Janeiro (UERJ), Specialist in Orthodontics, UERJ.

*** Associate Professor, Department of Orthodontics, UERJ.

**** Specialist in Otorhinolaryngology.

***** Head Professor, Department of Orthodontics, UERJ.

Editor's summary

The radiographic evaluation, besides being the most used method in the medical literature to evaluate hypertrophy of adenoids, is also the most used method to plan an orthodontic treatment. But the doctor normally uses the cavum radiograph and the orthodontist uses the lateral cephalometric radiograph. Both are lateral radiographs of the cranium but the cephalometric radiograph is standardized by stabilizing the patient's head with a cephalostat. In the cavum radiograph, the lack of the cephalostat during the exam allows the patient to alter head position, which requires more attention during its acquisition.

The results of the present study showed that the otorhinolaryngologists have little knowledge

of the cephalometric technique, since only two of the twelve doctors interviewed knew this radiographic method. It's important to say that when both techniques were compared, most doctors picked as best view of the nasopharyngeal airway and adenoids the cephalometric radiograph (49.4% and 48.9%) and one fourth of the otorhinolaryngologists didn't see any difference between both techniques for the two analyzed structures (27.8% and 27.2%).

This study also evaluated if the visual method used by the otorhinolaryngologists in the diagnoses of adenoid hypertrophy was compatible with the results found by measuring those anatomical structures with the Schulhof's method (1978). A low correlation between those two methods was found.

Questions to the authors

1) What evaluation techniques would result in a higher number of diagnoses of nasopharyngeal obstruction, the quantitative evaluation by the method reported or the visual assessment used by otorhinolaryngologists?

There are no differences among the number of possible diagnoses. The difference between the methods is related to the reproducibility of the diagnoses. Using the quantitative analysis increases the chances of several professionals achieving the same diagnosis for a specific case or of a single professional giving the same diagnosis for a case in different periods of time. In the visual analysis the differences among the diagnoses increases.

2) Interdisciplinarity among orthodontists and otorhinolaryngologists could be a benefit to the patient?

Yes. Because both areas could work together for the well being of the patient, discussing the best time for each approach and not making the treatment time longer than it should be.

3) How to enable the interdisciplinarity between these areas?

Maybe elaborating interdisciplinary courses or with mouth breathers treatment centers that included orthodontics as one of the disciplines involved.

Contact address

Rhita Cristina Cunha Almeida
Av. das Américas, 3434 bl.5 sala 223. Barra da Tijuca
CEP: 22.640-102 - Rio de Janeiro / RJ, Brazil
Email: rhita.almeida@gmail.com