

## Challenge in the diagnosis of pulmonary strongyloidiasis

Desafio no diagnóstico de estrogiloidíase pulmonar

Andrea dos Santos Pereira<sup>1</sup>, Alexandre Gimenes Marques<sup>1</sup>, André Mario Doi<sup>1</sup>, Marinês Dalla Valle Martino<sup>1</sup>, Paula Célia Mariko Koga<sup>1</sup>, Vivian Renata Chiarato<sup>1</sup>, Liang Fung<sup>1</sup>, Rima Batah Martins<sup>1</sup>, Jacyr Pasternak<sup>1</sup>

<sup>1</sup> Hospital Israelita Albert Einstein, São Paulo, SP, Brazil.

DOI: 10.31744/einstein\_journal/2019AI4441

### How to cite this article:

Pereira AS, Marques AG, Doi AM, Martino MD, Koga PC, Chiarato VR, et al. Challenge in the diagnosis of pulmonary strongyloidiasis. *einstein* (São Paulo). 2019;17(1):eAI4441. [http://dx.doi.org/10.31744/einstein\\_journal/2019AI4441](http://dx.doi.org/10.31744/einstein_journal/2019AI4441)

### Corresponding author:

Alexandre Gimenes Marques  
Clinical laboratory  
Avenida Albert Einstein, 627/701, Building E  
2<sup>nd</sup> floor – Morumbi  
Zip code: 05652-900 – São Paulo, SP, Brazil  
Phone: (55 11) 2151-5555  
E-mail: alexandregm@einstein.br

### Received on:

Mar 1, 2018

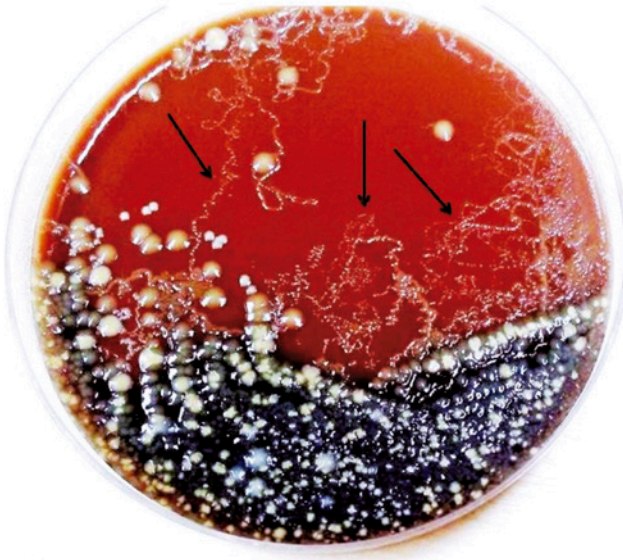
### Accepted on:

June 22, 2018

### Copyright 2018

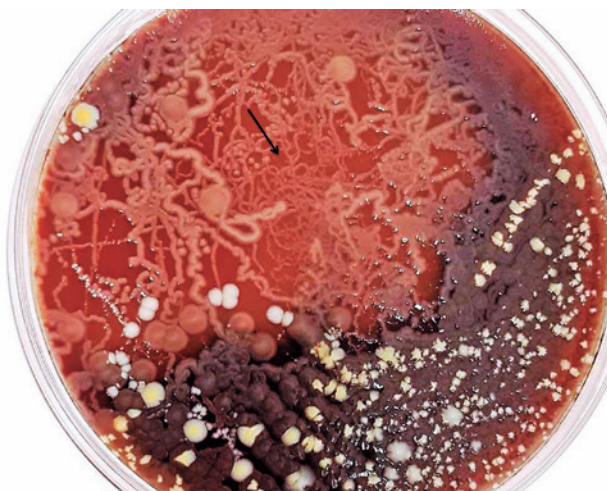

This content is licensed under a Creative Commons Attribution 4.0 International License.



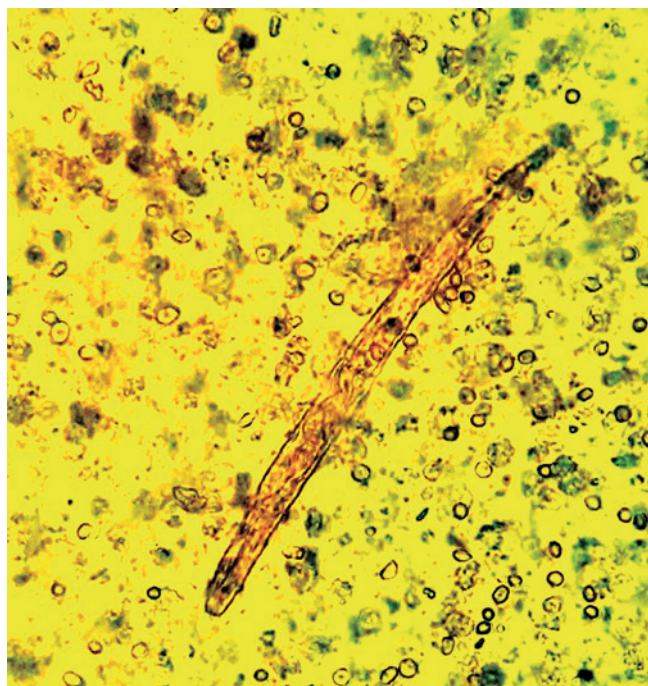
Line drawing among bacterial colonies (arrows).

**Figure 1.** Blood agar plate after a 24-hour incubation



Line drawing among bacterial colonies (arrows).

**Figure 2.** Blood agar plate after a 48-hour incubation



**Figure 3.** *Strongyloides stercoralis* larvae in fresh tracheal secretion.

A 33-years-old man was admitted to the intensive care unit because of alcoholic cirrhosis, cocaine toxicity, and septic shock to be accurately assessed. Further tests were requested.

His X-ray did not show compatible patterns with pulmonary strongyloidiasis, blood culture was positive for enterobacteria that produce *Klebsiella pneumoniae* carbapenemase (KPC), and discrete eosinophylin hemogram and tracheal secretion culture were observed.

In culture requested 6 days after interventions, a characterized and uncommon pattern polymicrobial flora growth was observed in culture medium. The phenomeum “traits” was observed (Figures 1 and 2), which suggests that something was moving between agar colonies, as reported by other authors.<sup>(1)</sup> In this culture, a fresh research was conducted and results confirmed the presence of larvae of *Strongyloides stercoralis* (Figure 3).

After this result, both the department of nosocomial infection and medical team were promptly communicated.

A treatment with ivermectine was administered. Although specific therapy for disseminated Strongyloidiasis was started, the patient died due to advanced clinical complications.

Strongyloidiasis is an infection caused by *Strongyloides stercoralis* helminthic parasite, which distribution occurs mainly in tropical and subtropical countries in rural and low-socioeconomic status areas. The infection has two life cycles: (1) free life cycle in which the larvae can penetrate the intact skin after contact with contaminated soil, and (2) in which the larvae migrates to the lungs, after, to pharynx, which is them swallowed, and become adult in the intestine and is released in the stools.

Both the physician and the microbiology laboratory should carefully follow-up the microorganism growth in immunosuppressed patients, which is uncommon in culture of immunocompetent patients. In our case, the microscopy of fresh material was fundamental to elucidate the diagnosis, once the *strongyloides* research was not initially requested. This infection can be fatal for immunosuppressed individuals.<sup>(2,3)</sup>

#### AUTHORS' INFORMATION

Pereira AS: <http://orcid.org/0000-0001-7023-2462>  
 Marques AG: <http://orcid.org/0000-0001-8773-8515>  
 Doi AM: <http://orcid.org/0000-0002-0722-1880>  
 Martino MD: <http://orcid.org/0000-0003-4801-7226>  
 Koga PC: <http://orcid.org/0000-0001-5069-5718>  
 Chiarato VR: <http://orcid.org/0000-0002-8488-5904>  
 Fung L: <http://orcid.org/0000-0001-8806-9827>  
 Martins RB: <http://orcid.org/0000-0001-8240-0697>  
 Pasternak J: <http://orcid.org/0000-0003-2428-8873>

#### REFERENCES

1. Kia EB, Mahmoudi M, Zahabiun F, Meamar AR. An evaluation on the efficacy of agar plate culture for detection of *strongyloides stercoralis*. *Iranian J Parasitol.* 2007;2(1):29-34.
2. Centers for Disease Control and Prevention (CDC). DPDx – Laboratory identification of parasites of public health concern. Strongyloidiasis [Internet]. USA: CDC; 2017 [cited 2018 June 20]. Available from: <https://www.cdc.gov/dpdx/strongyloidiasis/index.html>
3. Ash LR, Orihel TC. *Atlas of Human Parasitology*. 4th ed. Chicago: ASCP Press; 1997.