

# The hyperboloid device does not affect masticatory electromyographic activity during jaw movements in individuals with temporomandibular joint disorders

*A hiperboloide não influencia a atividade eletromiográfica dos músculos mastigatórios durante movimentos mandibulares em indivíduos com distúrbios temporomandibulares*

Kaline Zanoni 

Laís Lume 

Franciele Cabral Giasson 

Luana Borges 

William Dhein \*

Renata D'Agostini Nicolini-Panisson 

Centro Universitário da Serra Gaúcha, Caxias do Sul, RS, Brazil

**Date of first submission:** March 23, 2023

**Last received:** August 1, 2023

**Accepted:** August 17, 2023

\*Correspondence: willdhein@gmail.com

## Abstract

**Introduction:** The hyperboloid is a masticatory device made of silicone with an hourglass (hyperbolic) shape that has been used as an aid to jaw functional orthopedic therapy. **Objective:** To evaluate whether the hyperboloid device affects electromyographic (EMG) activity of the masticatory muscles during jaw movements in individuals with temporomandibular joint disorders (TMD) compared to controls. **Methods:** The study sample consisted of 49 participants divided into two groups: mild, moderate and severe TMD (TMD group; n = 25) and a control group (n = 24). We evaluated EMG activities of temporal and masseter muscles bilaterally during jaw protraction and retraction, and left and right lateralization with and without the use of the hyperboloid device. Statistical analyses were performed using two-way ANOVA with two factors: group (healthy and TMD) and situation (with or without the use of the hyperboloid). **Results:** We found higher EMG activity in the left temporal in the TMD group and no difference in EMG activities with the use of the hyperboloid device. **Conclusion:** The use of the hyperboloid device did not affect EMG activity of the muscles evaluated in the groups studied. We found higher EMG activity of the left temporal muscle in participants with TMD. Long-term randomized studies should be conducted in individuals with TMD to investigate the effects of functional orthopedic therapy using the hyperboloid device with visual and quantitative feedback.

**Keywords:** Electromyography. Hyperboloid device. Masticatory muscles. Physical therapy. Temporomandibular joint.

## Resumo

**Introdução:** O hiperboloide é um aparelho mastigatório feito de silicone com formato de ampulheta (hiperbólica), que tem sido utilizado como auxiliar na terapia ortopédica funcional da mandíbula. **Objetivo:** Avaliar se o dispositivo hiperbolóide afeta a atividade eletromiográfica (EMG) dos músculos mastigatórios durante os movimentos mandibulares em indivíduos com disfunção da articulação temporomandibular (DTM) em comparação com controles. **Métodos:** A amostra do estudo foi composta por 49 participantes divididos em dois grupos: DTM leve, moderada e severa (grupo DTM;  $n = 25$ ) e grupo controle ( $n = 24$ ). Avaliaram-se as atividades EMG dos músculos temporal e masseter bilateralmente durante a protração e retração da mandíbula e lateralização esquerda e direita com e sem o uso do dispositivo hiperboloide. As análises estatísticas foram realizadas por ANOVA two-way com dois fatores: grupo (saúdável e DTM) e situação (com ou sem uso do hiperbolóide). **Resultados:** Encontramos maior atividade EMG no temporal esquerdo no grupo DTM e nenhuma diferença nas atividades EMG com o uso do dispositivo hiperboloide. **Conclusão:** O uso do hiperboloide não afetou a atividade EMG dos músculos avaliados nos grupos estudados. Encontramos maior atividade EMG do músculo temporal esquerdo em participantes com DTM. Estudos randomizados de longo prazo devem ser conduzidos em indivíduos com DTM para investigar os efeitos da terapia ortopédica funcional usando o dispositivo hiperbolóide com feedback visual e quantitativo.

**Palavras-chave:** Eletromiografia. Dispositivo hiperbolóide. Músculos mastigatórios. Fisioterapia. Articulação temporomandibular.

## Introduction

The temporomandibular joint (TMJ) is a highly specialized anatomical structure that is part of the stomatognathic system and is associated with orthopedic, musculoskeletal and neurological impairments leading to temporomandibular disorders (TMD). The etiology of TMD is multifactorial and factors involved include malocclusion, mandibular or TMJ trauma, muscle alterations, parafunctional habits and emotional or postural problems. Common signs and symptoms of TMD are limited jaw opening, clicking or crepitus when opening or closing the mouth, ear ringing, vertigo and malocclusion.<sup>1-4</sup>

Patients with TMD may present with either acute pain and mild symptoms or chronic pain progressing to physical, behavioral, psychological and psychosocial symptoms.<sup>5</sup> The Fonseca Anamnestic Index (FAI) is a scale proposed by Fonseca et al.<sup>6</sup> to measure the severity of TMD symptoms. It is a simple, practical tool used for routine diagnosis and treatment of patients with TMD.<sup>6,7</sup>

Several studies have investigated whether there are differences in the electromyographic (EMG) activity of the masticatory muscles between individuals with TMD and healthy ones.<sup>8</sup> This subject area, however, is particularly challenging as studies have used different approaches for signal capture and different methods of analysis and surface electromyography signal capturing techniques.<sup>8</sup> A systematic review on this subject found no difference in EMG activity of the masticatory muscles between healthy individuals and those with TMD. Understanding EMG behavior is crucial for developing a functional jaw therapy plan.<sup>8</sup>

The hyperboloid is a masticatory device made of silicone with a hourglass (hyperbolic) shape that has been used as an aid to jaw functional orthopedic therapy.<sup>9</sup> It has been used for treating individuals with TMD, but the results available are from case reports: one focused on TMD and neurological diagnosis of cerebral palsy,<sup>10</sup> and another examined musculoskeletal conditions associated with TMD.<sup>11</sup>

The hyperboloid device has been available for over 35 years. Its application helps rebalancing TMJ structures by strengthening or stretching the masticatory muscles, relocating the articular disc to a normal anatomical position, and promoting relaxation and pain relief of painful structures.<sup>9</sup>

In addition, the hyperboloid device can be employed as an aid to normal orodental development, abnormal occlusion and bruxism. It allows non-traumatic exercises because its hardness and texture are consistent with the optimal force applied during mastication.<sup>9,10,12</sup> It promotes proprioceptive stimulation in the dentoalveolar nerve, spindles, and Golgi tendon organs and jaw movements through a complex system of neuromuscular pathways controlled by sensory afferent fibers innervating the oral cavity, muscles and joints leading to muscle toning responses, muscle activity modulation, biomechanical bone stimulation and stimulation of adjacent structures (salivary glands) and growth and development of the stomatognathic system.<sup>9</sup>

Given that there are very few studies examining EMG activity of the masticatory muscles with the use of the hyperboloid device and most of them are of low methodological quality, the objective of the present study was to evaluate whether the hyperboloid device affects EMG activity of the masticatory muscles during jaw movements in individuals with TMD compared to controls.

## Methods

This is a quantitative observational and cross-sectional study conducted at the Integrated Health Center at Centro Universitário da Serra Gaúcha, in Caxias do Sul city, Brazil. Patients of both sexes aged 18-60 years diagnosed with TMD based on the FAI (score > 20) were included in the TMD group.<sup>6,7</sup> The FAI is a questionnaire for characterizing the severity of TMD (no TMD, mild, moderate and severe). Patients on pain medication, using orthodontic appliances and with facial fractures were excluded. Individuals aged 18 years or more with preserved range of motion were included in the control group. Those who reported TMJ pain and/or dysfunction, use of orthodontic appliances and missing teeth in the dental arch were excluded. We calculated the sample size using G\*Power version 3.1.9.2 based on the following criteria: effect size of 0.38, 5% error probability, and statistical power of 0.8 for ANOVA (F).<sup>13</sup> The sample size required to meet these criteria was 50 individuals.

The study was approved by Centro Universitário da Serra Gaúcha research ethics committee (protocol # 3508384) and followed the ethical considerations of the Brazilian National Health Council as well as the principles of the Declaration of Helsinki. Informed consent has been obtained from all individuals included in this study.

### Study procedures

Data collections were performed at the physical therapy clinic of the Integrated Health Center at Centro Universitário da Serra Gaúcha, where initially the participants sign an informed consent form and answered a sociodemographic questionnaire. Once this stage was concluded, the participant began the procedures for the electromyographic evaluation. EMG data were obtained using a measuring device for EMG (Miotec) with 4-channel 32-bit A/D converter connected to a notebook (Samsung). Miotec Suite

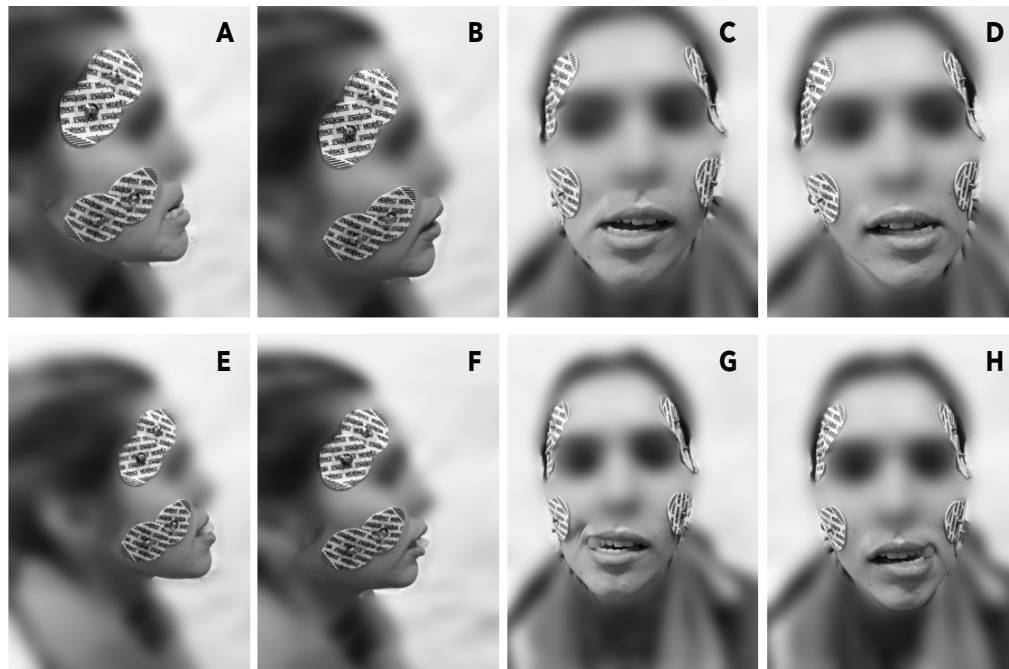
program was used with a sampling rate of 2,000 Hz.

To collect the data all participants were comfortably seated in a chair with their back supported, keeping their head in a neutral position, eyes open, feet on the floor and hands resting on the lower limbs. After they were positioned, their skin was prepared for EMG electrode placement, which included shaving and cleaning with cotton balls containing 70% alcohol. This procedure was carried out using sterilized gloves. After skin preparation, surface electrodes (Ag/AgCl) were placed for bipolar EMG recording on the right masseter (RM), left masseter (LM), right temporal (RT) and left temporal (LT) muscles.<sup>14</sup> The reference electrode was placed on the participant's right clavicle.

All participants were instructed to perform maximal voluntary isometric contractions (MVICs). Using sterile gloves, the evaluator placed cotton rolls bilaterally between the upper and lower dental arches. They were then instructed to clench on the cotton rolls performing maximum bite force (maximum occlusion). MVIC collection consisted of two MVICs maintaining contraction for 5 seconds two minutes apart.<sup>15</sup>

After MVIC data were collected, all participants were asked to execute some jaw movements to become familiar with them. They then executed the following jaw movements: protraction (Figure 1A); retraction (Figure 1B); right lateralization (Figure 1C); and left lateralization (Figure 1D). These same movements were then performed applying a medium-size hyperboloid device. The hyperboloid was placed on incisor teeth during jaw protraction (Figure 1E) and retraction (Figure 1F) and on premolar teeth during left and right lateralization (Figure 1G/H). The participants were instructed to exert minimum pressure on the hyperboloid while holding and moving it. At the end of the exercise, all electrodes were removed and their skin was cleaned and the participants completed their participation in the study.

EMG data were analyzed using Miotec Suite and Biomec-SAS program.<sup>16</sup> MVIC data and EMG signals collected during mandibular movements were filtered using a band-pass of 20-400 Hz and a 4th order Butterworth filter. After filtering the data, jaw movement repetitions were removed. For MVICs, peak RMS envelope value were obtained for each muscle evaluated. From the calculated RMS envelope values, EMG signals were analyzed with time-domain root mean square with a hamming windowing of 1 second. RMS value for each muscle evaluated was normalized to the ratio of RMS value to peak MVIC.



**Figure 1** - Electrode positioning and temporomandibular joint movements without the use of the hyperboloid device: (A) protraction, (B) retraction, (C) right lateralization, (D) left lateralization. Illustrations of jaw movements with the use of the hyperboloid device: (E) protraction, (F) retraction, (G) right lateralization, (H) left lateralization.

### Statistical analysis

All statistical analyses were performed using Statistical Package for the Social Sciences (SPSS version 25.0). We tested the normality of the data using the Shapiro-Wilk test and homogeneity of variances with Levene test. Mauchly's sphericity test was used to test sphericity, and the Greenhouse-Geisser correction was used when the assumption of sphericity was violated. We performed two-way ANOVA using two factors: group (healthy; TMD) and situation (with and without the use of the hyperboloid device) for each of the four muscles evaluated (RT, LT, RM and LM). When there was a significant difference for the main factors of ANOVA, a Bonferroni post hoc test was performed to explore the differences. We set the significance level at  $\alpha = 0.05$  for all tests.

### Results

The initial sample included 50 participants, but one participant in the control group was excluded due to issues in EMG data analysis. Therefore, we evaluated

25 participants in the TMD group and 24 in the control group. Table 1 shows the characteristics of the study participants.

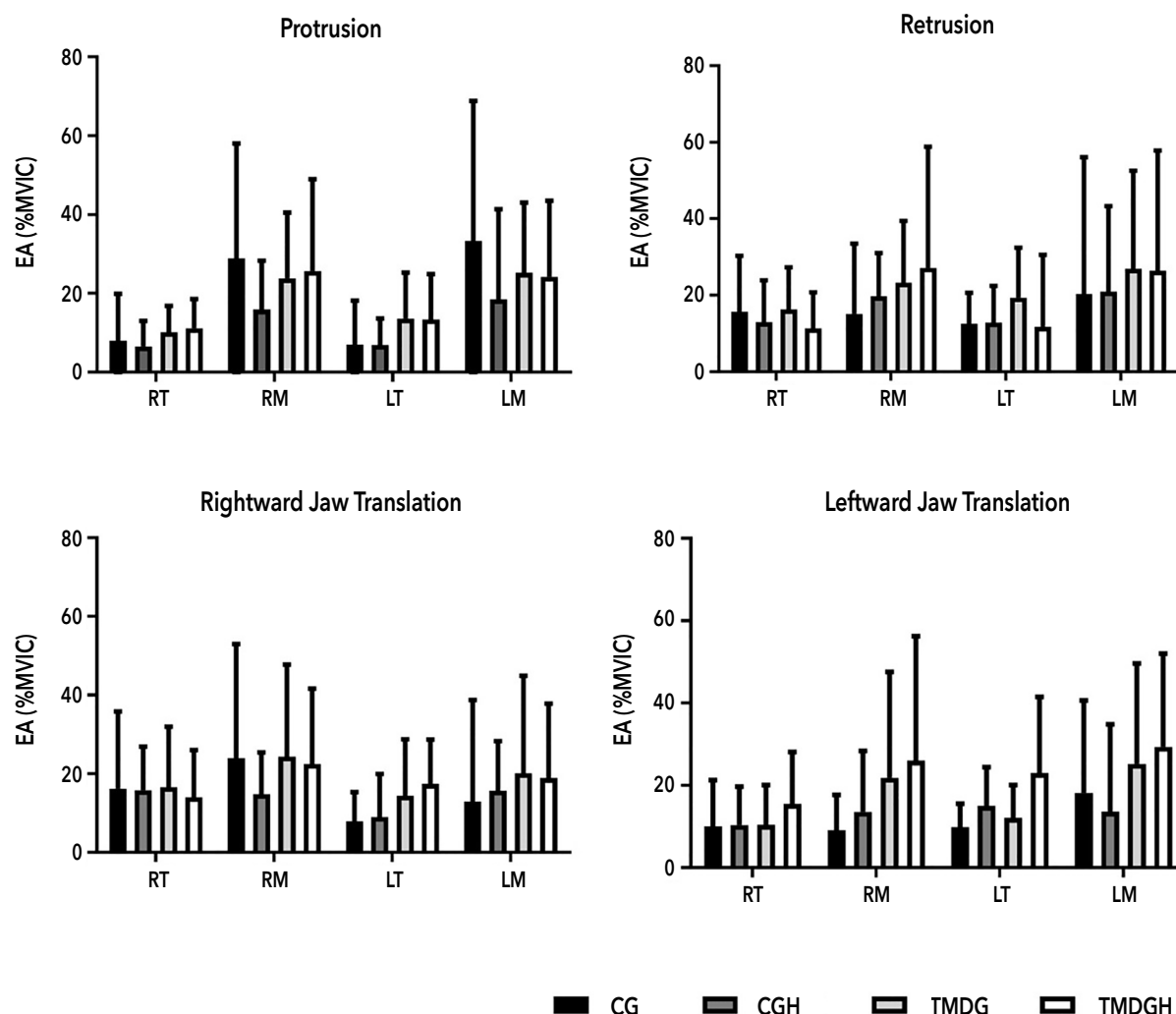
**Table 1** - Characteristics of the study participants

Characteristics	CG (n = 24)	TMDG (n = 25)
Age (years)	29.8 ± 10.2	39.8 ± 12.7
Body weight (kg)	75.0 ± 15.5	78.0 ± 15.8
Height (m)	1.7 ± 0.1	1.7 ± 0.1
Smoking	3 (12.5)	1 (4.0)
Physically active	15 (62.5)	19 (76.0)
Ongoing medication use	6 (25.0)	16 (64.0)
FAI	-	48.0 ± 16.6
Min-max	-	25-80
Mild	-	12 (48.0)
Moderate	-	9 (36.0)
Severe	-	4 (16.0)

Note: Continuous variables presented as mean ± standard deviation. Categorical variables presented as absolute frequency n (relative frequency %). CG = control group; TMDG = temporomandibular disorder group; FAI = Fonseca Anamnestic Index.

As for the group factor, there were no differences in EMG activity for RT [F (1.376) 0.699;  $p = 0.404$ ], RM [F (1.376) 2.570;  $p = 0.110$ ] and LM muscles [F (1.376) 0.254;  $p = 0.615$ ]. However, we found a significant difference for LT muscle in the main factor of ANOVA [F (1.376) 11.537;  $p = 0.001$ ] with higher EMG activity in the

TMD group (Figure 2). As for the use of the hyperboloid device during jaw movements, we found no significant difference for any of the muscles evaluated: RT [F (1.376) 0.029;  $p = 0.866$ ], RM [F (1.376) 0.710;  $p = 0.400$ ], LM [F (1.376) 0.889;  $p = 0.346$ ] and LT [F (1.376) 11.537;  $p = 0.001$ ] (Figure 2).



**Figure 2** - Electromyographic activity (EA) of the right temporal (RT), right masseter (RM), left temporal (LT), left masseter (LM) muscles during jaw movements with and without the use of the hyperboloid device.

Note: MVIC = maximal voluntary isometric contractions; CG = control group; CGH = control group with the use of the hyperboloid device; TMDG = temporomandibular disorder group; TMDGH = temporomandibular disorder group with the use of the hyperboloid device.

## Discussion

In this study we evaluated EMG activity of the masticatory muscles during jaw protraction, retraction and bilateral lateralization in healthy individuals and those with TMD and found no difference in the activation of the masseter and RT and LT muscles with and without the use of the hyperboloid device. Yet it is challenging to discuss this finding because few studies have analyzed electromyographic activity of the jaw muscles and most have focused on maximum occlusion and mastication. In addition, very few studies have examined the use of a hyperboloid device.<sup>10,11</sup> One case report analyzed EMG activity of the jaw closing muscles during MVIC and at rest for the management of bruxism in a child with cerebral palsy. They evaluated EMG before and after nine months of functional jaw therapy using the hyperboloid device and found improved electrical activity of the masticatory muscles and reduced sleep bruxism.<sup>10</sup> In another case report, a patient with systemic lupus erythematosus reporting TMJ pain underwent 8-week therapy using the hyperboloid device, which resulted in increased mandibular mobility and reduced pain.<sup>11</sup>

A comparison of our results with existing literature is difficult because this is a pioneer study evaluating the electrical activity of the masticatory muscles using the hyperboloid device. One study reported that long-term use of the hyperboloid device can increase mandibular mobility, reduce pain in the masseter muscles and improve mastication in a patient with TMD.<sup>11</sup> Reduced EMG hyperactivity of the RT and RM masseter muscles and greater symmetry of the masticatory muscles during maximal occlusion and jaw rest have also been reported in a child with cerebral palsy and bruxism.<sup>10</sup> However, these are case reports with limited results.

In our study, we found no effect of the use of the hyperboloid device on any of the masticatory muscles evaluated. We expected there would be an increase in EMG activities of the masticatory muscles with the use of the hyperboloid because in addition to the jaw movements the participants executed a closing movement of the jaw to keep the hyperboloid in place. However, we can speculate that the degree of occlusion was variable in the sample studied. All participants were given the same verbal command to keep the hyperboloid device between their teeth, but they most likely understood this command differently

and responded with varying degrees of pressure on the device, which lead to great variability of EMG data. Future studies should evaluate the use of this device with visual and quantitative feedback to minimize the effect of this intervening variable.

As for the group factor (control group and TMD group), we found no difference in EMG activities of the RM, LM and RT muscles. Electromyographic activity is not different in individuals with TMD when compared to healthy individuals, except for the activity of the LT muscle. When we analyzed the activity of the LT muscle during four different jaw movements, we found greater activation in the TMD group when compared to the control group, which potentially characterizes excessive activation of this muscle. The finding of greater EMG activity of the LT muscle is consistent with that reported in the literature of EMG hyperactivity of this muscle during mastication,<sup>17</sup> as well as mandibular asymmetry during bite.<sup>18</sup> Another aspect reported in the literature is the difference between the masseter and sternocleidomastoid muscles, though they were not evaluated in our study. The finding of a difference in the LT muscle only supports an association with mandibular asymmetry. However, some studies have reported that people with pain may use the contralateral muscles during mastication and show greater activity leading to asymmetry.<sup>19</sup>

Another study evaluated EMG activity of the masticatory muscles at rest and during jaw movement in adult patients with different levels of oral motor impairment (cerebral palsy) compared to healthy patients. All EMG recordings were significantly higher at rest and during mouth opening in patients with cerebral palsy than those in the control group.<sup>20</sup>

The finding of no difference in the activity of the RT and masseter muscles between the groups is in line with that reported in a meta-analysis,<sup>8</sup> but these muscles were evaluated during biting rather than jaw movements as in the present study. Yet, the authors of this important meta-analysis stressed that there is no well-established protocol to collect and analyze data on the activity of the masticatory muscles, and that time point of data collection relative to muscle activation at rest, number of readings, type of muscle contraction evaluated, normalization of signal amplitude and type of electromyographic signal processing are all factors that may interfere with the results, making it difficult to compare results from different EMG studies.



The present study has some limitations. Occlusion with the hyperboloid device during jaw movements was not controlled and may have contributed to the variability of EMG activity data. Future studies should evaluate EMG activity using a hyperboloid device with force sensors to provide quantitative feedback and standardize the degree of occlusion. Another limiting aspect is that the participants showed different severity of TMD (mild, moderate and severe) assessed by the FAI. In addition, not all patients with TMJ dysfunction show EMG changes, which may have contributed to increased variability of results in this group. Furthermore, surface electromyographic evaluation of major masticatory muscles such as the medial and lateral pterygoid muscles is not practicable, which is a limiting factor for the analysis during jaw movements. Although the participants had the opportunity to become familiarized and learn how to use the hyperboloid device, there is a need to more rigorous control of this device, which may require more practice and time.

The practical implications of this study pose a paradox. On one hand, the fact that no differences in EMG activities were seen with the use of the hyperboloid device during jaw movements in healthy individuals and those with TMD is somewhat positive. Yet one should bear in mind that all jaw movements were performed without resistance load (an elastic band) attached to the hyperboloid. On the other hand, considering the finding of no EMG difference with and without the use of the hyperboloid device, one should wonder whether this device actually have an immediately therapeutic effect; but this result was obtained for the temporal and masseter muscles. The effect of the use of the hyperboloid on EMG activity in the medial and lateral pterygoid muscles and other muscles moving the mandible were not examined and are not known. Therefore, long-term randomized clinical trials with individuals with TMD should investigate the effects of the use of the hyperboloid device in a functional jaw therapy program.

## Conclusion

The use of the hyperboloid device did not affect EMG activity of the muscles evaluated in the groups studied. We found higher EMG activity of the LT muscle in participants with TMD. Long-term randomized

studies should be conducted in individuals with TMD to investigate the effects of functional orthopedic therapy using the hyperboloid device with visual and quantitative feedback.

## Authors' contributions

RANP and WD carried out the research problem and data interpretation. KZ, LL, LB and FCG carried out data collection and analysis. All authors wrote and approved the final version of the manuscript.

## References

1. Chaves TC, Oliveira AS, Grossi DB. Main instruments for assessing temporomandibular disorders, part II: diagnostic criteria; a contribution to clinicians and researchers. *Fisioter Pesqui.* 2008;15(1):101-6. [DOI](#)
2. Donnarumma MDC, Muzilli CA, Ferreira C, Nemr K. Disfunções temporomandibulares: sinais, sintomas e abordagem multidisciplinar. *Rev CEFAC.* 2010;12(5):788-94. [DOI](#)
3. Oliveira AS, Dias EM, Contato RG, Berzin F. Prevalence study of signs and symptoms of temporomandibular disorder in Brazilian college students. *Braz Oral Res.* 2006;20(1):3-7. [DOI](#)
4. American Society of Temporomandibular Joint Surgeons. Guidelines for diagnosis and management of disorders involving the temporomandibular joint and related musculoskeletal structures. *Cranio.* 2003;21(1):68-76.
5. Vilar EGS, Pereira ESBM, Eleutério RG, Trazzi BFM, Silva WS. Indicações cirúrgicas de deslocamento do disco articular da articulação temporomandibular. *Braz J Hea Rev.* 2020;3(5):13790-809. [DOI](#)
6. Fonseca DM, Bonfante G, Valle AL, Freitas SFT. Diagnóstico pela anamnese da disfunção craniomandibular. *RGO (Porto Alegre).* 1994;42(1):23-8.
7. Campos JADB, Gonçalves DAG, Camparis CM, Speciali JG. Confiabilidade de um formulário para diagnóstico da severidade da disfunção temporomandibular. *Rev Bras Fisioter.* 2009;13(1):38-43. [DOI](#)

8. Barros BM, Biasotto-Gonzalez DA, Bussadori SK, Gomes CAFP, Politti F. Is there a difference in the electromyographic activity of the masticatory muscles between individuals with temporomandibular disorder and healthy controls? A systematic review with meta-analysis. *J Oral Rehabil.* 2020;47(5):672-82. DOI
9. Cheida A. Hiperbolóide: instrumento de mastigação. *J Bras Ortodontia Ortop Maxilar.* 1997;2(11):49-53.
10. Giannasi LC, Batista SRF, Matsui MY, Hardt CT, Gomes CP, Amorim JBO, et al. Effect of a hyperbolide mastication apparatus for the treatment of severe sleep bruxism in a child with cerebral palsy: long-term follow-up. *J Bodyw Mov Ther.* 2014;18(1):62-7. DOI
11. Herpich CM, Gomes CAFP, El Hage Y, Gloria IPS, Amaral AP, Politti F, et al. Efeitos do hiperboloide masticator apparatus na desordem temporomandibular - Estudo de caso. *ConScientiae Saude.* 2015;14(4):641-5. DOI
12. Grossi DB, Chaves TC. Physiotherapeutic treatment for temporomandibular disorders (TMD). *Braz J Oral Sci.* 2015; 3(10):492-7. Full text link
13. Espírito Santo H, Daniel F. Calcular e apresentar tamanhos do efeito em trabalhos científicos (1): as limitações do  $p < 0,05$  na análise de diferenças de médias de dois grupos. *Rev Port Invest Comport Social.* 2015;1(1):3-16. DOI
14. Politti F, Casellato C, Kalytczak MM, Garcia MBS, Biasotto-Gonzalez DA. Characteristics of EMG frequency bands in temporomandibular disorders patients. *J Electromyogr Kinesiol.* 2016;31:119-25. DOI
15. Konrad P. The ABC of EMG - A practical introduction to kinesiological electromyography. Scottsdale, AZ: Noraxon INC USA; 2005. p. 30-5. Full text link
16. La Torre M. Desenvolvimento de um software para processamento e análise de sinais biológicos utilizados em biomecânica [dissertation]. Porto Alegre: Universidade Federal do Rio Grande do Sul; 2013.
17. Tartaglia GM, Lodetti G, Paiva G, De Felicio CM, Sforza C. Surface electromyographic assessment of patients with long lasting temporomandibular joint disorder pain. *J Electromyogr Kinesiol.* 2011;21(4):659-64. DOI
18. Pitta NC, Nitsch GS, Machado MB, Oliveira AS. Activation time analysis and electromyographic fatigue in patients with temporomandibular disorders during clenching. *J Electromyogr Kinesiol.* 2015;25(4):653-7. DOI
19. Santana-Mora U, Cudeiro J, Mora-Bermúdez M, Rilo-Pousa B, Ferreira-Pinho JC, Otero-Cepeda JL, et al. Changes in EMG activity during clenching in chronic pain patients with unilateral temporomandibular disorders. *J Electromyogr Kinesiol.* 2009; 19(6):e543-9. DOI
20. Matsui MY, Giannasi LC, Batista SRF, Amorim JBO, Oliveira CS, Oliveira LVF, et al. Differences between the activity of the masticatory muscles of adults with cerebral palsy and healthy individuals while at rest and in function. *Arch Oral Biol.* 2017;73:16-20. DOI