

## Letter to the Editor

# Fluorescence in situ hybridization (FISH) in imprint of biopsies suspected of lymphoproliferative neoplasms: report on 17 cases



Dear Editor,

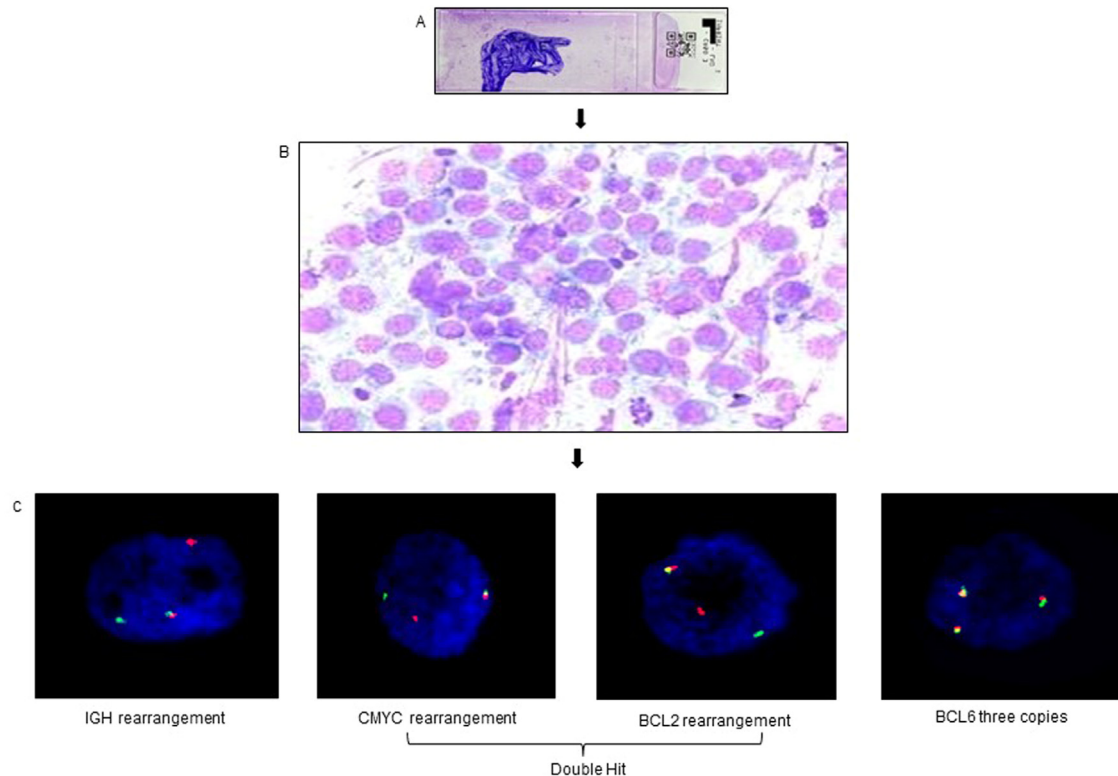
The diagnosis of lymphoproliferative neoplasms is mainly established by morphological and immunophenotypic aspects of Formalin-Fixed Paraffin Embedded (FFPE) tissue.<sup>1</sup> However, distinct genetic alterations have been specifically associated with some lymphoproliferative neoplasms, and its identification may be crucial for a complete diagnosis.<sup>2,3</sup> Fluorescence In Situ Hybridization (FISH) technique can be applied to different types of sample preparation, such as methanol–acetic acid fixed cells suspensions, tissue imprints and FFPE.<sup>4,5</sup> The FISH technique in dewaxed tissue sections is widely used and very challenging, depending on pre-analytical processes such as fixation and paraffinization; cell overlap is also an obstacle.<sup>6,7</sup> Due to these difficulties, we propose to validate the FISH technique in imprint of biopsies from several materials suspected of having lymphoproliferative neoplasms.

Imprint slides from 17 tissue samples: lymph nodes ( $n = 12$ ), muscle lesion, mediastinal mass, chest wall lesion, thyroid and lung ( $n = 1$ , each) with suspected lymphomas ( $n = 15$ ) or myeloid sarcoma ( $n = 2$ ) were performed by pathologists during excisional or core biopsy. Four to 5 imprint slides were prepared for each fragment, dried at room temperature and sent to the cytogenetic laboratory. One slide per case was stained with Rosenfeld dye and the others were stored at room temperature; FISH technique was performed within

90 days. The same probes already used for routine laboratory FISH in cell suspension were validated for this type of sample. Break apart *IGH* probe was performed in all cases and *CMYC*, *BCL2* and *BCL6* (break apart probes: CytoCell<sup>®</sup>, Cambridge, UK) were also used in two samples. Interphase FISH analysis was performed under a fluorescence microscope by two analysts with a total score of 100 nuclei, reference values previously established in bone marrow cell suspensions; *IGH*, *CMYC*, *BCL2*, *BCL6* rearrangements cut-offs were 8.5%, 11.9%, 4.6% and 6.0%, respectively.<sup>5,8</sup>

Hybridization was successful in all samples. Four of the six samples diagnosed with non-Hodgkin B cell lymphoma (NHL-B) presented *IGH* rearrangement, two also presented with *CMYC* and *BCL2* rearrangements (Diffuse B cell lymphoma double hit) (Figure 1). In one case of T cell NHL and one case of undifferentiated neoplasia, a gain in the *IGH* signal was observed. Two cases of Hodgkin Lymphoma, two thymomas, three reactive lymphoid proliferations and two myeloid sarcomas showed normal FISH *IGH* study (supplementary Table 1).

FISH in FFPE material is a useful technique, but dependent on pre-analytical factors and is limited by the smaller variety of commercial probes. This study validated the FISH technique in imprint of various tissues, showing to be easy to perform, score and interpret, being a quick and useful option for diagnostic purposes.



**Figure 1**–Diffuse large B-cell lymphoma, double hit (lymph nodes biopsy). (A) Imprint slide stained with Rosenfeld. (B) Lymph node shows neoplastic lymphoid cell (Rosenfeld,  $\times 500$ ). (C) Interphase FISH analyses using probes dual fusion break apart showing IGH, CMYC and BCL2 rearrangements (one normal fusion signal and one red and one green signals) and three copies of BCL6 gene (three fusion signals).

### Conflicts of interest

We have no conflict of interest to declare associated with this publication and as corresponding author, I confirm that the manuscript has been read and approved for submission by all the authors.

### Supplementary materials

Supplementary material associated with this article can be found in the online version at [doi:10.1016/j.htct.2023.01.008](https://doi.org/10.1016/j.htct.2023.01.008).

### REFERENCES

1. Swerdlow SH, Campo E, Harris NL, et al. WHO classification of tumours of haematopoietic and lymphoid tissues. 4th ed. Lyon, France: International Agency for Research on Cancer; 2008.
2. Savage KJ, Johnson NA, Ben-Neriah S, Connors JM, Sehn LH, Fariha P, et al. MYC gene rearrangements are associated with a poor prognosis in diffuse large B-cell lymphoma patients treated with R-CHOP chemotherapy. *Blood*. 2009;114(17):3533–7.
3. Tibiletti MG. Specificity of interphase fluorescence in situ hybridization for detection of chromosome aberrations in tumor pathology. *Cancer Genet Cytogenet*. 2004;155(2):143–8.
4. Tibiletti MG, Bernasconi B, Dionigi A, Riva C. The applications of FISH in tumor pathology. *Adv Clin Pathol*. 1999;3(4):111–8.
5. Garcia CH, Safranauskas RMDSO, Bezerra AMPS, Velloso EDRP. Cytogenetic studies for cMYC, BCL2 and BCL6 genes in neoplasm: comparison of karyotype, FISH in paraffin-embedded tissue and FISH in methanol-acetic acid-fixed cells suspensions. *Hematol Transfus Cell Ther*. 2021;43(4):521–6.
6. Hyytinen E, Visakorpi T, Kallioniemi A, Kallioniemi OP, Isola JJ. Improved technique for analysis of formalin-fixed, paraffin-embedded tumors by fluorescence in situ hybridization. *Cytometry*. 1994;16(2):93–9.
7. Haralambieva E, Banham AH, Bastard C, Delsol G, Gaulard P, Ott G, Pileri S, Fletcher JA, Mason DY. Detection by the fluorescence in situ hybridization technique of MYC translocations in paraffin-embedded lymphoma biopsy samples. *Br J Haematol*. 2003;121(1):49–56.
8. Tanizawa RS, Kumeda CA, de Azevedo Neto RS, Leal AM, Ferreira PB, Velloso ED. Karyotypic and fluorescent in situ hybridization study of the centromere of chromosome 7 in secondary myeloid neoplasms. *Rev Bras Hematol Hemoter*. 2011;33(6):425–31.

Roberta Maria da Silva Oliveira Safranauskas <sup>1</sup>, Denise da Cunha Pasqualin <sup>2</sup>, Renata Kiyomi Kishimoto <sup>3</sup>, Maria Marta Silva <sup>4</sup>, Cristina Kaori Oki <sup>5</sup>, Renee Zon Filippi <sup>6</sup>, Alanna Mara Pinheiro Sobreira Bezerra <sup>7</sup>, Elvira Deolinda Rodrigues Pereira Velloso <sup>8</sup>  
Hospital Israelita Albert Einstein, São Paulo, SP, Brazil

\*Corresponding author at: Hospital Israelita Albert Einstein, Av. Albert Einstein, 627/701 – Morumbi, 05652-900 São Paulo, SP, Brazil.

E-mail addresses: [roberta\\_oliveiras@yahoo.com.br](mailto:roberta_oliveiras@yahoo.com.br) (R.M.d.S.O. Safranauskas), [denise.pasqualin@einstein.br](mailto:denise.pasqualin@einstein.br) (D.d.C. Pasqualin), [renata.kishimoto@einstein.br](mailto:renata.kishimoto@einstein.br) (R.K. Kishimoto), [maria.marta@einstein.br](mailto:maria.marta@einstein.br) (M.M. Silva), [cristina.oki@einstein.br](mailto:cristina.oki@einstein.br) (C.K. Oki), [renee.filippi@einstein.br](mailto:renee.filippi@einstein.br) (R.Z. Filippi), [alaninamara@gmail.com](mailto:alaninamara@gmail.com) (A.M.P.S. Bezerra), [elvira.veloso@yahoo.com.br](mailto:elvira.veloso@yahoo.com.br) (E.D.R.P. Velloso).

Received 21 November 2022

Accepted 29 January 2023

Available online 9 March 2023

<https://doi.org/10.1016/j.htct.2023.01.008>  
2531-1379/

© 2023 Associação Brasileira de Hematologia, Hemoterapia e Terapia Celular. Published by Elsevier España, S.L.U. This is an open access article under the CC BY-NC-ND license (<http://creativecommons.org/licenses/by-nc-nd/4.0/>).