



Images in Clinical Hematology

Acute monocytic leukaemia with histiocytic differentiation and erythrophagocytosis

Verónica Roldán Galiacho ^{a,*}, Xabier Martin Martitegui ^a,
Maite Moreno Gamiz ^a, Javier Arzuaga-Mendez ^{a,b}, Elena Amutio ^{a,b},
Juan Carlos García-Ruiz ^{a,b}

^a Cruces University Hospital, Barakaldo, Bizkaia, Spain

^b BioCruces Health Research Institute, Barakaldo, Bizkaia, Spain

ARTICLE INFO

Article history:

Received 23 June 2022

Accepted 16 November 2022

Available online 5 December 2022

A 66-year-old man presented with hematuria. On admission, laboratory test revealed: hemoglobin 132 g/L, leukocytes $15.3 \times 10^9/L$, platelets $41 \times 10^9/L$, fibrinogen 0,97 g/L (normal range 1.8–4.0 g/L), prothrombin ratio 1.46 (0.8–1.2), D-dimer 26,300ng/mL (<500 ng/mL) and lactate dehydrogenase 4234 U/L (26–245). Peripheral blood smear showed atypical monocytoid cells and 2% of blast cells. With suspicion of acute promyelocytic leukaemia, we started all-transretinoic acid (ATRA) treatment.

Bone marrow aspirate showed a hypercellular marrow with a heterogeneous blast population: large cells with fine chromatin and irregular basophilic cytoplasm with vacuoles; large cells with foamy cytoplasm, which were compatible

with histiocytes; medium size blastic cells including promonocytes and mature monocytes (Figure 1A-B). Figures of mitosis and erythrophagocytosis by leukemic blasts were frequently observed (Figures 1C-D). Cytochemical staining with alpha-naphthyl acetate esterase activity (Figure 1E) and periodic acid-Schiff (Figure 1F) were positive and myeloperoxidase (MPO) was negative. Immunophenotype showed an increase in monocytic population (CD33+, CD13+, CD11b+, CD4+, HLADR+) without aberrancies (CD2-, CD7-, CD56-) and with predominance of mature monocytes (71% CD14++). Bone marrow biopsy was done to confirm the suspicion of a histiocytic component. Pathological analysis showed a massive infiltration by CD68, CD163, CD4, CD15 and lysozyme positive cells, confirming the diagnosis of acute monocytic leukemia. Cytogenetic analysis displayed a normal karyotype and nested RT-PCR to dismiss KAT6A-CREBBP rearrangement was negative.

With these results, we stopped ATRA and we began cytarabine and idarubicin induction chemotherapy but the disease was refractory to induction and also to other salvage treatments. Finally, the patient received azacitidine achieving complete response with ulterior consolidation with a

* Corresponding author at: Department of Hematology, Cruces University Hospital, Barakaldo, Bizkaia, 48903, Spain.

E-mail addresses: veronica.roldangaliacho@osakidetza.eus (V. Roldán Galiacho), xabier.martinmartitegui@osakidetza.eus (X. Martin Martitegui), maite.morenogamiz@osakidetza.eus (M. Moreno Gamiz), javier.arzuagamendez@osakidetza.eus (J. Arzuaga-Mendez), mariaelena.amutiodiez@osakidetza.eus (E. Amutio), juancarlos.garcia Ruiz@osakidetza.eus (J.C. García-Ruiz).

<https://doi.org/10.1016/j.htct.2022.11.007>

2531-1379/© 2022 Associação Brasileira de Hematologia, Hemoterapia e Terapia Celular. Published by Elsevier España, S.L.U. This is an open access article under the CC BY-NC-ND license (<http://creativecommons.org/licenses/by-nc-nd/4.0/>).

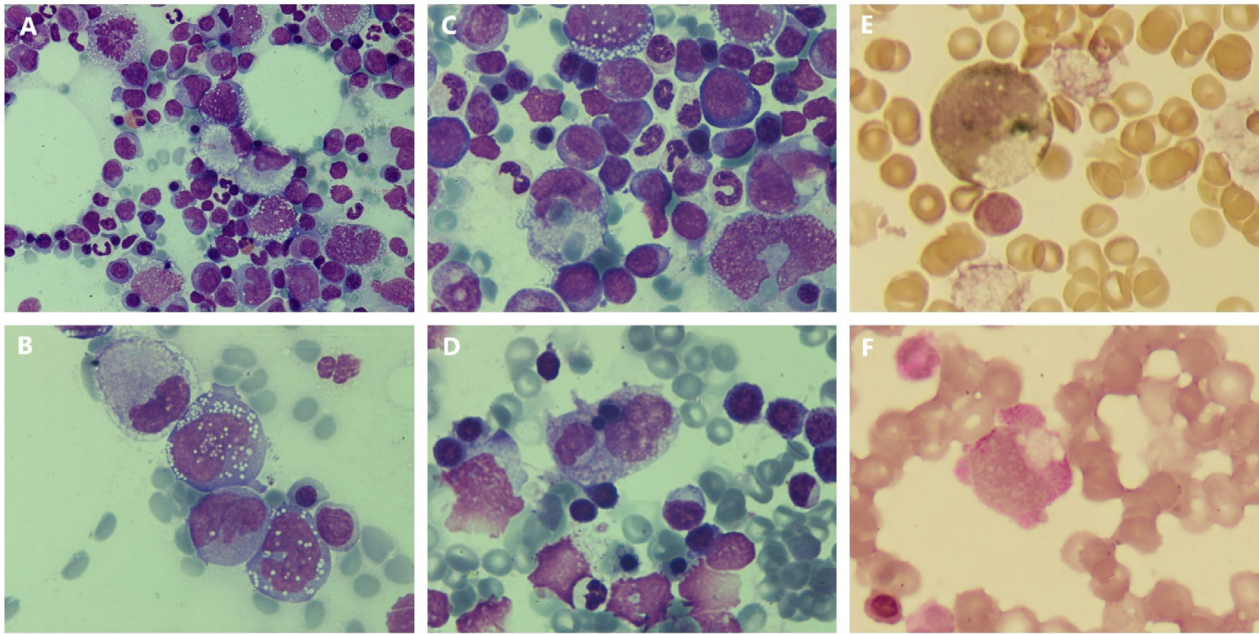


Figure 1 – (A) Hypercellular bone marrow with heterogeneous blast population (May-Grünwald Giemsa x50 objective). (B) Heterogeneity of blasts (MGG x100 objective). (C and D) Phagocytosis by blasts with histiocytic morphology (MGG x100). (E) Large blast with histiocytic morphology positive to alpha-naphthyl acetate esterase (x100 objective). (F) Blast with histiocytic features positive to periodic acid-Schiff (x100 objective).

haploidentical hematopoietic stem cell transplantation and remains alive two years after the procedure.

Erythrophagocytosis by leukemic blasts is an extremely rare phenomenon that could be seen in leukemias with monocytic differentiation with rearrangements involving KAT6A gene and sometimes this leukaemia due its clinical course is confused with acute promyelocytic leukemia.¹ Hemophagocytosis has also been described in leukemias with histiocytic morphology.²⁻⁴

Leukemia with histiocytic differentiation is an unusual morphologic variant of acute monocytic leukemia. The phenotypic markers of these leukemias are CD68, CD11b, CD11c, CD14, CD4, and lysozyme.^{2,5}

This case emphasizes, the importance of integrated diagnosis, were the morphology as well as the cytochemistry continue having a crucial role in the diagnosis of malignant hemopathies.

Conflicts of interest

The authors of this paper have no conflicts of interest, including specific financial interests, relationships, and/or affiliations relevant to the subject matter or materials included.

REFERENCES

- Hastings A, Apperley JF, Nadal-Melsio E, Brown L, Bain BJ. Acute myeloid leukemia with a severe coagulopathy and t(8;16)(p11; p13). *Am J Hematol*. 2021 Jan;96(1):163–4. <https://doi.org/10.1002/ajh.25903>. Epub 2020 Jul 28. PMID: 32520413.
- Lauret FM, Chapuis B, Roux-Lombard P, Dayer JM, Beris P. Malignant histiocytosis in the leukaemic stage: a new entity (M5c-AML) in the FAB classification? *Leukemia*. 1994 Mar;8(3):502–6. PMID: 8127155.
- Esteve J, Rozman M, Campo E, Muñoz F, Urbano-Ispizua A, Rozman C. Leukemia after true histiocytic lymphoma: another type of acute monocytic leukemia with histiocytic differentiation (AML-M5c)? *Leukemia*. 1995 Aug;9(8):1389–91. PMID: 7643629.
- Sato S, Tamai Y. Acute monocytic leukemia with histiocytic morphology in hematological remission after azacytidine and venetoclax therapy. *Int J Hematol*. 2022 Mar;115(3):299–300. <https://doi.org/10.1007/s12185-022-03296-x>. Epub 2022 Feb 8. PMID: 35133573.
- Liu B, Li T. Relapsed acute monocytic leukemia presenting as histiocytic morphology. *Int J Hematol*. 2020 Nov;112(5):607–8. <https://doi.org/10.1007/s12185-020-02995-7>. Epub 2020 Sep 20. PMID: 32954486.