

# Endoscopic or Microscopic Tympanoplasty Advantages and Disadvantages: A Theory Domain Systematic Review

Ana Júlia Bianchini<sup>1</sup> Vitória Gabriela Berlitz<sup>1</sup> Aurenzo Gonçalves Mocelin<sup>1</sup>   
 Juliana Ferraz Ribeiro<sup>1</sup> João Gabriel Keruk<sup>1</sup> Rogério Hamerschmidt<sup>1</sup>

<sup>1</sup>Otorhinolaryngology Department, Universidade Federal do Paraná, Alto da Glória, Curitiba, PR, Brazil

Int Arch Otorhinolaryngol 2023;27(3):e528–e535.

Address for correspondence Aurenzo Gonçalves Mocelin, Medical Student, Universidade Federal do Paraná, Rua Padre Camargo, 285, Alto da Glória, Curitiba, PR, Zip Code: 80060-240, Brazil (e-mail: aurenzomocelin@gmail.com).

## Abstract

**Introduction** Tympanoplasty is a reparative surgery that has multiple indications. The aid of a microscope or an endoscope is necessary to carry out the procedure. The classic method utilizes the microscope; however, in the recent decades, the endoscope has been popular. Although many articles try to compare these two techniques, there is still no robust evidence that confirms the superiority of either technique. In the present work, we seek to perform a systematic review contribute with this discussion.

**Objectives** The present systematic review attempted to compare endoscopic and microscopic surgery techniques and to discover whether there would be superiority in the results of any of them, based on data currently available in the literature.

**Data Synthesis** The objectives of the present review were organized according to the PICO planning and strategy adapted for systematic reviews. The inclusion and exclusion criteria were established aiming to select only select primary data. The main medical databases were searched using an optimized search string with appropriate descriptors. The searched databases were MEDLINE, LILACS, SciELO, and EMBASE. A total of 99 studies were selected and 38 were fully assessed after the inclusion criteria were applied. All included articles were reviewed by all authors and their results were discussed and summarized.

**Conclusion** The endoscopic technique was shown to be a safer technique comparable in effectiveness to the use of microscopy. In addition, it provides possible advantages such as shortening the surgical time and better postoperative pain outcomes.

## Keywords

- ▶ tympanoplasty
- ▶ endoscopes
- ▶ microsurgery
- ▶ otologic surgical procedure
- ▶ natural orifice endoscopic surgery

## Introduction

Endoscopes were used for the first time in the context of otorhinolaryngology in cholesteatoma removal procedures and myringoplasties.<sup>1</sup> They are currently used as a primary or auxiliary device in a variety of middle ear procedures, including tympanoplasty, ossiculoplasty, and cochlear im-

plant surgery.<sup>2-4</sup> The microscopic technique is still widely used, since it has considerable advantages, such as stereoscopic vision together with amplified surgical vision, and the possibility of using the two hands of the surgeon to handle the equipment, facilitating the removal of blood from the operative field during the procedures.<sup>5</sup> However, characteristics of microscopes such as narrow-angle vision and

received  
February 16, 2022  
accepted  
March 21, 2022  
article published online  
July 13, 2022

DOI <https://doi.org/10.1055/s-0042-1748808>.  
ISSN 1809-9777.

© 2022. Fundação Otorrinolaringologia. All rights reserved.  
This is an open access article published by Thieme under the terms of the Creative Commons Attribution-NonDerivative-NonCommercial-License, permitting copying and reproduction so long as the original work is given appropriate credit. Contents may not be used for commercial purposes, or adapted, remixed, transformed or built upon. (<https://creativecommons.org/licenses/by-nc-nd/4.0/>)  
Thieme Revinter Publicações Ltda., Rua do Matoso 170, Rio de Janeiro, RJ, CEP 20270-135, Brazil

straight field of view do not allow a wide observation of more hidden areas of the middle ear, such as the facial recess, the attic, the epitympanum, and the tympanic sinus, requiring the performance of procedures such as bone curettage or anterior canaloplasty, in addition to external incisions.<sup>6,7</sup> Endoscopes, especially angular ones, guarantee direct access to these hidden areas,<sup>8</sup> besides offering considerable benefits, such as panoramic view, high definition and magnification without loss of resolution, simplicity in obtaining zoom, and less chance of incisions or perforations, given that the light source is located at the tip of the endoscope itself.<sup>9</sup> In addition, the endoscopic approach, being minimally invasive, can guarantee more satisfactory results for patients<sup>10</sup> and a better chance of education for trainees during the procedures.<sup>11</sup> Therefore, it is still important to elucidate and clarify the relationship of relative benefits and disadvantages between the two techniques. In the present review, it is also discussed whether there would be superiority in the choice of any of them, to allow a more adequate choice for the surgeon, considering their technical experience, and for the patient, taking into account their medical indication and adequacy to the results and peri- and postoperative implications. The aim of the present study was to compare the benefits and disadvantages of each technique, endoscopic and microscopic, applied in tympanoplasty.

## Literature Review

### Research Protocol

The present systematic review was developed according to the Preferred Reporting Items for Systematic Reviews and Meta-Analyses (PRISMA) recommendations.<sup>12</sup> A PRISMA flow diagram was used to describe the flow of information throughout the various phases of the systematic review. The present study used qualitative methods to examine the results.

In the present study, the main question was to evaluate what were the benefits of endoscopic over microscopic tympanoplasty, with “to verify which method is safer, comparing the endoscopic technique with the microscopic one” as the primary objective and with “identify possible advantages and disadvantages of each technique, as well as possible benefits in choosing these treatments” as the secondary objective.

### PICO Strategy Adapted for Systematic Review

**Intervention** (what will be seen in the review): Raising of a hypothesis of primary data from studies that assess the benefits of endoscopic versus microscopic tympanoplasty treatment. **Control** (already established background, exploratory analysis): The endoscopic technique offers a less invasive access, as well as better visualization of the middle ear structures, which led to the hypothesis of safer procedures and better postoperative periods for patients, when compared with the microscopic technique. **Population** (group of articles that will be observed): Primary data articles that show the differences and benefits of endoscopic tympanoplasty compared with microscopic treatment.

**Expected results:** A list with plausible hypotheses that justify or explain the superiority of one treatment over another. **Application/Outcome** (who will benefit): The entire scientific community that seeks to better understand the advantages and benefits of one treatment over another and to assess the main issues that may support possible future research aimed at better understanding the physiology behind these benefits.

### Research Strategy

The authors searched the MEDLINE/PubMed, EMBASE, SciELO, and Lilacs databases for all available articles reporting comparison between the endoscopic and microscopic tympanoplasty techniques. The string used for searching the databases was as follows, considering titles and abstracts: (*endoscopic tympanoplasty*) AND (*microscopic tympanoplasty*) AND (*outcomes OR benefits OR hearing outcomes*).

### Eligibility Criteria

All primary data articles were considered eligible studies. Thus, descriptive, cross-sectional, observational, case-control, cohort, case reports, and controlled clinical trials have been revised. Studies were included without restriction of language, period, or location.

All controlled clinical trial studies that contained terms found in their titles or abstracts by searching the databases using the complete string with optimized keywords and organized with Boolean operators were selected. Therefore, only primary studies that evaluated the outcome and comparison between treatment with endoscopic tympanoplasty and microscopic tympanoplasty were selected.

### Exclusion Criteria

Secondary data studies published in the form of letters to the editor, guidelines, literature reviews, narrative reviews, systematic reviews, meta-analyses, and abstracts were excluded.

Studies that did not describe the specificities chosen by the researchers as an objective for the present research or that were unclear were also excluded. Other exclusion criteria were: 1) Articles that did not investigate any pathophysiological, symptomatic, subjective, or objective outcome or result related to treatment with endoscopic or microscopic tympanoplasty; 2) articles that did not specify in detail in the study methodology how each investigated favorable results or outcomes were evaluated; 3) articles in a language other than English that are not fully available in English; and 4) duplicates.

### Data Analysis

The process of analyzing and extracting information from selected and eligible studies was performed using a specific form for systematic reviews prepared by the authors in Microsoft Excel software (Microsoft Corporation, Redmond, WA, USA). In this form, the title and abstract of each selected study were first added. Then, all titles and abstracts were read by the authors to seek and apply the inclusion and

exclusion criteria for each one. Based on titles or abstracts, the articles were selected for full reading, and those that met at least one inclusion criteria and no exclusion criteria were included. In case of disagreement between evaluators, a third evaluator made the decision on the eligibility of the study in question.

### Study Selection

After the studies were searched and listed, the authors evaluated full texts of eligible articles based on the inclusion and exclusion criteria. The inclusion criteria were as follows:<sup>1</sup> Article whose main or secondary objective was to identify and/or explore favorable and/or unfavorable outcomes of treatment by endoscopic tympanoplasty and microscopic tympanoplasty<sup>2</sup>; and articles whose primary or secondary objective was to compare treatment by endoscopic tympanoplasty with microscopic tympanoplasty. The following types of publications were excluded:<sup>1</sup> Articles that did not investigate any pathophysiological, symptomatic, subjective, or objective outcome related to treatment with endoscopic or microscopic tympanoplasty<sup>2</sup>; articles that did not specify in detail in the study methodology how each investigated favorable outcome was evaluated;<sup>3</sup> articles in a language other than English that do not have full text available in English;<sup>4</sup> publications whose original articles were inaccessible (only abstracts were available) and/or in which incomplete data were provided;<sup>5</sup> duplicates;<sup>6</sup> systematic reviews (since this type of article does not provide primary data).

### Collected Data

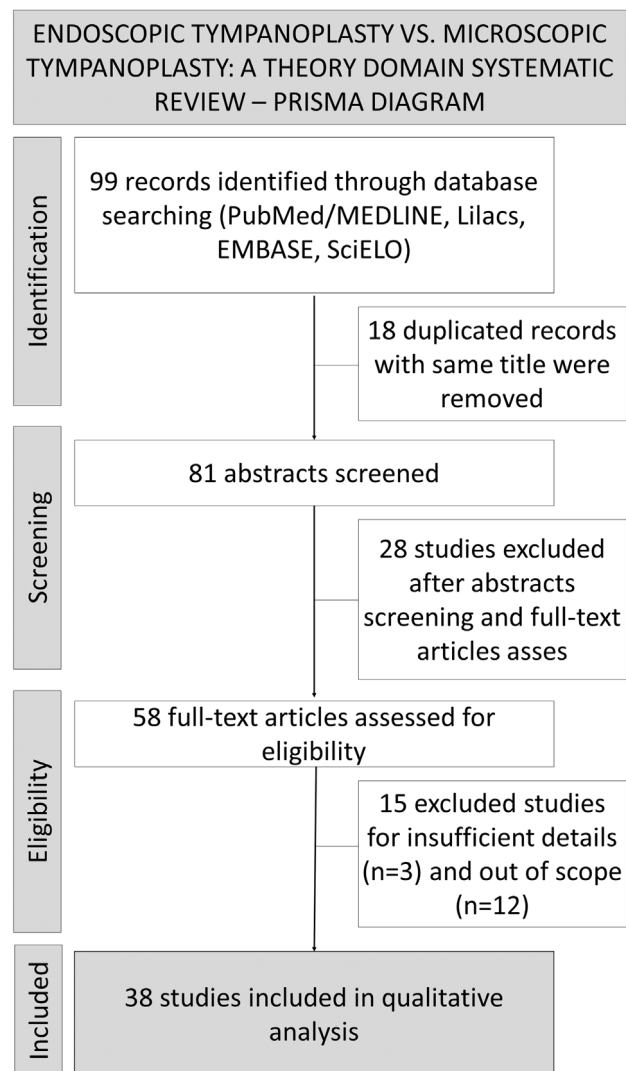
The authors reviewed all relevant studies and independently extracted data, which were put in a chart with their characteristics, to qualitatively compile the results. Any discrepancies were resolved by consensus between the authors. The list of all included studies and their respective study designs is described in the results.

### Clinical Outcome

The clinical outcomes of interest were summarized and systematically analyzed, comparing studies with similar designs and contrasting divergent results. The clinical outcomes of interest from each included study were highlighted and discussed. Studies that did not present results or outcomes referring to at least one analyzed technique were not included in the sample of the present review.

## Results

The first phase of the present systematic review found 99 articles in 4 databases. After deleting 18 duplicate studies, 81 studies were selected by the reviewers for reading their titles and abstracts. Of these, 28 articles were excluded according to the established exclusion criteria and 15 articles were included in the second step, which consisted of reading the entire manuscript. The entire article selection process is described in ►Fig. 1, which shows the PRISMA flow diagram for the inclusion of articles.



**Fig. 1** PRISMA diagram. Source: developed by the authors.

All articles included in the present study were reviewed by the authors and their results and conclusions were discussed to summarize all the results and support the discussion on the topic. The highlights of each article and the design of each study are shown in ►Table 1.

A total of 31 included retrospective studies evaluated and compared the success of the surgical technique and the effectiveness of the two techniques in the final anatomical result, graft success, and hearing recovery in patients (air-bone gap), all of which obtained a similar positive result, with no statistically significant difference between the endoscopic and the microscopic approach. The duration of surgery was compared in 21 of these studies,<sup>13–36</sup> 13 of which reported a shorter surgical time in the endoscopic technique.<sup>14,16,18–22,24–31,33–36</sup> The postoperative recovery time and level of pain presented by patients were evaluated by nine retrospective studies, seven of which had a significant difference in favor of endoscopic tympanoplasty, showing a great improvement in both the pain reported by the patients and the length of stay in the hospital.

**Table 1** Endoscopic Tympanoplasty Compared with Microscopic Tympanoplasty: Study Designs and Conclusions of Included Studies

	Author and year	Study design	Conclusions
1	Aoki (2001) <sup>38</sup>	Retrospective	The endoscopic approach was effective for the treatment of attic cholesteatoma.
2	Ayache et al. (2008) <sup>6</sup>	Retrospective	Otoendoscopy was essential for remaining lesions of the retrotympanum and epitympanum after MT approach.
3	Botti et al. (2020) <sup>13</sup>	Retrospective	No significant differences between ET and MT techniques.
4	Choi et al. (2017) <sup>14</sup>	Retrospective	The ET technique had shorter operation time and reduced pain level.
5	Cohen et al. (2016) <sup>15</sup>	Retrospective	TM closure success rates, hearing outcomes and surgical time were similar in both techniques.
6	Dixon et al. (2020) <sup>39</sup>	Retrospective	TEES may be an alternative to a postauricular approach for removal of cholesteatoma limited to the middle ear and/or the attic in children.
7	Dünder et al. (2014) <sup>16</sup>	Retrospective	ET and MT approach had similar results in terms of visualization of the TM and extra interventions. The first technique had a shorter surgical time.
8	Dunya et al. (2021) <sup>17</sup>	Retrospective	The ET approach was an appropriate alternative to MT for difficult-to-repair anterior perforations.
9	Fina et al. (2016) <sup>18</sup>	Retrospective	Similar results for ET and MT approach without significant statistical differences.
10	Gulsen et al. (2021) <sup>19</sup>	Retrospective	The ET had graft success rates and hearing results similar to MT approach.
11	Gülşen et al. (2019) <sup>20</sup>	Retrospective	ET had inferior complications rates, shorter surgical time than MT and similar graft success rates in anterior perforations of the TM.
12	Guneri et al. (2020) <sup>21</sup>	Retrospective	ET and MT had similar results in the reconstruction of the ossicular chain. ET surgery had a shorter duration.
13	Hargunani et al. (2020) <sup>22</sup>	Retrospective	There was no statistical difference between ET and MT results.
14	Hashim et al. (2020) <sup>40</sup>	Retrospective	Endoscopic and microscopic IBCT were associated with good success rates. The endoscopic approach facilitates visualization, and a better understanding of the middle ear anatomy and the required surgical steps.
15	Hsu et al. (2018) <sup>23</sup>	Retrospective	The TEES approach can achieve surgical outcomes and hearing restoration comparable to those of MES. TEES was associated with shorter surgical and anesthesia time.
16	Huang et al. (2016) <sup>24</sup>	Retrospective	The ET approach offers superior visualization and shorter operative time than MT, in addition to equal hearing outcomes and perforation rates.
17	James et al. (2017) <sup>41</sup>	Prospective	TEES is recommended as providing equivalent likelihood of perforation closure to the postauricular approach but with less postoperative morbidity.
18	Ji et al. (2020) <sup>42</sup>	Retrospective	The frequency-specific hearing outcomes of ET and MT tympanoplasty were similar.
19	Karataş et al. (2019) <sup>25</sup>	Retrospective	EIBCT is safer than the MT approach in pediatric patients with COM and has less postoperative morbimortality.
20	Kim et al. (2021) <sup>26</sup>	Retrospective	ET has similar graft success rate, comparable hearing outcomes, and shorter operative period when compared with MT.
21	Kuo et al. (2017) <sup>27</sup>	Retrospective	The success rate, audiometry improvement, and complication rate are comparable between ET and MT. ET had smaller operation wounds and lower medical expenditures.
22	Lee et al. (2019) <sup>43</sup>	Retrospective	The EIBCT technique and MT had similar success rates and hearing improvement.
23	Lee et al. (2020) <sup>28</sup>	Retrospective	ET offers similar surgical results compared with the MT technique, and a shorter operative time and hospital stay after surgery.

(Continued)

**Table 1** (Continued)

	Author and year	Study design	Conclusions
24	Li et al. (2019) <sup>29</sup>	Retrospective	Good outcomes and similar results can be maintained during a transition of a surgeon to adopting ET and teaching it to residents.
25	Li et al. (2021) <sup>30</sup>	Retrospective	ET has similar results when compared with MT, and a shorter surgical time. The incidence of delayed facial palsy was not significantly different between the two approaches.
26	Marchioni et al. (2020) <sup>44</sup>	Retrospective	Endoscopic type I tympanoplasty can be considered as an alternative technique for tympanic membrane perforations.
27	Marchioni et al. (2015) <sup>45</sup>	Retrospective	ET is a conservative and minimally invasive technique that showed a reduction of hospitalization time with a good postoperative ABG.
28	Min et al. (2018) <sup>31</sup>	Retrospective	ET has smaller operative time and pain than MT, similar hearing improvement and graft success.
29	Ohki et al. (2019) <sup>32</sup>	Retrospective	Under favorable conditions of the middle ear, TEES and PAMES resulted in similar hearing improvement by tympanoplasty without ossiculoplasty. However, under adverse conditions, TEES was a more beneficial approach.
30	Pal et al. (2019) <sup>46</sup>	Randomized Clinical Trial	Hearing improvement and graft success was similar for both the ET and the MT technique. However, postoperative morbidity and surgery time were smaller in the ET approach.
31	Plodpai (2018) <sup>47</sup>	Randomized Clinical Trial	EOT provides more favorable anatomical and audiometric outcomes, a superior visibility of middle ear structures, with fewer complications and less invasiveness than MOT.
32	Sanji et al. (2016) <sup>33</sup>	Retrospective	ET and MT had similar success rates. However, ET was associated with reduced surgery time.
33	Shakya et al. (2020) <sup>34</sup>	Retrospective	Similar results without significant statistical difference. ET is a minimally invasive technique with a shorter surgery time.
34	Shakya et al. (2021) <sup>35</sup>	Prospective	The ET offered superior visualization avoiding postauricular incision and canaloplasty. It offers significantly faster completion of the procedure and provides minimally invasive surgery.
35	Tseng et al. (2018) <sup>37</sup>	Cost-effectiveness study	The cost-effectiveness analysis indicates that ET is comparable to MT for treating COM in Taiwan.
36	Wu et al. (2017) <sup>48</sup>	Prospective	When compared with MT surgery, ET achieves comparable postoperative hearing outcomes with less invasiveness and a shorter operation time.
37	Zhang et al. (2021) <sup>36</sup>	Retrospective	ET is a minimally invasive surgery with similar graft success rate, comparable hearing improvement, fast recovery, and low cost when compared with MT.
38	Zhang et al. (2020) <sup>49</sup>	Prospective	Hearing improvement was similar in ET and MT techniques. ET had reduced operation time and postoperative pain.

Abbreviations: ABG, air-bone gap; COM, chronic otitis media; EIBCT, endoscopic inlay butterfly cartilage tympanoplasties; EOT, endoscopic overlay tympanoplasty; ET, endoscopic tympanoplasty; IBCT, inlay butterfly cartilage tympanoplasty; MES, microscopic ear surgery; MOT, microscopic overlay tympanoplasty; MT, microscopic tympanoplasty; PAMES, postauricular microscopic ear surgery; TEES, transcanal totally endoscopic ear surgery; TM, Tympanic Membrane.

Source: developed by the authors.

The selection also included four prospective studies that found a shorter surgical time in endoscopic tympanoplasty. In addition, the postoperative period was better for the patients in these studies, both in terms of length of stay and referred pain. Both techniques demonstrated similar results in tympanic membrane closure and graft success rate. Hearing improvement was significant and equivalent in both groups and the complication rate did not show any statistically significant difference in the results. Two randomized clinical

trials were also included in the present study, both evaluating hearing outcomes and obtaining equivalence between the two techniques. The anatomical closure presented better results in the endoscopic approach, as well as in the postoperative complications, which were minimized; besides, the endoscopic approach allows a better visualization of the middle ear structures. Surgery time was shorter in one of the studies and the postoperative period proved to be much more advantageous in the endoscopic technique.



Only one study evaluated cost-effectiveness parameters, using a simulated mathematical model in the Taiwanese healthcare system, and no significant difference was found between the cost-effectiveness of each technique. However, it is important to point out that these values may vary depending on the reality of each service, as well as on the available materials and professionals. Thus, the biggest difference was that the endoscopic approach, probably because it is less invasive, had a lower cost of postoperative consultation, while the microscopic approach had a slightly higher cost.

## Discussion

None of the 38 studies analyzed showed inferiority between the techniques when they were compared regarding surgical outcomes, such as the success rates of the grafts performed or postoperative complications at the surgical site. This indicates an adequate comparison in the safety and effectiveness of the endoscopic approach in technical terms in relation to the traditional microscopic approach. Moreover, despite being more recent and not yet fully incorporated in all hospital services, the endoscopic approach demonstrates a promising capacity to be included and used in large scale. However, endoscopy may still be preferentially indicated when addressing regions known to be difficult for the microscopic technique. Thus, surgeries involving manipulation of the epitympanum, the retrotympanum, or the attic may have a greater weight in the choice of endoscopy, aiming at the complete removal of lesions without the permanence of unseen remnants.

Li et al. also state that endoscopic results are positive and suitable even for surgeons in transition in relation to techniques, allowing for good safety even during the learning curve of the physician.<sup>29</sup>

However, it should be noted that, in certain studies, the use of the microscope as a comparative technique was not isolated. In many cases, despite the convenience of using both hands and greater knowledge and adaptation to microscopy, the endoscopes served as an aid for a final review of the surgical site, in order to analyze the unreachable places for the microscope and to reduce the chances of lingering injuries. In one of the articles, Cohen et al.<sup>15</sup> even use a didactic classification to adequately specify at what level the endoscope was used as an aid in microscopic surgery (whether only to enlarge the visualization or even to aid in curettage), being able, therefore, to standardize its results and those of subsequent studies, bringing greater clarity to the analyses.

On the other hand, among the 31 articles that evaluated audiometric outcomes, none found significant differences in hearing recovery between the microscopic and the endoscopic approach, which prompts a discussion about the importance of immediate indication of speech and cognitive approaches for patients with complications resulting from chronic otitis media, cholesteatomas, or other conditions that may compromise the ossicular chain. Considering especially the most vulnerable groups, which would be the

extremes of age, hearing impairment can lead to important consequences on language, understanding, and socialization. Thus, the very need for a surgical approach to the tympanic membrane and the analysis of audiometric results subsequent to the procedure should trigger the attention of the surgeon to adequately and early advise on the performance of speech therapy or even the indication of the use of individual sound amplification hearing aids in more complicated and chronic conditions.

There is a theoretical basis that indicates the possibility of an increase in temperature in the middle ear due to the use of the flashlight at the tip of the endoscope and in important proximity to the middle and internal structures of the ear during surgery; however, none of the studies analyzed in the present study list any outcomes related to this situation, in addition to demonstrating very similar audiometric outcomes between the evaluated techniques.

Positive factors related to the endoscopic approach to the tympanic membrane include its cost-effectiveness or lower cost, in addition to shorter surgical, anesthetic, and hospital stay, which were found in 13 studies.<sup>36,37</sup> In addition, aesthetic and postoperative pain outcomes also favored the choice of this technique in seven analyses. In the approach of pediatric patients, the safety in choosing endoscopy was even considered superior, considering the narrowness of the auditory meatus in children, the possibility of tragal incision, and the wide field of vision made possible by the endoscopic camera.<sup>25</sup>

In the present systematic review, 31 evaluated articles followed the retrospective methodology, based on the analysis of past cases. Only two were randomized clinical trials. Thus, the possibility of biases presents during the selection of patients, the choice of procedures, and the data analysis itself should be pointed out, since these are factors that reduce the quality of evidence. More randomized and prospective studies are needed to more accurately measure complication rates, surgery time, postoperative pain, and audiometric outcomes. Comparative studies related to myringoplasty surgeries were not included in the present, since this is an approach with its own characteristics and which is naturally less invasive.

Although still under study, the endoscopic technique has already shown a very positive potential to become an alternative both as an aid and as a total approach for tympanoplasties, especially when it comes to beneficial results for the patient (aesthetic result, pain, time to hospitalization, and comparable surgical quality). For an adequate choice, therefore, the surgeon must keep in mind that both the microscopic and the endoscopic technique have in fact comparable results, postoperative complications, and audiometric outcomes, and that the endoscopic approach can provide more comfort for the patient regarding pain and aesthetics. However, the availability of adequate materials in each service, the costs involved in the technique and hospitalization, in addition to the experience of the physician and comfort regarding the procedure are essential points to be considered.

## Final Comments

The studies analyzed in the present study demonstrate that the results obtained in terms of tympanic membrane closure, audiometric results, and complication rates in tympanoplasties by the endoscopic approach are equivalent to the results obtained by the conventional microscopic method, in addition to allowing, in many cases, less surgical time and less postoperative pain for patients.

### Funding

The author(s) received no financial support for the research.

### Conflict of Interests

The authors have no conflict of interests to declare.

## References

- Thomassin JM, Korchia D, Doris JM. Endoscopic-guided otosurgery in the prevention of residual cholesteatomas. *Laryngoscope* 1993;103(08):939–943
- Tarabichi M. Endoscopic management of cholesteatoma: long-term results. *Otolaryngol Head Neck Surg* 2000;122(06):874–881
- el-Guindy A. Endoscopic transcanal myringoplasty. *J Laryngol Otol* 1992;106(06):493–495
- Karhuketo TS, Puhakka HJ. Endoscope-guided round window fistula repair. *Otol Neurotol* 2001;22(06):869–873
- Emre IE, Cingi C, Bayar Muluk N, Nogueira JF. Endoscopic ear surgery. *J Otol* 2020;15(01):27–32
- Ayache S, Tramier B, Strunski V. Otoendoscopy in cholesteatoma surgery of the middle ear: what benefits can be expected? *Otol Neurotol* 2008;29(08):1085–1090
- Kozin ED, Lee DJ. Basic principles of endoscopic ear surgery. *Oper Tech Otolaryngol Neck Surg* 2017;28(01):2–10
- Kiringoda R, Cohen MS. Endoscopic tympanoplasty. *Oper Tech Otolaryngol Neck Surg* 2017;28(01):17–22. Doi: 10.1016/j.otot.2017.01.003
- Akyigit A, Sakallioğlu O, Karlıdag T. Endoscopic tympanoplasty. *J Otol* 2017;12(02):62–67
- Plinkert P, Löwenheim H. Trends and perspectives in minimally invasive surgery in otorhinolaryngology-head and neck surgery. *Laryngoscope* 1997;107(11 Pt 1):1483–1489
- Gokgoz MC, Tasli H, Helvacioğlu B. Results of endoscopic transcanal tympanoplasty performed by a young surgeon in a secondary hospital. *Rev Bras Otorrinolaringol (Engl Ed)* 2020;86(03):364–369
- Moher D, Shamseer L, Clarke M, et al; PRISMA-P Group. Preferred reporting items for systematic review and meta-analysis protocols (PRISMA-P) 2015 statement. *Syst Rev* 2015;4(01):1. Doi: 10.1186/2046-4053-4-1
- Botti C, Fermi M, Amorosa L, et al. Cochlear function after type-1 tympanoplasty: endoscopic versus microscopic approach, a comparative study. *Eur Arch Otorhinolaryngol* 2020;277(02):361–366. Doi: 10.1007/s00405-019-05706-z
- Choi N, Noh Y, Park W, et al. Comparison of Endoscopic Tympanoplasty to Microscopic Tympanoplasty. *Clin Exp Otorhinolaryngol* 2017;10(01):44–49. Doi: 10.21053/ceo.2016.00080
- Cohen MS, Landegger LD, Kozin ED, Lee DJ. Pediatric endoscopic ear surgery in clinical practice: Lessons learned and early outcomes. *Laryngoscope* 2016;126(03):732–738
- Dündar R, Kulduk E, Soy FK, et al. Endoscopic versus microscopic approach to type 1 tympanoplasty in children. *Int J Pediatr Otorhinolaryngol* 2014;78(07):1084–1089
- Dunya G, Casazza GC, Blotter J, Park EJ, Park AH. Comparing two different techniques to repair pediatric anterior tympanic membrane perforations. *Int J Pediatr Otorhinolaryngol* 2021;150 (April):110903. Doi: 10.1016/j.ijporl.2021.110903
- Fina M, Yang R, Asche SE, Yueh B. Comparison of outcomes in endoscopic and microscopic tympanoplasty. *Otolaryngol - Head Neck Surg (United States)* 2016;155:107
- Gulsen S, Baltacı A. Comparison of endoscopic transcanal and microscopic approach in Type 1 tympanoplasty. *Braz J Otorhinolaryngol* 2021;87(02):157–163. Doi: 10.1016/j.bjorl.2019.07.005
- Gülşen S, Arıcı M. Endoscopic transcanal versus conventional microscopic tympanoplasty in treatment of anterior tympanic membrane perforations. *Eur Arch Otorhinolaryngol* 2019;276 (12):3327–3333. Doi: 10.1007/s00405-019-05646-8
- Güneri EA, Cakir Cetin A. Ossicular chain reconstruction: endoscopic or microscopic? *J Laryngol Otol* 2020;134(12):1108–1114
- Hargunani CA, King E, Milczuk HA, MacArthur CJ. Endoscopic ear surgery in children with down syndrome. *Int J Pediatr Otorhinolaryngol* 2020;131(January):109884. Doi: 10.1016/j.ijporl.2020.109884
- Hsu YC, Kuo CL, Huang TC. A retrospective comparative study of endoscopic and microscopic Tympanoplasty. *J Otolaryngol Head Neck Surg* 2018;47(01):44
- Huang TY, Ho KY, Wang LF, Chien CY, Wang HM. A comparative study of endoscopic and microscopic approach type 1 tympanoplasty for simple chronic otitis media. *J Int Adv Otol* 2016;12(01):28–31
- Karataş M, Doğan S. Endoscopic inlay butterfly cartilage tympanoplasty in pediatric patients. *Int J Pediatr Otorhinolaryngol* 2019;121(February):10–14
- Kim DJ, Lee HM, Choi SW, Oh SJ, Kong SK, Lee IW. Comparative study of endoscopic and microscopic tympanoplasty performed by a single experienced surgeon. *Am J Otolaryngol - Head Neck Med Surg* 2021;42(01):102788. Doi: 10.1016/j.amjoto.2020.102788
- Kuo C-H, Wu H-M. Comparison of endoscopic and microscopic tympanoplasty. *Eur Arch Otorhinolaryngol* 2017;274(07):2727–2732
- Lee S, Cho HH. Transcanal endoscopic tympanoplasty for pediatric patients under 15 years of age with chronic otitis media. *Clin Exp Otorhinolaryngol* 2020;13(01):41–46
- Li B, Asche S, Yang R, Yueh B, Fina M. Outcomes of Adopting Endoscopic Tympanoplasty in an Academic Teaching Hospital. *Ann Otol Rhinol Laryngol* 2019;128(06):548–555
- Li KH, Chan LP, Chen CK, et al. Comparative Study of Endoscopic and Microscopic Type I Tympanoplasty in Terms of Delayed Facial Palsy. *Otolaryngol Head Neck Surg* 2021;164(03):645–651
- Min J, Kim SH. Comparison of transcanal endoscopic tympanoplasty with sterile acellular dermal allograft to conventional endaural microscopic tympanoplasty with tragal perichondrium. *Am J Otolaryngol* 2018;39(02):167–170. Doi: 10.1016/j.amjoto.2017.11.014
- Ohki M, Kikuchi S, Tanaka S. Endoscopic Type 1 Tympanoplasty in Chronic Otitis Media: Comparative Study with a Postauricular Microscopic Approach. *Otolaryngol Head Neck Surg* 2019;161 (02):315–323
- Sanji R, Channegowda C, Patil S. Retrospective evaluation of the surgical result of tympanoplasty for inactive chronic otitis media and comparison of endoscopic versus microscopic tympanoplasty. *Indian J Otol.* 2016;22(03):171–176
- Shakya D, Kc A, Nepal A. A Comparative Study of Endoscopic versus Microscopic Cartilage Type I Tympanoplasty. *Int Arch Otorhinolaryngol* 2020;24(01):e80–e85
- Shakya D, Kc A, Tamang N, Nepal A. Endoscopic versus microscopic type-I cartilage tympanoplasty for anterior perforation - a comparative study. *Acta Otolaryngol* 2021;141(02):135–140. Doi: 10.1080/00016489.2020.1834616

- 36 Zhang Y, Wang W, Xu K, Hu M, Ma Y, Lin P. Comparison of clinical outcome between endoscopic and postauricular incision microscopic type-1 tympanoplasty. *Acta Otolaryngol* 2021;141(01):29–33. Doi: 10.1080/00016489.2020.1821091
- 37 Tseng CC, Lai MT, Wu CC, Yuan SP, Ding YF. Cost-effectiveness analysis of endoscopic tympanoplasty versus microscopic tympanoplasty for chronic otitis media in Taiwan. *J Chin Med Assoc* 2018;81(03):284–290. Doi: 10.1016/j.jcma.2017.06.024
- 38 Aoki K. Advantages of endoscopically assisted surgery for attic cholesteatoma. *Diagn Ther Endosc* 2001;7(3-4):99–107
- 39 Dixon PR, James AL. Evaluation of Residual Disease Following Transcanal Totally Endoscopic vs Postauricular Surgery Among Children With Middle Ear and Attic Cholesteatoma. *JAMA Otolaryngol Head Neck Surg* 2020;146(05):408–413
- 40 Hashim ND, Lee SA, Jang SH, Moon IS. A comparison of endoscopic and microscopic inlay butterfly cartilage tympanoplasties and their educational utility. *PLoS One* 2020;15(10):e0241152. Doi: 10.1371/journal.pone.0241152
- 41 James AL. Endoscope or microscope-guided pediatric tympanoplasty? Comparison of grafting technique and outcome. *Laryngoscope* 2017;127(11):2659–2664
- 42 Ji L, Zhai S. Comparison of frequency-specific hearing outcomes after endoscopic and microscopic tympanoplasty. *Acta Otolaryngol* 2020;140(12):990–994. Doi: 10.1080/00016489.2020.1804074
- 43 Lee SA, Kang HT, Lee YJ, Kim BG, Lee JD. Microscopic versus endoscopic inlay butterfly cartilage tympanoplasty. *J Audiol Otol* 2019;23(03):140–144
- 44 Marchioni D, Gazzini L, De Rossi S, et al. The Management of Tympanic Membrane Perforation With Endoscopic Type I Tympanoplasty. *Otol Neurotol* 2020;41(02):214–221
- 45 Marchioni D, Soloperto D, Rubini A, et al. Endoscopic exclusive transcanal approach to the tympanic cavity cholesteatoma in pediatric patients: our experience. *Int J Pediatr Otorhinolaryngol* 2015;79(03):316–322. Doi: 10.1016/j.ijporl.2014.12.008
- 46 Pal R, Surana P. Comparative Study Between Microscopic and Endoscopic Tympanoplasty Type I. *Indian J Otolaryngol Head Neck Surg* 2019;71(Suppl 2):1467–1473. Doi: 10.1007/s12070-018-1555-5
- 47 Plodpai Y. Endoscopic vs Microscopic Overlay Tympanoplasty for Correcting Large Tympanic Membrane Perforations: A Randomized Clinical Trial. *Otolaryngol Head Neck Surg* 2018;159(05):879–886
- 48 Wu CC, Chen YH, Yang TH, et al. Endoscopic versus microscopic management of congenital ossicular chain anomalies: our experiences with 29 patients. *Clin Otolaryngol* 2017;42(04):944–950
- 49 Zhang J, Hu S. Comparison of endoscopic tympanoplasty to microscopic tympanoplasty in anterior tympanic membrane perforation. *Laparosc Endosc Robot Surg* 2020;3(03):70–73. Doi: 10.1016/j.lers.2020.06.001