

## SPECIAL ARTICLE COVID-19

# Barrier for Particle Dispersion Control During Mastoidectomy

Camila Rêgo Muniz<sup>1</sup> Carlos Felype Oliveira Pena<sup>2</sup> Marcio Ribeiro Studart da Fonseca<sup>3</sup>   
 Marcos Rabelo de Freitas<sup>1</sup>

<sup>1</sup> Discipline of Otorhinolaryngology, Hospital Walter Cantídio, Universidade Federal do Ceará, CE, Brazil

<sup>2</sup> Medicine College, Universidade de Fortaleza, CE, Brazil

<sup>3</sup> Discipline of Head and Neck Surgery, Hospital Walter Cantídio, Hospital da Universidade Federal do Ceará, CE, Brazil

**Address for correspondence** Camila R. Muniz, MD, Rua Capitão Francisco Pedro, 1290, Ilha 6, Rodolfo Teófilo, Fortaleza, CE, 60430-370, Brazil (e-mail: camila\_rmuniz@hotmail.com).

Int Arch Otorhinolaryngol 2021;25(2):e296–e300.

## Abstract

**Introduction** The China Health Authority alerted the World Health Organization (WHO) of several cases of pneumonia, and the WHO has declared the novel coronavirus (COVID-19) a global pandemic. Mastoidectomy is a high-risk aerosol generating procedure with the potential to expose the surgeon to infectious particles.

**Objective** Aim to develop a low-cost prototype for a barrier device that can be used during mastoidectomy.

**Methods** Describe the steps involved during otological emergency, requiring immediate surgical procedure, in untested patients. The Otorhinolaryngology Surgical Team of Walter Cantídio Hospital developed the barrier for particle dispersion presented here.

**Results** During surgery, the prototype did not compromise visualization of the surgical field and instrumentation. Microscope repositioning was not compromised or limited by tent instrumentation and instrument pouch under the Microscope-Tent (MT) performed surgery. After surgery, the plastic sheet was removed simply, without requiring strength. Bone dust and irrigation droplets were collected on the tent.

**Conclusion** Our team developed and practiced, in an otologic emergency, a low-cost and reproducible barrier device that can be used in mastoidectomy in COVID-19 patients. Further tests on efficacy may be necessary.

## Keywords

- ▶ mastoidectomy
- ▶ aerosols
- ▶ SARS-CoV
- ▶ health personnel
- ▶ otologic surgical procedures
- ▶ otorhinolaryngology

## Introduction

In December 2019, the China Health Authority alerted the World Health Organization (WHO) of several cases of pneumonia of unknown etiology in Wuhan City, in the Hubei Province in central China. In January 2020, the WHO declared the SARS-CoV-2 outbreak as a Public Health Emergency of International Concern.<sup>1,2</sup> One month later, the WHO declared the novel coronavirus (COVID-19) outbreak a global pandemic.<sup>3</sup>

On June 06 2020, (21:00 GMT-3), 6,750,521 confirmed cases and 395,779 deaths had been reported the in world, and confirmed cases had been detected in 216 countries.<sup>4</sup> In Brazil, on the same date, the total confirmed cases were 614,941, with 34,021 deaths.<sup>5</sup> In the state of Ceará, in the northeast of Brazil, an official epidemiological report showed 50,502 cases confirmed, with 3,390 deaths.<sup>6</sup>

The primary method of person-to-person transmission occurs among close contacts mainly via respiratory droplets

received  
 July 24, 2020  
 accepted  
 August 26, 2020  
 published online  
 February 19, 2021

DOI <https://doi.org/10.1055/s-0040-1718960>  
 ISSN 1809-9777.

© 2021. Fundação Otorrinolaringologia. All rights reserved.  
 This is an open access article published by Thieme under the terms of the Creative Commons Attribution-NonDerivative-NonCommercial-License, permitting copying and reproduction so long as the original work is given appropriate credit. Contents may not be used for commercial purposes, or adapted, remixed, transformed or built upon. (<https://creativecommons.org/licenses/by-nc-nd/4.0/>)  
 Thieme Revinter Publicações Ltda., Rua do Matoso 170, Rio de Janeiro, RJ, CEP 20270-135, Brazil

produced when an infected person coughs or sneezes. Otorhinolaryngologists are extremely susceptible to SARS-CoV-2 infection. Thus, a variety of aerosol generating procedures are routinely performed, during clinic and endoscopic examinations and surgeries.<sup>7-9</sup>

The presence of COVID-19 in the upper airway mucosa, also in the middle ear, is probably the reason for risk of contamination in otological surgeries and procedures. Previous publications have already demonstrated the presence of other types of coronaviruses in the middle ear in cases of acute infection. The formation of aerosols due to mastoidectomy should also be considered. If the virus is present, it should infect all healthcare workers in a closed operating room for hours.<sup>7-9</sup>

The recommendations of the Brazilian Association of Otorhinolaryngology and Cervical-Facial Surgery (ABORL-CCF, in the Portuguese acronym), are the usage of powerful aspirators with a filtering system, if the procedure is absolutely necessary. Every patient must be considered positive for COVID-19 disease, due to the impossibility of carrying out tests on all patients and the high possibility of false negatives in the current available tests.<sup>9</sup> However, the majority of public health hospitals do not have this high-cost equipment.

Although the masks prevent the inhalation of particles, standard eye protection may not adequately prevent the exposure of the eye of the surgeon to aerosols generating procedures. It is necessary to improve the security of healthcare workers, especially when powerful aspirators with a filtering system are not available.<sup>9</sup>

More recently, a device called "COVID-Box" has been suggested to be used as an efficient, reproducible, low-cost barrier enclosure device that can be used for open tracheotomies in ICU patients during the COVID-19 pandemic.<sup>10</sup> Despite the fact that it can be easily fabricated and its use for open surgery, the present study presents a low-cost prototype for a barrier device which can be used during microscope surgery, such as otologic, neurological and ophthalmologic surgery.

## Material and Methods

We describe the steps and devices involved during an otological emergency, requiring immediate surgical procedure: an acute complication of middle ear cholesteatoma, intracranial abscesses and otogenic meningitis, in untested patients. The Otorhinolaryngology Surgical Team of Walter Cantídio Hospital developed the barrier enclosure device presented here.

### Surgery Preparation and Protection of Healthcare Workers

The procedure should ideally be performed at the operating room with powerful aspirators and filtering system, but in this case the hospital did not have this equipment. Proper protection of the operative team was paramount during mastoidectomy. Personal protective equipment (PPE) for the procedure should include N95 masks, goggles, face shield, surgical gown and double gloves.

### Microscope-Tent

The Microscope-Tent (MT) consists of a sterile disposable transparent polyethylene plastic sheet, which is used to cover the patient, with 90 g/m<sup>2</sup> grammage forming a tent fixed the microscope. The latter part consists of 2 × 2 m.<sup>10</sup>

### Surgical Field and Procedure

The following are considered otological emergencies, requiring immediate surgical procedure: acute complications of diseases of the middle ear with a risk of death (intracranial abscesses and otogenic meningitis), and the presence of a foreign body in the ear (batteries, due to the risk of chemical leakage) and malignant temporal bone tumors.<sup>9</sup>

The patient was placed in the operating position with the usual skin preparation and surgical fields. A Zeiss OPMI Vario S88 microscope (Carl Zeiss Meditec AG, Jena, Germany), covered by a sterile cover to protect equipment, was used.

For the preparation of the MT, first, the sterile plastic sheet was positioned above the sterile fields and under the microscope, using the external auditory canal (EAC) as the center point (►Fig. 1a). Second, the access ports on the MT was created by cross-shape incisions made on the plastic sheets, two on each side, at the height of the arms of the surgeon (►Fig. 1b, ►1c). Third, the plastic sheet was fixed to enclose the microscope lens with a rubber band (►Fig. 1d). Fourthly, the plastic sheet was cut to allow the microscope lens to be not obstructed and cleaned during surgery (►Fig. 1e). At last, an extra small port was created near to the ear on the periphery of the MT, which may be used for irrigation (►Fig. 1f).<sup>10,11</sup> Finally, the surgeon began to drill the mastoid bone.

The instruments were passed under the MT, to perform surgery and reduce aerosol dispersion.

### Postprocedure Steps

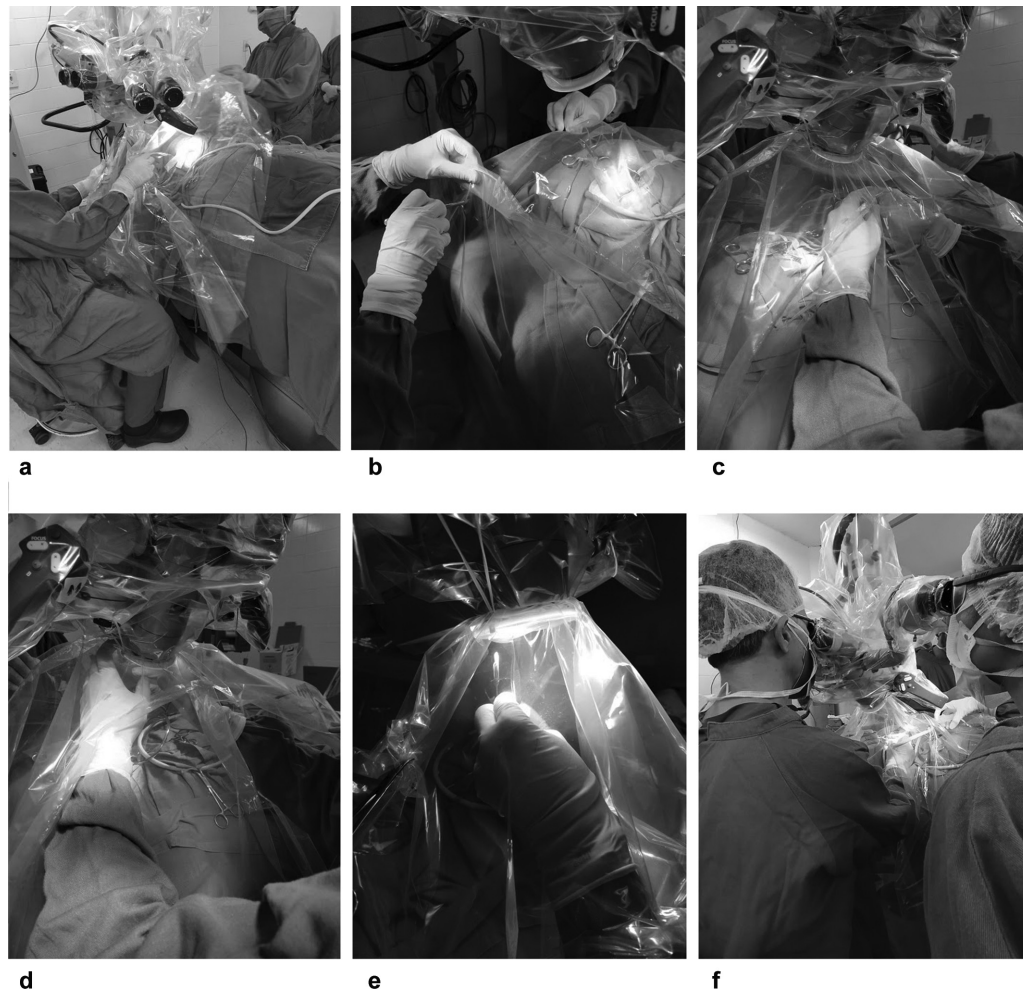
The postprocedure waste disposal and decontamination of equipment need careful consideration to minimize contamination of the environment. After surgery, we recommend leaving the Microscope-Tent placed on the head of the patient at the end of the procedure. Extreme care during plastic sheet removal should be taken. It should never be shaken or removed quickly, to minimize the risk of exposure.<sup>10,11</sup>

## Results

The surgery was performed completely without the tent getting in the way. During extensive irrigation and drilling, clear vision of the surgical field was maintained and instrumentation was possible without difficulty (►Fig. 2a, ►2b). When necessary, the residue on the inside face of the tent was cleaned easily with suction instruments within minutes.

Microscope repositioning was not compromised or even limited by the tent (►Fig. 2c). Instrumentation under the MT while performing the surgery (►Fig. 2c). No ergonomic problem was observed while using the tent.

After surgery, the plastic sheet was removed in a simple way, without requiring strength (►Fig. 2d). Bone dust and irrigation droplets were collected from the tent (►Fig. 2e).



**Fig. 1** Preparing the Microscope-Tent (MT). (a) Plastic sheet positioned (b) Access ports on the MT were created by cross-shape incisions made on the plastic sheets (c) Access ports on the MT at the height of the surgeon's arms (d) Fixed center of plastic sheet enclosed the microscope lens with rubber band (e) Cut plastic sheet to allow microscope lens (f) Auxiliary surgeon irrigation by extra small port near to ear on the periphery of the MT.

## Discussion

Otorhinolaryngologists are part of the front care for acute respiratory infections. They must understand that patients will continue to have other diseases with specific demands and treatments that cannot be postponed, such as otological emergencies, requiring immediate surgical procedure: acute complications of diseases of the middle ear with a risk of death (intra-cranial abscesses and otogenic meningitis).<sup>9,12</sup>

Professionals should prepare strategies to mitigate the risk of COVID-19 transmission. These include preoperative COVID-19 testing, if timing and resources are available. In Brazil, we have a limited use of it.<sup>11</sup> The ABORL-CCF recommends that all patients should be considered positive for COVID-19, due to the impossibility of carrying out tests on all of them and the high rate of false negatives results. Thus, the ABORL-CCF strongly recommends the use of powerful aspirators with a filtering system.<sup>9</sup>

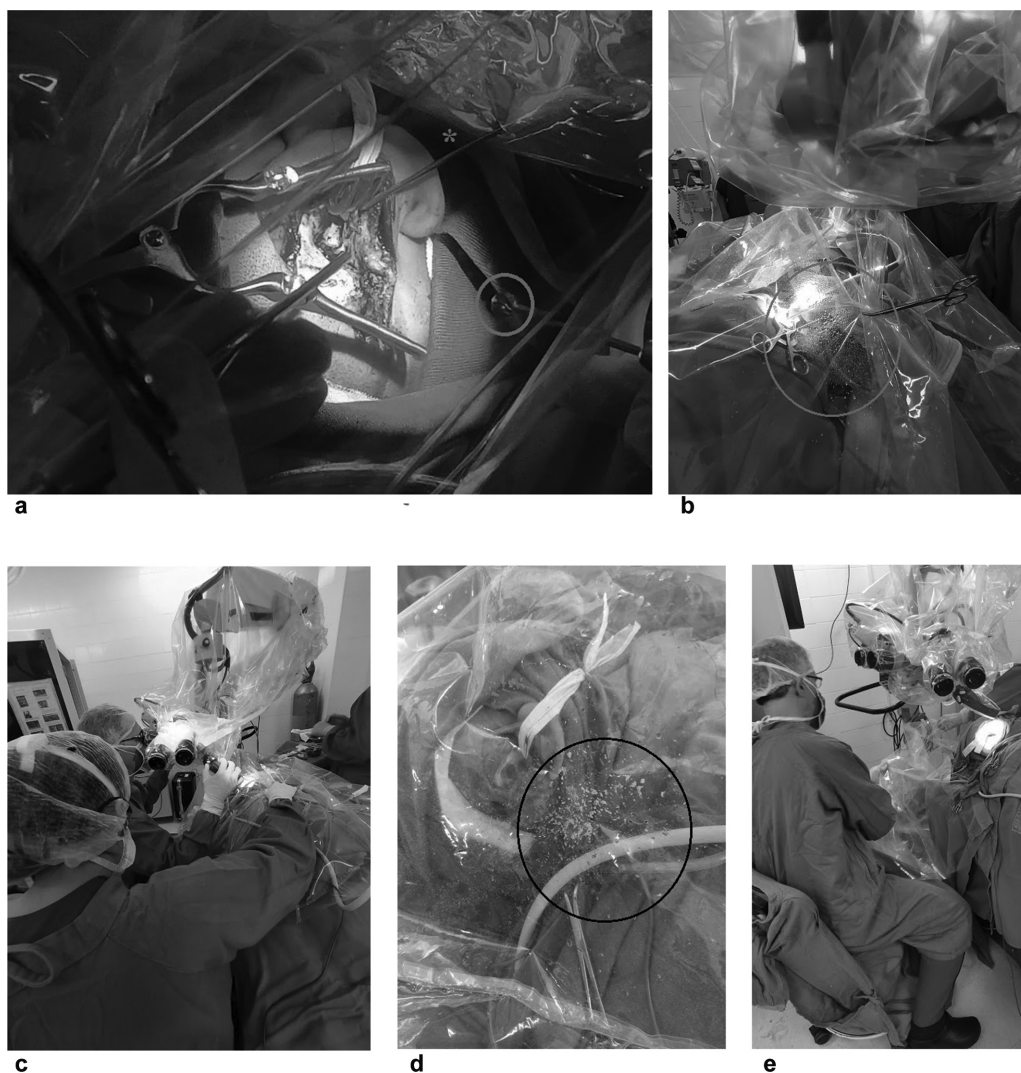
However, the majority of public health hospitals do not have this high-cost equipment, so specific strategies to decrease the risk of transmission from patients who are at risk or positive for COVID-19 is imperative and the highest

priority during this pandemic. In light of surgical emergencies, limited use of COVID-19 test, unavailability of powerful aspirators with a filtering system and the need to protect health care workers, the Otorhinolaryngology Surgical Team of Walter Cantídio Hospital developed a reproducible and low-cost barrier for surgery using a microscope, such as otologic, neurological and ophthalmologic surgeries.

Cortical mastoidectomy is the treatment for several serious complications of acute and chronic otitis media. Significant aerosolization of bone and other tissues occurs during mastoid drilling.<sup>11</sup> Previous studies demonstrated presence of respiratory virus, like other subtypes of coronavirus, in the middle ear during otitis.<sup>13,14</sup> Probably, the respiratory mucosa is involved in COVID-19, it lines the middle ear and the mastoid air cell system. Drilling through the mastoid creates droplet and aerosols in significant clouds that, if the virus is present, could risk infecting everyone in the operating room environment.<sup>12,15</sup>

As yet, there are no formal guidelines on the best practices to reduce viral transmission during common otology or neurotology procedures, likely, because elective surgery is forbidden in the COVID-19 pandemic. Novel techniques had





**Fig. 2** Surgical field and procedure. (a,b) Mastoidectomy irrigation (\*) and burr drill (red circle), The MT did not compromise visualization of surgical field (c) Microscope repositioning was not limited by the tent; instrumentation and instrument pouch under the MT on feet side by auxiliary surgeon (d) Bone dust and irrigation droplets were collected from the tent (e) Plastic sheet was of simple removal, without requiring strength.

recently been reported to mitigate the risk during mastoid surgery.<sup>7,11,16</sup>

Carron et al. described a simple technique for droplet control during mastoid surgery designed to avoid the need for face shields to allow for otherwise normal drilling conditions. They drilled a cadaveric temporal bone during 5 minutes in an operating room. For protection, they used two different clear drapes and loban (3M, Saint Paul, MN, USA).<sup>7</sup> The limitations of this study stem from constraints on the materials available and unclear steps of preparation of the surgical field. Likewise, the bone of cadaveric models may differ from those of living patients, and short-time drilling does not represent a real surgical procedure.

The OtoTent was described as a simple barrier drape, easy to create and affixed to the microscope, for the same objective of the present study. It was fixed at four points and the surgeon operated under the tent, arms passed by intervals of fixation. However, the setting was distinct to real surgery. It was used for bone of cadaver and not tested for different drill

speeds, burr types, burr sizes, suction irrigator sizes, other microscope configurations, other drilling techniques, and the use of unconventional alternatives to high-speed drills.<sup>11</sup>

In the present study, we developed a barrier method and used it in a real otological emergency case. We suggest the use of a simple barrier drape, the MT, to limit the spread of aerosols and droplets during mastoidectomy. The plastic sheet was easy to create and to affix to the microscope (►Fig. 1). The authors used a large sheet, a fixation in the lens of the microscope and gravitational stretch to define the form of the tent. It keeps the MT in place adapting to microscope angulation during surgery (►Fig. 2c). Also, instruments were easily passed under the MT to perform surgery and reduce aerosol dispersion (►Fig. 2c).

The access ports on the MT were create by cross-shape incisions made at the plastic sheets, two on each side, at the height of the arms of the surgeon, allowing for the surgeon's ergonomics (►Fig. 1b, -1c). The right-handed surgeon spread aerosolized debris predominantly in the left upper quadrant of

the field, followed by the right lower quadrant (–Fig. 2b, –2d), in a different result comparing with the Oto-Tent, maybe, because setting was distinct, cadaver versus real surgery.

In an economic crisis scenario, another advantage is the low-cost of this prototype. Barrier precautions are highly recommended during patient's care in light of limited availability of N95 masks, respiratory isolation rooms and air purifying respirators, devices recommended by protocols.<sup>9,12</sup> MT is not a substitute for appropriate PPE and should only be used as an adjunct.

Another PPE currently used by the surgeon, but not present in recommendations, is the face shield. But its adaptation to microscope ocular lens is unlikely, and the method described here should be considered a substitute for it.<sup>7</sup> Both the MT and face shield are considered a protector barrier. We prefer the MT, because it protects all the operating room workers from infectious particles and it is more ergonomic.

In the present study, particle dispersion was not quantitatively assessed in the operating room and individual particles that may have conglomerated upon hitting surfaces. If studies could be repeated on patients with COVID-19, it would be possible to test dispersed and individual particles droplets for virus. Meanwhile, we suggest the use of the MT as an adjunct of all PPE recommended.

## Conclusion

The COVID-19 pandemic has impacted health care workers. Otolological emergencies, requiring immediate surgical procedure, continue in the routine of the otorhinolaryngologist. Mastoidectomy is a high-risk aerosol-generating procedure with the potential to expose all the operating room workers to infectious particles. Our institution developed and practiced in an emergency mastoidectomy a low-cost, reproducible barrier device that can be used during otologic, neurological and ophthalmologic surgery in COVID-19 patients. Further tests on efficacy may be necessary.

### Conflict of Interests

The authors have no conflict of interests to declare.

## References

- 1 Burki TK. Coronavirus in China. *Lancet Respir Med* 2020;8(03):238

- 2 Harapan H, Itoh N, Yufika A, et al. Coronavirus disease 2019 (COVID-19): A literature review. *J Infect Public Health* 2020;13(05):667–673
- 3 World Health Organization WHO Director-General's opening remarks at the media briefing on COVID-19 - 11 March 2020 WHO Dir Gen speeches. 2020. Accessed June 6, 2020: <https://www.who.int/dg/speeches/detail/who-director-general-s-opening-remarks-at-the-media-briefing-on-covid-19-11-march-2020>
- 4 World Health Organization W WHO Coronavirus (COVID-19) Dashboard. 2020. Accessed June 6, 2020: <https://covid19.who.int/>
- 5 World Health Organization W. Brazil WHO Coronavirus Disease (COVID-19) Dashboard. 2020. Accessed June 6, 2020: <https://covid19.who.int/region/amro/country/br>
- 6 Centro de Operações de Emergências em Saúde Pública - Secretaria de Saúde do Governo do estado do Ceará/Ministério da Saúde. Doença pelo Novo Coronavírus 2019 COVID-19. *Boletim Epidemiológico* N° 282020:1–34
- 7 Carron JD, Buck LS, Harbarger CF, Eby TL. A Simple Technique for Droplet Control During Mastoid Surgery. *JAMA Otolaryngol Head Neck Surg* 2020:1–2
- 8 Xu K, Lai X, Liu Z. Suggestions on the prevention of COVID-19 for health care workers in department of otorhinolaryngology head and neck surgery. *World J Otorhinolaryngol Head Neck Surg* 2020;••:1–3
- 9 Lavinsky J, Kosugi EM, Baptistella E, et al. An update on COVID-19 for the otorhinolaryngologist - a Brazilian Association of Otolaryngology and Cervicofacial Surgery (ABORL-CCF) Position Statement. *Rev Bras Otorrinolaringol (Engl Ed)* 2020;86(03):273–280
- 10 Filho WA, Teles TSPG, da Fonseca MRS, et al. Barrier device prototype for open tracheotomy during COVID-19 pandemic. *Auris Nasus Larynx* 2020;47(04):692–696
- 11 Chen JX, Workman AD, Chari DA, et al. Demonstration and mitigation of aerosol and particle dispersion during mastoidectomy relevant to the COVID-19 era. *Otol Neurotol* 2020; Volume published ahead of print1–18
- 12 Givi B, Schiff BA, Chinn SB, et al. Safety Recommendations for Evaluation and Surgery of the Head and Neck During the COVID-19 Pandemic. *JAMA Otolaryngol Head Neck Surg* 2020;1:1–6
- 13 Heikkinen T, Thint M, Chonmaitree T. Prevalence of various respiratory viruses in the middle ear during acute otitis media. *N Engl J Med* 1999;340(04):260–264
- 14 Pitkäranta A, Virolainen A, Jero J, Arruda E, Hayden FG. Detection of rhinovirus, respiratory syncytial virus, and coronavirus infections in acute otitis media by reverse transcriptase polymerase chain reaction. *Pediatrics* 1998;102(2 Pt 1):291–295
- 15 Rea P, Loyd S, Jenkins D. Guidance for undertaking otological procedures during COVID-19 pandemic. *British Society of Otolology* 2020. Accessed June 6, 2020: <https://www.entuk.org/guidance-undertaking-otological-procedures-during-covid-19-pandemic>
- 16 Hellier W, Mitchell T, Thomas S. Mastoidectomy in the COVID Era – The 2 Microscope Drape Method to Reduce Aerosolization Mastoidectomy. *British Society of Otolology* 2020. Accessed June 6, 2020: [https://www.entuk.org/sites/default/files/Mastoidectomy in the COVID Era – The 2.pdf](https://www.entuk.org/sites/default/files/Mastoidectomy%20in%20the%20COVID%20Era%20-%20The%202.pdf)