



A wet dressing for hypospadias surgery

Ana Gabriela Santos Martins, Salvador Vilar Correia Lima, Luiz Alberto Pereira de Araújo, Fábio de Oliveira Vilar, Niedson Thiago Pereira Cavalcante

Urologic Department (SVCL, FOV), Pediatric Surgery (AGSM, LAPA, NTPC), Hospital das Clínicas - Federal University of Pernambuco (HC-UFPE), PE, Brazil

ABSTRACT

Introduction: One of the main problems faced by surgeons involved in male genitalia surgeries, in particular in children with hypospadias, is the type of dressing and its use during the post-operative period.

Materials and Methods: From a multidisciplinary project involving the use of sugarcane biopolymer membrane developed in the last 10 years, produced by bacterial action over sugarcane molasses, we developed a multiperforated pellicle that, when applied around the penis, protects the surgical field. It is a proven inert material that does not induce any reaction on the surgical field and can be left in situ maintaining the same characteristics during a long period of time without the need of replacement. This multiperforated tape can involve several times the penis shaft and due to its adhesiveness it hardly loosens. We compared the use of this dressing with a commercial one (made by polyurethane). Thirty patients with hypospadias were randomly selected for the use of this new type of dressing in the last 18 months. A similar group of patients used a similar commercial dressing made of polyurethane (Tegaderm®) according to the same criteria of use. For safety reasons, we applied one or two sutures without the inclusion of the skin using an absorbable suture in order to prevent early detachment. A small gauze was left for 24 hours in order to absorb any possible bleeding. We recommended the irrigation of the dressing with water or saline at least three or four times a day and the patient was allowed to bath. The dressing did not need any special care and if not removed it usually detached spontaneously after 10 to 14 days.

Results: The tolerance to the material was satisfactory and there were no adverse reactions on the penile surface. In two cases of the biopolymer group the dressing detached spontaneously on the first and third days, respectively. In two cases of the polyurethane group it was observed major edema. The grade of satisfaction of the patients and their relatives was excellent on the biopolymer group.

Conclusion: This dressing produced by a polysaccharide is a promising alternative for the treatment of children and adolescents submitted to genital surgery. Its main advantage is the possibility of several washes along the day without the need of any other manipulation.

ARTICLE INFO

Key words:

Hypospadias; Biopolymers; canecystatin protein, sugarcane [Supplementary Concept]; Polysaccharides

Int Braz J Urol. 2013; 39: 408-13

Submitted for publication:
November 07, 2012

Accepted after revision:
April 10, 2013

INTRODUCTION

Surgical correction of male genitalia anomalies in children and adolescents has evolved in the last years with the use of new techniques,

instruments and sutures, that somehow have contributed to better results. In spite of that, the correct choice of dressing is still challenging. Several materials have been used with various results, and there is no consensus about their use (1-9).

The clinical indication of a specific dressing is based upon the protective function and mechanical barrier of the tissues against contamination and reduction of the edema caused by the surgical trauma. The structure material should present physical characteristics including elasticity, resistance and flexibility, and must adjust tightly on the surface of the tissues. The chosen dressing must present minimal adverse reactions when in contact with living tissues or organic fluids and must be easily removable.

The main objective of the study was to prove that the biopolymer tape made of sugarcane molasses is biocompatible and protects the affected area in the same or better manner than the commercial available polyurethane tape (Tegaderm®) that is used nowadays for dressing after surgical correction of hypospadias.

MATERIALS AND METHODS

The target population included children and adolescents with hypospadias, and the parents were correctly informed about the study and were invited to join it. Thirty patients used the biopolymer tape as dressing and a similar group of patients used the polyurethane pellicle Tegaderm®. The groups ages varied between 1 and 18 years old, with a median age of 6.6 years for the group that used the sugarcane biopolymer and 7.4 for the group that used the polyurethane tape.

The comparison of the two materials was made with the use a question form that allowed the evaluation of the results until complete recovery of the patients submitted to surgical correction of hypospadias. It was also analyzed local inflammatory reaction, edema, hyperemia, transudation and adhesiveness of the material to the surgical field until its removal.

The evaluation of adverse reactions as skin irritability was categorized by the researcher observation as absent, limited to the foreskin, or extended to other areas.

Grade of adhesiveness: the researcher observed the adhesiveness as with areas of detachment, adhesiveness without detachment or without adhesiveness.

Grade of discomfort: the patients or their relatives described it during the questionnaire as “very troubled”, “troubled” or “not troubled” with the use of the dressing.

Grade of adhesiveness and fixedness “in situ”: this aspect was evaluated after the patients or their relatives cleaned the dressing with water three times a day and informed the researcher.

Sample size

This was an experimental controlled and randomized clinical trial and the size of the sample included 60 patients, divided between two groups: group 1 (n = 30), patients submitted to surgical correction of hypospadias using biopolymer tape made of sugarcane molasses and group 2 (n = 30), patients that used the polyurethane pellicle as dressing.

All patients were submitted to anamnesis including questions about previous surgeries, physical and urological exam and classification of the hypospadias grade, along with pre-operative routine exams. There were 21 proximal hypospadias and 9 distals in the group that used the biopolymer tape. In the group that used the polyurethane pellicle, 19 presented proximal hypospadias and 11 distal.

The patients were assigned randomly to the groups (use of biopolymer made of sugarcane molasses or polyurethane), through sealed envelopes containing numbered randomized distributions generated by computer in a 1:1 manner in groups of 10. The envelopes were opened at the surgical room by a nurse right before the surgical procedure. All volunteer patients were operated by one or more members of the surgical team. To make sure that all procedures were done properly all patients were hospitalized for 8 days.

The polyurethane pellicles sized 4.4 x 4.4 and 6.0 x 7.0, were waterproof and protected against external contaminants, and were adequately fitted with comfort of all patients (Figure-1).

The biopolymers tapes of sugarcane presented the same measures of the polyurethane pellicles and could be cut out according to the size of the patient organ (Figure-2). They were sterilized using gamma rays.

Figure 1 - Polyurethane pellicle molded to the penile shaft.

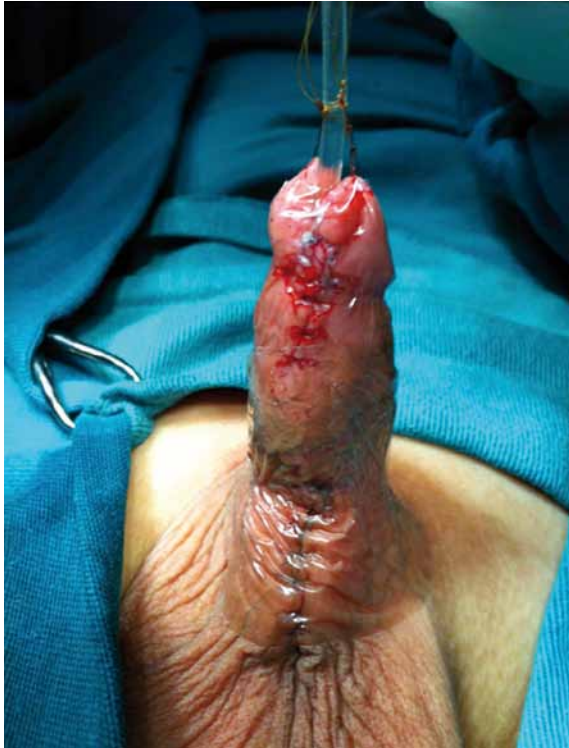
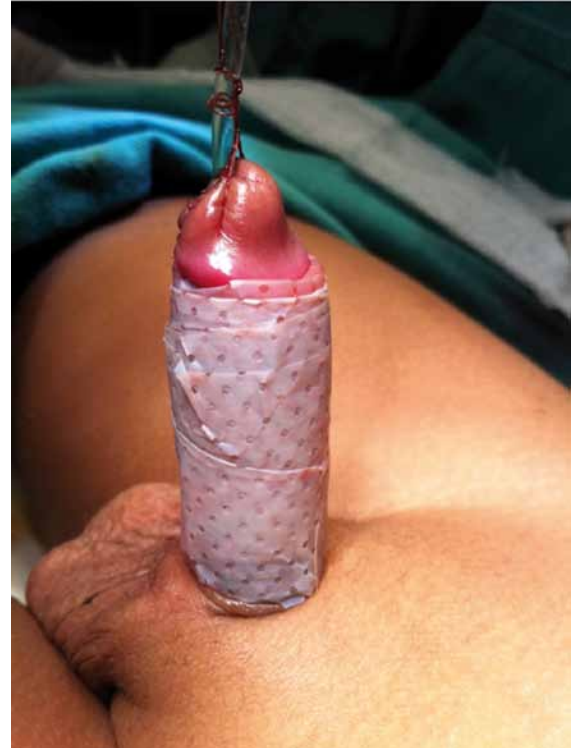
Figure 2 - Biopolymer pellicle made of sugarcane molded to the penile shaft.



Technique of pellicle application

After completion of the surgical correction of the hypospadias according to several techniques, the area was washed with saline and dried with gauze. Then, the dressings were applied over the surgical field involving all penile surface (Figures 3a,b,c and d). There was no tension over the surgical field (Figure-4). Although they adhered correctly, three sutures were passed on the ends of the dressings using catgut 6-0, not including the skin, as a safety measure. No creams were used in both groups. In the group of patients with up to 7 years and that used a catheter, it was used a double diaper layer; the catheters were passed from a first to a second diaper through an opening, preventing the urine to be in touch with the dressing. In the group of boys more than 7 years old the urine drainage included a urethral catheter attached to a closed collecting system.

Ethical Aspects

This study did not present ethical risks and was in accordance to the determinations of the Na-

tional Council of Health, the Helsinki Declaration and the Nuremberg Code for human experiment. The project was approved by the local Ethical Committee of the Institution. This was a randomized and controlled clinical experimental and observational trial.

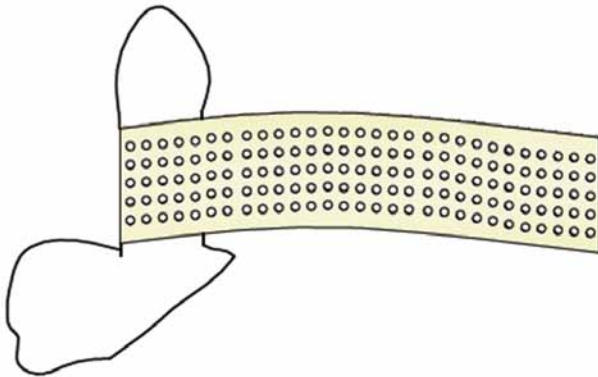
RESULTS

The follow-up evaluations were made by one of the members of the team daily until the removal of the dressing in the eighth day after the surgery before discharge (Figure-5). Eight parents of patients of the biopolymer group decided not to remove the dressing, allowing it to spontaneously fall, which occurred after 10 to 14 days, maintaining the recommendations of regular washes (Figure-6). All patients tolerated well the dressings in both groups. In one patient of the biopolymer group it was observed spontaneous fall of the dressing, one during the first day after the surgery and the other after three days of the surgery. There was significant edema in two patients of the Tegaderm® group, along

Figure 3 a, b, c and d - Placement of the biopolymer pellicle of sugarcane, involving all penile surface.

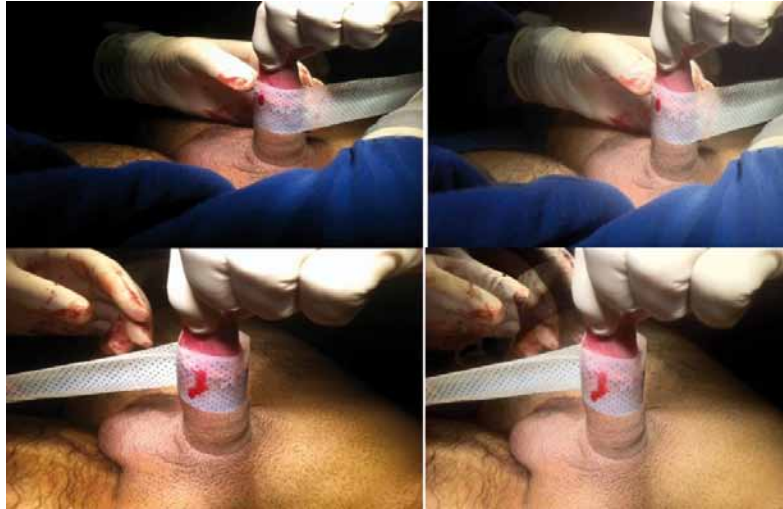

Figure 4 - Schematic drawing of the application of the biopolymer pellicle of sugarcane.



with a foul odor resembling urine, according to relatives. Such cases were not observed in the biopolymer group.

DISCUSSION

There is no consensus about the correct dressing material for use during the post-operative period of male patients with genital anomalies. Some groups advocate not to use any dressings and others use complex dressings with different grades of handling difficulties (10,11).

In a study from Canada, three groups of patients were compared. The median age was 2.2 years and all patients were submitted to surgical correction of different grades of hypospadias and used three different dressings: one with the same material used in the present study, one group using a porous material and a third group that did not use dressings. All patients used an ointment and the surgeries were made in a day hospital. The study did not establish the correct number of patients of each group. The dressing was removed by the parents after three days and the most important aspects was the urine odor and concerning about feces contamination. It concluded that dressings were not necessary in hypospadias surgeries (12). It is known that in minimal grades of hypospadias presenting minimal detachment of the foreskin, the same approach similar to post-tectomy can be applied, as stated by Leclair et al. (11). In the present study, there was no need of dressing exchange and it was possible to wash it as many times as needed, including the daily bath; the post-operative handling was similar to those patients without dressings and the advantage that the surgical field is protected against external agents as feces. The fact that the studied material has already been studied regarding cytotoxicity and that it was used in other areas (including as

Figure 5 - Sugarcane biopolymer pellicle on the 8th day, before removal.

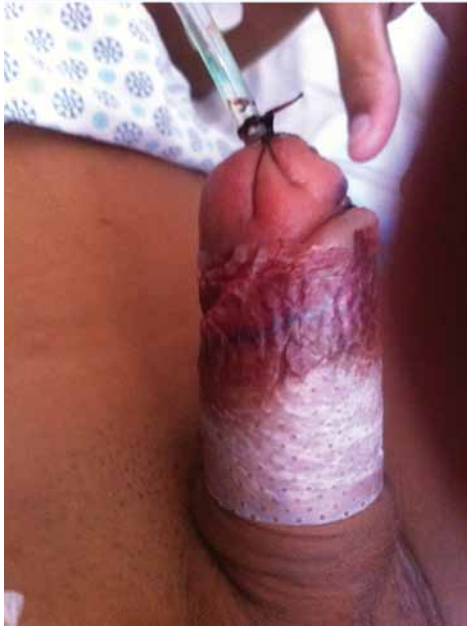
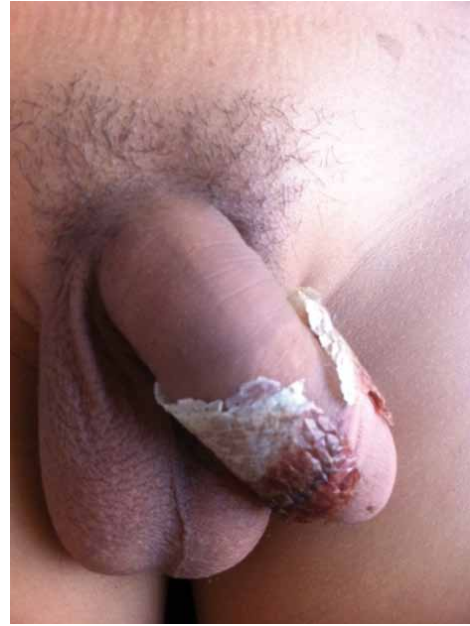
Figure 6 - Spontaneous loss of the biopolymer tape after the 10th day.



implants) makes it a safe option, with minimal undesired effects when applied to operated surfaces (13,14). It is important to reinforce that this material has been used in an uncontrolled manner for more than 5 years with good results (15). The present controlled study also studied prospectively the material and compared the results with previous reports. Since this material is multiperforated and transparent it is possible the observation of hematomas or areas of necrosis by the parents and doctors, that are very troublesome in male genitalia surgeries. The early withdrawal of the dressing as advocated by some (4,12) does not seem correct, since the development of edema will increase the tension in the sutured area and possible dehiscence. Another important aspect in the randomized trials is that the median age of the patients is low (less than 3 years old) in which group there seldom is observed erection (11,12). It seems possible that the use of a dressing with adequate contention of distension limits the occurrence of edema and its consequences on the surgical surface. As stated, the median age of the patients in our study was superior than the others.

CONCLUSIONS

Based on the present study it is possible to conclude that the proposed material is a highly satisfactory alternative. Since it is a product obtained from a renewable and natural source, possibly cheaper, its use is adequate for surgical dressing of hypospadias repair.

CONFLICT OF INTEREST

None declared.

REFERENCES

1. Bhat A: General considerations in hypospadias surgery. *Indian J Urol.* 2008; 24: 188-94.
2. de Mattos e Silva E, Gorduza DB, Catti M, Valmalle AF, Demède D, Hameury F, et al.: Outcome of severe hypospadias repair using three different techniques. *J Pediatr Urol.* 2009; 5: 205-11; discussion 212-4.
3. Gormley A, Fishwick J, Whitnall B: Home dressing removal following hypospadias repair. *J Child Health Care.* 2007; 11: 158-66.

4. Sanders C: Comparison of dressing removal following hypospadias repair. *Br J Nurs.* 2003; 12: S21-8.
5. Singh RB, Khatri HL, Sethi R: Glove-finger dressing in paediatric hypospadias. *Pediatr Surg Int.* 2002; 18: 218-9.
6. Guralnick ML, al-Shammari A, Williot PE, Leonard MP: Outcome of hypospadias repair using the tubularized, incised plate urethroplasty. *Can J Urol.* 2000; 7: 986-91.
7. Roberts J: Hypospadias surgery past, present and future. *Curr Opin Urol.* 2010; 20: 483-9.
8. Baskin LS, Ebbers MB: Hypospadias: anatomy, etiology, and technique. *J Pediatr Surg.* 2006; 41: 463-72.
9. Cook A, Khoury AE, Neville C, Bagli DJ, Farhat WA, Pippi Salle JL: A multicenter evaluation of technical preferences for primary hypospadias repair. *J Urol.* 2005; 174: 2354-7, discussion 2357.
10. Van Savage JG, Palanca LG, Slaughenhaupt BL: A prospective randomized trial of dressings versus no dressings for hypospadias repair. *J Urol.* 2000; 164: 981-3.
11. Leclair MD, Camby C, Battisti S, Renaud G, Plattner V, Heloury Y: Unstented tubularized incised plate urethroplasty combined with foreskin reconstruction for distal hypospadias. *Eur Urol.* 2004; 46: 526-30.
12. McLorie G, Joyner B, Herz D, McCallum J, Bagli D, Merguerian P, et al.: A prospective randomized clinical trial to evaluate methods of postoperative care of hypospadias. *J Urol.* 2001; 165: 1669-72.
13. de Barros Marques SR, LM Esdras, de Andrade Aguiar JL, Albuquerque MCS, Rossiter RO, Montenegro LT, et al.: A new vascular substitute: femoral artery angioplasty in dogs using sugarcane biopolymer membrane patch - hemodynamic and histopathologic evaluation *J Vasc Bras.* 2007; 6: 309-15.
14. Falcão SC, Coelho AR, Evêncio Neto J: Biomechanical evaluation of microbial cellulose (*Zoogloea* sp.) and expanded polytetrafluoroethylene membranes as implants in repair of produced abdominal wall defects in rats. *Acta Cir Bras.* 2008; 23: 184-91.
15. Lima SVC, Aguiar JLA, Vilar FO: A New Dressing for Hypospadias Surgery. In: XXVIII Congresso de la Confederacion Americana de Urologia - CAU 2006, 2006, Recife-PE. *International Brazilian Journal Urology.* Recife-PE: Editorial and Graphic Composition, 2006; 32: pp. 189.

Correspondence address:

Dr. Salvador Vilar Correia Lima
Hospital das Clínicas - Federal University of Pernambuco
(HC-UFPE)
Avenida Parnamirim, N 95, Parnamirim
Recife, Pernambuco, 50.060-901, Brazil
Fax: +55 81-3031-3846
E-mail: salvador@ufpe.br