

# Clamp Ablation of the Testes Compared to Bilateral Orchiectomy as Androgen Deprivation Therapy for Advanced Prostate Cancer

AD Zarrabi, CF Heyns

*Department of Urology, University of Stellenbosch and Tygerberg Hospital, Western Cape, South Africa*

---

## ABSTRACT

*Purpose:* Burdizzo clamp ablation of the testes (CAT) may provide an incisionless, cost-effective form of androgen deprivation therapy (ADT) in men with adenocarcinoma of the prostate (ACP) who find bilateral orchiectomy (BO) unacceptable or can not afford medical ADT. The aim of this study was to compare CAT with BO as primary ADT in men with ACP.

*Materials and Methods:* Written, informed consent was obtained from men with locally advanced or metastatic ACP. Patients were prospectively randomized to BO (n = 9) or CAT (n = 10) under local anaesthesia, and were evaluated 3 and 7 days, 6 weeks and 3 months post-procedure. The protocol was approved by the local institutional ethics committee. Statistical analysis was performed using Student's, Mann-Whitney's and Fisher's tests.

*Results:* Mean duration of the procedure was significantly longer for BO than CAT (16.9 vs. 10.9 minutes). Mean pain scores during and after the procedure did not differ significantly. Serum testosterone decreased significantly on days 3 and 7 after CAT, but increased at 6 weeks, and was significantly higher than after BO. Serum luteinizing hormone increased significantly from day 3 after BO and from day 7 after CAT. Serum prostate specific antigen decreased significantly after BO, but not after CAT. Minor complications were more common after BO (89%) than CAT (40%). In the 9 men who did not achieve castrate levels of testosterone after CAT, BO was performed.

*Conclusions:* CAT was quicker to perform and had a lower complication rate, but was not as effective as BO in achieving castrate serum testosterone levels.

*Key words:* Prostate Cancer; orchiectomy; androgens; castration.

*Int Braz J Urol. 2011; 37: 347-354*

---

## INTRODUCTION

Androgen deprivation therapy (ADT) is the most effective treatment for locally advanced or metastatic adenocarcinoma of the prostate (ACP). Surgical ADT consists of bilateral orchiectomy (BO) whereas medical ADT can be achieved by means of luteinizing hormone releasing hormone agonists (LHRHa), anti-androgens or estrogens (1,2).

BO requires surgical facilities, complications are quite common (although usually minor) and re-

moval of the testes (castration) is psychologically unacceptable to many men, although it is less expensive than LHRHa (3). Medical ADT is psychologically more acceptable, but requires strict patient compliance with regular follow-up. LHRHa therapy is extremely expensive and therefore, unavailable to many patients in developing countries (3). Anti-androgen monotherapy is also expensive, and not as effective as BO or LHRHa. Estrogen therapy is inexpensive, but causes mastalgia and gynecomastia and may cause fatal thrombo-embolism (1,2).

The Burdizzo clamp is widely used in veterinary practice as an incisionless method of castration (4). It consists of pincers with a compound leverage action which crushes the spermatic cord, resulting in testicular infarction (Figure-1) (5). Skin damage or bruising is reported to be minimal (6,7).

Scientific literature with regard to its use in humans is scant. Zufall reported in 1958 on 200 patients who had vasectomy performed using the clamp (5). Herzog and Santucci reported in 2002 a case of gender reassignment where the clamp was used at the patient's insistence (8).

The aim of this study was to evaluate the feasibility, safety and efficacy of clamp ablation of the testes (CAT) using the Burdizzo clamp in men with ACP.

## MATERIALS AND METHODS

The protocol was approved by the Human Research Ethics Committee of the Faculty of Health Sciences of the University of Stellenbosch.

The inclusion criteria were (1) histologically confirmed ACP, (2) locally advanced or metastatic cancer requiring ADT, (3) patient of sound mental status and willing to give written, informed consent.

The exclusion criteria were (1) serious or life-threatening complications requiring immediate ADT (e.g. severe bone pain, impending or established paralysis, renal failure, brain metastases) and (2) local testicular or scrotal abnormalities.

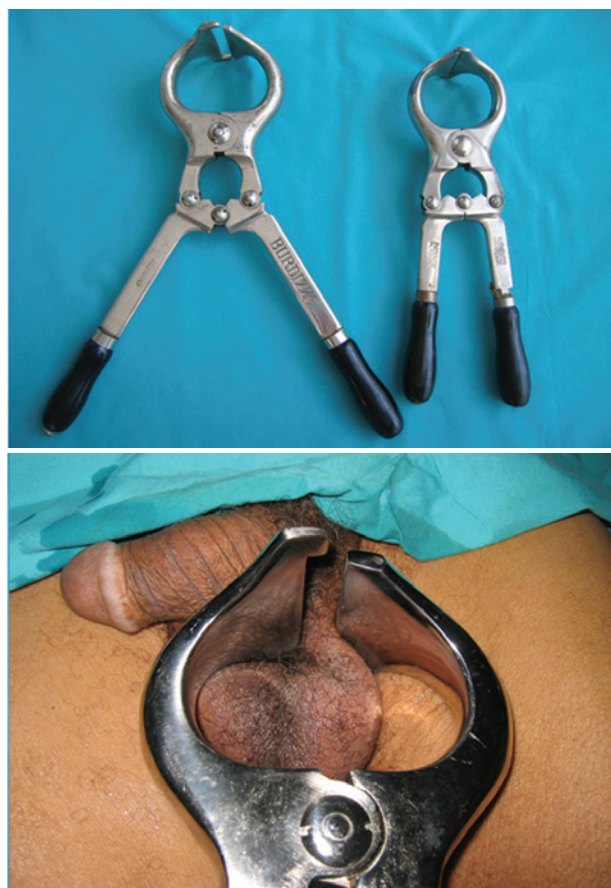Evaluation at randomization, during the procedure, and at 3 days, 7 days, 6 weeks and 3 months post-procedure included pain assessment using a visual analog scale (VAS) with range 0-100, analgesic use, complications, serum testosterone (TT), luteinizing hormone (LH) and prostate specific antigen (PSA) levels, and testicular volume measured by ultrasound.

Group 1, patients underwent surgical BO under aseptic conditions in an operating room as a day case. Bilateral spermatic cord blocks and midline scrotal skin infiltration were performed using a mixture of 10 mL lignocaine Lidocaine 1% and 10 mL bupivacaine Bupivacaine 0.5% (9). In accordance with the guidelines of the European Association of Urology, it is not our practice to administer routine peri-operative antibiotic prophylaxis for so called "clean operations" where the urinary tract is not opened (10).

Group 2 patients underwent CAT (Figure-1). Bilateral spermatic cord blocks, as well as, a scrotal block were performed using 20 mL bupivacaine Bupivacaine 0.5%. The scrotal block entailed circumferential infiltration of the scrotal skin at the narrowest part of its attachment to the perineum, which effectively anaesthetized the entire scrotal skin (11). Using the thumb and forefinger of the non-dominant hand, the testis was grasped and the jaws of the Burdizzo clamp positioned over the spermatic cord. The spermatic cord on each side was then clamped twice; - cranially and caudally - for 60 seconds.

Prophylactic antibiotics were not given. For post-procedure analgesia, all patients received oral paracetamol Paracetamol and ibuprofen Ibuprofen tablets to be taken as needed for pain. The protocol provided for patients with uncontrolled pain to be hospitalized for treatment with opiates and regional anaesthesia if necessary. Group 2, patients with

**Figure 1** - The Burdizzo clamp (A) positioned to crush the spermatic cord (B).



serum TT above castration level ( $< > 1.7$  nmol/L) at week 6 were offered salvage BO.

Statistical analysis was performed using GraphPad InStat® software with Student's t-test for parametric data, Mann-Whitney test for nonparametric data and Fisher's exact test for contingency tables. A two-tailed p-value  $< 0.05$  was accepted as statistically significant (SS). All data are shown as mean  $\pm$  standard error of the mean (SE).

## RESULTS

From November 2007 to November 2008, 19 patients were randomized to group 1 (n = 9) or group 2 (n = 10). Mean patient age and serum TT, LH, PSA and testis volume at randomization were not significantly different between the two groups (Table-1). Mean duration of the procedure was significantly longer for BO than CAT (Table-1).

**Table 1** - Study data (mean  $\pm$  SE and range).

	Group 1 (Bilateral orchidectomy)	Group 2 (Clamp ablation of the testes)
Number of patients	9	10
Baseline data		
Age (years)	64.7 $\pm$ 2.6 (57-77.8)	66.1 $\pm$ 2.0 (57-78.6)
Testosterone (TT) (nmol/L)	12.4 $\pm$ 2.6 (1.7-27.6)	13.9 $\pm$ 2.9 (4.7-33.1)
Luteinizing hormone (LH) (IU/L)	4.3 $\pm$ 1.2 (0.1-10.4)	8.1 $\pm$ 3.1 (1.8-34.8)
Prostate specific antigen (PSA) ( $\mu$ g/L)	108.6 $\pm$ 36.8 (3.2-311.0)	160.8 $\pm$ 89.0 (4.4-869.0)
Testis volume (cc)	14.6 $\pm$ 1.5 (6.9-28.2)	15.2 $\pm$ 1.5 (5.8-26.9)
Duration of procedure (minutes)	16.9 $\pm$ 0.9 (13-20)	10.9 $\pm$ 1.1 (6-17)**
Castrate serum TT ( $< 1.7$ nmol/L) (%)		
3 days	9 (100%)	3 (30%)**
7 days	9 (100%)	4 (40%)**
6 weeks	8 (89%)	1 (10%)**
Complications (%)		
Any complication	8/9 (89%)	4/10 (40%)
Haematoma of scrotum	4	2
Oedema of scrotum/penis	0	2
Infection / abscess	4	0
Sinus	6	0
Antibiotics given	4	0
Sutures removed	3	0
Surgery (excision of sinus)	1	0

\*\* statistically significant difference compared to group 1

## Clamp Ablation Of The Testes Compared To Bilateral Orchiectomy

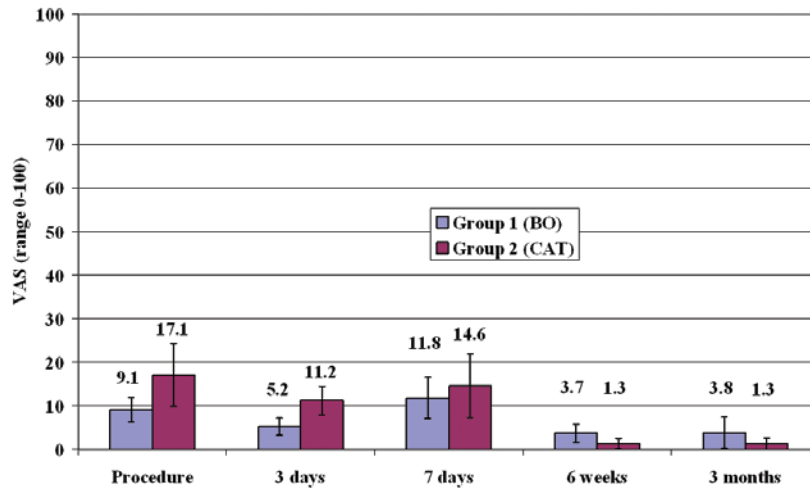
There were no statistically significant differences in pain scores (Figure-2) or analgesic use between the groups. No patient had severe pain requiring opiates or regional anaesthesia.

Mean serum TT decreased significantly from day 3 in group 1 (BO) and was significantly lower than in group 2 (CAT) on days 3 and 7 and at 6 weeks (Figure-3). Mean serum TT in group 2 was significantly lower than baseline on days 3 and 7, but not at 6 weeks. Serum TT was below castration level (< 1.7

nmol/L) in all patients in group 1 from day 3 onwards, but in only 3/10 patients at 3 days, 4/10 at 7 days and 1/10 at 6 weeks in group 2 (Table-1).

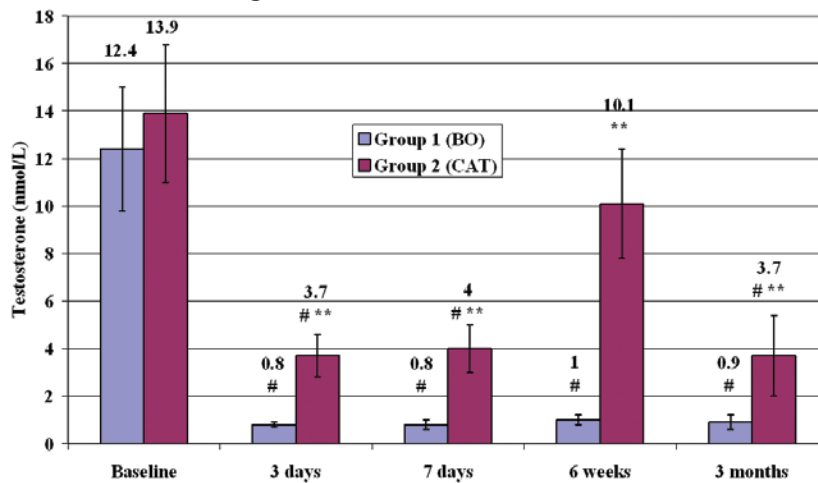
In group 2, 9 patients above castration level not castrate at 6 weeks after CAT were offered BO. This was performed within 3 months in 8 of these patients. The remaining patients initially refused BO, but later consented and the procedure was performed 7 months after the initial CAT. Histological examination of the testes removed after CAT

*Figure 2 - Visual analog pain score.*



\*\* statistically significant difference compared to group 1 at corresponding time.

*Figure 3 - Serum testosterone.*



# statistically significant difference compared to value at randomization in same group.

showed blood vessels that were thickened but patent, with areas of fibrosis. The lumen of the vas deferens was obliterated.

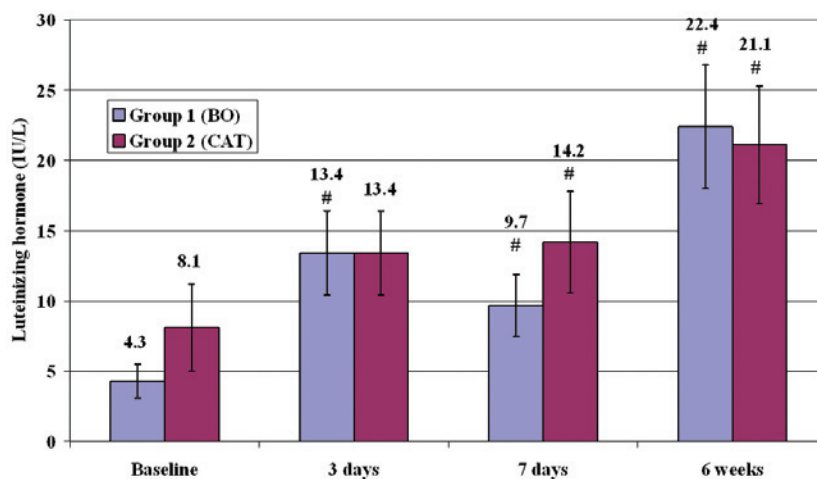
Mean serum LH increased significantly compared to baseline in group 1 from day 3, and in group 2 from day 7 onwards (Figure-4).

Mean serum PSA was significantly lower than baseline at 6 weeks and 3 months in group 1, but did not decrease significantly in group 2 (Figure-5).

Mean testis volume increased significantly on day 7 and decreased significantly at 6 weeks in group 2 (Figure-6).

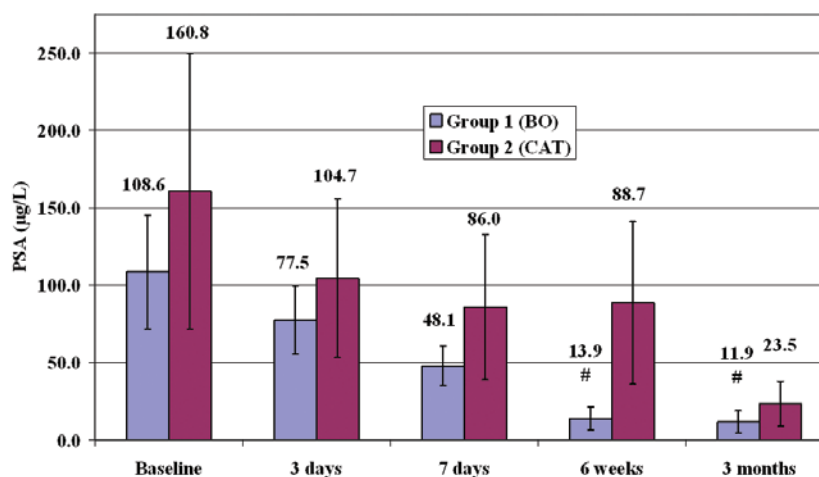
No vaso-vagal attacks crisis or other adverse events occurred during any of the procedures. In group 2, linear bruising of the scrotal skin in the areas where the clamp was applied occurred in all patients, but had completely disappeared by 6 weeks in all cases. Overall, complications were more common

Figure 4 - Serum luteinizing hormone.



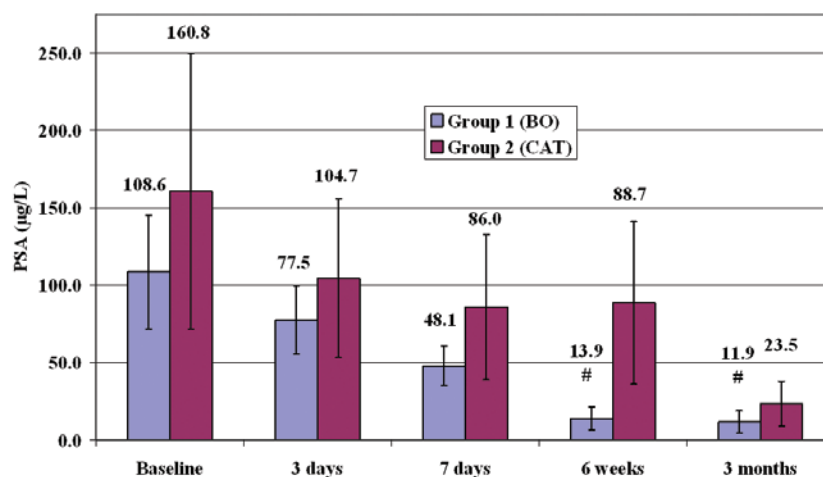
# statistically significant difference compared to value at randomization in same group.

Figure 5 - Serum prostate specific antigen.



# statistically significant difference compared to value at randomization in same group.

Figure 6 - Testicular volume.



# statistically significant difference compared to value at randomization in same group.

in group 1 (89%) than group 2 (40%) ( $p = 0.057$ ) and 4/9 patients required antibiotics for wound infection after BO (Table-1).

## DISCUSSION

The ethical aspects of this study were thoroughly reviewed and discussed before approval of the protocol by the institutional review board. Numerous surgical techniques and medicines that are used in veterinary practice are also used in humans, and vice versa. Therefore, the fact that the Burdizzo clamp is used in veterinary practice should not, in itself, preclude its use in humans. Performing an animal study to evaluate testosterone and PSA levels after clamp ablation would not provide an answer to the question whether this technique is feasible in humans or would produce the same effect as in veterinary practice, where it is well established as an effective form of incisionless castration. Parental consent for neonatal circumcision under local anesthesia is generally accepted from an ethical point of view; therefore, CAT under local anesthesia in adult men with advanced ACP who have given written, informed consent should also be ethically acceptable.

Theoretically, CAT has several potential advantages. It is incisionless, does not require aseptic technique, sterilized surgical instruments, electro-

cautery or suture materials, and it avoids the risks of postoperative hematoma formation, wound infection with abscess formation or wound dehiscence. It can be performed more rapidly and at much lower cost than BO. In men who find surgical castration unacceptable, it may be psychologically and cosmetically more acceptable than BO, because it does not involve removal of the testes.

In the present study CAT was performed in an operating room because of initial concern about the risk of a vaso-vagal reaction requiring the availability of resuscitation facilities adequate treatment. However, CAT can be easily performed outside an operating room, because aseptic technique is not necessary.

The probable mechanism of action of CAT is damage to the blood vessels, presumably intimal injury, leading to subsequent thrombosis, therefore testicular infarction should not be dependent on the duration of clamping. The literature describes successful outcomes in veterinary practice after clamp application times varying from less than 5 seconds to 60 seconds. Up to 70% of practitioners apply the clamp twice or more to each cord (6,7,10,12).

The results of this study indicate that CAT delivered a significant injury to the testes, causing a statistically significant but transient decrease in the mean serum TT level and a sustained increase in mean serum LH. However, CAT was not as effective

as BO in decreasing the serum TT level. The mean TT level by 6 weeks after CAT had increased compared with the mean value at 7 days, possibly because there was a concomitant increase in LH level. Mean testicular volume increased significantly at 7 days, probably due to an inflammatory response resulting from ischaemia-ischemia-reperfusion injury, and decreased significantly at 6 weeks.

The histological findings in the testes removed 6 weeks after CAT showed that, although the lumen of the vas deferens was obliterated, there were still some patent blood vessels. This indicates that CAT, as performed in this study, was not sufficiently effective in causing arterial vessel injury leading to complete obliteration of testicular blood supply. However, if the technique can be modified to achieve complete ischaemic-ischemic infarction of the testes, CAT may offer a rapid, low-cost form of incisionless surgical ADT in men with advanced ACP who do not have access to medical ADT and who find BO psychologically or cosmetically unacceptable.

## CONCLUSIONS

In this study CAT was quicker to perform and had a lower complication rate compared with BO under local anaesthesia. CAT caused significant testicular ischaemic injury, but was not as effective as BO in achieving castrate serum TT levels. However, if the technique of CAT can be adapted to achieve complete infarction of the testes, it may become a cost-effective and appealing form of ADT in men who find BO unacceptable and do not have access to expensive LHRHa therapy.

## ABBREVIATIONS

ACP adenocarcinoma of the prostate; ADT androgen deprivation therapy; BO bilateral orchiectomy; CAT clamp ablation of the testes; LH luteinizing hormone; LHRH luteinizing hormone releasing hormone; PSA prostate specific antigen; TT testosterone; VAS visual analog scale;

## CONFLICT OF INTEREST

None declared.

## ACKNOWLEDGEMENT

This study was funded by a research grant from the Urological Association of South Africa.

## REFERENCES

1. Aus G, Abbou CC, Bolla M, Heidenreich A, Schmid HP, van Poppel H, et al.: EAU guidelines on prostate cancer. *Eur Urol.* 2005; 48: 546-51.
2. Sharifi N, Gulley JL, Dahut WL: Androgen deprivation therapy for prostate cancer. *JAMA.* 2005; 294: 238-44.
3. De Paula AA, Piccelli HR, Pinto NP, Teles AG, Franqueiro AG, Maltez AR, et al.: Economical impact of orchiectomy for advanced prostate cancer. *Int Braz J Urol.* 2003; 29: 127-30; discussion 130-2.
4. Stafford KJ, Mellor DJ: The welfare significance of the castration of cattle: a review. *N Z Vet J.* 2005; 53: 271-8.
5. Zufall R: Use of Burdizzo clamp to crush vas. *J Urol.* 1958; 80: 199-202.
6. Kent JE, Thrusfield MV, Robertson IS, Molony V: Castration of calves: a study of methods used by farmers in the United Kingdom. *Vet Rec.* 1996; 138: 384-7.
7. Ortega-Pacheco A, Bolio-González ME, Colin-Flores RF, Sauri-Arceo CH, Gutiérrez-Blanco E, Jiménez-Coello M, et al.: Evaluation of a Burdizzo castrator for neutering of dogs. *Reprod Domest Anim.* 2006; 41: 227-32.
8. Herzog ME, Santucci RA: Incisionless in-office castration using a veterinary castration device (Burdizzo clamp). *Urology.* 2002; 59: 946.
9. Hinman F Jr. *Atlas of Urologic Surgery.* WB Saunders Co. 1992; 375.
10. Grabe M: Antibiotic prophylaxis in urological surgery, a European viewpoint. In: Naber KG, Schaeffer AJ, Heyns CF, Matsumoto T, Shoskes DA, Bjerklund Johansen TE (ed.), *International Consultation on Urogenital Infections.* Publisher. European Association of Urology. Chapter 12.5. 2010; pp. 686-98.
11. Mellema SC, Doherr MG, Wechsler B, Thuerer S, Steiner A: Influence of local anaesthesia on pain and distress induced by two bloodless castration methods in young lambs. *Vet J.* 2006; 172: 274-83.
12. Fisher AD, Crowe MA, Alonso de la Varga ME,

Enright WJ: Effect of castration method and the provision of local anesthesia on plasma cortisol,

scrotal circumference, growth, and feed intake of bull calves. *J Anim Sci.* 1996; 74: 2336-43.

**Correspondence address:**

Dr. C F Heyns  
Department of Urology  
PO Box 19063  
Tygerberg, 7505, South Africa  
Fax: + 27 21 933-8010  
E-mail: cfh2@sun.ac.za

*Accepted after revision:  
November 29, 2010*

**EDITORIAL COMMENT**

The basis of androgen deprivation (AD) in prostate cancer was established, back in 1941, by Huggins and Hodges (1). The dramatic clinical regression of advanced disease with the surgical or medical hormonal blockade was awarded by a Nobel Prize in 1967. In 1971, Schally et al., discovered and developed an analogue of luteinizing hormone releasing hormone (LH-RH), as effective as orchiectomy, which also rendered a Nobel Prize (2). All AD modalities may have negative or adverse events, such as depression due to the empty scrotum, high costs (analogues of LH-RH), gynecomastia and cardiovascular toxicity (estrogens) (3). The present article aimed to test a new, less-inva-

sive, low-cost and incisionless approach to achieve hormonal blockade. The authors used a veterinary instrument (Burdizzo clamp) applied to the scrotum, in order to cause testes infarction by crushing the gonadal vessels. The major objective was to compare orchiectomy with this novel method, but the vascular damage caused by the clamp was not severe enough to sustain low testosterone levels. Almost seventy years have gone since Huggins and Hodges published the benefits of orchiectomy. Despite few modifications in the original technique were presented (subcapsular orchiectomy), up to date, no other surgical or medical castration method showed to be more efficient, rapid, low cost and less complicated treatment for advanced prostate cancer. It really deserved a Nobel Prize!

**REFERENCES**

1. Huggins C, STEVENS RE, Hodges CV: Studies on prostatic cancer II: the effects of castration on advanced carcinoma of the prostate gland. *Arch Surg.* 1941; 43: 209-23.
2. Schally AV, Arimura A, Baba Y, Nair RM, Matsuo H, Redding TW, et al.: Isolation and properties of the FSH and LH-releasing hormone. *Biochem Biophys Res Commun.* 1971; 43: 393-9.
3. Lepor H: Comparison of single-agent androgen suppression for advanced prostate cancer. *Rev Urol.* 2005; 7(Suppl 5): S3-S12.

***Dr. Adriano Augusto Peclat de Paula***  
*Hospital Araujo Jorge*  
*Association Against Cancer of Goias, Brazil*  
*E-mail: adrianopaula@brturbo.com.br*