

## Bladder Substitution by Ileal Neobladder for Women with Interstitial Cystitis

Wachira Kochakarn, Panuwat Lertsithichai, Wipaporn Pummangura

*Division of Urology, Department of Surgery, School of Medicine Ramathibodi Hospital, Mahidol University, Bangkok, Thailand*

---

### ABSTRACT

*Objective:* To report our experience with cystectomy and ileal neobladder for women with interstitial cystitis (IC).

*Materials and Methods:* Thirty-five female patients treated during 2000-2005 with the mean age of  $45.9 \pm 4.4$  years were included in this study. All of them had experience suprapubic pain with irritative voiding symptoms and were diagnosed as having IC based on NIDDK criteria for at least 2 years. Conservative treatments had failed to relieve their symptoms; and therefore all of them agreed to undergo a bladder removal. For cystectomy, the urethra was cut 0.5 cm below the bladder neck, proximal to the pubourethral ligament, leaving the endopelvic fascia intact. An ileal segment of 65 cm was used to create the neobladder with the Studer's technique.

*Results:* All patients presented good treatment outcome with regard to both diurnal and nocturnal urinary control without any pain. Quality of life using the SF-36 questionnaire showed significant improvement of both physical health and mental health. Spontaneous voiding with minimal residual urine was found in 33 cases (94.3%), and the remaining 2 cases (5.7%) had spontaneous voiding with residual urine and were placed on clean intermittent catheterization (CIC). Twelve out of 30 cases with sexually active ability had a mild degree of dyspareunia but without disturbance to sexual life.

*Conclusion:* Bladder substitution by ileal neobladder for women who suffer from IC can be a satisfactory option after failure of conservative treatment. Resection of the urethra distal to the bladder neck can preserve continence and allow spontaneous voiding in almost all patients.

*Key words:* interstitial cystitis; surgery; ileum; bladder

*Int Braz J Urol. 2007; 33: 486-92*

---

### INTRODUCTION

Interstitial cystitis (IC) is a chronic inflammatory disease of the bladder with unknown etiology. It is characterized by suprapubic pain, urinary frequency and urgency (1). Due to severity of symptoms, the patient with IC becomes socially incapacitated (2). Treatment is mostly non-curative because of its yet unknown etiology. Therefore, oral medications, many kinds of intravesical instillations,

neuromodulation, hydrodistention of bladder and acupuncture are introduced as means of treatments (3). Moreover, surgery is recommended as the treatment of choice in the intractable cases that do not respond to conservative treatment (4). Because of little knowledge about the female continence mechanism, supratrigonal cystectomy and replacement using intestinal segment are introduced. Preservation of the trigone makes patients continent because there is no damage to the autonomic nerve system. On the

other hand, preservation of trigone prevents spontaneous voiding in this group of patients (5). Benjary & Politano in 1995 advised to cut the urethra distal to the bladder neck and reported spontaneous voiding and patients completely dry (6).

In the present paper, we reported our experience with this technique with long-term follow up.

## MATERIALS AND METHODS

From January 2000 to December 2005, a total of 35 women aged from 35-53 years (mean = 45.9 ± 4.4 years) who underwent total cystectomy and bladder replacement due to intractable IC were included in this study. The follow-up time was 15 to 68 months (mean 28 months). All patients presented symptoms of frequency, urgency to urinate and suprapubic pain relief by voiding. All of them were proven as IC according to the National Institute of Diabetes and Digestive and Kidney Diseases (NIDDK) criteria. Cystoscopy revealed glomerulation in all cases and no Hunner's ulcer was noted in any case. Awake cystometric bladder capacity was done and the results are shown in Table-1. Unresponsive to conservative treatment including medical, intravesical and bladder hydrodistention were noted for at least 2 years. All patients suffered from severe intractable symptoms and had agreed to bladder removal.

Hysterectomy was performed in 32 patients who had enough children or were postmenopausal. The bladder was removed and the urethra was sectioned proximal to the pubourethral ligaments and

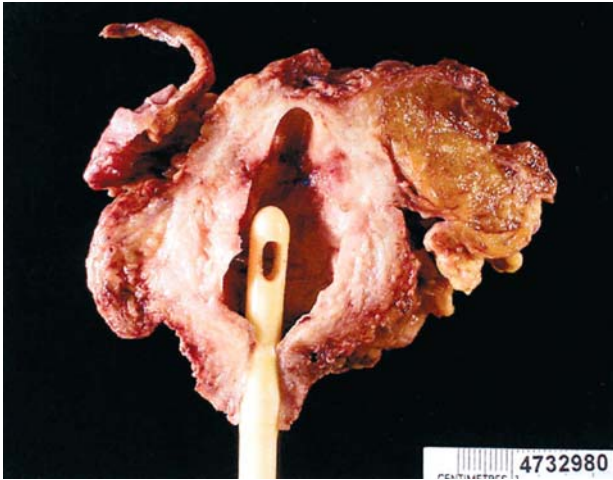
0.5 cm distal to the bladder neck, leaving the endopelvic fascia intact as described by Benjary & Politano (6) and shown in Figure-1. Bladder substitution was then carried out by using a 65 cm ileal segment as described by Studer et al. (7). In the case of hysterectomy, the vaginal wall was closed with a double row of 2-0 polyglycolic sutures (Figure-2). The omentum was harvested to keep vascular supply intact and over sewn with vaginal stump keeping as back support of neobladder. Kinking between the urethra and the neobladder as well as fistula formation is prevented by omentum covering (Figure-3 and 4).

Intraoperative complications, as well as immediate and late consequences were studied. Voiding pattern and continence were determined by expert nurse personal interviews during regular follow-up. The patients were classified as spontaneous voiding with minimal residual urine, spontaneous voiding with significant residual urine (more than 100 mL) and unable to void. Daytime continence was defined as completely dry without any pad. Nighttime continence was defined when the patient was dry without need for pads and uncontrolled urinary leakage. Pain was evaluated by using visual analog scale (VAS) with scoring from 1-10. Quality of life (QoL) was evaluated at 3 months and 6 months by using SF-36 questionnaire that was translated into Thai. Questionnaire reliability as well as validity was assessed following previous studies (8). The SF-36 questionnaire is a generic instrument assessing eight domains: physical functioning, role physical health, body pain, general health, vitality, social functioning, role emotion and mental health. We analyzed into two groups: physical health and mental health, scores range from 0-100 for each dimension, with 100 indicating optimum QoL.

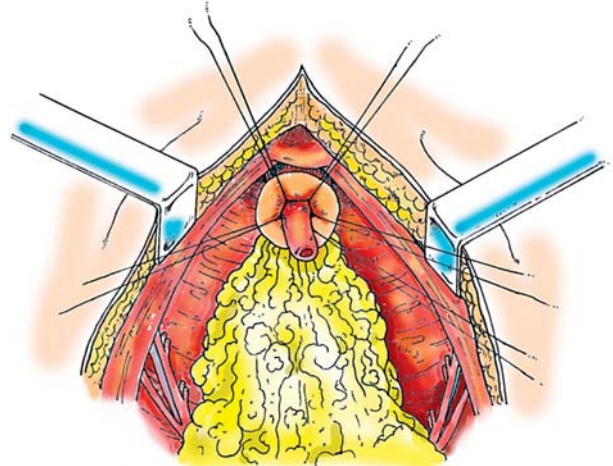
**Table 1** – Baseline and follow up data on bladder capacity, pain score and SF36 score, mean (SD).

Outcome	Baseline	3 Months	6 Months	12 Months	p Value
Bladder capacity (mL)	170.6(61.5)	-	462.3(54.9)	-	<0.001*
Pain score (VAS) SF-36	9.8(0.43)	3.9(1.0)	1.7(0.70)	1.8(0.55)	<0.001**
Physical health score SF-36	55.7(2.3)	-	-	82.6(1.8)	<0.001*
Mental health score	50.7(1.7)	-	-	75.7(2.7)	<0.001*

\* = paired t-test; \*\* = repeated measures ANOVA.

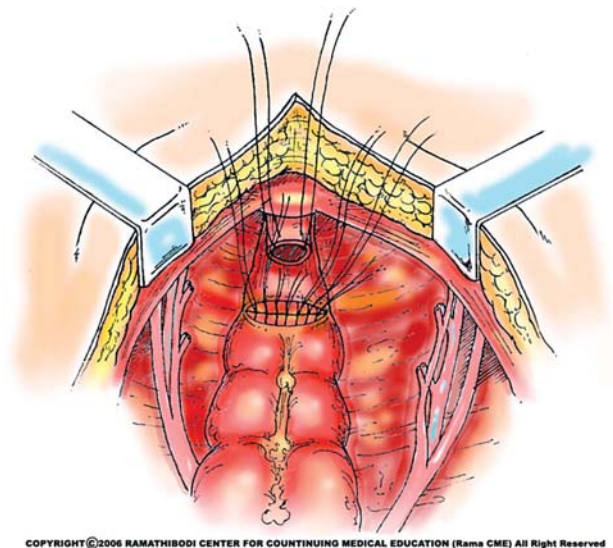


**Figure 1** – Bladder specimen.



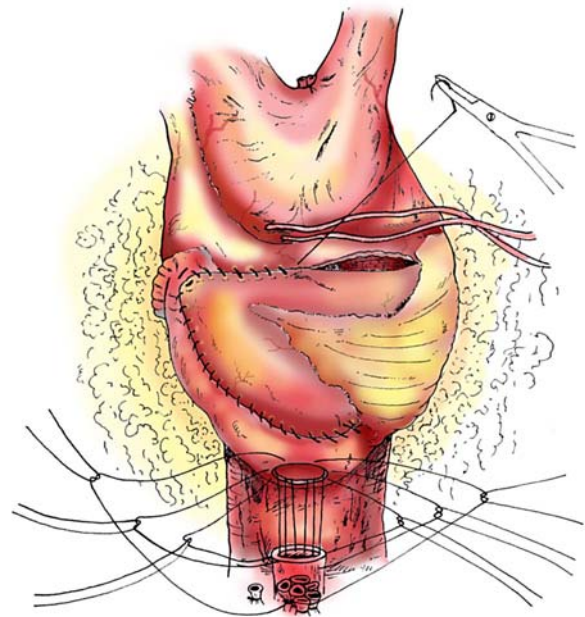
COPYRIGHT © 2006 RAMATHIBODI CENTER FOR CONTINUING MEDICAL EDUCATION (Rama CME) All Right Reserved

**Figure 3** – Omentum is used over sewn with vaginal stump. Dead space of pelvis is obliterated and omentum act as back support for neobladder.



COPYRIGHT © 2006 RAMATHIBODI CENTER FOR CONTINUING MEDICAL EDUCATION (Rama CME) All Right Reserved

**Figure 2** – View of the pelvis from above with urethral suture placement as well as vaginal stump suture, leave sutured end for over sewn with omentum.



COPYRIGHT © 2006 RAMATHIBODI CENTER FOR CONTINUING MEDICAL EDUCATION (Rama CME) All Right Reserved

**Figure 4** – Studer's ileal neobladder is placed using 5 stitches of polyglycolic acid seromuscular sutures.

All of the patients came to follow up at 2 weeks, 3 months, and 6 months after operation. If no major side effects were noted, yearly check up was done. Ultrasonography, urea, creatinine and routine blood chemistry were performed at 3 months, 6 months and yearly. When indicated, intravenous pyelography,

renal scan and endoscopic examination were performed.

Statistical methods were used to analyze continuous and ordinal data and summarized as mean

$\pm$  SD. Statistical comparison of continuous or ordinal outcomes before and after an operation was performed using paired t-test or, in the case of pain score, by repeated measures ANOVA. Statistical significance was defined as a p-value of 0.05 or less. Stata v.7 (Stata Corp, College Station, TX, USA) was used for all statistical analyses.

## RESULTS

On reviewing the medical records, no intraoperative complications were noted. One case developed intestinal obstruction in the second week after operation and improved with conservative treatment. Postoperatively, all of the patients had pain improvement through visual analog scale and all of them returned to normal life within 2 months. The average pain score is plotted against the follow-up time as shown in Figure-5, where the spread of the data at each time point is also shown.

There was a highly significant increase in bladder capacity 6 months after operation. The pain score significantly and consistently decreases after operation reaching a minimum from 6 to 12 months after operation. The quality of life as measured by the SF-36 v. 2 scale showed a significant increase in the scales of both physical and mental health components (Figure-5).

At the follow up of 6 months, diurnal and nocturnal continence were achieved in all of them (100%). Spontaneous voiding was noted in 33 cases and the other 2 cases were spontaneous voiding with significant residual urine. Residual urine was recorded around 100-250 mL and clean intermittent catheterization was used. Three patients experienced acute pyelonephritis in one month, 4 months and 6 months, respectively. All were cured after conventional treatment and had no recurrent infection since the last follow up. On the late follow up, bilateral hydronephrosis was found in one case but renal scan

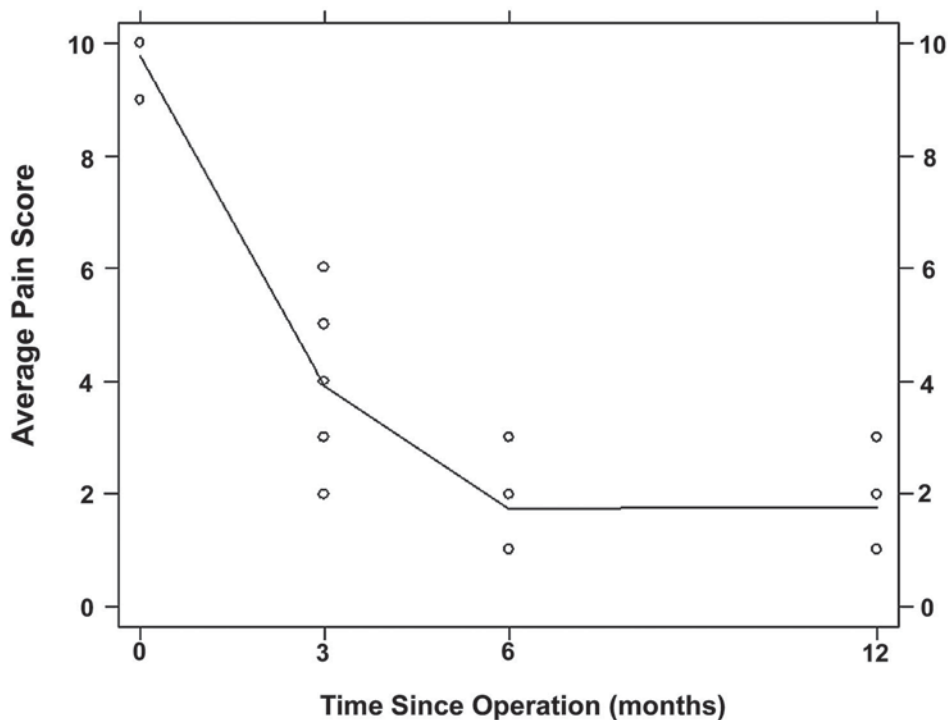


Figure 5 – Plot of average pain score versus follow-up time in months, showing data spread at each time point.

showed no anatomical obstruction. Mucous plug was found in almost all of the cases but intermittent bladder irrigation in the early postoperative period was enough to get rid of this problem. No mucous plug was reported after 6 months of surgery. Neobladder stone developed in one case and treated endoscopically. No stress incontinence was found in all cases. Among 30 cases of sexually active patients, 12 cases had mild degree of dyspareunia during the first year and no patient had disturbance in sexuality after 1 year of follow up.

## COMMENTS

Interstitial cystitis (IC) encompasses a major portion of the chronic painful bladder syndrome. It is characterized by suprapubic pain, irritative voiding symptoms including frequency, urgency and dysuria (1). Interstitial cystitis predominantly affects middle-aged women but it is occasionally found in men. On a surveying study, IC affects 10.6 per 100,000 people with male to female ratio of 1 to 12 (9). Criteria for diagnosis of IC are chronic irritative voiding symptoms, sterile urine and characteristic cystoscopic findings (10). Potassium test was mentioned as one modality for diagnosis but it was found to be not specific for IC (11). The diagnosis of this condition is usually delayed due to the lack of knowledge of diagnosis criteria. Treatment is mostly palliative and non-curative because its etiology is still obscure (3). Only chronic inflammatory cells infiltrate in the bladder wall, particularly mast cells without infective agents were mentioned in pathological examinations (12). Many reported series have suggested that IC may be a cell-mediated autoimmune disorder. Familial history is also found, so genetic predisposing may be another factor determining the etiology of IC (13).

Many types of treatment have been used for the management of IC including oral medications, hydrodistention, intravesical instillation of DMSO, heparin and BCG. Also, immunosuppressive drugs with corticosteroid and azathioprine are mentioned as treatment of IC (14). After treatment failure, neuromodulation, acupuncture or even urinary diversions were used (15). In cases of failure of all conservative treatments, cystectomy with

enterocystoplasty is used in many institutes. At the beginning of bladder substitution in women, supratrigonal cystectomy was done to avoid urinary incontinence, nevertheless, hypercontinence was the result and patients were unable to urinate and, therefore, clean intermittent catheterization was needed for urinary drainage (16). Even leaving only vestigial bladder muscle, persistent painful bladder was still present (17). Webster & Maggio reported complete painful relief after additional removal of the trigone in patients submitted to supratrigonal cystectomy and enterocystoplasty for treating IC (18).

Urinary incontinence after a neobladder operation depends on creating adequate storage reservoir and preserving the sphincteric mechanism. Sectioning the urethra below bladder neck in female patients can maintain the continence mechanism with better emptying than in the case of bladder neck preservation (19). In cases where the sphincteric mechanism is not functional enough to prevent urinary leakage, Kegel exercises is recommended (20). In the postoperative period, daily use of saline irrigations into bladder can get rid of mucous plug that usually obstructs voiding (21). Nerve sparing cystectomy is another factor believed to provide early continence in female patients. Sparing of autonomic nerve fibers supply beneath the urethra was found to provide early urinary control in derived patients. Keeping endopelvic fascia intact not only preserves the nerve but also keeps urethropelvic ligament, enhancing urinary control (22).

The use of cystectomy with ileal neobladder for treatment of patients with bladder carcinoma has been reported with long-term follow up, demonstrating that this operation is safe for female patients (23). After gaining more experience in treatment of bladder malignancy, we were more confident to perform this operation in a benign bladder disease as IC. There is a small risk of developing malignancy in the neobladder and it usually occurs after 15 years postoperatively (24). Metabolic and nutritional complications may result with the use of B12 and fat-soluble vitamins, chronic metabolic acidosis, intestinal osteopathy and diarrhea. Although periodical follow up for any metabolic or nutritional disorder is suggested, bladder reconstruction with ileum is safer than reconstruction with colon (25). Our study confirmed that this operation

is safe with minimal complication and allow our patients with IC to enjoy a better quality of life after bladder removal.

We concluded that bladder substitution with ileal neobladder may be an appropriate option in intractable symptomatic interstitial cystitis patients. Urethral resection distal to bladder neck, nerve preservation, and leaving endopelvic fascia intact can preserve continence and spontaneous voiding.

### CONFLICT OF INTEREST

None declared.

### ACKNOWLEDGEMENTS

Dr. Amnuay Thithapandha provided suggestions and manuscript corrections.

### REFERENCES

- Gillenwater JY, Wein AJ: Summary of the National Institute of Arthritis, Diabetes, Digestive and Kidney Diseases Workshop on Interstitial Cystitis, National Institutes of Health, Bethesda, Maryland, August 28-29, 1987. *J Urol.* 1988; 140: 203-6.
- Burkman RT: Chronic pelvic pain of bladder origin: epidemiology, pathogenesis and quality of life. *J Reprod Med.* 2004; 49: 225-9.
- Geirsson G, Wang YH, Lindstrom S, Fall M: Traditional acupuncture and electrical stimulation of the posterior tibial nerve. A trial in chronic interstitial cystitis. *Scand J Urol Nephrol.* 1993; 27: 67-70.
- Blaivas JG, Weiss JP, Desai P, Flisser AJ, Stember DS, Stahl PJ: Long-term followup of augmentation enterocystoplasty and continent diversion in patients with benign disease. *J Urol.* 2005; 173: 1631-4.
- Peeker R, Aldenborg F, Fall M: The treatment of interstitial cystitis with supratrigonal cystectomy and ileocystoplasty: difference in outcome between classic and nonulcer disease. *J Urol.* 1998; 159: 1479-82. Erratum in: *J Urol* 1998; 160: 136.
- Bejany DE, Politano VA: Ileocolic neobladder in the woman with interstitial cystitis and a small contracted bladder. *J Urol.* 1995; 153: 42-3.
- Studer UE, Varol C, Danuser H: Orthotopic ileal neobladder. *BJU Int.* 2004; 93: 183-93.
- Krittayaphong R, Bhuripanyo K, Raungratanaamporn O, Chotinaiwatarakul C, Chaowalit N, Punlee K, et al.: Reliability of Thai version of SF-36 questionnaire for the evaluation of quality of life in cardiac patients. *J Med Assoc Thai.* 2000; 83 (Suppl 2): S130-6.
- Leppilahti M, Tammela TL, Huhtala H, Auvinen A: Prevalence of symptoms related to interstitial cystitis in women: a population based study in Finland. *J Urol.* 2002; 168: 139-43.
- Oberpenning F, van Ophoven A, Hertle L: Interstitial cystitis: an update. *Curr Opin Urol.* 2002; 12: 321-32.
- Gupta SK, Pidcock L, Parr NJ: The potassium sensitivity test: a predictor of treatment response in interstitial cystitis. *BJU Int.* 2005; 96: 1063-6.
- Rosamilia A, Igawa Y, Higashi S: Pathology of interstitial cystitis. *Int J Urol.* 2003; 10 (Suppl): S11-5.
- Dimitrakov JD: A case of familial clustering of interstitial cystitis and chronic pelvic pain syndrome. *Urology.* 2001; 58: 281.
- Theoharides TC, Sant GR: New agents for the medical treatment of interstitial cystitis. *Expert Opin Investig Drugs.* 2001; 10: 521-46.
- Selo-Ojeme DO, Onwude JL: Interstitial cystitis. *J Obstet Gynaecol.* 2004; 24: 216-25.
- Hautmann RE, Paiss T, de Petriconi R: The ileal neobladder in women: 9 years of experience with 18 patients. *J Urol.* 1996; 155: 76-81.
- Singh G, Wilkinson JM, Thomas DG: Supravescical diversion for incontinence: a long-term follow-up. *Br J Urol.* 1997; 79: 348-53.
- Webster GD, Maggio MI: The management of chronic interstitial cystitis by substitution cystoplasty. *J Urol.* 1989; 141: 287-91.
- Venn SN, Mundy AR: 'Nerve-sparing' cystectomy in women. *Int Urogynecol J Pelvic Floor Dysfunct.* 2000; 11: 237-40.
- Hautmann RE: The ileal neobladder to the female urethra. *Urol Clin North Am.* 1997; 24: 827-35.
- Haupt G, Pannek J, Knopf HJ, Schulze H, Senge T: Rupture of ileal neobladder due to urethral obstruction by mucous plug. *J Urol.* 1990; 144: 740-1.
- Chiang PH, Huang YS, Wu WJ, Chiang CP: Orthotopic bladder substitution in women using the ileal neobladder. *J Formos Med Assoc.* 2000; 99: 348-51.
- Hautmann RE, Volkmer BG, Schumacher MC, Gschwend JE, Studer UE: Long-term results of standard procedures in urology: the ileal neobladder. *World J Urol.* 2006; 24: 305-14.

24. Pannek J, Haupt G, Schulze H, Senge T: Influence of continent ileal urinary diversion on vitamin B12 absorption. *J Urol*. 1996; 155: 1206-8.
25. Schrier BP, Laguna MP, van der Pal F, Isorna S, Witjes JA: Comparison of orthotopic sigmoid and ileal neobladders: continence and urodynamic parameters. *Eur Urol*. 2005; 47: 679-85.

*Accepted after revision:  
May 30, 2007*

**Correspondence address:**

Dr. Wachira Kochakarn  
Division of Urology, Dept of Surgery  
School of Medicine Ramathibodi Hospital  
Rama 6 Road, Bangkok 10400 Thailand  
E-mail: ravkc@mahidol.ac.th

**EDITORIAL COMMENT**

The authors report one of the largest series of cystectomy and orthotopic neobladder formation for bladder pain syndrome/interstitial cystitis in the literature. Their results are outstanding, though follow-up is relatively brief. Urologists should be aware that long-term results of cystectomy and continent diversion for this disease are mixed, that pain can become centralized and persist despite cystectomy, and that pain can develop in the urinary reservoir years

after the initial procedure. For patients with severe, longstanding disease unresponsive to standard therapies, urinary diversion with or without cystectomy is certainly a reasonable option. I have preferred conduit diversion because it avoids the possibility of pouch or neobladder pain in the future. As is obvious after reading this report, these procedures are best done in centers by surgeons with extensive experience in reconstructive surgery.

***Dr. Philip M. Hanno***  
*Professor of Urology*  
*University of Pennsylvania*  
*Philadelphia, Pennsylvania, USA*  
*E-mail: hannop@uphs.upenn.edu*