

AN ORTHODONTIC-SURGICAL APPROACH TO CLASS II SUBDIVISION MALOCCLUSION TREATMENT

Marcos JANSON¹, Guilherme JANSON², Eduardo SANT'ANA³, Tassiana Mesquita SIMÃO⁴, Marcos Roberto de FREITAS⁵

1- DDS, MSc, Private Practice, Bauru, SP, Brazil.

2- DDS, MSc, PhD, MRCDC (Member of the Royal College of Dentists of Canada), Professor and Head, Department of Pediatric Dentistry, Orthodontics and Community Health, Bauru School of Dentistry, University of São Paulo, Bauru, SP, Brazil.

3- DDS, MSc, PhD, Associate Professor, Department of Stomatology, Bauru School of Dentistry, University of São Paulo, Bauru, SP, Brazil.

4- DDS, MSc, Orthodontic Graduate Student, Department of Pediatric Dentistry, Orthodontics and Community Health, Bauru School of Dentistry, University of São Paulo, Bauru, SP, Brazil.

5- DDS, MSc, PhD, Professor, Department of Pediatric Dentistry, Orthodontics and Community Health, Bauru School of Dentistry, University of São Paulo, Bauru, SP, Brazil.

Corresponding address: Dr. Guilherme Janson - Universidade de São Paulo - Faculdade de odontologia de Bauru - Departamento de Odontopediatria, Ortodontia e Saúde Coletiva - Alameda Octávio Pinheiro Brisolla 9-75 - 17012-90 - Bauru - SP - Brazil - Business Phone/Fax: 55 14 32344480 - Home Phone/Fax: 55 14 32342650 - e-mail: jansong@travelnet.com.br

Received: September 15, 2008 - Accepted: February 27, 2009

ABSTRACT

Despite the different orthodontic approaches to Class II subdivision malocclusions one has also to consider the skeletal components before undertaking any treatment protocol. Significant involvement of the skeletal structures may require a combined surgical orthodontic treatment, which has remained stable for more than four years, as illustrated in this case report.

Key words: Class II subdivision. Orthodontic-surgical approach.

INTRODUCTION

Class II subdivision malocclusions can be corrected through a variety of treatment protocols, depending on the etiological factor which produces the asymmetric dentoalveolar characteristics of the malocclusion^{1,11-15,24,29}. However, when there is also a severe skeletal component associated with the malocclusion, such as a vertical growth pattern and a retruded mandible, a combined surgical approach would be the best treatment option^{2,7,8,26,30,33}. Therefore, the purpose of this article is to describe the combined surgical/orthodontic diagnosis and treatment of a Class II subdivision malocclusion with these characteristics and discuss the pros and cons of this approach.

DIAGNOSIS AND ETIOLOGY

J.F.P presented for orthodontic treatment at the private office of Dr. MJ with the chief complaint of protrusive incisors and gummy smile. He was 16 years and 9 months old with a Class II Division 1 subdivision right malocclusion with 7mm of overjet, lower midline deviated 2 mm to the right, a retrognathic mandible, a hyperdivergent skeletal pattern and incompetent lips (Figures 1 to 3 and Tables 1 and 2).

TREATMENT OBJECTIVES

The treatment objectives were to improve the facial profile, correcting the retrognathic mandible, the excessive lower anterior face height, the gummy smile and the mandibular dental midline discrepancy, finishing with ideal overbite and overjet.

TREATMENT ALTERNATIVES

Based on the objectives one of the treatment options would be to extract 2 maxillary premolars and 1 mandibular premolar on the Class I side^{1,5,6,11-15,28,29,32}. However, this would not reduce his excessive lower anterior face height and would not improve his retrognathic mandible. Consequently, no improvement in his gummy smile could be anticipated. Another treatment option consisted of extracting the mandibular left first premolar, retracting the lower anterior teeth and surgically advancing the mandible while impacting the maxilla. Maxillary impaction can significantly improve a gummy smile^{3,20,21}. Because the patient and his parents were chiefly concerned with the gummy smile, they chose the second option.

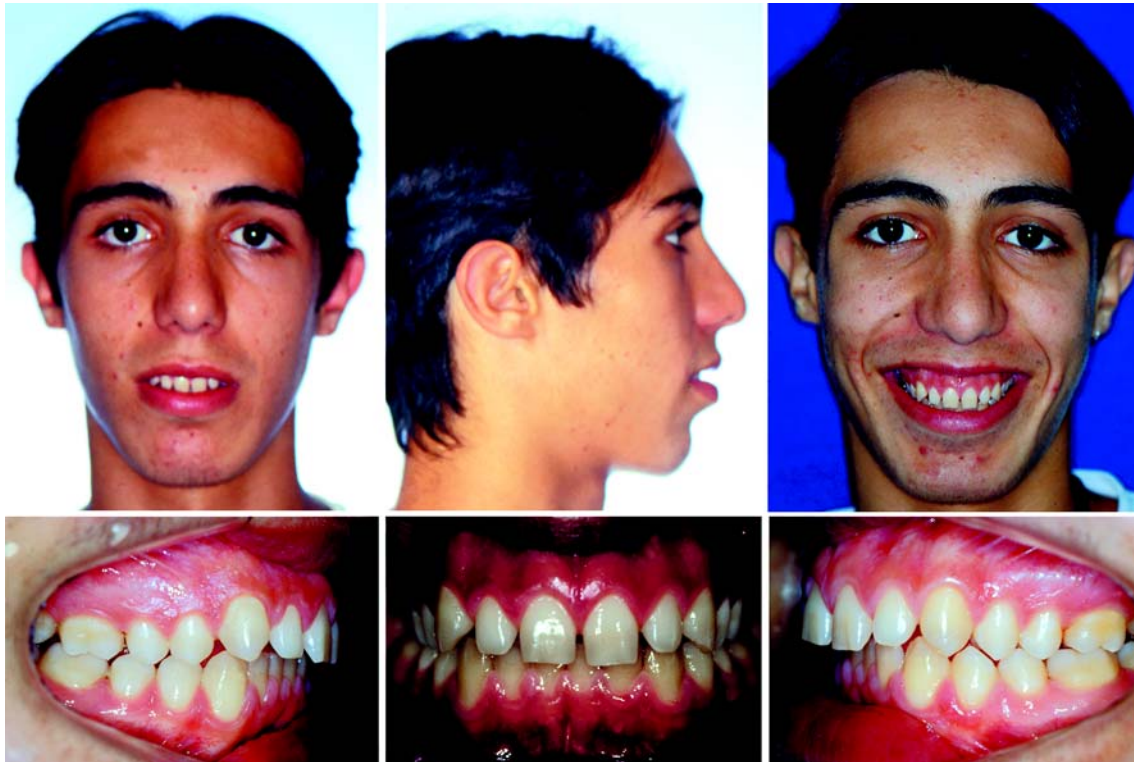

FIGURE 1- Pretreatment extraoral and intraoral photographs (patient signed informed consent authorizing the publication of these pictures)

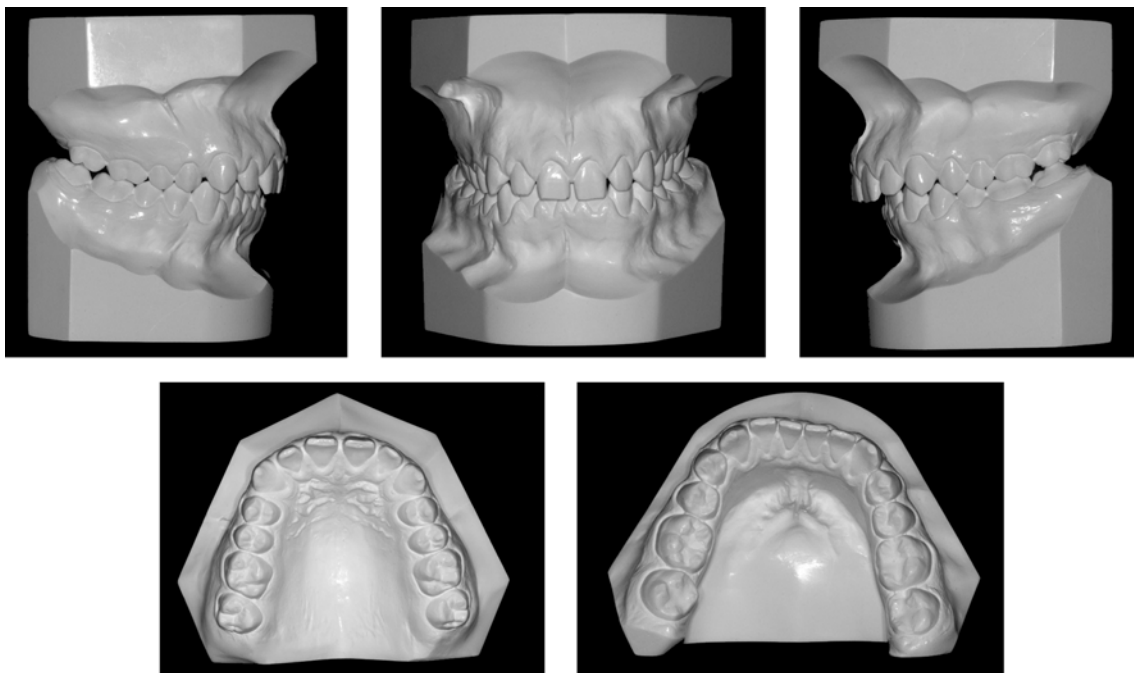


FIGURE 2- Pretreatment study models photographs

TREATMENT PROGRESS

Pre-adjusted 0.022x0.030-inch slot fixed appliances were used. After extraction of the mandibular left first premolar, leveling and alignment with the usual wire sequence of 0.016-inch nitinol, followed by 0.016, 0.018

and 0.020-inch round stainless steel archwires was accomplished (Figure 4). Left anterior retraction was performed with rectangular stainless steel archwires (0.019 x 0.025-inch). Twenty-five months later, when the left canine reached a Class II relationship and the extraction space was closed, orthognathic surgery was undertaken. The surgical

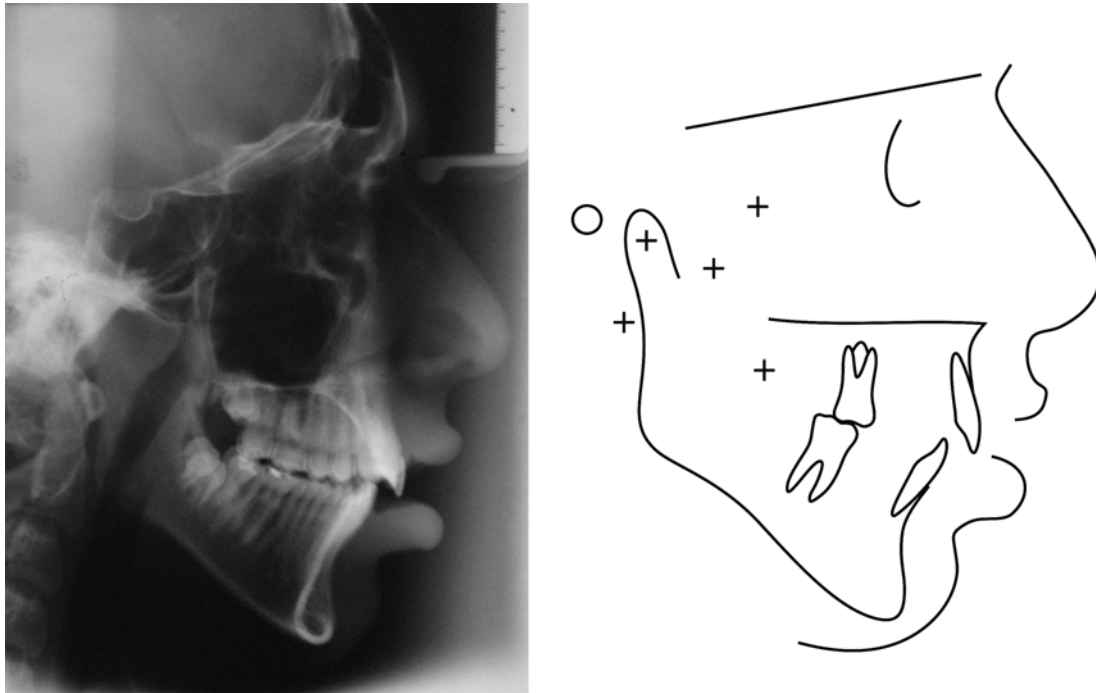


FIGURE 3- Pretreatment headfilm and cephalogram

TABLE 1- Definition of unusual cephalometric variables

A-Nperp	Maxillary component Distance between A point to nasion-perpendicular
Co-A	Distance between Condylion to A point
SN.PP	Angle formed between sella nasion line and palatal plane
	Mandibular component
P-Nperp	Distance between pogonion to nasion-perpendicular
Co-Gn	Distance between condylion to gnathion
	Maxillomandibular relationship
NAP	Supplementary angle formed by point N, A and pogonion.
	Facial Pattern
LAFH	Lower anterior face height: distance from anterior nasal spine to menton.
	Maxillary dental component
Mx1.NA	Maxillary incisor long axis to NA angle
Mx1-NA	Linear distance between the most anterior point of crown of maxillary incisor and NA line
	Mandibular dental component
Md1.NB	Mandibular incisor long axis to NB angle
Md1-NB	Linear distance between the most anterior point of crown of mandibular incisor and NB line
	Soft tissue component
Mentolabial Sulcus	Angle formed between: labrale inferius, soft tissue B point and soft tissue pogonion.
Max1 Exposure	Distance between the maxillary central incisor edge and the upper lip

protocol consisted of impacting the maxilla 7mm anteriorly and 4mm posteriorly, with 1mm of advancement. This would also produce a counter-clockwise mandibular rotation, projecting the chin anteriorly. Surgery in the mandible consisted of an advancement and counterclockwise intramandibular rotation to adapt it to the differential impaction of the maxila. Subsequent minor orthodontic

finishing procedures took an additional year. The patient was retained with a maxillary Hawley plate and a mandibular bonded canine-to-canine retainer. Total active treatment time was 3 years and 1 month.

TABLE 2- Cephalometric status at the pretreatment and posttreatment stages

Measurements	Unit	Standard Values ^{2,9,10,17,19,23,27,31}	Pretreatment	Posttreatment
Maxillary component				
SNA	°	82	77.6	77.8
A-NPerp	mm	+1	- 2.8	- 3.6
Co-A	mm	85	89.8	88.8
Mandibular component				
SNB	°	80	70.4	72.1
P-NPerp	mm	- 2/+4	-18.1	-15.7
Co-Gn	mm	108	117.0	117.0
Maxillomandibular relationship				
ANB	°	2	7.2	5.7
Mx-Md Diff	mm	30	26.8	27.0
NAP	°	1.6	13.2	8.6
Wits	mm	0	6.6	-1.6
Facial Pattern				
SN-Ocl	°	14	12.6	18.9
FMA	°	25	37.4	35.4
SN-GoGn	°	32	45.3	42.5
LAFH	mm	62	76.8	77.3
Maxillary dental component				
Mx1.NA	°	22	13.2	13.3
Mx1-NA	mm	4	2.4	2.4
Mandibular dental component				
Md1.NB	°	25	27.1	34.2
Md1-NB	mm	4	7.1	8.4
IMPA	°	87	89.2	97.7
Soft tissue component				
Nasolabial angle	°	102	97.4	92.3
Mentolabial Sul	mm	4	8.9	6.9
Li-HLine	mm	0 to 0.5	4.8	1.9
Interlabial Gap	mm	2	8.9	2.1
Upper Lip Length	mm	19 to 22	24.5	30.7
Max 1 Exposure	mm	2	8.4	4.3

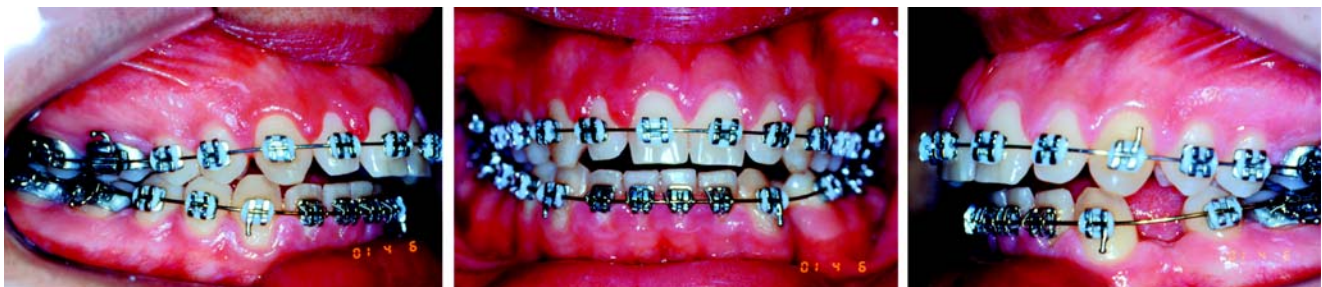

FIGURE 4- Leveling and alignment with 0.020-inch stainless steel archwire

TREATMENT RESULTS

The extraoral photographs show a symmetric, harmonious relationship of the facial soft tissue and a pleasant profile, with

passive lip competence. A Class I bilateral canine occlusion with normal anterior relationship was obtained (Figures 5 to 7). The panoramic radiograph revealed good root parallelism and bone integration in the maxillary right canine area, as well

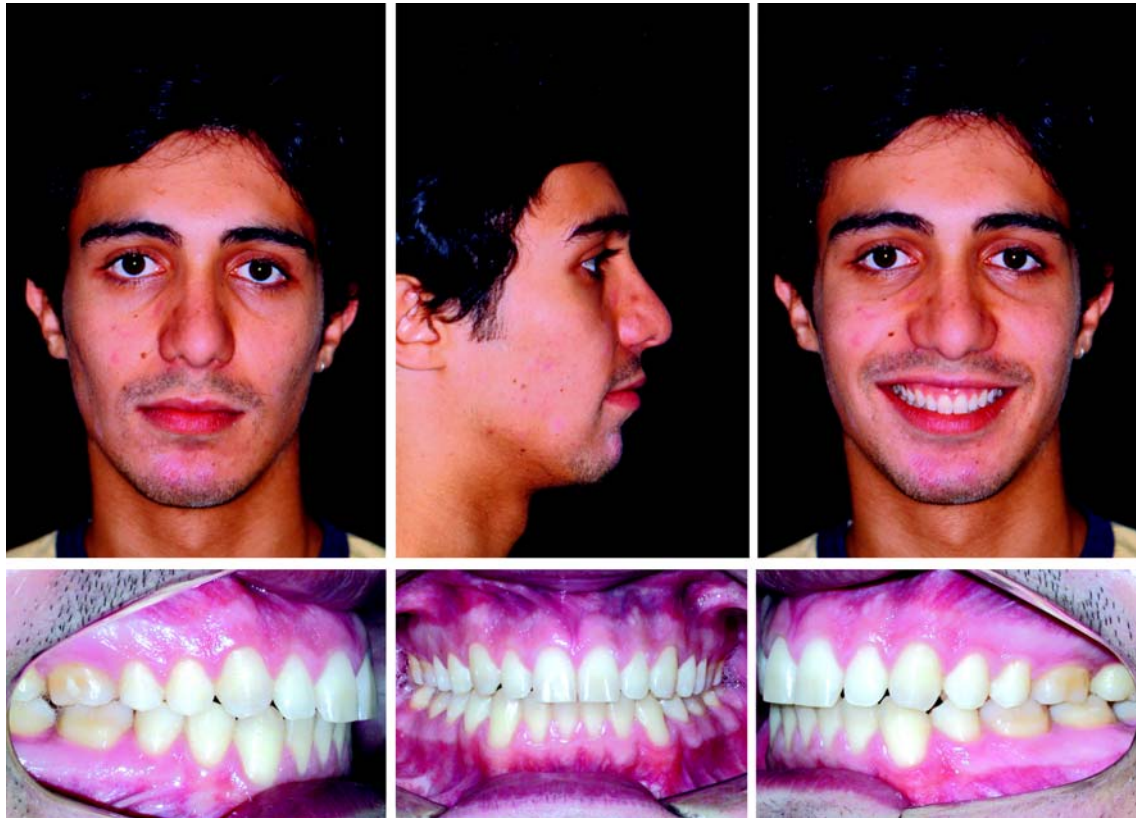


FIGURE 5- Posttreatment extraoral and intraoral photographs (patient signed informed consent authorizing the publication of these pictures)

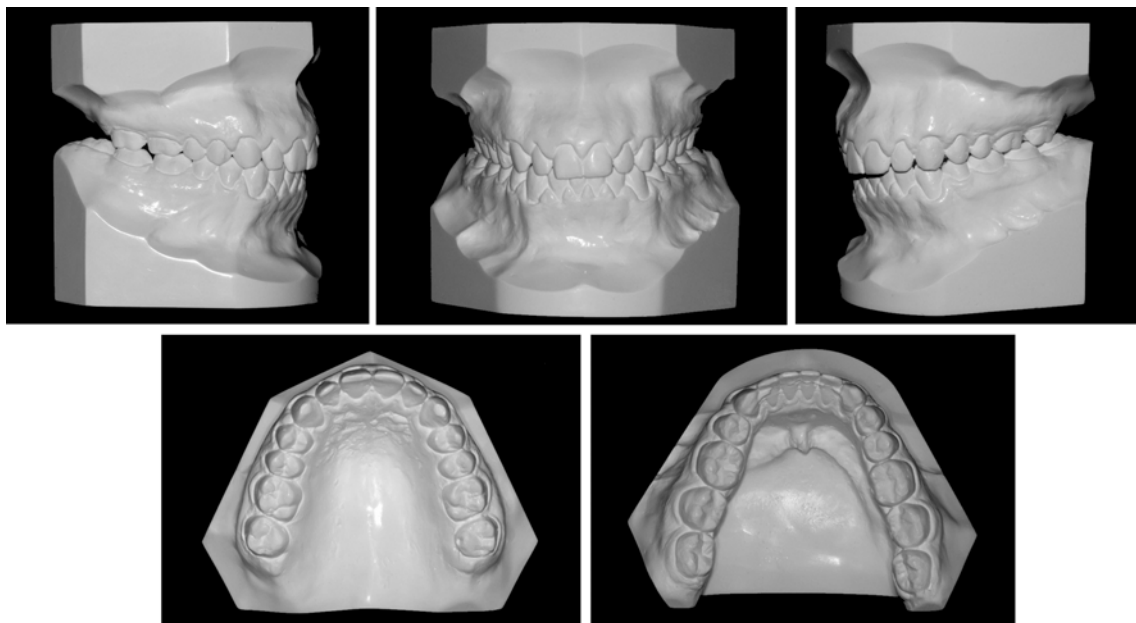


FIGURE 6- Posttreatment study models

as root length control in the maxillary incisors (Figure 8). The superimposition shows the amount of maxillary impaction and consequent mandibular counterclockwise rotation contributing to a more favorable anteroposterior chin position and improvement in lip competence, despite the increase in lower

anterior face height (Figure 9). Cephalometrically, there was no increase in mandibular length, but due to the counterclockwise mandibular rotation there was an increase in mandibular protrusion, which contributed to reduce the apical base anteroposterior discrepancy and profile convexity.

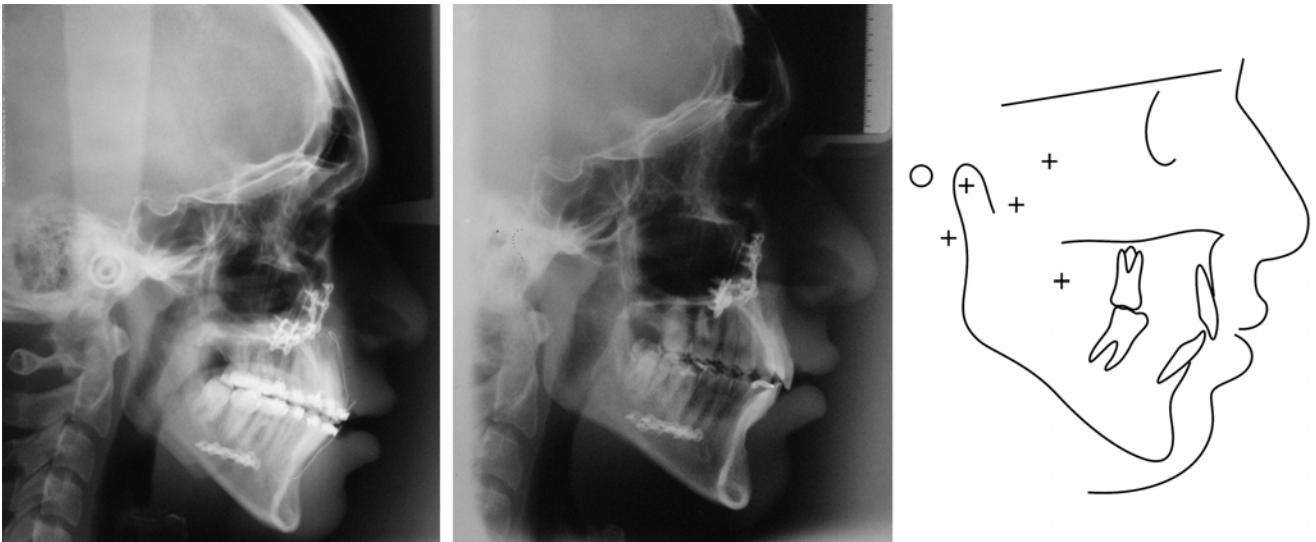


FIGURE 7- A- Headfilm immediately after surgery. B- Posttreatment headfilm and cephalogram

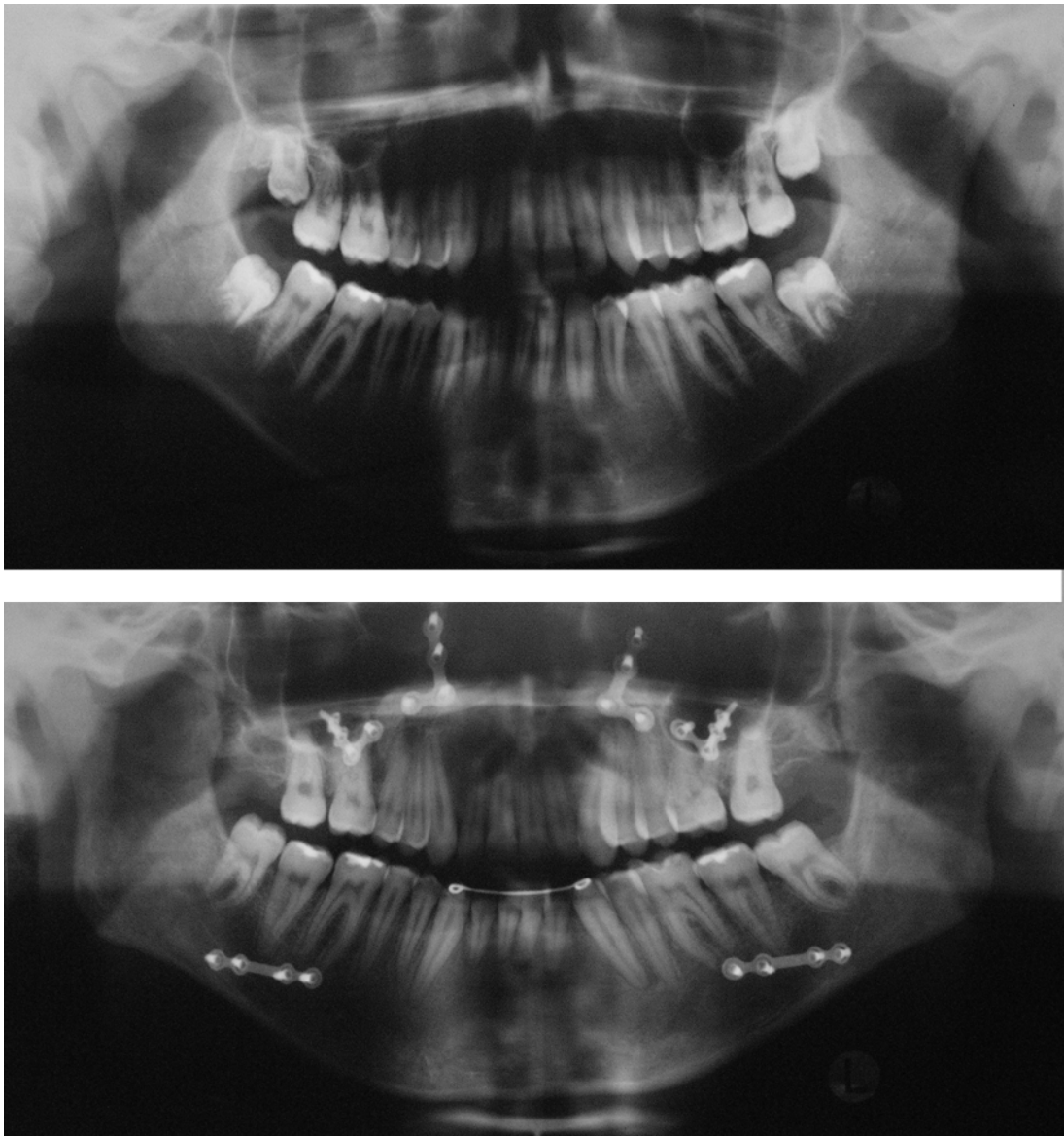


FIGURE 8- A- Pretreatment panoramic radiographs. B- Posttreatment panoramic radiographs

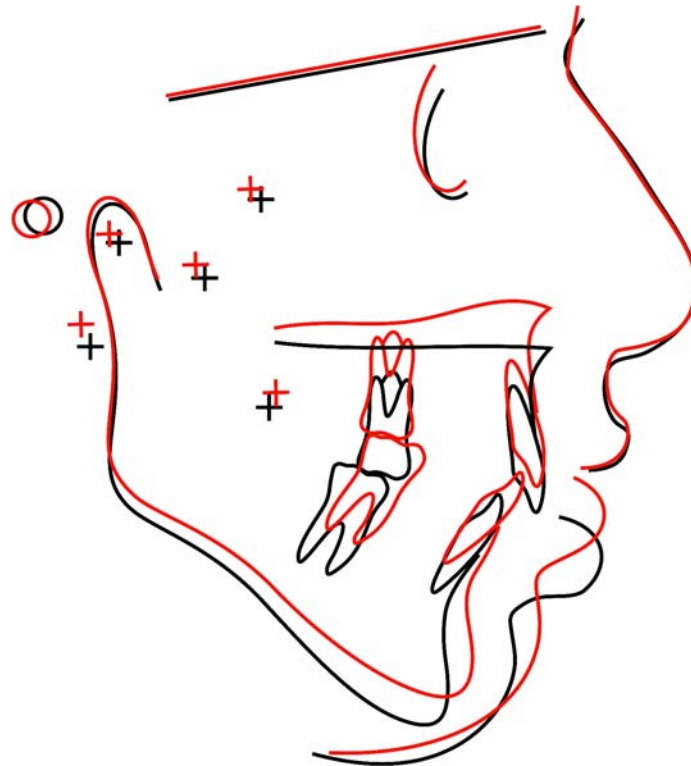


FIGURE 9- Superimpositions of initial and final tracings (black: pretreatment; red: posttreatment)

DISCUSSION

According to recently suggested classification of Class II subdivision malocclusions, this case would be classified as a Type 1 subdivision case because the maxillary midline is coincident to the midsagittal plane and the mandibular midline is deviated to the right^{11-15,29}. It is also suggested in these cases, extraction of two maxillary premolars and one mandibular premolar on the Class I side, provided that the patient's profile allows for some incisor retraction^{1,5,6,11-15,28,29,32}. The patient's profile would allow some retraction of the incisors. However, this treatment protocol would not be able to decrease his gummy smile, which was his chief complaint, and improve his mandibular retrognathism. Therefore, this was the reason why the patient and his parents selected the surgical-orthodontic approach. This shows that despite there are some suggested treatment protocols for Class II subdivision treatment, a thorough examination of all the aspects has to be performed before a conclusive treatment plan is elaborated. Had the patient refused a surgical intervention, the three-premolar extraction protocol could be performed. However, the gummy smile and the mandibular retrognathism would not improve.

Extraction of the first left mandibular premolar and retraction of the anterior segment was performed with the intention of creating a bilateral canine Class II dental malocclusion that would allow symmetric advancement of the mandible, whereas it was asymmetric. If the mandible was asymmetric, maintenance of the asymmetric canine malocclusion would be indicated, requiring surgical correction with asymmetric mandibular advancement¹⁶. With differential impaction of the maxilla, 7mm anteriorly and 4mm posteriorly,

there was a counterclockwise mandibular rotation which concurrently advanced the mandible, correcting the Class II malocclusion. The surgical mandibular advancement was also associated to an intramandibular counterclockwise rotation to adapt it to the differential impaction of the maxilla, so that no increase in the effective mandibular length was observed (Table 2). This treatment protocol was possible to be undertaken because there was no apparent skeletal facial asymmetry of the patient as is usually the case in Class II subdivision patients^{1,15,24} (Figure 1). Therefore, no asymmetric surgery had to be performed.

The cephalometric treatment changes demonstrate the effect of the treatment protocol on the dentoskeletal structures. There was an increase in mandibular prognathism, with resultant improvement in apical base anteroposterior relationship and facial convexity. The SN to occlusal plane angle increased, despite the counterclockwise mandibular rotation. Probably this was consequent to post-surgical use of Class II elastics to improve the dental anteroposterior relationship^{4,18,22,25}. FMA and SN.GoGn decreased, as expected, with the counterclockwise mandibular rotation. Another possible side effect of Class II elastics were the mandibular incisor labial proclination and protrusion that occurred. In fact, despite the good patient compliance with elastics use, the canines on the left side still demonstrate a slight Class II relationship (Figures 5 and 6). The maxillary impaction decreased the interlabial gap and the maxillary incisor exposure. These were the most important changes required by the patient and his parents. Therefore, as these expectations were met with the proposed treatment, they were very satisfied with the results.

CONCLUSIONS

Treatment of Class II subdivision malocclusions, after a careful diagnosis is performed, can be orthodontically handled throughout a variety of treatment protocols. However, if a severe skeletal discrepancy is associated with the malocclusion, a combined orthodontic-surgical approach, as presented, will provide a better esthetic result for the patient. Asymmetry of the malocclusion has to be associated with facial asymmetry. If the face is also asymmetric, the asymmetric malocclusion is maintained pre-surgically, but if the face is symmetric, the malocclusion must be modified so that the basal bone can be symmetrically manipulated.

REFERENCES

- 1- Alavi DG, BeGole EA, Schneider BJ. Facial and dental arch asymmetries in Class II subdivision malocclusion. *Am J Orthod Dentofacial Orthop*. 1988;93(1):38-46.
- 2- Arnett GW, Kreashko RG, Jelic JS. Correcting vertically altered faces: orthodontics and orthognathic surgery. *Int J Adult Orthodon Orthognath Surg*. 1998;13(4):267-76.
- 3- Ataoglu H, Uckan S, Karaman AI, Uyar Y. Bimaxillary orthognathic surgery in a patient with long face: a case report. *Int J Adult Orthodon Orthognath Surg*. 1999;14(4):304-9.
- 4- Burstone CJ. JCO Interviews: on the uses of the computer in orthodontic practice (Part 1). *J Clin Orthodont*. 1979;13(7):442-53.
- 5- Burstone CJ. Diagnosis and treatment planning of patients with asymmetries. *Semin Orthod*. 1988;4(3):153-64.
- 6- Cheney EA. Dentofacial asymmetry and their clinical significance. *Am J Orthod*. 1961;47(11):814-29.
- 7- Epker BN, Fish LC. Dentofacial deformities: integrated orthodontics and surgical correction. St. Louis: Mosby; 1986. p 400-6.
- 8- Goncalves JR, Buschang PH, Goncalves DG, Wolford LM. Postsurgical stability of oropharyngeal airway changes following counter-clockwise maxillo-mandibular advancement surgery. *J Oral Maxillofac Surg*. 2006;64(5):755-62.
- 9- Holdaway RA. A soft-tissue cephalometric analysis and its use in orthodontic treatment planning. Part I. *Am J Orthod*. 1983;84(1):1-28.
- 10- Jacobson A. The Witts appraisal of jaw disharmony. *Am J Orthod*. 1975;67(2):125-38.
- 11- Janson G, Cruz KS, Woodside DG, Metaxas A, Freitas MR, Henriques JF. Dentoskeletal treatment changes in class II subdivision malocclusions in submentovertex and posteroanterior radiographs. *Am J Orthod Dentofacial Orthop*. 2004;126(4):451-63.
- 12- Janson G, Dainesi EA, Henriques JF, Freitas MR, Lima KJ. Class II subdivision treatment success rate with symmetric and asymmetric extraction protocols. *Am J Orthod Dentofacial Orthop*. 2003;124(3):257-64; quiz 339.
- 13- Janson G, Lima KJ, Woodside DG, Metaxas A, Freitas MR, Henriques JF. Class II subdivision malocclusion types and evaluation of their asymmetries. *Am J Orthod Dentofacial Orthop*. 2007;131(1):57-66.
- 14- Janson G, Woodside DG, Metaxas A, Henriques JFC, Freitas MR. Orthodontic treatment of subdivision cases. *World J Orthod*. 2003;4(1):36-46.
- 15- Janson GR, Metaxas A, Woodside DG, Freitas M R, Pinzan A. Three-dimensional evaluation of skeletal and dental asymmetries in Class II subdivision malocclusions. *Am J Orthod Dentofacial Orthop*. 2001;119(4):406-18.
- 16- Janson M. Surgical-orthodontic treatment. In: Janson M. *Adult orthodontics and interdisciplinary treatment*. Maringá: Ed. Dental Press; 2008. p.581.
- 17- Legan HL, Burstone CJ. Soft tissue cephalometric analysis for orthognathic surgery. *J Oral Surg*. 1980;38(10):744-51.
- 18- Lewis PD. The deviated midline. *Am J Orthod*. 1976;70(6): 601-16.
- 19- McNamara JA Jr. A method of cephalometric evaluation. *Am J Orthod*. 1984;86(6):449-69.
- 20- Mommaerts MY, Marinho RO, Abeloos JV, De Clercq CA, Neyt LF. The nasal frame osteotomy: technical note. *Int J Adult Orthodon Orthognath Surg*. 1999;14(4):310-4.
- 21- Mommaerts MY, Marxer H. A cephalometric analysis of the long-term, soft tissue profile changes which accompany the advancement of the mandible by sagittal split ramus osteotomies. *J Craniomaxillofac Surg*. 1987;15(3):127-31.
- 22- Proffit WC. *Contemporary orthodontics*. St. Louis: Mosby; 1986.
- 23- Riedel RA. The relation of maxillary structures to cranium in malocclusion and in normal occlusion. *Angle Orthod*. 1952;22(3):142-45.
- 24- Rose JM, Sadowsky C, BeGole EA, Moles R. Mandibular skeletal and dental asymmetry in Class II subdivision malocclusions. *Am J Orthod Dentofacial Orthop*. 1994;105(5):489-95.
- 25- Shroff B, Siegel SM. Treatment of patients with asymmetries using asymmetric mechanics. *Semin Orthod*. 1998;4(3):165-79.
- 26- Silvestri A, Cascone P, Natali G, Iaquaniello M. Long-term control of the stability of skeletal structures in Class II dentoskeletal deformities after surgical-orthodontic therapy. *Am J Orthod Dentofacial Orthop*. 1994;105(4):375-82.
- 27- Steiner CC. Cephalometrics for you and me. *Am J Orthod*. 1953;39(10):729-55.
- 28- Todd M, Hosier M, Sheehan T, Kinser D. Asymmetric extraction treatment of a Class II Division 1 subdivision left malocclusion with anterior and posterior crossbites. *Am J Orthod Dentofacial Orthop*. 1999;115(4):410-7.
- 29- Turpin DL. Correcting the Class II subdivision malocclusion. *Am J Orthod Dentofacial Orthop*. 2005;128(5):555-6.
- 30- Turvey TA, Phillips C, Zaytoun HS Jr, Proffit WR. Simultaneous superior repositioning of the maxilla and mandibular advancement. A report on stability. *Am J Orthod Dentofacial Orthop*. 1988;94(5):372-83.
- 31- Tweed CH. The Frankfort-Mandibular Incisor Angle (FMIA) in orthodontic diagnosis, treatment planning and prognosis. *Angle Orthod*. 1954;24(3):121-69.
- 32- Wertz RA. Diagnosis and treatment planning of unilateral Class II malocclusions. *Angle Orthod*. 1975;45(2):85-94.
- 33- Wolford LM, Chemello PD, Hilliard F. Occlusal plane alteration in orthognathic surgery—Part I: effects on function and esthetics. *Am J Orthod Dentofacial Orthop*. 1994;106(3):304-16.