

## Granulomatous interstitial nephritis secondary to sarcoidosis

## Nefrite intersticial granulomatose secundária a sarcoidose

## Authors

Tamires Teixeira Piraciaba<sup>1</sup>Carlos Alberto Balda<sup>1</sup>Luiz Antônio Ribeiro de Moura<sup>1</sup>Carlos Alberto de Castro Pereira<sup>2</sup>Gianna Mastroianni Kirsztajn<sup>1</sup>

<sup>1</sup> Universidade Federal de São Paulo, Disciplina de Nefrologia, São Paulo - SP, Brasil.

<sup>2</sup> Universidade Federal de São Paulo, Disciplina de Pneumologia, São Paulo - SP, Brasil.

Submitted on: 02/14/2017.

Approved on: 03/09/2017.

## Correspondence to:

Tamires Teixeira Piraciaba.  
E-mail: tamires.nefro@gmail.com

DOI: 10.5935/0101-2800.20170084

## ABSTRACT

**Introduction:** Granulomatous interstitial nephritis is a rare condition, in which renal involvement is uncommon. Its etiology is variable, and may be medicinal, infectious or inflammatory origin. **Case report:** This is a 65-year-old male patient with renal lesions of unknown etiology, associated with hypercalcaemia. During the investigation, cardiac insufficiency with diastolic dysfunction and interstitial lung involvement on chest tomography were evidenced. Renal function (glomerular filtration rate) has partially improved with clinical measures. Renal biopsy was performed, which showed moderate interstitial lesion with tuberculoid granulomas without caseous necrosis. **Conclusion:** The objective of the article was to describe a case of NIG and to alert to the importance of its clinical investigation. In this case, renal biopsy, associated with systemic clinical manifestations, contributed to the diagnosis of sarcoidosis.

**Keywords:** hypercalcemia; interstitial; nephritis; sarcoidosis.

## RESUMO

**Introdução:** a nefrite intersticial granulomatosa é uma condição rara, na qual o envolvimento renal é incomum. Sua etiologia é variável e pode ter origem medicinal, infecciosa ou inflamatória. **Relato de caso:** trata-se de um paciente do sexo masculino, com 65 anos de idade, com lesões renais de etiologia desconhecida, associadas à hipercalcemia. Durante a investigação, evidenciaram-se insuficiência cardíaca com disfunção diastólica e envolvimento pulmonar intersticial à tomografia torácica. A função renal (taxa de filtração glomerular) melhorou parcialmente com medidas clínicas. Foi realizada biópsia renal, que apresentou lesão intersticial moderada com granulomas tuberculoides sem necrose caseosa. **Conclusão:** o objetivo do artigo foi descrever um caso de GIN e alertar para a importância de sua investigação clínica. Neste caso, a biópsia renal, associada a manifestações clínicas sistêmicas, contribuiu para o diagnóstico de sarcoidose.

**Palavras-chave:** hipercalcemia; nefrite intersticial; sarcoidose.

## INTRODUCTION

Granulomatous interstitial nephritis (GIN) is a rare condition. Medications, infectious agents, vasculitis and sarcoidosis are some of its possible etiologies.<sup>1</sup>

Sarcoidosis is a disease of unknown origin, characterized by the formation of granulomas in the tissues, especially at the lower respiratory tract. Renal damage is uncommon, and it is described in 0.7 to 4.3% of the cases. Major forms of renal impairment are related to alterations in calcium metabolism, manifesting as nephrocalcinosis and nephrolithiasis.<sup>1</sup>

This paper aims to report a case of GIN in a patient with renal dysfunction of unknown cause, in which the renal biopsy, associated with the clinical manifestations, contributes to the diagnosis of sarcoidosis.

## CASE REPORT

A 65 year-old male patient of oriental descent, who was divorced and who was a retired metallurgical worker, was admitted reporting nausea and malaise for a week. He had bilateral parotiditis for 15 days, taking nimesulide for three days, without

improvement. He developed fever and weight loss. He reported hyperuricemia, gastritis and dyslipidemia. He was using allopurinol, ranitidine and sinvastatin to treat each of the conditions, respectively. Upon physical examination, on admission, he had bilateral enlarged parotids, which were painless to palpation.

Initial laboratory tests: hemoglobin 9.8g/dl, hematocrit 28.7%, 8,140 leukocytes/mm<sup>3</sup> (7.6% eosinophils) and 400.000 platelets; serum creatinine 8.65 mg/dl and urea 118 mg/dl; electrolytes were within the limits of normality, except for total calcium of 12.5 mg/dl. Urinalysis: 11.000 leukocytes/ml, 1000 erythrocytes/ml and proteinuria of 0.5 g/l.

In view of hypercalcemia and renal dysfunction, vigorous venous hydration was prescribed, with a good response (Table 1), that is, there was a progressive decrease in serum urea and creatinine, in addition to serum calcium normalization without the need for other measures for hypercalcemia. Other complementary tests: phosphate 5.3 mg/dl, PTH 7.7 pg/ml, 25-OH-vitamin D 4ng/ml, serum albumin 3.9 g/dl.

Kidney and urinary tract ultrasonography showed right kidney with 10.6 cm and left with 10.8 cm, renal parenchyma with preserved thickness and echogenicity. There was a 0.5 cm stone in the right calicinal group, without signs of dilatation of the pelvic system.

Cervical ultrasonography showed enlarged parotid glands, with heterogeneous ecotexture, multiple cystic lesions at the border, associated with some prominent intraparotid lymph nodes. The submandibular glands were preserved and there was no lymph node enlargement.

The parotid glands returned to their usual size progressively during hospitalization.

A chest X-ray revealed discrete bilateral interstitial infiltrate. Following this, a chest computed tomography showed an increase of mediastinal lymph nodes, infiltrated diffuse ground-glass, predominant in the bases, and small granulomas (Figure 1).

Transthoracic echocardiography showed a 47% ejection fraction, moderate left ventricular diastolic dysfunction and a PSAP of 38 mmHg, in addition to minimal pericardial effusion.

Stabilization of renal function, with a decrease in serum creatinine at levels around 3.5 mg/dL, was observed throughout the evolution. In order to elucidate an etiology of the renal lesion, it was performed a renal biopsy (Figures 1 to 4).

In light microscopy showed 22 glomeruli, 3 globally sclerosed, the others with conserved cellularity and peripheral capillaries with regular contours were identified. The tubules presented regenerative epithelia, signs of atrophy, surrounded by enlarged interstitium due to edema and inflammatory infiltrate of lymphoid cells. There were clusters of histiocytes, with epithelioid characteristics and multinucleated giant cells, in addition to moderate fibrosis. Immunofluorescence microscopy was negative for immunoglobulins, complement and fibrinogen. Additional tests in the biopsy material were negative for fungus and BAAR.

Due to the presence of granulomatous non-caseous lesions, and radiological features suggestive of systemic clinical manifestations, after excluding a role for drugs and infections, prednisone was initiated (40 mg/day orally).

Serum angiotensin I converting enzyme was determined, and its level was elevated: 87.72 mmol/ml/min (reference value: 25-30).

The patient underwent ambulatory follow-up at the Nephrology and Pneumology Services of UNIFESP, and after five weeks of treatment, he presented serum creatinine levels of 2.5 mg/d and ionic calcium of 1.38mg/dl.

## DISCUSSION

GIN is a rare cause of acute kidney injury. It is diagnosed in 0.5 to 0.9% of the native kidney biopsies and has several possible causes, among which the most notable are drugs, infections and autoimmune<sup>2</sup> diseases (Table 2). Joss *et al.*<sup>2</sup> analyzed a series of 18 cases over 15 years and found that nine cases were idiopathic, five related to sarcoidosis and two to the use of medication. Patients had varying degrees of renal failure and proteinuria.

Among the drugs that can cause GIN, antibiotics represent one of the main classes. Shah *et al.*<sup>3</sup> reported a case of NIG related to doxycycline exposure in a 69-year-old patient who, in addition to renal failure, had skin rash and mental impairment.

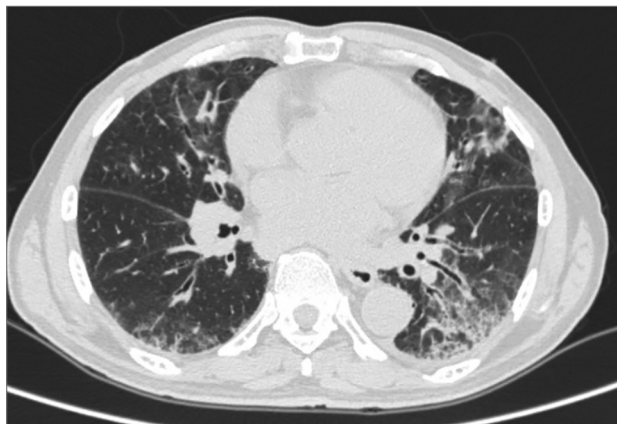
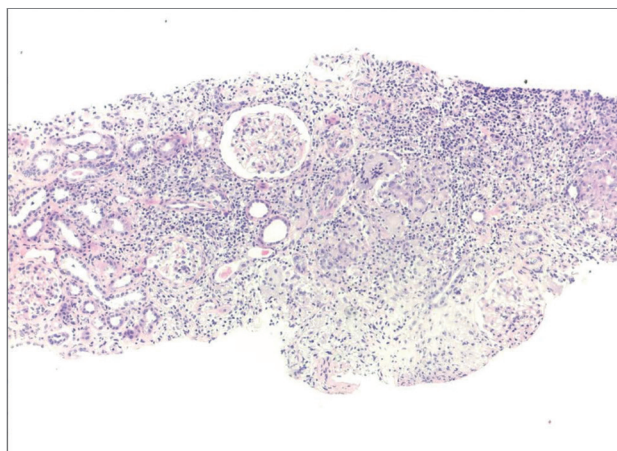
Other drugs related to NIG are analgesics, diuretics and allopurinol.<sup>3</sup>

The main infectious etiology is tuberculosis. Kidney involvement is insidious and is often diagnosed post-mortem.<sup>3</sup> Other important agents are fungi and atypical bacteria.<sup>3</sup>

In children the diagnosis of pediatric granulomatous arthritis (PGA), which may be a familial

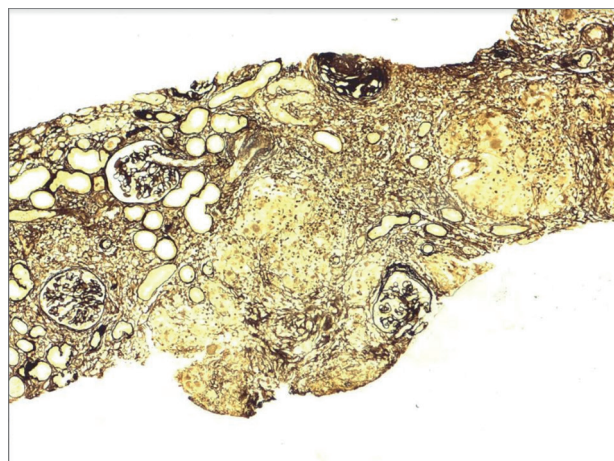
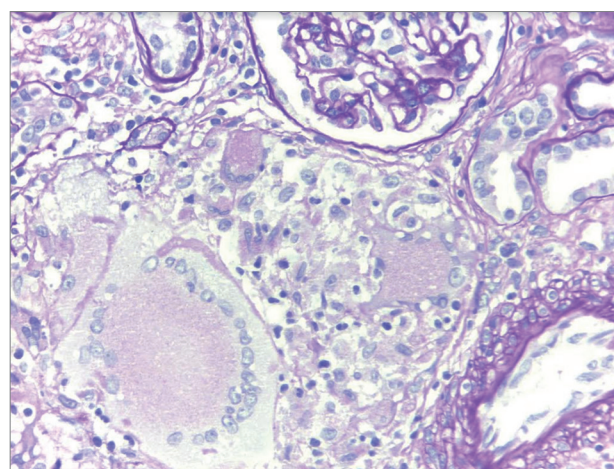
**TABLE 1** LABORATORIAL EVALUATION

	D1	D2	D3	D4	D5	D6	D7	D8	D9
Creatinine(mg/dl)	8.65	7.94	7.54	7.56	7.2	6.41	5.3	4.92	4.58
Urea (mg/dl)	118	114	111	103	100	92	81	72	71
Total/ionized Calcium (mg/dl)	12.5	12			9.7/1.28	8.6	9.3	8.9	

**Figure 1.** Chest CT scan: diffuse frosted glass infiltrate, mainly in pulmonary bases, and increased septal thickness.**Figure 2.** Kidney biopsy fragment (stained by HE), showing interstitial enlargement by inflammatory infiltrate (H & E - 40x).

condition (Blau's syndrome) or sporadic (sarcoidosis of early onset), should be considered. Unlike sarcoidosis, PGA has autosomal dominant inheritance and is caused by mutations in the NOD2 gene, also known as CARD15, located on chromosome 16.<sup>10</sup> In this entity there is non-caseous granulomatous infiltration in the affected tissues, skin rash, arthritis and uveitis.<sup>11</sup>

The diagnosis of GIN in sarcoidosis is rare. Granulomatous inflammation in the parenchyma is most commonly found in post-mortem series in up to 40% of cases. This is because this type of involvement usually does not lead to renal dysfunction. Most patients with this type of lesion also have extrarenal

**Figure 3.** Renal biopsy (silver impregnation) showing interstitial enlargement with nodular areas. Negative staining, corresponding to granulomas (Jones Silver - 40x).**Figure 4.** Histological section of kidney with interstitial agglomerate of epithelioid histiocytes and multinucleated giant cell (PAS - 100x).

manifestations (such as ocular, pulmonary and cutaneous), but it may also occur in isolation.<sup>2</sup>

Renal involvement in sarcoidosis is most commonly due to disorders in calcium metabolism, resulting from the deregulated production of 1,25-dihydroxyvitamin D3 by activated macrophages in the granuloma. Hypercalcemia is detected in 10% of patients, while hypercalciuria is more common, seen in up to 60%.<sup>1</sup>

In sarcoidosis there is production of angiotensin-converting enzyme by granulomas and its dosage may



**TABLE 2** CAUSES OF GRANULOMATOUS INTERSTITIAL NEPHRITIS

Drugs	Allopurinol, omeprazole, furosemide, captopril, analgésicos (paracetamol, NSAIS), antibióticos (penicillin, quinolone, acyclovir, vancomycin, rifamycin)
Infectious	Tuberculosis, leprosy, toxoplasmosis, candidiasis, cryptococcosis
Inflammatory	Granulomatosis and polyangiitis, eosinophilic granulomatosis and polyangiitis, sarcoidosis
Miscellaneous	Uric acid crystals, heroin, tubulointerstitial nephritis and uveitis (TINU)

be elevated in 60% of cases.<sup>7</sup> Their levels may still be influenced by genetic polymorphisms.<sup>7</sup> In the study by Mahévas *et al.*,<sup>8</sup> 55% of the patients studied presented such disorder.

The enzyme was increased in the presented case, however, it is emphasized that its dosage is not specific, and can be found in diseases such as tuberculosis, leprosy, lymphoma, diabetes, hyperthyroidism, among others.<sup>9</sup> Its follow-up throughout the evolution of sarcoidosis does not have a well established role.<sup>4</sup>

Glomerular disorders can also be found, such as minimal change disease, membranous glomerulopathy, and focal and segmental glomerulosclerosis.<sup>3</sup> In the reported case, renal histopathological evaluation revealed normal glomeruli, and important tubulo-interstitial involvement.

Corticosteroid therapy is the mainstay of the treatment, with 20 to 40 mg/day of prednisone being used for 6 to 12 weeks, with subsequent dose reduction.<sup>4</sup> In cases with neurological, renal, cardiac or ophthalmologic impairment, it is recommended to administer 1mg/kg/day of prednisone orally. In cases of failure to respond to corticosteroids or if there are contraindications, immunosuppressive agents may be used in treatment such as azathioprine and mycophenolate mofetil.<sup>4</sup> In recent years, the TNF-alpha infliximab antagonist has been used with good response in refractory cases.<sup>4</sup>

In this case, the clinical, laboratorial, radiological and pathological data together contributed to establish the diagnosis of sarcoidosis, an entity that can be treated with corticosteroid with a chance of

adequate response. The reported patient partially recovered renal function and presented systemic clinical improvement.

## REFERENCES

1. Sharmeen S, Kalkan E, Yi C, Smith SD. Granulomatous Interstitial Nephritis Presenting as Hypercalcemia and Nephrolithiasis. *Case Rep Nephrol* 2016;2016:4186086. DOI: <http://dx.doi.org/10.1155/2016/4186086>
2. Joss N, Morris S, Young B, Geddes C. Granulomatous interstitial nephritis. *Clin J Am Soc Nephrol* 2007;2:222-30. DOI: <http://dx.doi.org/10.2215/CJN.01790506>
3. Shah S, Carter-Monroe N, Atta MG. Granulomatous interstitial nephritis. *Clin Kidney J* 2015;8:516-23. DOI: <http://dx.doi.org/10.1093/ckj/sfv053>
4. Valeyre D, Prasse A, Nunes H, Uzunhan Y, Brillet PY, Müller-Quernheim J. Sarcoidosis. *Lancet* 2014;383:1155-67. PMID: 24090799 DOI: [http://dx.doi.org/10.1016/S0140-6736\(13\)60680-7](http://dx.doi.org/10.1016/S0140-6736(13)60680-7)
5. Ikeda A, Nagai S, Kitaichi M, Hayashi M, Hamada K, Shigematsu M, et al. Sarcoidosis with granulomatous interstitial nephritis: report of three cases. *Intern Med* 2001;40:241-5.
6. Robson MG, Banerjee D, Hopster D, Cairns HS. Seven cases of granulomatous interstitial nephritis in the absence of extrarenal sarcoid. *Nephrol Dial Transplant* 2003;18:280-4. DOI: <http://dx.doi.org/10.1093/ndt/18.2.280>
7. Iannuzzi MC, Rybicki BA, Teirstein AS. Sarcoidosis. *N Engl J Med* 2007;357:2153-65. PMID: 18032765 DOI: <http://dx.doi.org/10.1056/NEJMra071714>
8. Mahévas M, Lescure FX, Boffa JJ, Delastour V, Belenfant X, Chapelon C, et al. Renal sarcoidosis: clinical, laboratory, and histologic presentation and outcome in 47 patients. *Medicine (Baltimore)* 2009;88:98-106. DOI: <http://dx.doi.org/10.1097/MD.0b013e31819de50f>
9. Studdy PR, Bird R. Serum angiotensin converting enzyme in sarcoidosis-its value in present clinical practice. *Ann Clin Biochem* 1989;26:13-8. PMID: 2544134 DOI: <http://dx.doi.org/10.1177/000456328902600102>
10. Jesus A, Oliveira JB, Hilário MOE, Terreri MTRA, Fujihira E, Watase M, et al. Síndromes autoinflamatórias hereditárias na faixa etária pediátrica. *J Pediatr* 2010;86:353-66
11. Wouters CH, Maes A, Foley KP, Bertin J, Rose CD. Blau syndrome, the prototypic auto-inflammatory granulomatous disease. *Pediatr Rheumatol Online J* 2014;12:33. DOI: <http://dx.doi.org/10.1186/1546-0096-12-33>