

## Hemolytic uremic syndrome due to gemcitabine in a young woman with cholangiocarcinoma

Síndrome hemolítico-urêmica causada por gencitabina em uma paciente jovem com colangiocarcinoma

### Authors

John Fredy Nieto-Ríos<sup>1,2</sup>  
 Mónica Zuluaga-Quintero<sup>3</sup>  
 Lina María Serna Higuaita<sup>2</sup>  
 Cristian Ivan García Rincón<sup>1</sup>  
 Kenny Mauricio Galvez-Cárdenas<sup>1</sup>  
 Catalina Ocampo-Kohn<sup>1,2</sup>  
 Arbey Aristizabal-Alzate<sup>1,2</sup>  
 Adriana Alejandra Florez-Vargas<sup>4</sup>  
 Gustavo Adolfo Zuluaga-Valencia<sup>1,2</sup>

<sup>1</sup> Hospital Pablo Tobon Uribe.

<sup>2</sup> Universidad de Antioquia.

<sup>3</sup> Universidad Pontificia Bolivariana.

<sup>4</sup> Fundación Santa Fé de Bogotá.

Submitted on: 06/08/2015.

Approved on: 12/11/2015.

### Correspondence to:

Lina María Serna Higuaita.  
 Hospital Pablo Tobon Uribe and Antioquia University.  
 Calle 78B # 69 - 240, Medellín, Colombia.  
 CEP: 57-4-4459902  
 E-mail: lm.serna@hotmail.com

DOI: 10.5935/0101-2800.20160035

### ABSTRACT

Gemcitabine is a medication used to treat various types of malignant neoplasms. Its association with hemolytic uremic syndrome (HUS) has been described in few cases, although these cases have resulted in mortality rates of at least 50%. We report on the case of a 25-year-old patient with cholangiocarcinoma in remission who developed microangiopathic hemolytic anemia with acute anuric renal failure after receiving 5 cycles of gemcitabine chemotherapy; this condition was consistent with HUS caused by the side effects of this drug. The administration of gemcitabine was stopped, and hemodialysis, blood transfusions, plasma exchanges, steroids, doxycycline, and rituximab were used to treat the patient. A favorable outcome was achieved; in particular, hemolysis was controlled, and renal function was completely recovered.

**Keywords:** acute kidney injury; cholangiocarcinoma; hemolytic-uremic syndrome; thrombotic microangiopathies.

### RESUMO

A gencitabina é um fármaco utilizado no tratamento de vários tipos de neoplasias malignas. Há poucas descrições de associação entre a droga e a síndrome hemolítico-urêmica (SHU), apesar de os pacientes em questão terem ido a óbito em pelo menos 50% dos casos. O presente artigo relata o caso de uma paciente com 25 anos de idade em remissão diagnosticada com colangiocarcinoma que apresentou anemia hemolítica microangiopática acompanhada de insuficiência renal aguda anúrica após cinco ciclos de quimioterapia com gencitabina; as manifestações eram condizentes com SHU causada pelos efeitos colaterais do medicamento. A administração de gencitabina foi interrompida, e a paciente foi tratada com hemodiálise, transfusões de sangue, trocas de plasma, corticosteroides, doxiciclina e rituximabe. Foi atingido um desfecho favorável; mais especificamente, a hemólise foi controlada e a função renal foi plenamente restabelecida.

**Palavras-chave:** colangiocarcinoma; lesão renal aguda; microangiopatias trombóticas; síndrome hemolítico-urêmica.

### INTRODUCTION

Thrombotic microangiopathies (TMAs) are a series of disorders characterized by the presence of non-immune hemolytic anemia, thrombocytopenia, and multiple organ failure, with frequent renal and/or neurological damage.<sup>1</sup> Differential diagnoses of TMAs are extremely wide-ranging. TMAs may be associated with ADAMTS-13 deficiency, which would result in a diagnosis of thrombotic thrombocytopenic purpura (TTP);<sup>2</sup> intestinal infection by enterobacteria that produce Shiga-toxin, which would

lead to a diagnosis of typical hemolytic uremic syndrome (tHUS);<sup>3</sup> or complement disorders that cause atypical hemolytic uremic syndrome (aHUS).<sup>4</sup> In addition, TMAs may be initiated or triggered by multiple secondary causes, including autoimmune diseases, metabolic diseases, neoplastic diseases, infectious diseases, cardiovascular diseases, and drug-related effects.<sup>1</sup>

The drugs most frequently associated with TMAs include chemotherapeutic agents such as mitomycin C, cisplatin, 5-fluorouracil, carboplatin, and gemcitabine.<sup>1,5</sup> The early recognition of

drug-associated TMAs is important because it allows for the immediate suspension of treatment with the causal agent and the establishment of timely support measures to curb damage-causing pathophysiological processes; this issue is particularly critical given the extremely poor short- and long-term prognoses of these disorders.<sup>5,6</sup>

The following section describes the case of a young woman diagnosed with cholangiocarcinoma in remission who developed hemolytic uremic syndrome (HUS) during the fifth cycle of gemcitabine chemotherapy.

## CLINICAL CASE

The examined case involved a 25-year-old woman with a history of intrahepatic cholangiocarcinoma, which was diagnosed 18 months prior to this report. Her treatment included a hepatectomy and 5 cycles of chemotherapy with gemcitabine. She was admitted due to the recent onset of the following symptoms: malaise, a throbbing headache, progressive lower limb edema, oliguria and dyspnea. During physical examination, the patient was pale; petechiae and anasarca were observed. Laboratory tests revealed pancytopenia, elevated lactate dehydrogenase (LDH) levels, schistocytosis and acute renal failure (Table 1).

An immunological profile was negative except for hypocomplementemia. Shiga toxin tests were not requested because the patient did not present with diarrhea. Images of the patient's abdomen and skull revealed no abnormalities. Given these findings, HUS resulting from gemcitabine-induced TMA was diagnosed.

The patient was treated with daily plasma exchanges and renal replacement therapy. A total of 14 plasma exchanges were performed, with partial response. The patient concomitantly received 1 mg/kg of prednisone per day, 100 mg of doxycycline every 12 hours and 2 doses of rituximab (1 g every two weeks).

After the second rituximab dose a hemolysis was controlled, although oliguric acute renal failure persisted. Therefore, a renal biopsy was obtained; this biopsy confirmed the presence of active TMA (Figure 1). Eight weeks after the onset of the patient's clinical condition, her renal function completely recovered; no relapse was observed at 12-month follow-up (Figure 2).

## DISCUSSION

We report on the case of a patient with cholangiocarcinoma in remission who received treatment with gemcitabine, developed severe TMA associated with this medication, and exhibited a successful response to treatment.

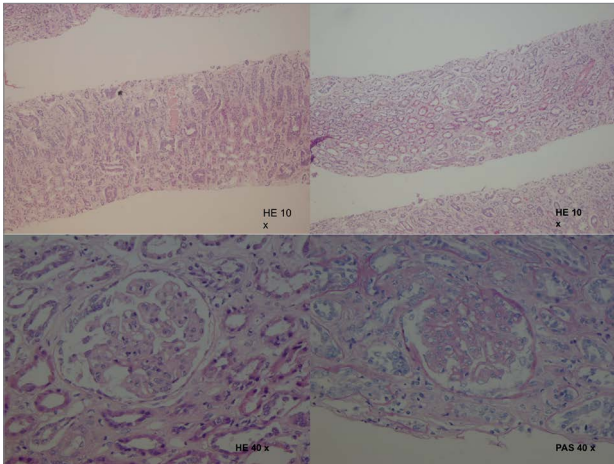
Gemcitabine is used to treat certain malignant conditions, including pancreatic cancer, cholangiocarcinoma, hepatocarcinoma, lymphoma, bladder cancer, and breast cancer.<sup>5</sup> In 1994, Casper *et al.* first described an association between gemcitabine and HUS in a study of a group of pancreatic adenocarcinoma patients who received chemotherapy.<sup>6</sup> Subsequently, gemcitabine-associated HUS has been described in the treatment of many malignant neoplastic conditions; in particular, this condition exhibits incidences ranging from 0.015% to 2.2%,<sup>7,8</sup> although these values are underestimates due to the underreporting of HUS cases.<sup>5</sup>

**TABLE 1** LABORATORY RESULTS

Urinalysis	pH	Density	Proteinuria	Bilirubin	Erythrocytes	Leukocytes
	6	1020	> 300mg/dl	Positive	11-20CAP	0-5CAP
Arterial gases	pH	PaO <sub>2</sub>	HCO <sub>3</sub>	PCO <sub>2</sub>	Saturated	Base Deficit
	7.38	76 mmHg	18.3 mmol/L	27 mmHg	96%	-5.8 mmol/L
Serum tests	Hemoglobin	Leukocytes	Platelets	PBS	Ferritin	LDH
	4.9 g/dl	4700 mm <sup>3</sup>	67000 mm <sup>3</sup>	Schistocytes++	1556 ng/ml	649 u/L
	Fibrinogen	Haptoglobin	Total CPK	Creatinine	BUN	Total Bilirubin
	337 mg/dl	< 10 mg/dl	20 U/L	1.82 mg/dl	36 mg/dl	0.9 mg/dl
	TP/INR	TPT	Hepatitis C	Hepatitis B	HIV infection	Blood cultures
	10.8 seg/0.9	25.6 seg	Negative	Negative	Negative	Negatives
Immunological tests	Complement C3	Complement C4	ANAS	ENAS	Anticardiolipin	ANCAS
	59 mg/dl	9 mg/dl	Negative	Negative	Negative	Negative

PBS: peripheral blood smear; BUN: blood urea nitrogen; LDH: lactate dehydrogenase; ANAS: antinuclear antibodies; ENAS: anti-RNP, anti-Sm, anti-Ro, and anti-La; ANCAS: circulating antineutrophil cytoplasm autoantibodies

**Figure 1.** Renal biopsy and histological findings - Collapsed glomeruli, capillary loop shrinkage, luminal obliteration, microthrombosis, glomerular congestion, and fragmented red blood cell were identified; these findings are consistent with thrombotic microangiopathy. Cellular debris and cylinders in the tubules were also observed, indicating the presence of associated acute tubular damage.



The exact mechanisms by which gemcitabine causes HUS is unclear; among the various hypotheses, the most prominent theory is that direct damage to endothelial cells leads to cellular edema, the separation of the endothelium from its basement membrane, and the formation of microthrombi as a side effect of the activation of inflammatory, coagulation, growth, platelet activation, prothrombotic, and chemotactic factors.<sup>9</sup>

Another theory, which is focused on the immune system, suggests that circulating complexes form that trigger platelet aggregation and deposition in areas

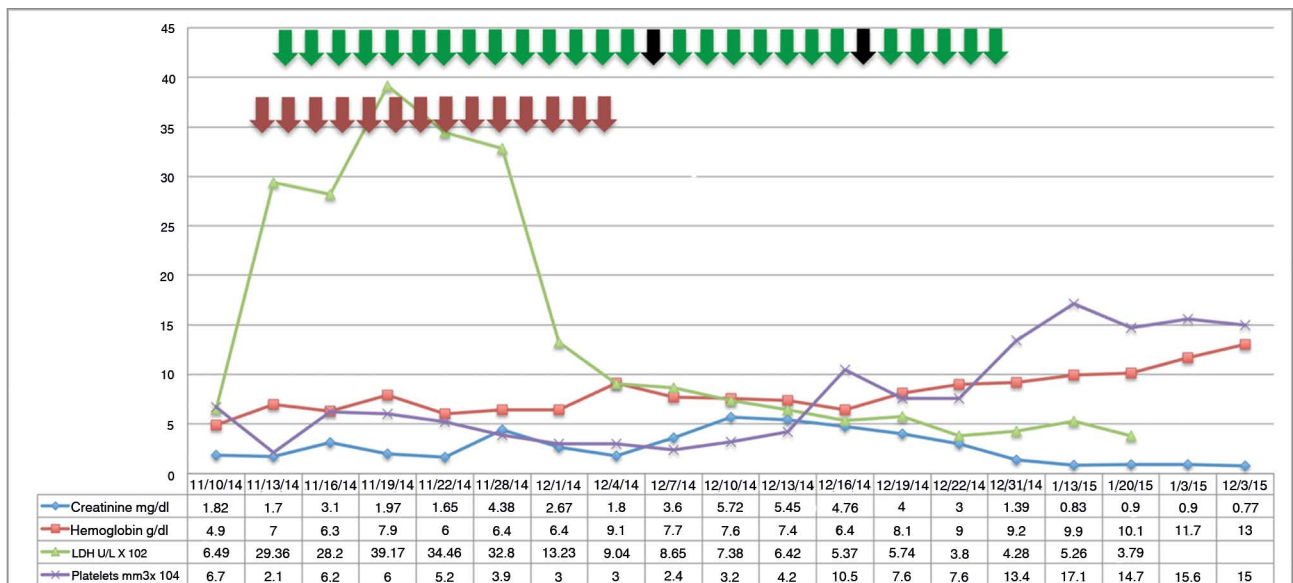
of endothelial damage in the renal microcirculation or that antibodies against self-antigens form after gemcitabine-induced endothelial damage.<sup>10</sup> Certain authors have proposed that antibodies against the ADAMTS-13 enzyme are produced; as a result, large von Willebrand multimers cannot be cleaved, leading to platelet activation and capillary thrombosis.<sup>1,9</sup>

None of these theories have been confirmed. However, it has been demonstrated that stopping the administration of gemcitabine can lead to the resolution of HUS, whereas the reintroduction of gemcitabine treatment can result in recurrence; these findings support a causal association between gemcitabine and HUS.<sup>5</sup>

In general, the cumulative gemcitabine doses reported in the literature are 20,000 mg/m<sup>2</sup> or 6 cycles, although descriptions have indicated that HUS cases can occur after a single dose. Patients are at greater risk for HUS when combined chemotherapeutic schemes are administered. In most cases, it is difficult to determine whether the presence of HUS is due to an underlying malignant condition or a patient's therapeutic regimen; however, poor disease control, evidence of unresolved or metastatic lesions, and clinical deterioration after chemotherapy is stopped provide evidence to support the possibility that an underlying neoplasia is triggering HUS.<sup>5,11</sup>

Multiple treatment strategies for gemcitabine-associated HUS have been proposed. However, the only approach clearly supported by evidence is the

**Figure 2.** The evolution of lab tests during treatment - The evolution of laboratory parameters during the course of receiving the following treatments: 14 plasma exchange sessions (red arrows); hemodialysis from November 16, 2014 until December 31, 2014 (green arrows); and two doses of rituximab (black arrows).



complete suspension of the drug; after gemcitabine treatment has been suspended, clinical recovery occurred in 50 to 100% of the cases in the main cohorts that have been described.<sup>5-8</sup> Nonetheless, there are cases in which patients exhibit no response; in these cases, overall mortality can reach 50%.<sup>5</sup> Steroids have been proposed for the treatment of these refractory cases, although steroid administration has produced controversial results. The major steroid treatment-related results described in the literature have involved the use of 1 mg/kg per day of prednisone for varying periods.<sup>5,6,11</sup> A report has also described satisfactory responses to 200 mg/day of doxycycline, which may reflect its possible immunomodulatory role in gemcitabine-associated HUS.<sup>5</sup>

Despite advancements in the understanding of TMAs, plasma exchanges remain the standard treatment for these conditions; in particular, plasma exchanges are immediately initiated upon a clinical suspicion of TMA, with variable success rates.<sup>12</sup> However, in cases of chemotherapy-associated HUS, the role of plasma exchanges is controversial, although this treatment remains the approach recommended by American Society for Apheresis guidelines.<sup>13</sup>

Certain reports have described adequate responses to this intervention; in particular, in a literature review of a total of 706 patients, Izzedine *et al.* observed that 85% of patients responded to plasma exchanges in combination with steroid treatment.<sup>5</sup> However, other results, such as the findings described by Gore *et al.*<sup>14</sup> in a literature review of 44 cases from 2009, do not support the benefits of plasma exchanges. One confounding factor that prevents definitive conclusions from being obtained is that patients treated with plasma exchanges were more ill than patients who did not receive plasma exchanges. The number of plasma exchanges required to treat chemotherapy-associated HUS also has not been clearly defined; reports have described that up to 30 exchanges may be performed before positive responses are observed.<sup>5</sup>

Several literature reports have suggested that the administration of rituximab (monoclonal anti CD20-antibody) is an alternative treatment in certain refractory cases of gemcitabine-associated TMA; it can produce favorable responses because this illness is associated with immune complexes as is suggested in our case by the decrease of serum complement levels.<sup>14,15</sup>

Many uncertainties remain in cases of gemcitabine-associated TMA, and the incidence of

gemcitabine-induced HUS likely continues to increase given the widespread use of this drug either alone or in combination with other chemotherapeutic agents. Therefore, medical professionals should be highly alert for gemcitabine-induced HUS because the early recognition and timely treatment of this syndrome could decrease morbidity and mortality.

Literature sources recommend that for all patients receiving gemcitabine chemotherapy, basal hemolysis markers should be assessed before each cycle, and medical practitioners should be attentive to indications such as uncontrolled hypertension, pulmonary or peripheral edema, neurological deficits, and impaired renal function.<sup>5,6,9,11</sup>

In the case described in this report, we decided to use therapeutic approaches for gemcitabine-induced HUS that had been demonstrated to be beneficial in the literature. Therefore, in addition to stopping gemcitabine administration, the patient received dialysis and transfusion support, plasma therapy, steroid treatment, rituximab and doxycycline (as it was reported by Izzedine to have immunomodulatory properties).<sup>5</sup> Clinical improvement was observed, but no conclusions can be drawn regarding which of these therapies was most effective in the described case.

## REFERENCES

1. Tsai HM. Thrombotic thrombocytopenic purpura and the atypical hemolytic uremic syndrome: an update. *Hematol Oncol Clin North Am* 2013;27:565-84. DOI: <http://dx.doi.org/10.1016/j.hoc.2013.02.006>
2. Kessler CS, Khan BA, Lai-Miller K. Thrombotic thrombocytopenic purpura: a hematological emergency. *J Emerg Med* 2012;43:538-44. DOI: <http://dx.doi.org/10.1016/j.jemermed.2012.01.027>
3. Petruzzello-Pellegrini TN, Marsden PA. Shiga toxin-associated hemolytic uremic syndrome: advances in pathogenesis and therapeutics. *Curr Opin Nephrol Hypertens* 2012;21:433-40. DOI: <http://dx.doi.org/10.1097/MNH.0b013e328354a62e>
4. Kavanagh D, Goodship TH, Richards A. Atypical hemolytic uremic syndrome. *Semin Nephrol* 2013;33:508-30. DOI: <http://dx.doi.org/10.1016/j.semnephrol.2013.08.003>
5. Izzedine H, Isnard-Bagnis C, Launay-Vacher V, Mercadal L, Tostivint I, Rixe O, et al. Gemcitabine-induced thrombotic microangiopathy: a systematic review. *Nephrol Dial Transplant* 2006;21:3038-45. DOI: <http://dx.doi.org/10.1093/ndt/gfl507>
6. Casper ES, Green MR, Kelsen DP, Heelan RT, Brown TD, Flombaum CD, et al. Phase II trial of gemcitabine (2,2'-difluorodeoxycytidine) in patients with adenocarcinoma of the pancreas. *Invest New Drugs* 1994;12:29-34. PMID: 7960602 DOI: <http://dx.doi.org/10.1007/BF00873232>
7. Fung MC, Storniolo AM, Nguyen B, Arning M, Brookfield W, Vigil J. A review of hemolytic uremic syndrome in patients treated with gemcitabine therapy. *Cancer* 1999;85:2023-32. DOI: [http://dx.doi.org/10.1002/\(SICI\)1097-0142\(19990501\)85:9%3C2023::AID-CNCR21%3E3.0.CO;2-2](http://dx.doi.org/10.1002/(SICI)1097-0142(19990501)85:9%3C2023::AID-CNCR21%3E3.0.CO;2-2)
8. Desramé J, Duvic C, Bredin C, Béchade D, Artru P, Brézault C, et al. Hemolytic uremic syndrome as a complication of gemcitabine treatment: report of six cases and review of the literature. *Rev Med Interne* 2005;26:179-88.

9. Vega J, Parodi C, Méndez GP, Goecke H Hemolytic-uremic syndrome associated with gemcitabine use: report of one case. *Rev Med Chil* 2013;141:797-802. PMID: 24121585
10. Walter RB, Joerger M, Pestalozzi BC. Gemcitabine-associated hemolytic-uremic syndrome. *Am J Kidney Dis* 2002;40:E16. PMID:12324937 DOI: <http://dx.doi.org/10.1053/ajkd.2002.35758>
11. Sadjadi SA, Annamaraju P. Gemcitabine induced hemolytic uremic syndrome. *Am J Case Rep* 2012;13:89-91. DOI:<http://dx.doi.org/10.12659/AJCR.882858>
12. Scully M, Goodship T. How I treat thrombotic thrombocytopenic purpura and atypical haemolytic uraemic syndrome. *Br J Haematol* 2014;164:759-66. DOI: <http://dx.doi.org/10.1111/bjh.12718>
13. Schwartz J, Winters JL, Padmanabhan A, Balogun RA, Delaney M, Linenberger ML, et al. Guidelines on the use of therapeutic apheresis in clinical practice-evidence-based approach from the Writing Committee of the American Society for Apheresis: the sixth special issue. *J Clin Apher* 2013;28:145-284. DOI: <http://dx.doi.org/10.1002/jca.21276>
14. Gore EM, Jones BS, Marques MB. Is therapeutic plasma exchange indicated for patients with gemcitabine-induced hemolytic uremic syndrome? *J Clin Apher* 2009;24:209-14.
15. Bharthuar A, Egloff L, Becker J, George M, Lohr JW, Deeb G, et al. Rituximab-based therapy for gemcitabine-induced hemolytic uremic syndrome in a patient with metastatic pancreatic adenocarcinoma: a case report. *Cancer Chemother Pharmacol* 2009;64:177-81. DOI: <http://dx.doi.org/10.1007/s00280-008-0900-x>