

Fascin overexpression in nasal mucosa in patients with chronic rhinosinusitis with and without nasal polyps

Superexpressão de fascina na mucosa nasal em pacientes com rinossinusite crônica com e sem pólipos nasais

Anton S. Tkachenko¹; Galina I. Gubina-Vakulyck¹; Anatolii I. Onishchenko¹; Iulii M. Kalashnyk¹; Yaroslava O. Butko²; Tatyana V. Gorbach²

1. Kharkiv National Medical University, Kharkiv, Ukraine. 2. National University of Pharmacy, Kharkiv, Ukraine.

ABSTRACT

Objective: The aim of our research is to assess fascin expression in nasal tissues of patients with chronic rhinosinusitis with (CRSwNP) and without (CRSSNP) nasal polyps. **Methods:** Fascin expression in nasal tissues of 11 CRSwNP patients and 10 CRSSNP patients was immunohistochemically evaluated and compared with control subjects. **Results:** Fascin was found to be strongly expressed in epithelial cells in polyps in CRSwNP and nasal tissue in CRSSNP. Its strong expression was observed both in lamina propria and nasal epithelial cells in CRSSNP. Fascin overexpression in nasal mucosa in CRSwNP was more pronounced compared with CRSSNP. In addition, proliferating epithelial cells in polyp tissue were weakly immunostained, whereas mature cells expressed much more fascin. **Conclusion:** CRSwNP and CRSSNP are associated with fascin overexpression, which makes fascin a promising target for therapeutic interventions.

Key words: fascin; nasal polyps; chronic rhinosinusitis; actins; epithelial-mesenchymal transition.

RESUMO

Objetivo: O objetivo desta pesquisa foi avaliar a expressão de fascina nos tecidos nasais de pacientes com rinossinusite crônica com (RSCcPN) e sem (RSCsPN) pólipos nasais. **Métodos:** A expressão de fascina nos tecidos nasais de 11 pacientes com RSCcPN e 10 pacientes com RSCsPN foi avaliada imuno-histoquimicamente e comparada com os indivíduos-controle. **Resultados:** Fascina foi encontrada por ser fortemente expressa em células epiteliais em pólipos na RSCcPN e em tecido nasal na RSCsPN. Sua forte expressão foi observada tanto na lâmina própria quanto nas células epiteliais nasais na RSCsPN. A superexpressão de fascina na mucosa nasal na RSCcPN foi mais pronunciada em comparação com a RSCsPN. Além disso, as células epiteliais em proliferação no tecido do pólipo foram imunocoradas fracamente, enquanto as células maduras expressaram muito mais fascina. **Conclusão:** RSCcPN e RSCsPN estão associadas à superexpressão de fascina, o que torna a fascina um alvo promissor para intervenções terapêuticas.

Unitermos: fascina; pólipos nasais; rinossinusite crônica; actinas; transição epitélio-mesenquimal.

RESUMEN

Objetivo: El objetivo de esta investigación fue evaluar la expresión de fascin en los tejidos nasales de pacientes con rinosinusitis crónica con (RSCcPN) y sin pólipos nasales (RSCsPN). **Métodos:** La expresión de fascin en los tejidos nasales de 11 pacientes con RSCcPN y 10 pacientes con RSCsPN fue analizada por inmunohistoquímica y comparada con los individuos control. **Resultados:** Fascina fue encontrada por ser fuertemente expresada en células epiteliales de pólipos en la RSCcPN y en tejido nasal en la RSCsPN. Su fuerte expresión fue observada tanto en la lámina propia como en las células epiteliales nasales en la RSCsPN.

La sobreexpresión de fascina en la mucosa nasal en la RSCcPN fue más pronunciada en comparación con la RSCsPN. Además, las células epiteliales proliferantes en el tejido del pólipo fueron inmunoteñidas débilmente, mientras las células maduras expresaron mucho más fascina. Conclusión: RSCcPN y RSCsPN están asociadas a la sobreexpresión de fascina, lo que hace la fascina un objetivo prometedor para intervenciones terapéuticas.

Palabras clave: fascina; pólipos nasales; rinosinusitis crónica; actinas; transición epitelial-mesenquimal.

INTRODUCTION

Chronic rhinosinusitis (CRS) is an inflammatory disease of nasal and paranasal mucosa that lasts at least twelve weeks⁽¹⁾. CRS clinically manifests by nasal discharge, facial pain, olfactory dysfunction, and nasal airway obstruction⁽²⁾. Depending on the morphological features of the chronic sinonasal inflammation, CRS is subdivided into two types: CRS with nasal polyps (CRSwNP) and CRS without nasal polyps (CRSSNP). The former is characterized by the development of benign growths on the nasal or paranasal mucosa. This type is less widespread and only 25% patients with CRS present nasal polyps. CRSSNP is therefore not accompanied by the formation of nasal polyps⁽³⁾. According to various estimates, the prevalence of CRS ranges from 4.5% to 12% in developed European and North American countries, making it a huge socioeconomic burden⁽⁴⁾. For example, the direct CRS-related costs in the United States reach 13\$ billion annually⁽⁵⁾.

It has been demonstrated that CRS is associated with microbial and fungal colonization of upper airways, changes in the nasal microbiome, defects in airway epithelial cell innate immune functions, impaired mucociliary clearance, abnormal expression of pro- and anti-inflammatory cytokines, tissue remodeling, epigenetic genome modifications, etc.⁽⁶⁻⁹⁾.

Despite numerous attempts to find out the detailed pathogenic mechanisms underlying CRSSNP and CRSwNP, they still remain to be elucidated. In particular, the role of fascin, an actin-bundling protein necessary for the formation of actin-based structures involved in cell motility and migration, in the development of CRS has not been reported. Elucidation of the mechanisms of the disease development and progression may aim at creating new therapeutic approaches, since the current treatment strategies, including antibacterial drugs, antihistamines, corticosteroids, and surgery, don't allow affecting and removing the root causes of CRS^(10,11).

The aim of our study was to investigate fascin expression in nasal tissues of CRSwNP and CRSSNP patients.

METHODS

Patients and tissue samples

A total of 28 patients were recruited from the Kharkiv Regional Clinical Hospital (Kharkiv, Ukraine). They were divided into three groups. Group 1 included 11 CRSwNP patients (seven males; four females) whose age ranged from 23 to 56 years with the mean age of 39.36 ± 3.39 years. Group 2 consisted of 10 patients (seven males; three females) varying from 21 to 50 years of age. Their mean age reached 35.8 ± 2.78 years. Seven control subjects (five males; two females) ranging from 23 to 59 years of age who underwent surgery due to nasal septum deviation under combined general and regional anesthesia formed group 3. Their mean age was 35.43 ± 4.86 years. Individuals from group 3 presented no clinical signs of inflammation in the sinonasal tissue. CRSwNP and CRSSNP were verified in accordance with the criteria of EPOS 2012: European Position Paper on Rhinosinusitis and NPs 2012 guidelines⁽¹²⁾.

Smokers, patients with acute or chronic inflammatory diseases, cystic fibrosis, or any signs of atopic diseases and asthma were excluded from the study. Patients were not administered oral and intranasal glucocorticoids for at least one month.

Immunohistochemistry

All nasal tissue samples were obtained during surgery. Tissue specimens were fixed in a 10% formalin solution. Four- μ m-thick sections from paraffin-embedded nasal tissues were immunostained using mouse monoclonal fascin antibodies purchased from Thermo Fischer Scientific (UK). The sections were incubated with the primary antibodies to fascin and treated with an anti-[mouse immunoglobulin class G (IgG)]-horseradish peroxidase conjugate. The distribution of peroxidase was visualized using 3,3'-diaminobenzidine (DAB).

Bioethics

All procedures and manipulations were carried out in accordance with the standards 196/96 of the Brazilian National

Health Council and the revised Declaration of Helsinki (2000). Our research was approved by the local Ethics and Bioethics Committee at Kharkiv National Medical University (Kharkiv, Ukraine). All subjects enrolled in our research signed the written informed consent.

RESULTS

In the control group, nasal mucosa was formed by a multi-row epithelium, basement membrane, and lamina propria. Epithelial cells were intact. The epithelium has all layers, and the contour of the junction separating the basal epithelium from the underlying lamina propria is slightly convoluted. No signs of inflammation were observed. The lamina propria is characterized by a high amount of lymphatic and blood vessels. It is slightly infiltrated with lymphocytes and macrophages.

In CRSsNP patients, the mucous membrane of the nasal cavity has signs of atrophy. Epithelial cells cover the lamina propria in one or two layers. The basement membrane is not observed in some areas. On the other hand, it is replaced by a thick layer of interstitial collagen in other regions. In some areas, the epithelial layer is thicker. It consists of more epitheliocytes, and epithelial papillae can be seen on the surface of the epithelium, indicating proliferation. The lamina propria is abundantly infiltrated with leukocytes. Neutrophils are the most abundant among them.

Analysis of samples of polyp tissues obtained from CRSwNP patients allowed revealing signs of epithelial atrophy. In some areas, epithelial layer was virtually absent. However, in some epithelial cells, euchromatic nuclei were found, indicating active proliferation. Such findings support that polyps were characterized by various morphofunctional states, i.e. hyperplastic and atrophic. The latter was accompanied by the development of thick collagen interlayer between nasal epithelial cells and lamina propria. However, some areas where the basement membrane was not revealed were found. The lamina propria was severely infiltrated with macrophages and lymphocytes (**Figure 1C-D**).

Immunohistochemistry performed on nasal tissue from control subjects showed that fascin expression was weak in nasal epithelial cells. Fascin immunostaining was observed in cytosol and was mainly limited to the basal layer of nasal epithelium.

Fascin immunostaining of samples from CRSsNP patients showed that fascin was strongly expressed in the mucous membrane of the nasal cavity. Fascin overexpression was observed both in the epithelial layer and in the lamina propria (**Figure 1A-B**) in CRSsNP patients. However, in some areas, fascin

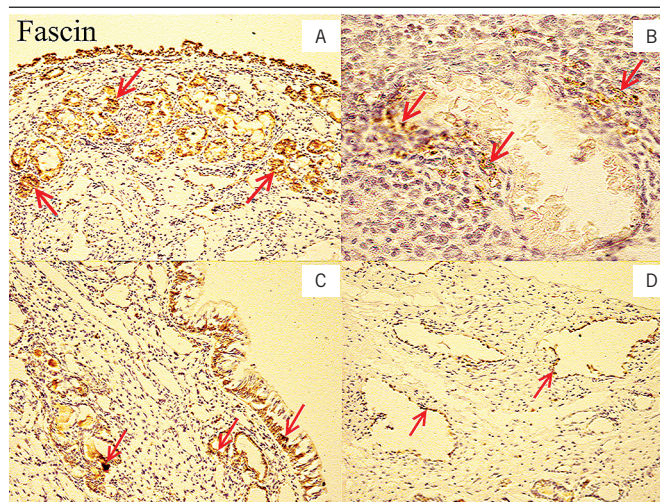


FIGURE 1 – Nasal tissues of patients with CRSsNP and CRSwNP were immunostained with fascin antibodies

A) nasal tissue of CRSsNP patient. Strong fascin expression is observed both in the epithelial layer and in the lamina propria (identified with red arrows), 100×; B) nasal tissue of an individual with CRSsNP. A vessel is surrounded by fascin-positive cells, which are identified with red arrows. The lamina propria is heavily infiltrated with macrophages and lymphocytes, 400×; C) polyp tissue of a CRSwNP patient. Fascin overexpression is revealed in nasal epithelial cells and in vascular walls in the lamina propria (identified with red arrows), 100×; D) polyp tissue of a CRSwNP patient. Fascin-positive cells are in the vascular walls in the lamina propria (identified with red arrows), 400×.

CRSwNP: chronic rhinosinusitis with nasal polyps; CRSsNP: chronic rhinosinusitis without nasal polyps.

expression was not observed. It is interesting to note that fascin upregulation was detected in the basal epithelial layer. It is worth noting that fascin expression is more abundant in the cytosol of superficial and glandular epithelial cells compared with areas of hyperproliferative epitheliocytes in nasal tissue.

Strong fascin staining was observed in the epithelial layer of the polyp tissue of patients with nasal polyps. However, there were areas of weakly fascin-labeled epithelial cells where epithelium seemed to proliferate, i.e. epitheliocytes and their nuclei were long and narrow. In areas where the epithelial cells were more mature, fascin was strongly expressed. Moreover, fascin-positive cells were found in vascular endothelial cells in the lamina propria (Figure 1C-D). However, in CRSwNP patients, endothelial cells in microcirculatory blood and lymphatic vessels lacked fascin labeling or were weakly labeled. Fascin overexpression in the nasal mucosa in CRSwNP was more pronounced compared with CRSsNP.

DISCUSSION

Fascin is an evolutionarily conserved 55kDa protein involved in the formation of bundles from actin microfilaments⁽¹³⁻¹⁵⁾. It is used by the cells for microspikes, filopodia, and invadopodia

formation to provide motility and cell migration. Thus, fascin is widely overexpressed in various types of tumors⁽¹⁶⁾. In normal human tissues, fascin expression is detected in nerve cells, dendritic cells, and endothelial cells^(17, 18).

The main interest of our study was to compare fascin expression patterns in healthy individuals and patients with two forms of chronic rhinosinusitis: CRSsNP and CRSwNP. We observed weak cytosolic fascin expression in nasal epithelial cells of control subjects. This finding is consistent with other reports on fascin expression in upper airways. In particular, Papaspyrou K *et al.* (2014)⁽¹⁹⁾ and Hashimoto Y *et al.* (2006)⁽²⁰⁾ have demonstrated that fascin is either not expressed or insignificantly locally expressed in healthy adult nasal epithelial cells.

A notable observation in the present study was that fascin is upregulated in the nasal epithelium in tissue specimens from both CRSsNP and CRSwNP patients. We can presume that such changes in fascin immunostaining are indicative of the increased ability of fascin-expressing nasal epithelial cells to migrate. This becomes possible due to the fact that fascin upregulation in such epitheliocytes promotes the formation of fascin-containing actin bundles⁽²¹⁾.

We believe that fascin may be involved in tissue repair in CRS. It is known that CRS is accompanied by mucosal destruction. Fascin-expressing cells gain the ability to move and therefore to close gaps in the epithelial layer. In addition, the virtual absence of fascin expression in actively proliferating nasal epithelial cells found in this study may be due to their immaturity and low

rates of differentiation. Moreover, it has been reported that fascin upregulation is associated with the epithelial-to-mesenchymal transition (EMT), which is characterized by the ability of epithelial cells to gain features of mesenchymal cells (loss of cell-cell interaction, acquisition of migratory capacity, etc.)^(22, 23). Mao X *et al.* (2016)⁽²²⁾ have also demonstrated that fascin expression is positively correlated with vimentin expression. The latter is a well established and characterized EMT biomarker expressed exclusively in cells of mesenchymal origin unlike epithelial cells⁽²⁴⁾. We found that CRSwNP was associated with vimentin overexpression in the nasal epithelial layer⁽²⁵⁾. In addition, our recent findings suggest that CRSsNP is also accompanied by vimentin upregulation in nasal epithelial cells, however, to a lesser extent compared with CRSwNP^(25, 26). Thus, our current data may support the activation of EMT in the nasal epithelium of patients with chronic rhinosinusitis.

Fascin in CRS may be a potential target for therapeutic interventions to affect tissue repair and promote the resolution of the inflammatory process. However, further studies are required to assess the possible advantages and disadvantages of fascin-affecting interventions, since they may worsen the healing process of mucosal lesions in inflammation.

CONFLICT OF INTERESTS

The authors declare no conflict of interest.

REFERENCES

- Lam K, Schleimer R, Kern RC. The etiology and pathogenesis of chronic rhinosinusitis: a review of current hypotheses. *Curr Allergy and Asthma Rep.* 2015; 15(7): 41.
- Hoffmans R, Wagemakers A, van Druenen C, Hellings P, Fokkens W. Acute and chronic rhinosinusitis and allergic rhinitis in relation to comorbidity, ethnicity and environment. *PLoS One.* 2018; 13(2): e0192330.
- Stevens WW, Schleimer RP, Kern RC. Chronic rhinosinusitis with nasal polyps. *J Allergy Clin Immunol Pract.* 2016; 4(4): 565-72.
- DeConde AS, Soler ZM. Chronic rhinosinusitis: epidemiology and burden of disease. *Am J Rhinol Allergy.* 2016; 30(2): 134-9.
- Rudmik L. Economics of chronic rhinosinusitis. *Curr Allergy Asthma Rep.* 2017; 17(4): 20.
- Kim JY, Kim DK, Yu MS, Cha MJ, Yu SL, Kang J. Role of epigenetics in the pathogenesis of chronic rhinosinusitis with nasal polyps. *Mol Med Rep.* 2018; 17(1): 1219-27.
- Mahdavinia M, Keshavarzian A, Tobin MC, Landay A, Schleimer RP. A comprehensive review of the nasal microbiome in chronic rhinosinusitis (CRS). *Clin Exp Allergy.* 2016; 46(1): 21-41.
- Hulse KE, Stevens WW, Tan BK, Schleimer RP. Pathogenesis of nasal polyposis. *Clin Exp Allergy.* 2015; 45(2): 328-46.
- Gudis D, Zhao K, Cohen NA. Acquired cilia dysfunction in chronic rhinosinusitis. *Am J Rhinol Allergy.* 2012; 26(1): 1-6.
- Piromchai P, Kasemsiri P, Laohasiriwong S, Thanaviratananich S. Chronic rhinosinusitis and emerging treatment options. *Int J General Med.* 2013; 6: 453-64.
- Tan BK, Schleimer RP, Kern RC. Perspectives on the etiology of chronic rhinosinusitis. *Curr Opin Otolaryngol Head Neck Surg.* 2010; 18(1): 21-6.
- Fokkens WJ, Lund VJ, Mullol J, et al. EPOS 2012: European position paper on rhinosinusitis and nasal polyps 2012. A summary for otorhinolaryngologists. *Rhinology.* 2012; 50(1): 1-12.
- Adams JC. Fascin-1 as a biomarker and prospective therapeutic target in colorectal cancer. *Expert Rev Mol Diagn.* 2015; 15(1): 41-8.
- Qualtrough D, Smallwood K, Littlejohns D, Pignatelli M. The actin-bundling protein fascin is overexpressed in inflammatory bowel disease and may be important in tissue repair. *BMC Gastroenterol.* 2011; 11: 14.
- Machesky LM, Li A. Fascin: invasive filopodia promoting metastasis. *Commun Integr Biol.* 2010; 3(3): 263-70.

16. Villari G, Jayo A, Zanet J, et al. A direct interaction between fascin and microtubules contributes to adhesion dynamics and cell migration. *J Cell Sci.* 2015; 128(24): 4601-14.
17. Min KW, Chae SW, Kim DH, et al. Fascin expression predicts an aggressive clinical course in patients with advanced breast cancer. *Oncol Lett.* 2015; 10(1): 121-30.
18. Zhang F-R, Tao L-H, Shen Z-Y, Lv Z, Xu L-Y, Li E-M. Fascin expression in human embryonic, fetal, and normal adult tissue. *J Histochem Cytochem.* 2008; 56(2): 193-9.
19. Papaspyrou K, Brochhausen C, Schmidtman I, et al. Fascin upregulation in primary head and neck squamous cell carcinoma is associated with lymphatic metastasis. *Oncol Lett.* 2014; 7(6): 2041-6.
20. Hashimoto Y, Skacel M, Lavery IC, Mukherjee AL, Casey G, Adams JC. Prognostic significance of fascin expression in advanced colorectal cancer: an immunohistochemical study of colorectal adenomas and adenocarcinomas. *BMC Cancer.* 2006; 6: 241.
21. Yamashiro S, Yamakita Y, Ono S, Matsumura F. Fascin, an actin-bundling protein, induces membrane protrusions and increases cell motility of epithelial cells. *Mol Biol Cell.* 1998; 9(5): 993-1006.
22. Mao X, Duan X, Jiang B. Fascin induces epithelial-mesenchymal transition of cholangiocarcinoma cells by regulating Wnt/ β -catenin signaling. *Med Sci Monit.* 2016; 22: 3479-85.
23. Morris HT, Machesky LM. Actin cytoskeletal control during epithelial to mesenchymal transition: focus on the pancreas and intestinal tract. *Br J Cancer.* 2015; 112(4): 613-20.
24. Mao X, Chen D, Wu J, et al. Differential expression of fascin, E-cadherin and vimentin: proteins associated with survival of cholangiocarcinoma patients. *Am J Med Sci.* 2013; 346(4): 261-8.
25. Onishchenko AI, Lupyr AV, Tkachenko AS, Gorbach TV, Nakonechna OA, Gubina-Vakulyck GI. Epithelial-to-mesenchymal transition and some parameters of extracellular matrix remodeling in chronic rhinosinusitis with nasal polyps. *HVM Bioflux.* 2018; 10(3): 128-32.
26. Onishchenko AI, Tkachenko AS, Kalashnyk IM, et al. Vimentin expression in nasal mucosa of patients with exacerbated chronic rhinosinusitis without nasal polyps. *Acta Medica Bulgarica.* 2019; 46(1): 39-42.

CORRESPONDING AUTHOR

Anton S. Tkachenko  0000-0002-1029-1636
e-mail: antontkachenko555@gmail.com



This is an open-access article distributed under the terms of the Creative Commons Attribution License.