

Case Report

Pulmonary actinomycosis as a pseudotumor: A rare presentation*

Actinomicose pulmonar na forma pseudotumoral: Uma apresentação rara

Hylas Paiva da Costa Ferreira, Carlos Alberto Almeida de Araújo,
Jeancarlo Fernandes Cavalcanti, Roberta Lacerda Almeida de Miranda,
Rachel de Alcântara Oliveira Ramalho

Abstract

Some lung diseases are true diagnostic challenges due to their various clinical presentations. Actinomycosis is one such disease, potentially affecting various organs and systems. We report the case of a patient with pulmonary actinomycosis as a pseudotumor, which is usually only diagnosed by thoracotomy or thoracoscopy.

Keywords: Actinomycosis; Thoracic neoplasms; Bacterial infections and mycoses.

Resumo

Algumas patologias pulmonares apresentam-se como verdadeiros desafios diagnósticos devido às suas diversas formas de apresentação. A actinomicose é uma dessas patologias, podendo atingir diversos órgãos e sistemas. Relatamos o caso de uma paciente com a forma pseudotumoral pulmonar da doença, cujo seu diagnóstico geralmente só é realizado através de toracotomia ou toracoscopia.

Descritores: Actinomicose; Neoplasias torácicas; Infecções bacterianas e micoses.

Introduction

Actinomycosis is a rare, chronic disease, and there is thoracic involvement in 15-50% of cases.⁽¹⁾ Actinomycosis is characterized by the formation of abscesses and by tissue fibrosis.⁽²⁾ The disease is caused by facultative anaerobic gram-positive bacteria that normally colonizes the mouth, colon, and urogenital tract.^(1,3-5) The bacterium was first isolated from human autopsy material by Israel in 1878,^(2,3) and the first case of pulmonary actinomycosis was described by Ponfick in 1882.⁽³⁾ The pathogenic species of *Actinomyces* do not exist in nature; they are natural inhabitants and commensals of the oropharynx, gastrointestinal tract, and female genital tract in humans; consequently, humans are a natural reservoir of *Actinomyces* spp.,⁽²⁾ and there have been no reports of person-to-person transmission.^(1,2,5) Because the microorganism involved is not virulent, the adjacent tissues will become infected only if there is a loss of

mucosal integrity.^(4,5) The cervicofacial, thoracic, abdominal, and pelvic areas, as well as the central nervous system, are the areas that are most commonly affected,^(1,2) and the treatment of choice is long-term penicillin therapy.⁽¹⁾

Case report

A 26-year-old female patient was hospitalized for the investigation of a tumor mass in the left upper lobe, with invasion of the mediastinum and chest wall. The patient presented with a 60-day history of chest pain that did not radiate and did not improve with the use of analgesics. The pain was accompanied by daily fever, dyspnea, worsening of overall health status, and productive cough with mucoid expectoration. She reported no weight loss or hemoptysis; nor did she report headache or other neurological symptoms.

* Study carried out at the Onofre Lopes University Hospital, *Universidade Federal do Rio Grande do Norte* – UFRN, Federal University of Rio Grande do Norte – Natal, Brazil.

Correspondence to: Hylas Paiva da Costa Ferreira. Rua Auris Coelho, 235, Lagoa Nova, CEP 59075-050, Natal, RN, Brasil.

Tel 55 84 9623-0910. E-mail: endotorax@hotmail.com

Financial support: None.

Submitted: 12 May 2010. Accepted, after review: 25 August 2010.

The patient was referred to the thoracic surgery department of our hospital for diagnostic investigation. Contrast-enhanced magnetic resonance imaging showed a mass with irregular borders, measuring 9.2 × 7.2 × 6.0 cm. The mass occupied the entire left upper lobe, invading the mediastinum and chest wall and involving the left common carotid artery, the left subclavian artery, and part of the aortic arch (Figure 1). A CT scan of the chest revealed invasion of the abovementioned structures and of the vertebral bodies, as well as the left supraclavicular fossa (Figures 2 and 3).

Two CT-guided transthoracic needle biopsies were performed, but the results were inconclusive (chronic inflammatory process). Because the results were inconclusive, we decided to perform exploratory thoracotomy, which revealed intense hepatization in the left upper lung lobe and a hardened mass that bled when cut. Frozen section analysis was negative for neoplasia. The Grocott-Gomori methenamine-silver stain technique revealed filamentous structures and foreign body giant cell reaction, which facilitated the diagnosis of pulmonary actinomycosis.

Treatment with crystalline penicillin was initiated, and, on postoperative day 7, the patient presented with progressive clinical worsening, accompanied by psychomotor agitation and progressive respiratory failure. Mechanical ventilation and vasoactive drugs were required. On post-admission day 30, the patient presented with convulsions, which responded well to the use of anticonvulsants. Treatment with crystalline penicillin was continued. The patient showed progressive improvement and was discharged with a prescription for 6 months of continuous treatment with amoxicillin. Complete remission was achieved. At this writing, the patient presented with fibrosis of the left lower lobe and was under follow-up treatment.

Discussion

Actinomycosis is a chronic granulomatous infectious disease,⁽⁶⁾ caused by a filamentous, anaerobic gram-positive microorganism of the genus *Actinomyces*,^(2,3,6) a microorganism that is part of the microbiota of the oral cavity, gastrointestinal tract, and urogenital tract.^(1,4-6) Approximately 30 *Actinomyces* spp. have been isolated, and the most common are *A. israelii*, *A. naeslundii*, *A. odontolyticus*, *A. viscosus*,

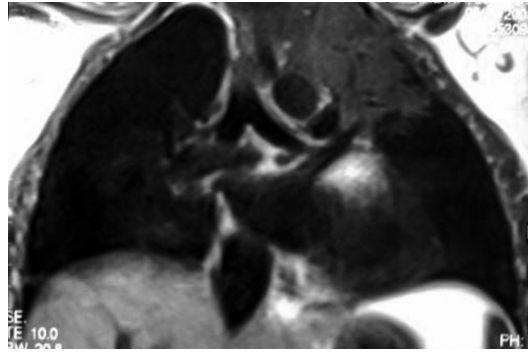


Figure 1 - Magnetic resonance imaging of the chest revealing a pulmonary mass without cleavage planes and with mediastinal structures.

A. meyeri, and *A. gerencseriae*,^(3,5) which are the species that are pathogenic for humans.⁽²⁾

Although the genus *Actinomyces* was once classified as a fungus because of its hyphal branching, it is currently classified as a bacterium,^(2,5,7) which presents endemically and is universally distributed, with no predominance of gender, age, race, occupation, or time of year. Although colonization with *Actinomyces* sp. is not considered an opportunistic infection, it is most common in patients with some degree of immunodeficiency.⁽⁵⁾

Pulmonary actinomycosis generally results from the aspiration of oropharyngeal or gastrointestinal secretions into the respiratory tract.⁽⁸⁾ Alcoholism, poor oral hygiene, and dental caries can also contribute to the development of the disease.⁽⁸⁾ This type of infection generally involves the cervicofacial region in approximately 55% of the cases,^(3,6,7,9,10) the thoracic region in approximately 15% of the cases,^(1,3,6,7,9,10) and

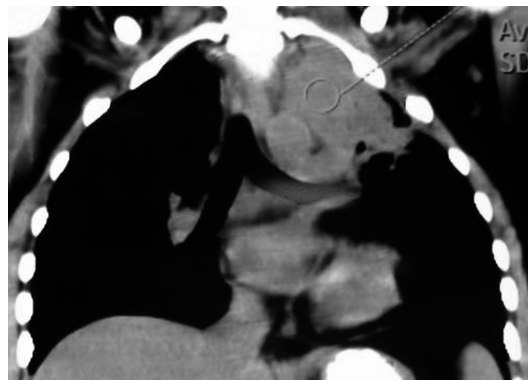

Figure 2 - Chest CT scan revealing a mass invading the chest wall, without cleavage planes and with mediastinal structures.

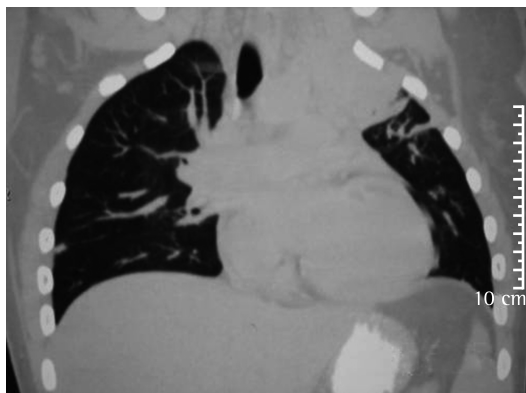


Figure 3 – Chest CT scan (lung window).

the abdominal/pelvic region in 20% of the patients,^(3,6,7,9,10) as well as the central nervous system, in a lower proportion of cases.^(3,9,10) The incidence of pulmonary actinomycosis has decreased because of the widespread use of antibiotics.⁽⁵⁾ Because of the uncommon presentation—large masses and invasion of adjacent structures—it is difficult to make a diagnosis of pulmonary actinomycosis, and the infection is easily mistaken for neoplasia. In general, pulmonary actinomycosis is diagnosed only by histopathological examination.^(1,3,5,11,12) The diagnosis is typically delayed because of the indolent natural history of the disease and the absence of inflammatory signs.⁽³⁾ Because pulmonary actinomycosis can coexist with lung cancer, nocardiosis, and tuberculosis,^(1,2) the diagnosis can be established by isolating *Actinomyces* sp. from tissue samples collected by thoracotomy.^(4,7-9) Therefore, tissue culture is required, and colonies appear after 3–7 days of incubation⁽²⁾; however, in order to confirm the diagnosis, the culture should remain under observation for 21 days.⁽²⁾

Thoracic actinomycosis is uncommon and, when it does occur, can be erroneously diagnosed as bronchopneumonia or lung cancer.⁽⁷⁾ Thoracic actinomycosis is far more common in adults than in children, as well as being far more common in males than in females.^(3,8,12) Thoracic actinomycosis can involve the lungs and pleura, as well as invading the mediastinum and chest wall.^(2,5,7) The expansion of a chronic pulmonary focus can lead to the development of empyema and invasion/destruction of the ribs, scapular girdle, and sternum.⁽²⁾ The involvement of mediastinal structures rarely results in

superior vena cava syndrome, tracheoesophageal fistula, or pericarditis/myocarditis.⁽²⁾ The onset of pulmonary actinomycosis is insidious (with cough, expectoration, fever, and weight loss), and hemoptysis or pleuritic pain can occur.⁽¹⁾ Inflammatory tissue can form within and obstruct the bronchus.⁽¹⁾ Hemoptysis is common and has been reported in up to 50% of the cases evaluated in case series.⁽¹²⁾

The incidence of pulmonary actinomycosis is higher in male patients because, among males, the number of cases of facial trauma is higher and oral hygiene is poorer.^(3,8) Pulmonary actinomycosis accounts for approximately 15–45% of all reported cases of actinomycosis, and cardiac involvement is rarer, accounting for only 2% of the cases.⁽⁵⁾ The species that is most commonly isolated in the thoracic form of the disease is *A. israelii*.⁽⁷⁾ The routes of *Actinomyces* infection include aspiration of oropharyngeal secretions or gastric contents; direct extension of cervicofacial infection to the mediastinum through the deep fascia of the neck; transdiaphragmatic or retroperitoneal infection from the abdomen; and, more rarely, hematogenous dissemination.^(2,7) The signs and symptoms are nonspecific and highly variable,⁽⁴⁾ the most common being chest pain, dyspnea, fever, weight loss, and cough,^(2,4,5,8,9,12) which are sometimes mistaken for symptoms of tuberculosis or neoplasia.⁽²⁾ Patients can also present with leukocytosis, accompanied by neutrophilia and moderate anemia.^(1,9)

There are no radiological signs that are indicative of thoracic actinomycosis,⁽⁴⁾ and chest X-ray findings can mimic a wide variety of diseases, including pulmonary infiltrate (suggestive of mild pneumonia) and micronodular infiltrate accompanied by pulmonary cavitation or large masses (suggestive of neoplasia), pleural effusion being common.^(1,2,4,8,9) In advanced cases, a CT scan of the chest can reveal involvement of the chest wall, mediastinal involvement, and pleural involvement.^(1,4,9) An image of diffuse involvement that crosses anatomical boundaries is highly suggestive of pulmonary actinomycosis.⁽⁴⁾

The differential diagnosis of pulmonary actinomycosis includes recurrent pneumonia, pulmonary infarction, lung cancer, Wegener's granulomatosis, nocardiosis, pulmonary sequestration, and bronchogenic cyst.^(1,2)

The prognosis of infections is excellent if treatment is given in a timely manner. Hematogenous dissemination is a relatively common complication of the thoracic and advanced forms of the disease.^(1,4,5) Less common complications, such as pleural empyema, hemoptysis, and chronic sinusitis, can also occur.⁽⁴⁾ The lack of diagnostic suspicion of actinomycosis can worsen the prognosis or treatment results, as well as leading patients to undergo unnecessary extensive surgery.⁽⁴⁾

The genus *Actinomyces* is susceptible to a wide variety of antibiotics in vitro, and penicillin G is the drug of choice for the treatment of actinomycosis, therapy consisting of high doses (18-24 million IU/day) for 2-6 weeks, followed by oral amoxicillin for 6-12 months.^(1-4,6-10,12) Patients who are allergic to penicillin can be treated with doxycycline, erythromycin, or cephalosporins, all of which have been shown to be effective.^(2,3,5,8,12) However, most strains are resistant to ciprofloxacin.⁽³⁾ There are reports of satisfactory results with the use of levofloxacin,⁽¹⁾ and some authors have suggested that patients with pulmonary actinomycosis can be individual candidates for shorter courses of antibiotics.⁽¹¹⁾ Surgical treatment of actinomycosis is controversial and should be restricted to abscess drainage, debridement of necrotic tissue, curettage of bone, and drainage of empyema.^(2,5) Mortality is relatively low, depending on the site of infection and on early diagnosis. However, there have been case series in which the reported mortality was as high as 28%.^(4,5)

In conclusion, actinomycosis is a disease of insidious onset with nonspecific symptoms and therefore poses a diagnostic challenge. The disease should be included in the differential diagnosis when patients with poor oral hygiene present with chronic pneumonia or a

pulmonary mass suggestive of lung cancer but accompanied by air bronchogram and an area of low attenuation on CT scans of the chest.

References

1. Ferreira Dde F, Amado J, Neves S, Taveira N, Carvalho A, Nogueira R. Treatment of pulmonary actinomycosis with levofloxacin. *J Bras Pneumol.* 2008;34(4):245-8.
2. Smego RA Jr, Foglia G. Actinomycosis. *Clin Infect Dis.* 1998;26(6):1255-61; quiz 1262-3.
3. Bartlett AH, Rivera AL, Krishnamurthy R, Baker CJ. Thoracic actinomycosis in children: case report and review of the literature. *Pediatr Infect Dis J.* 2008;27(2):165-9.
4. Barikbin P, Grosser K, Hahn G, Fischer R, Suttrop M. Thoracic actinomycosis imitating a malignant chest wall tumor. Diagnosis: pulmonary actinomycosis. *J Pediatr Hematol Oncol.* 2007;29(5):345-6.
5. Acevedo F, Baudrand R, Letelier LM, Gaete P. Actinomycosis: a great pretender. Case reports of unusual presentations and a review of the literature. *Int J Infect Dis.* 2008;12(4):358-62.
6. Sudhakar SS, Ross JJ. Short-term treatment of actinomycosis: two cases and a review. *Clin Infect Dis.* 2004;38(3):444-7.
7. Endo S, Murayama F, Yamaguchi T, Yamamoto S, Otani S, Saito N, et al. Surgical considerations for pulmonary actinomycosis. *Ann Thorac Surg.* 2002;74(1):185-90.
8. Santos JW, Nascimento DZ, Guerra VA, Vassoler RM, Simon TT, Machado FP, et al. Pulmonary Actinomycosis: An old disease that is still diagnosed late. *Clin Pulm Med.* 2008;15(3):173-6.
9. Taştepe AI, Ulaşan NG, Liman ST, Demircan S, Uzar A. Thoracic actinomycosis. *Eur J Cardiothorac Surg.* 1998;14(6):578-83.
10. Filipović B, Milinić N, Nikolić G, Ranthelović T. Primary actinomycosis of the anterior abdominal wall: case report and review of the literature. *J Gastroenterol Hepatol.* 2005;20(4):517-20.
11. Choi J, Koh WJ, Kim TS, Lee KS, Han J, Kim H, et al. Optimal duration of IV and oral antibiotics in the treatment of thoracic actinomycosis. *Chest.* 2005;128(4):2211-7.
12. Murali G, Selcer U, Lippmann M. Life-threatening hemoptysis with thoracic actinomycosis. Two cases reports and review of the literature. *Clin Pulm Med.* 2004;11(2):112-6.

About the authors

Hylas Paiva da Costa Ferreira

Professor of Thoracic Surgery. *Universidade Federal do Rio Grande do Norte* – UFRN, Federal University of Rio Grande do Norte – Natal, Brazil.

Carlos Alberto Almeida de Araújo

Professor of Thoracic Surgery. *Universidade Federal do Rio Grande do Norte* – UFRN, Federal University of Rio Grande do Norte – Natal, Brazil.

Jeancarlo Fernandes Cavalcanti

Professor of Emergency Medicine. *Universidade Federal do Rio Grande do Norte* – UFRN, Federal University of Rio Grande do Norte – Natal, Brazil.

Roberta Lacerda Almeida de Miranda

General Practitioner. Onofre Lopes University Hospital, *Universidade Federal do Rio Grande do Norte* – UFRN, Federal University of Rio Grande do Norte – Natal, Brazil.

Rachel de Alcântara Oliveira Ramalho

Doctoral Student in Medicine. *Universidade Federal do Rio Grande do Norte* – UFRN, Federal University of Rio Grande do Norte – Natal, Brazil.