

## Semiquantitative analysis of surgical biopsies of distinct lung lobes of patients with usual interstitial pneumonia/idiopathic pulmonary fibrosis\*

Análise semiquantitativa de biópsias cirúrgicas de diferentes lobos pulmonares de pacientes com pneumonia intersticial usual/fibrose pulmonar idiopática

José Júlio Saraiva Gonçalves, Luiz Eduardo Villaça Leão, Rimarcos Gomes Ferreira, Renato Oliveira, Luiz Hirotoshi Ota, Ricardo Sales dos Santos

### Abstract

**Objective:** To evaluate the differences between surgical biopsies of distinct lung lobes in terms of the histopathological features of usual interstitial pneumonia, using a semiquantitative score. **Methods:** We selected all of the patients diagnosed with idiopathic pulmonary fibrosis and submitted to surgical biopsy in two distinct lobes between 1995 and 2005 at the *Hospital São Paulo* and other hospitals operated by the Federal University of São Paulo. In the histological evaluation of the specimens, we used a semiquantitative method based on previous studies, assigning a score to each of the biopsied sites. **Results:** In this sample of patients, we found no statistically significant differences that would alter the stage of the disease, based on the score used. This finding was independent of the biopsy site (middle lobe or lingular segment). **Conclusions:** No significant histological differences were found between the lung lobes studied. The definitive histological diagnosis of usual interstitial pneumonia did not alter the stage of the disease.

**Keywords:** Lung diseases, interstitial; Pulmonary fibrosis; Thoracic surgery; Pathology; Thoracic surgery, video-assisted.

### Resumo

**Objetivo:** Avaliar as diferenças histológicas da pneumonia intersticial usual entre biópsias cirúrgicas de lobos pulmonares distintos, utilizando um escore semiquantitativo. **Métodos:** Foram selecionados todos os pacientes com o diagnóstico de fibrose pulmonar idiopática e submetidos à biópsia cirúrgica em dois lobos distintos no Hospital São Paulo e em hospitais afiliados da Universidade Federal de São Paulo, no período entre 1995 e 2005. Foi utilizado um método semiquantitativo na avaliação histológica dos espécimes, com base em estudos prévios, aplicando-se um escore para cada local submetido à biópsia. **Resultados:** Nenhuma diferença estatisticamente significativa foi encontrada nesta amostra de pacientes que viesse alterar o estágio da doença, com base no escore utilizado. Este achado foi independente do local da biópsia (lobo médio ou segmento lingular). **Conclusões:** Não foram observadas diferenças histológicas significantes entre os lobos pulmonares estudados. O diagnóstico histológico definitivo de pneumonia intersticial usual não alterou o estágio da doença.

**Descritores:** Doenças pulmonares intersticiais; Fibrose pulmonar; Cirurgia torácica; Patologia; Cirurgia torácica vídeo-assistida.

---

\* Study carried out in the Department of Thoracic Surgery, *Universidade Federal de São Paulo/Escola Paulista de Medicina* – UNIFESP/ EPM, Federal University of São Paulo/Paulista School of Medicine – São Paulo, Brazil.

Correspondence to: José Júlio Saraiva Gonçalves. Hospital São Paulo, Rua Napoleão de Barros, 715, 4º andar, Vila Clementino, CEP 04024-002, São Paulo, SP, Brasil.

Tel 55 11 5576-4295. E-mail: jjsgon@gmail.com

Financial support: None.

Submitted: 19 September 2008. Accepted, after review: 19 February 2009.

## Introduction

The clinical diagnosis of idiopathic pulmonary fibrosis (IPF) is associated with the histopathological pattern known as usual interstitial pneumonia (UIP).<sup>(1)</sup> The mean survival, after IPF has become established, ranges from two to six years.<sup>(2)</sup> More than 50% of patients with IPF die within two to three years after diagnosis,<sup>(3)</sup> as a consequence of complications resulting from the severe restrictive ventilatory defect, for which there is currently no satisfactory treatment.<sup>(4)</sup> In Brazil, data on the incidence and prevalence of the disease are scarce.<sup>(5)</sup> However, based on a Latin-American study, it is estimated that there are 2,225 new cases in men and 1,416 in women per year in the state of São Paulo alone. The mortality rate in the south of Brazil was reported to be 0.48/100,000 population in the 1990s.<sup>(5)</sup>

One of the significant histological characteristics of UIP is its temporal and regional heterogeneity, that is, the presence of areas of recent aggression in close proximity to regions of healing, together with apparently normal lung parenchyma.<sup>(6)</sup> Therefore, the criteria for this diagnosis, from a histopathological standpoint, are findings of fibrosis, limited chronic inflammation, honeycombing, fibroblastic foci and architectural remodeling of the acini and lobes.<sup>(7)</sup>

Since UIP has a heterogenous aspect, from a histological and tomographic standpoint, it cannot be adequately represented even in surgical biopsy specimens. This suggests that the site to be biopsied should be selected with caution, since the quality of the biopsy influences the diagnostic yield and the accuracy of disease staging. However, in the current literature, there is no consensus regarding the biopsy site, the ideal size of the lung parenchyma samples to be obtained or the number of such samples needed.<sup>(8-13)</sup> Nor is it known what influence these factors have on diagnosis or disease staging. Existing studies using semiquantitative techniques for histopathological analysis to evaluate biopsy samples obtained from distinct lung lobes present conflicting results.<sup>(8-13)</sup> As was observed, patients with IPF make ideal subjects in which to study the disparate histopathological alterations in a given patient, lung or lobe, as well as in contiguous areas.

The sensitivity and specificity of surgical biopsy are, on average, over 90%.<sup>(14)</sup> The objec-

tive of this study was to evaluate the differences between surgical biopsies of two lung lobes, such as the lingular segment and the middle lobe, in terms of the histopathological features of UIP, using a semiquantitative score.

## Methods

This was a retrospective study of 89 surgical lung biopsies (in 59 patients) performed, at the *Hospital São Paulo* and other hospitals operated by the *Universidade Federal de São Paulo* (UNIFESP, Federal University of São Paulo), between 1995 and 2005. All of the samples selected had been categorized histopathologically as being consistent with a diagnosis of UIP. The inclusion criteria were as follows: histopathological diagnosis of UIP and surgical lung biopsy of two lobes, one of which was the middle lobe or the lingular segment. The following exclusion criteria were applied: interstitial diseases secondary to collagenosis; exposure to chemical agents; other interstitial diseases; and diagnostic discordance between the biopsied lobes, even if the final clinical and radiological diagnosis was IPF. The project was approved by the UNIFESP Research Ethics Committee (Protocol no. 1.063/05).

All of the lung tissue specimens were collected by video-assisted thoracoscopy or anterior mini-thoracotomy. The histological sections were stained with H&E and Masson's trichrome. The pathologist was blinded to the biopsy site and patient identity.

The semiquantitative technique used in the histological analysis of the lung biopsies was based on the original description by Cherniak et al.<sup>(15,16)</sup> that was later validated by Hyde et al.,<sup>(17)</sup> who demonstrated the concord-

**Table 1** – Characteristics of the sample.

Characteristic	All surgical patients	Study group
Number of patients	59	16
Number of biopsies	89	32
Gender, male/female	45%/55%	56%/44%
Minimum age, years	34	31
Maximum age, years	76	75
Age, years (mean ± SD)	58.3 ± 9.6	55.5 ± 12.0
Concordant biopsies, n	44	32
Discordant biopsies, n	9	0

ance between this technique and the classical technique of quantitative morphometry. Other research centers in Brazil have published their experience using the same score, confirming previously published findings.<sup>(18,19)</sup>

For the use of this score, three main criteria for quantification were established: a) exudative/inflammatory changes; b) fibrotic/reparative changes; and c) airway changes. These alterations were quantified using a scale ranging from 0 to 5 for criteria a and b, together with a scale ranging from 0 to 2 for criterion c.

The level of statistical significance was set at 5% ( $\alpha = 0.05$ ). The program Statistical Package for the Social Sciences, version 13.0 (SPSS Inc., Chicago, IL, USA) was used for this analysis.

## Results

Of the 59 patients selected, 28 were excluded for having had only one site biopsied. Another 9 patients had discordance between the lobes: 3 due to nonspecific interstitial pneumonia; 3 due to an unclassifiable pattern; and 3 due to the fact that they had only emphysema in one of the lobes. Of the remaining 22 patients, 4 had had two specimens collected from the same lobe and 2 were excluded for having been submitted to biopsies that were performed on the same side (the right) but did not include the middle lobe.

Therefore, 16 patients (32 biopsies) fully met the inclusion criteria established. The statistical analysis was performed during this patient selection, and patients were divided into four groups according to the biopsy site.

There were no significant differences between the sides (right or left lung) in terms of age, gender or other characteristics of the patients (Table 1). Regarding the other variables, the lobes studied proved to be statistically different only in terms of the presence of fibroblastic foci ( $p = 0.011$ , Table 2). We found statistically significant differences for the variable "fibroblastic focus", this finding being significantly more common in the left lower lobe samples than in those obtained from the other sites.

No significant differences were found in terms of the other factors evaluated, regardless of the biopsy site. The differences found did not alter the overall disease staging.

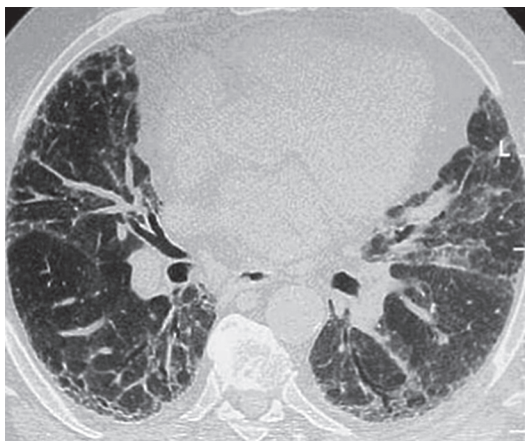
**Table 2** – Analysis of the statistical significance of the differences among all of the lung lobes biopsied.

Variable	Site	Mean	SD	p*
Extent of cellularity	ML	3.00	0.76	0.495
	RLL	3.13	0.64	
	LIG	2.63	0.74	
	LLL	2.88	0.64	
Intensity of cellularity	ML	3.00	0.76	0.572
	RLL	3.25	0.71	
	LIG	2.75	0.71	
	LLL	2.88	0.83	
Alveolar metaplasia	ML	1.75	0.89	0.531
	RLL	2.50	1.20	
	LIG	2.13	0.99	
	LLL	2.50	1.20	
Desquamation	ML	2.25	0.71	0.607
	RLL	2.50	0.53	
	LIG	2.50	0.76	
	LLL	2.75	0.71	
Fibroblastic focus	ML	1.75	0.46	0.011
	RLL	2.00	0	
	LIG	2.63	1.19	
	LLL	2.88	0.64	
Interstitial fibrosis	ML	3.00	1.20	0.923
	RLL	3.13	0.99	
	LIG	3.38	0.92	
	LLL	3.13	0.83	
Cysts	ML	2.00	1.20	0.764
	RLL	2.25	1.16	
	LIG	2.13	1.25	
	LLL	2.63	1.19	
Smooth muscle hyperplasia	ML	2.00	1.41	0.979
	RLL	2.13	0.99	
	LIG	2.25	1.04	
	LLL	2.25	0.89	
Myointimal thickening	ML	2.38	1.19	0.604
	RLL	3.13	0.35	
	LIG	2.88	0.83	
	LLL	3.00	0.93	

ML: middle lobe; RLL: right lower lobe; LIG: lingula; and LLL: left lower lobe. \*Kruskal-Wallis test.

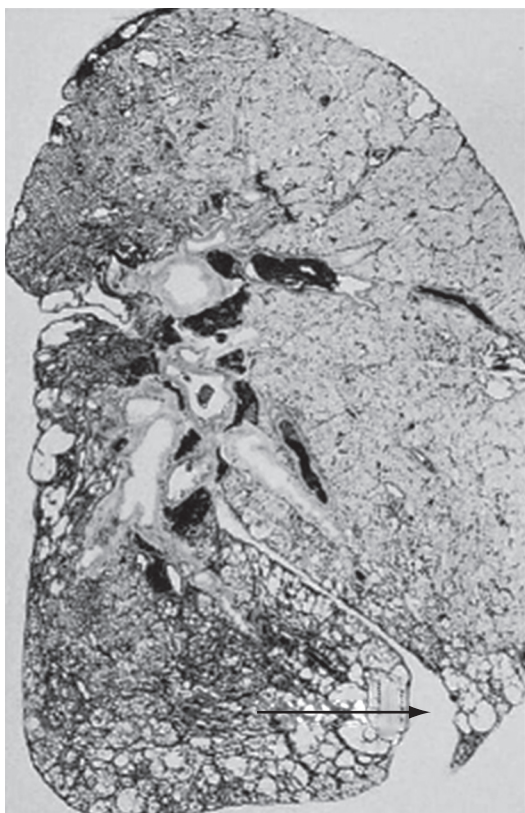
## Discussion

In the literature, there is disagreement regarding the site of choice for surgical lung biopsy. Studies conducted in the 1960s and 1970s<sup>(9,10,12,20,21)</sup> described pathological sequelae, such as fibrosis and vascular alterations, in the lung interstitium in biopsies of the middle lobe and lingular segment. These findings could affect diagnosis and disease staging even in patients



**Figure 1** - HRCT scan of a patient with usual interstitial pneumonia.

without active disease.<sup>(10)</sup> A comparison of the distinct biopsied lung sites was not performed, nor was a histopathological analysis to evaluate the effect of these findings on IPF staging. Nevertheless, certain sites were disregarded as options for biopsy and began to be excluded by specialists in interstitial diseases. Although,



**Figure 2** - Distribution of the disease in the parenchyma.

in subsequent studies,<sup>(13,20,22)</sup> it was stated that there was no unequivocal scientific evidence for this restriction, the prejudice against biopsies of such sites remained.

The semiquantitative technique used in the present study, a technique previously described by Cherniak et al.<sup>(15,16)</sup> and Hyde et al.,<sup>(17)</sup> is widely accepted among pulmonary pathologists, being the only one developed for this purpose that has been validated in multiple centers. The choice of this technique had a negative impact on the study: it limited the study to only the UIP pattern, requiring that the pattern be necessarily that of UIP for the comparison of the two sites studied. This led us to exclude many patients with discordant findings in view of the technical impossibility of assigning this score to other findings, such as nonspecific interstitial pneumonia.

The histological diagnosis of UIP is based on a series of characteristics of distribution of the disease, defining a histopathological pattern.<sup>(23)</sup> The size of the lung tissue specimen is related to the depth of the sample in the lung parenchyma. A lung biopsy should present the peripheral, subpleural region as well as the central or medullary region of the lung. Another recommendation is to obtain a sample of the area of transition between the clearly diseased region seen on HRCT scans and the apparently normal region.<sup>(24)</sup> An excellent evaluation of the entire lung parenchyma is possible using HRCT, which is routine practice in the initial evaluation of interstitial lung diseases.<sup>(25)</sup> Currently, HRCT is used as a routine test in the preoperative period of any surgical lung biopsy (Figure 1). With reasonable accuracy, HRCT allows the selection of ideal sites at distinct stages of the disease in the lung parenchyma to be biopsied.

For most thoracic surgeons, the middle lobe and the lingular segments are anatomically easy to resect, either by mini-thoracotomy or by video-assisted thoracoscopy. In the other lung segments, the collection of samples involving the central and peripheral regions is made difficult by the need to cut an appropriately sized wedge in the parenchyma. In order to obtain a standard sample of this type, the wedge should reach a depth of more than 2 cm, the mean thickness of the peripheral lung region (Figure 2).

The collection of lung tissue from the middle lobe and lingular segment permits samples with

satisfactory volumes to be obtained, and closure typically requires the use of only an endoscopic stapler or a single suture line. The high cost of endoscopic staplers has been a limiting factor for the use of video-assisted thoracoscopy in lung biopsies in our country. An additional advantage described in the literature is the lower incidence of postoperative bronchopleural fistulae after biopsies of the middle lobe or lingular segment.<sup>(26)</sup>

The UIP pattern is quite characteristic, with more severe disease in the subpleural region of the lung, frequently already at more advanced stages of the disease, with areas of honeycombing. Shallow biopsy depth allows only a peripheral representation of the lung parenchyma. In these situations, there is a predominance of chronic alterations that lead the pathologist to define the profile as terminal lung, without histopathological criteria for UIP or any other characteristic pattern that might have led to this situation.

Fibroblastic foci have been reported as an isolated factor for a worse prognosis in IPF.<sup>(2,27,28)</sup> In this study, this finding was significantly more common in the left lower lobes. However, one group of authors, having found no such association, questioned the prognostic value of fibroblastic foci in isolation.<sup>(7)</sup>

In the present study, there was a predominance of males in the group submitted to biopsies on the left side, in which the mean age was also higher, although neither difference was significant. Factors such as age and gender have also been associated with a worse prognosis in IPF,<sup>(18,23)</sup> and these factors could be the cause of this finding.

Currently, the objective is to find a way to quantify the findings in UIP and to stage the interstitial lung disease, based on the lung tissue collected in the biopsy. No matter how representative the parenchyma is in the biopsy, there will always be questions regarding the true stage of the disease.

After the release of the 2002 American Thoracic Society/European Respiratory Society consensus, in which the clinical, pathological and radiological diagnosis is considered a criterion for the diagnosis of UIP, there was a marked reduction in the number of lung biopsies performed. The consensus remains controversial for some researchers, since biopsy can be foregone in only 50% of the patients.<sup>(29)</sup> Nevertheless, at some

health care facilities, the clinical, pathological and radiological diagnosis has been sufficient as the inclusion criterion in clinical studies of IPF. In our opinion, clinical studies should involve patients whose diagnosis was confirmed by surgical biopsy of various lung lobes.

Video-assisted thoracoscopy allows the collection of various satisfactory samples and has lower postoperative morbidity, since it allows earlier hospital discharge at some health care facilities and dispenses with the use of chest tubes in the postoperative period. In the near future, there will be a progressive reduction in the incisions used to access the pleural space in diagnostic procedures and an even greater reduction in hospital stays, since biopsies will be performed on an outpatient basis, as well as a lower rate of chest tube use, contributing to the reduction in morbidity and mortality.<sup>(30)</sup>

In some situations, biopsies of the middle lobe and lingular segment have advantages over biopsies of other sites due to their anatomical characteristics. The volume and depth of a lung biopsy is known to affect the diagnostic yield and the quality of the biopsy in interstitial lung diseases. In this respect, the middle lobe and the lingula provide adequate volume and depth for histological evaluation.

In our sample of patients submitted to surgical biopsy of the middle lobe and lingular segment, there were no alterations that could be specifically attributed to these sites or that could affect disease staging, based on the semiquantitative score used. Therefore, we recommend that the clinical and surgical teams involved in diagnosing the patient evaluate HRCT scans in order to select the biopsy site during the preoperative period. Collecting multiple biopsy samples increases the diagnostic yield and makes it possible to stage the interstitial disease more accurately.

## References

1. Demedts M, Costabel U. ATS/ERS international multidisciplinary consensus classification of the idiopathic interstitial pneumonias. *Eur Respir J*. 2002;19(5):794-6.
2. Tiitto L, Bloigu R, Heiskanen U, Pääkkö P, Kinnula VL, Kaarteenaho-Wiik R. Relationship between histopathological features and the course of idiopathic pulmonary fibrosis/usual interstitial pneumonia. *Thorax*. 2006;61(12):1091-5.
3. Pereira CA, Malheiros T, Coletta EM, Ferreira RG, Rubin AS, Otta JS, et al. Survival in idiopathic pulmonary

- fibrosis-cytotoxic agents compared to corticosteroids. *Respir Med.* 2006;100(2):340-7.
4. Olson AL, Swigris JJ, Lezotte DC, Norris JM, Wilson CG, Brown KK. Mortality from pulmonary fibrosis increased in the United States from 1992 to 2003. *Am J Respir Crit Care Med.* 2007;176(3):277-84.
  5. Fortuna FP, Perin C, Cunha L, Rubin AS. Mortalidade por fibrose pulmonar idiopática no Rio Grande do Sul. *J Pneumol.* 2003;29(3):1-4.
  6. Monaghan H, Wells AU, Colby TV, du Bois RM, Hansell DM, Nicholson AG. Prognostic implications of histologic patterns in multiple surgical lung biopsies from patients with idiopathic interstitial pneumonias. *Chest.* 2004;125(2):522-6.
  7. Hanak V, Ryu JH, de Carvalho E, Limper AH, Hartman TE, Decker PA, et al. Profusion of fibroblast foci in patients with idiopathic pulmonary fibrosis does not predict outcome. *Respir Med.* 2008;102(6):852-6.
  8. Flint A, Martinez FJ, Young ML, Whyte RI, Toews GB, Lynch JP 3rd. Influence of sample number and biopsy site on the histologic diagnosis of diffuse lung disease. *Ann Thorac Surg.* 1995;60(6):1605-7; discussion 1607-8.
  9. Heath D, Whitaker W. Hypertensive pulmonary vascular disease. *Circulation.* 1956;14(3):323-43.
  10. Newman SL, Michel RP, Wang NS. Lingular lung biopsy: is it representative? *Am Rev Respir Dis.* 1985;132(5):1084-6.
  11. Qureshi RA, Stamenkovic SA, Carnochan FM, Walker WS. Video-assisted thoracoscopic lung biopsy in patients with interstitial lung disease. *Ann Thorac Surg.* 2007;84(6):2136-7.
  12. Ray JF 3rd, Lawton BR, Myers WO, Toyama WM, Reyes CN, Emanuel DA, et al. Open pulmonary biopsy. Nineteen-year experience with 416 consecutive operations. *Chest.* 1976;69(1):43-7.
  13. Temes RT, Joste NE, Allen NL, Crowell RE, Dox HA, Wernly JA. The lingula is an appropriate site for lung biopsy. *Ann Thorac Surg.* 2000;69(4):1016-8; discussion 1018-9.
  14. Flaherty KR, King TE Jr, Raghu G, Lynch JP 3rd, Colby TV, Travis WD, et al. Idiopathic interstitial pneumonia: what is the effect of a multidisciplinary approach to diagnosis? *Am J Respir Crit Care Med.* 2004;170(8):904-10.
  15. Cherniack RM, Colby TV, Flint A, Thurlbeck WM, Waldron J, Ackerson L, et al. Quantitative assessment of lung pathology in idiopathic pulmonary fibrosis. The BAL Cooperative Group Steering Committee. *Am Rev Respir Dis.* 1991;144(4):892-900.
  16. Cherniack RM, Colby TV, Flint A, Thurlbeck WM, Waldron JA Jr, Ackerson L, et al. Correlation of structure and function in idiopathic pulmonary fibrosis. *Am J Respir Crit Care Med.* 1995;151(4):1180-8.
  17. Hyde DM, King TE Jr, McDermott T, Waldron JA Jr, Colby TV, Thurlbeck WM, et al. Idiopathic pulmonary fibrosis. Quantitative assessment of lung pathology. Comparison of a semiquantitative and a morphometric histopathologic scoring system. *Am Rev Respir Dis.* 1992;146(4):1042-7.
  18. Canzian M, de Matos Soeiro A, de Lima Taga MF, Farhat C, Barbas CS, Capelozzi VL. Semiquantitative assessment of surgical lung biopsy: predictive value and impact on survival of patients with diffuse pulmonary infiltrate. *Clinics (Sao Paulo).* 2007;62(1):23-30.
  19. Ferreira RG, Colleta EM, Giannotti Filho O. Avaliação de parâmetros histológicos na pneumonia intersticial usual (fibrose pulmonar idiopática) *J Pneumol.* 2000;26(6):279-85.
  20. Miller JI Jr. The present role and future considerations of video-assisted thoracoscopy in general thoracic surgery. *Ann Thorac Surg.* 1993;56(3):804-6.
  21. Wetstein L. Sensitivity and specificity of lingular segmental biopsies of the lung. *Chest.* 1986;90(3):383-6.
  22. Chechani V, Landreneau RJ, Shaikh SS. Open lung biopsy for diffuse infiltrative lung disease. *Ann Thorac Surg.* 1992;54(2):296-300.
  23. Dempsey OJ. Clinical review: idiopathic pulmonary fibrosis--past, present and future. *Respir Med.* 2006;100(11):1871-85.
  24. Flaherty KR, Travis WD, Colby TV, Toews GB, Kazerooni EA, Gross BH, et al. Histopathologic variability in usual and nonspecific interstitial pneumonias. *Am J Respir Crit Care Med.* 2001;164(9):1722-7.
  25. Hunninghake GW, Lynch DA, Galvin JR, Gross BH, Müller N, Schwartz DA, et al. Radiologic findings are strongly associated with a pathologic diagnosis of usual interstitial pneumonia. *Chest.* 2003;124(4):1215-23.
  26. Miller RR, Nelems B, Müller NL, Evans KG, Ostrow DN. Lingular and right middle lobe biopsy in the assessment of diffuse lung disease. *Ann Thorac Surg.* 1987;44(3):269-73.
  27. Enomoto N, Suda T, Kato M, Kaida Y, Nakamura Y, Imokawa S, et al. Quantitative analysis of fibroblastic foci in usual interstitial pneumonia. *Chest.* 2006;130(1):22-9.
  28. Coletta EN, Pereira CA, Ferreira RG, Rubin AS, Villela LS, Malheiros T, et al. Achados histológicos e sobrevida na fibrose pulmonar idiopática. *J Pneumol.* 2003;29(6):371-8.
  29. Churg A, Schwarz M. Transbronchial biopsy and usual interstitial pneumonia: a new paradigm? *Chest.* 2006;129(5):1117-8.
  30. Luckraz H, Rammohan KS, Phillips M, Abel R, Karthikeyan S, Kulatilake NE, et al. Is an intercostal chest drain necessary after video-assisted thoracoscopic (VATS) lung biopsy? *Ann Thorac Surg.* 2007;84(1):237-9.

## ***About the authors***

---

### ***José Júlio Saraiva Gonçalves***

Professor. *Universidade para o Desenvolvimento do Estado e da Região do Pantanal* – UNIDERP, University for the Development of the State and Region of the Pantanal – School of Medicine, Campo Grande, Brazil.

### ***Luiz Eduardo Villaça Leão***

Full Professor. Department of Thoracic Surgery, *Universidade Federal de São Paulo/Escola Paulista de Medicina* – UNIFESP/EPM, Federal University of São Paulo/Paulista School of Medicine – São Paulo, Brazil.

### ***Rimarcs Gomes Ferreira***

Adjunct Professor. Department of Pathology, *Universidade Federal de São Paulo/Escola Paulista de Medicina* – UNIFESP/EPM, Federal University of São Paulo/Paulista School of Medicine – São Paulo, Brazil.

### ***Renato Oliveira***

Attending Thoracic Surgeon. Department of Thoracic Surgery, *Universidade Federal de São Paulo/Escola Paulista de Medicina* – UNIFESP/EPM, Federal University of São Paulo/Paulista School of Medicine – São Paulo, Brazil.

### ***Luiz Hirotoshi Ota***

Adjunct Professor. Department of Thoracic Surgery, *Universidade Federal de São Paulo/Escola Paulista de Medicina* – UNIFESP/EPM, Federal University of São Paulo/Paulista School of Medicine – São Paulo, Brazil.

### ***Ricardo Sales dos Santos***

Instructor in Cardiothoracic Surgery. Boston University School of Medicine, Boston, MA, USA.