

Effects of expiratory positive airway pressure on the electromyographic activity of accessory inspiratory muscles in COPD patients*

Efeitos da pressão positiva expiratória nas vias aéreas sobre a atividade eletromiográfica da musculatura acessória da inspiração em portadores de DPOC

Dannuey Machado Cardoso, Dulciane Nunes Paiva,
Isabella Martins de Albuquerque, Renan Trevisan Jost,
Andréia Vanessa da Paixão

Abstract

Objective: To evaluate the electromyographic activity (EA) of sternocleidomastoid (SCM) and scalene muscles during and after the use of expiratory positive airway pressure (EPAP) in patients with COPD. **Methods:** This was a clinical single-blind trial involving 13 healthy subjects as controls and 12 patients with stable COPD. At baseline, we determined EA during spontaneous respiration, lung function parameters, and respiratory muscle strength. Subsequently, EPAP at 15 cmH₂O was applied by means of a face mask for 25 min, during which the EA of the SCM and scalene muscles was recorded every 5 min. A final record was obtained 10 min after the mask removal. **Results:** We found that the behavior of the EA of SCM and scalene muscles was comparable between the controls and the COPD patients ($p = 0.716$ and $p = 0.789$, respectively). However, during the use of EPAP, both muscles showed a trend toward an increase in the EA. In addition, there was a significant decrease in the EA of the SCM between the baseline and final measurements ($p = 0.034$). **Conclusions:** The use of EPAP promoted a significant reduction in the EA of the SCM in the controls and in the patients with stable COPD. However, this did not occur regarding the EA of the scalene muscle.

Keywords: Electromyography; Respiratory muscles; Pulmonary disease, chronic obstructive; Positive-pressure respiration.

Resumo

Objetivo: Avaliar a atividade eletromiográfica (AE) dos músculos esternocleidomastoideo (ECM) e escaleno durante e após a aplicação de *expiratory positive airway pressure* (EPAP, pressão positiva expiratória nas vias aéreas) em portadores de DPOC. **Métodos:** Ensaio clínico simples cego com 13 indivíduos hígidos como controles e 12 pacientes com DPOC estável. No momento basal, foram determinados a AE em respiração espontânea, parâmetros da função pulmonar e a força muscular respiratória. Posteriormente, foi aplicada EPAP de 15 cmH₂O com uma máscara facial durante 25 min, com o registro do sinal eletromiográfico dos músculos ECM e escaleno a cada 5 min. Um último registro foi obtido 10 min após a retirada da máscara. **Resultados:** Observamos que o comportamento da AE dos músculos ECM e escaleno foi semelhante nos controles e pacientes com DPOC ($p = 0,716$ e $p = 0,789$, respectivamente). Porém, ao longo da aplicação de EPAP, ambos os músculos mostraram uma tendência ao aumento da AE. Além disso, houve uma redução significativa da AE do ECM entre o momento final e basal ($p = 0,034$). **Conclusões:** A aplicação de EPAP promoveu uma redução significativa da AE do músculo ECM tanto nos controles quanto nos portadores de DPOC estável. Porém, isso não ocorreu em relação à AE do músculo escaleno.

Descritores: Eletromiografia; Músculos respiratórios; Doença pulmonar obstrutiva crônica; Respiração com pressão positiva.

* Study carried out at the *Universidade de Santa Cruz do Sul* – UNISC, University of Santa Cruz do Sul – Santa Cruz do Sul, Brazil. Correspondence to: Dannuey Machado Cardoso. Rua Adriana Pereira Druck, 149, Farol, CEP 96690-000, Pântano Grande, RS, Brasil. Tel 55 51 3734-1204. E-mail: dannuey@yahoo.com.br
Financial support: None.
Submitted: 14 December 2009. Accepted, after review: 13 October 2010.

Introduction

The chronic airflow obstruction seen in individuals with COPD is accompanied by altered respiratory mechanics, leading to reduced aerobic capacity of the peripheral muscles, which results in reduced lung elastic recoil, increased lung compliance, and a change in the ventilation/perfusion ratio.^(1,2) As a result of these changes, there is increased physiological dead space, dynamic hyperinflation with flattening of the diaphragm, and inefficient respiratory biomechanics, causing increased energy expenditure.^(3,4)

Dynamic hyperinflation is the major cause of exercise limitation in patients with COPD, resulting in an increase in the inspiratory muscle effort required to produce a pressure that can overcome the threshold load of intrinsic positive end-expiratory pressure (PEEPi).⁽⁵⁾ The increase in inspiratory muscle effort occurs due to increased activation of the scalene muscle and to recruitment of accessory respiratory muscles, such as the sternocleidomastoid (SCM) muscle.⁽⁶⁾ These muscles are responsible for the cranial displacement of the sternum and rib cage during inhalation, although they are activated at different time points: the scalene is activated during the inhalation phase, even at rest, whereas the SCM muscle is recruited only after approximately 70% of tidal volume (V_T) has been reached, or when there is a hypercapnia- or hyperpnea-induced increase in inspiratory capacity,^(7,8) or at approximately 35% of MIP during an inspiratory effort from functional residual capacity in healthy subjects.⁽⁹⁾

Many authors have studied the effects of using expiratory positive airway pressure (EPAP) in patients with COPD,^(10,11) especially in terms of assistance in the removal of pulmonary secretions.^(12,13) In patients with COPD, the increase in resistance in the expiratory phase causes a decrease in minute volume, V_T , RR, and physiological dead space, as well as potentially improving the length-tension ratio of the respiratory muscles, thereby making them more efficient.^(13,14) However, other authors suggest that the use of EPAP in patients with moderate to severe airway obstruction, at rest or during exercise, is responsible for the increased sensation of dyspnea.⁽¹¹⁾

In a study employing a canine model of methacholine-induced bronchospasm, animals

were submitted to 10 cmH₂O of inspiratory positive airway pressure, EPAP, or continuous positive airway pressure.⁽¹⁵⁾ The authors found EPAP to be the only pressure mode that increased respiratory effort. In contrast, one of the major clinical applications of EPAP is the displacement of secretions in patients with COPD, promoting the important physiological effect of reducing the mechanism of pulmonary hyperinflation in these patients. Therefore, theoretically, during the use of EPAP in patients with COPD, the possible increase in respiratory effort could affect the inspiratory muscles. The objective of the present study was to evaluate the electromyographic activity of the SCM and scalene muscles during and after the use of EPAP in patients with COPD.

Methods

This was a single-blind clinical trial involving patients with COPD and healthy subjects, all between 40 and 70 years of age. The study sample comprised patients clinically diagnosed with COPD and classified as having stage II or III disease, based on the Global Initiative for Chronic Obstructive Lung Disease classification. In addition, these patients should be enrolled in a pulmonary rehabilitation program and should be clinically stable, as determined by a physician. The healthy subjects included were nonsmokers and had normal pulmonary function. The COPD patients with hemodynamic instability or clinical signs of acute exacerbation were excluded, as were those with an artificial airway and those who did not tolerate the EPAP mask. Regarding the healthy subjects, those with respiratory symptoms 30 days prior to inclusion in the study were excluded, as were those with chronic lung disease, those with claustrophobia, and those with hemodynamic instability.

The present study was approved by the Research Ethics Committee of the University of Santa Cruz do Sul, and all participants gave written informed consent.

The study was conducted in two phases. In the first phase, anthropometry, respiratory muscle strength, and pulmonary function were assessed. In the second phase, during the use of EPAP, V_T , RR, SpO₂, and the electromyographic activity were measured over 25 min. Two investigators, who were blinded to the outcome of the study, were responsible for the interventions.

The V_T was measured with a spirometer (Mark 8; Ferraris Medical Ltd., Middlesex, England), and SpO_2 was measured with an oximeter (Nonin Medical, Plymouth, MN, USA). In addition, RR (breaths/min) was determined. These variables were initially measured with the subjects breathing spontaneously, that is, prior to the use of EPAP, and at during the final minute of EPAP.

The electromyographic signal was initially recorded with the subjects breathing spontaneously (pre-EPAP), in a sitting position and at rest, with the cervical region and upper limbs in a neutral position. The subjects were instructed not to move those segments during signal recording.

For the recording of the electromyographic signal (EMGs), the area was shaved and the surface of the muscle of interest was disinfected with an alcohol swab in order to remove dead cells and reduce skin resistance to the EMGs passing through it. Surface circular electrodes with a bipolar configuration and a radius of 15 mm (Meditrace 100 Ag/AgCl pediatric electrodes; Tyco Healthcare Group Canada Inc, Pointe Claire, QC, Canada) were positioned with conductive adhesive solid gel (Tyco Healthcare Group Canada Inc), pre-amplified, and connected to a surface differential sensor (model SDS500; Miotec Equipamentos Biomédicos Ltda., Porto Alegre, Brazil). The center of each electrode was 30 mm from that of its neighbor. The level of resistance between the electrodes was measured, before each session, with a digital multimeter (model UT30B; UNIT, Guangzhou, China) and was regulated to remain below 3,000 ohms.⁽¹⁶⁾ As can be seen in Figure 1, a pair of surface electrodes were put into place, one over the SCM muscles (3 cm above the anterior muscle head and in both posterior triangles of the neck, at the level of the cricoid cartilage) and one over the lower portions of the anterior scalene muscles. This location was determined by palpating the lower third of a line drawn between the middle of the mastoid process and the middle of the sternal notch.⁽¹⁷⁾

For a total of 25 min, we applied EPAP using a flexible face mask (RHDSO; Vital Signs, Totowa, NJ, USA) with a head strap, which made it possible to minimize air leaks. The expiratory port of the mask was connected to a positive pressure generating system containing a

unidirectional valve and an expiratory resistance device, known as a spring-loaded valve (Vital Signs), and the level was set to 5 cmH_2O for the first 5 min (to allow adaptation), after which it was increased to 15 cmH_2O . A digital vacuum manometer (model MVD300; GlobalMed, Porto Alegre, Brazil) was connected to the EPAP mask in order to measure the mask pressure level and ensure that it did not exceed 15 cmH_2O .

Pulmonary function was measured with a portable spirometer (EasyOne® Model 2001; Diagnostic Spirometer, Zurich, Switzerland), and the protocol used was that recommended by the American Thoracic Society in 2005.⁽¹⁸⁾ We analyzed FVC, FEV_1 , FEV_1/FVC , and PEF. The curve with the best performance was compared with the values predicted in the literature,⁽¹⁹⁾ and the results are therefore expressed as percentage of predicted.

Respiratory muscle strength (MIP and MEP) was measured with a digital vacuum manometer (model MVD300; GlobalMed) with the subjects in a sitting position.⁽²⁰⁾ The MIP was obtained with the subjects inhaling from RV to TLC, whereas the MEP was obtained with a forced

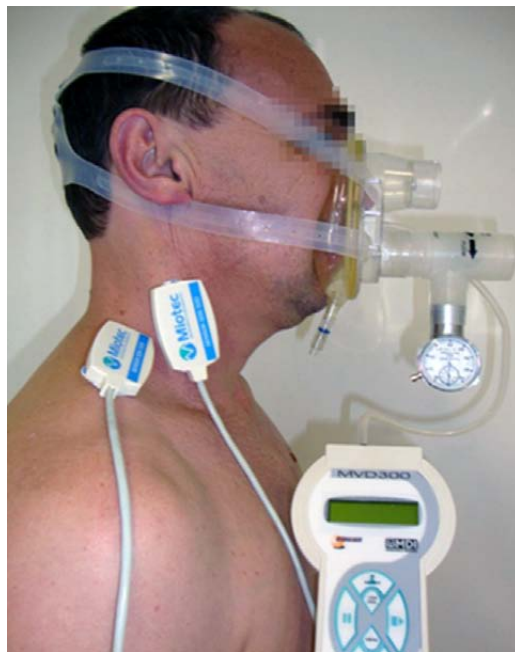

Figure 1 – Use of expiratory positive airway pressure (EPAP) in a volunteer. During the use of EPAP, the electromyographic activity of the sternocleidomastoid and scalene muscles was recorded simultaneously with tidal volume and mask pressure (with a vacuum manometer).

expiratory maneuver from TLC to RV against the occluded valve. For data analysis, we considered the highest value obtained in the five maneuvers performed, provided that it did not differ by more than 10% in relation to the second highest value in decreasing order. These values were compared with those reported in the literature⁽²¹⁾ and are expressed as percentage of predicted.

Electromyographic data acquisition involved a surface electromyograph (Miotool 400; Miotec, Porto Alegre, Brazil) consisting of a four-channel system, with a sampling frequency of 2,000 Hz per channel. Signal acquisition was performed before EPAP (pre-EPAP), every 5 min during EPAP (totaling 5 acquisitions), and 10 min after EPAP (post-EPAP). The curve corresponding to the electromyographic signal of the inspiratory phase was obtained by monitoring mask pressure with the MVD300 program (GlobalMed) from 1 s before the absence of pressure was detected to 1 s after pressure reached 15 cmH₂O,⁽²²⁾ and the root mean square (RMS) value was obtained. Subsequently, the data were transmitted to a laptop via USB port connection. These findings were exported to the SAD 32 program (Laboratório de Medições Mecânicas da Universidade Federal do Rio Grande do Sul, Porto Alegre, Brazil) for digital filtering with fifth order Butterworth bandpass filters at cut-off frequencies between 25 and 500 Hz.⁽²³⁾ The procedures for EMGs capture were those recommended by the International Society of Electrophysiology and Kinesiology.⁽²⁴⁾ Electromyographic activity during breathing at rest and during the use of EPAP is expressed as a percentage of RMS (%RMS), the values being normalized through the maximal voluntary isovolumetric contraction obtained during the measurement of MIP.

The Statistical Package for the Social Sciences, version 18.0 (SPSS Inc., Chicago, IL, USA) was used for analysis the results, which are expressed as mean and standard deviation and were evaluated for normality by the Shapiro-Wilk test. Data on age, BMI, pulmonary function, and respiratory muscle strength were assessed for heterogeneity by the F-test and were compared between groups by the Student's t-test for independent samples. To compare the V_T , RR, and SpO₂ values obtained before the use of EPAP with those obtained at 25 min of EPAP within each group, as well as to

compare the EMGs between the left and right segments, the paired Student's t-test was used. The chi-square test was used for comparing the gender proportions between the groups. For the analysis of the EMGs, data were converted into natural logarithms, this conversion being performed only to obtain relative data symmetry, and two-way repeated measures ANOVA with Greenhouse-Geisser correction was then used. For the comparison between the pre-EPAP and post-EPAP time points in terms of the EMGs of the SCM muscle, the paired Student's t-test was used. The level of statistical significance was set at $p < 0.05$.

Results

The sample comprised 25 participants, of whom 13 were healthy subjects (control group) and 12 were COPD patients (COPD group). There was a homogeneous distribution of participants in terms of gender, mean age, and respiratory muscle strength, represented by MIP and MEP. There were differences between the groups in terms of BMI (there were overweight subjects in the control group) and pulmonary function (all analyzed variables were reduced in the COPD group, which shows the losses caused by the disease; Table 1). Respiratory muscle strength was not significantly different between the groups, suggesting that COPD patients can maintain the pressures generated by the inspiratory and expiratory muscles. Despite the lack of statistical significance, which was probably due to the sample size, it is important to emphasize that there was a significant decrease in MIP in the COPD group (Table 1).

In the control group, the use of EPAP resulted in a significant increase in V_T (pre-EPAP vs. post-EPAP: 642.2 ± 344.4 mL vs. $1,540.5 \pm 702.5$ mL; $p = 0.002$) and in SpO₂ ($96.5 \pm 1.3\%$ vs. $98.4 \pm 0.8\%$; $p < 0.001$), as well as a significant decrease in RR (pre-EPAP vs. post-EPAP: 17.4 ± 4.6 breaths/min vs. 10.5 ± 4.7 breaths/min; $p = 0.002$). In the COPD group, there was an increase in SpO₂ (pre-EPAP vs. post-EPAP: $93.6 \pm 5.1\%$ vs. $95.4 \pm 3.2\%$; $p = 0.038$); and a decrease in RR (pre-EPAP vs. post-EPAP: 18.3 ± 4.1 breaths/min vs. 11.6 ± 3.8 breaths/min; $p < 0.001$), although there was no significant increase in V_T (pre-EPAP vs. post-EPAP: 470.4 ± 272.9 mL vs. 526.8 ± 267.4 mL; $p = 0.574$).

Table 1 – Baseline characteristics of the two study groups.^a

Characteristic	Control group	COPD group	p
	(n = 13)	(n = 12)	
Male gender, n (%)	7 (53.8)	4 (33.3)	0.302
Age, years	57.1 ± 7.1	57.2 ± 8.3	0.997
BMI, kg/m ²	27.1 ± 3.0	22.5 ± 5.9	0.020
Pulmonary function			
FVC, % of predicted	87.8 ± 9.6	63.7 ± 19.5	0.001
FEV ₁ , % of predicted	86.8 ± 14.3	44.0 ± 20.0	< 0.001
FEV ₁ /FVC, % of predicted	99.0 ± 9.3	66.8 ± 17.4	< 0.001
PEF, % of predicted	79.0 ± 35.4	40.7 ± 21.8	0.004
FEF ₂₅₀₋₇₅₀ , % of predicted	90.6 ± 31.5	23.3 ± 14.9	< 0.001
Respiratory muscle strength			
MIP, % of predicted	94.8 ± 26.2	77.7 ± 39.9	0.224
MEP, % of predicted	100.5 ± 31.7	98.8 ± 31.8	0.897

^aValues expressed as mean ± SD, except where otherwise indicated.

Regarding the electromyographic activity of the muscles studied, we initially observed that there were no significant differences between the right and left segments of the two muscles in terms of muscle activity, and, for this reason, we adopted the mean of the two segments. As can be seen in Figure 2, the electromyographic activity of the SCM muscle showed a significant difference between the time points ($p = 0.034$), although not between the groups ($p = 0.716$). Therefore, considering the sample as a whole ($n = 25$), we found a significant decrease between the pre- and post-EPAP measurements in terms of the EMGs of the SCM muscle ($16.7 \pm 11.0\%RMS$ vs. $12.5 \pm 10.4\%RMS$; $p = 0.006$; Figure 3). In contrast, as shown in Figure 4, there were no significant differences in terms of the EMGs of the scalene muscle, either between the groups ($p = 0.789$) or over time ($p = 0.195$).

Discussion

Our results suggest that, after EPAP at 15 cmH₂O is applied with a face mask for 25 min, there is a significant decrease in the electromyographic activity of the SCM muscle in healthy subjects and in patients with COPD. However, it is important to emphasize that this was not found to occur in the scalene muscle.

In contrast to what was expected, inspiratory muscle strength in the COPD group was not shown to be decreased in comparison with that in the control group, although clinical significance was demonstrated, because there was an overall decrease in respiratory muscle strength in the

COPD group, especially in MIP. As has been previously reported, the loss of respiratory muscle strength in patients with COPD is mainly due to the development of lung hyperinflation, which could result in these muscles being at a significant mechanical disadvantage, causing geometric changes to the thorax and diaphragm, as well as depression of the hemidiaphragm and shortening of its fibers, forcing it to operate in an unfavorable portion of the length-tension curve,^(25,26) in addition to increasing the demand on these muscles in an attempt to overcome the threshold load of PEEPi.⁽⁵⁾ Therefore, in patients with COPD, there is additional recruitment of

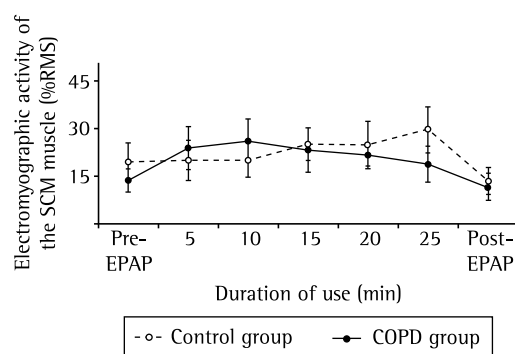


Figure 2 – Electromyographic activity of the sternocleidomastoid (SCM) muscle, in % root mean square (%RMS), with the participants in the control and COPD groups under expiratory positive airway pressure (EPAP) and breathing spontaneously: at the baseline measurement (pre-EPAP); during the use of EPAP, applied by means of a face mask (at 5, 10, 15, 20, and 25 min); and at the final measurement (post-EPAP).

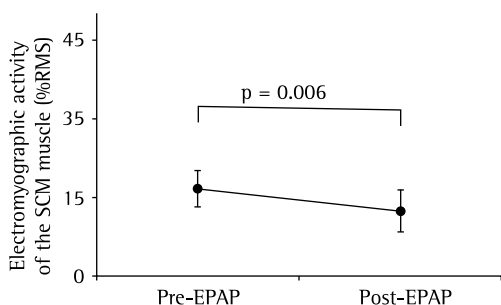


Figure 3 – Effect of expiratory positive airway pressure (EPAP), in % root mean square (%RMS), on the electromyographic activity of the sternocleidomastoid (SCM) muscle from the baseline measurement (pre-EPAP) to after the removal of the mask (post-EPAP) in the sample as a whole ($p = 0.006$).

the accessory inspiratory muscles, especially the SCM muscle, in an attempt to maintain adequate pulmonary filling pressures.⁽⁶⁾

We speculate that, during the use of EPAP, there was an increase in the electromyographic activity of the muscles studied in both groups, which might have been caused by the increase in respiratory effort. This finding might be due to the fact that the use of EPAP produces an increase in pleural and transdiaphragmatic pressures.⁽¹⁵⁾ With regard to the presence of increased electromyographic activity in the SCM muscle, it has been suggested that this muscle becomes more active during maximal lung inflation, which produces a marked displacement

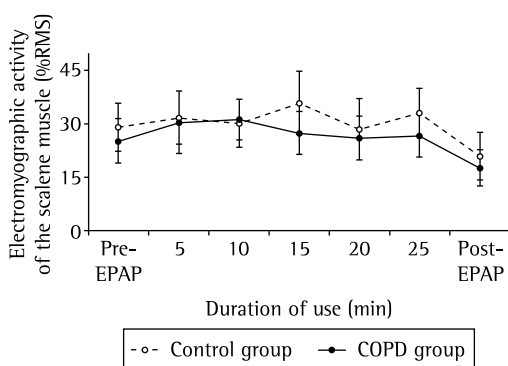


Figure 4 – Electromyographic activity of the scalene muscle, in % root mean square (%RMS), with the participants in the control and COPD groups under expiratory positive airway pressure (EPAP) and breathing spontaneously: at the baseline measurement (pre-EPAP); during the use of EPAP, applied by means of a face mask (at 5, 10, 15, 20, and 25 min); and at the final measurement (post-EPAP).

of the rib cage in the cranial direction.⁽²⁷⁾ When positive pressure is applied, this increased muscle activity occurs in an attempt to maintain adequate inspiratory pressure.⁽²⁸⁾ The recruitment of accessory inspiratory muscles during the use of EPAP prolongs expiratory time, which favors lung deflation and consequently reduces RR, as has also been observed in patients with obstructive sleep apnea syndrome.⁽²⁷⁾

In contrast to what was expected, the electromyographic activity of the scalene muscle showed no significant changes with the use of EPAP, although there was an apparent increase during the its use and a trend toward a decrease after its withdrawal. This finding is in accordance with the result of a study, in which, with the aim of evaluating the behavior of the scalene muscle in healthy individuals who received a PEEP of 5 or 15 cmH₂O, it was demonstrated that, during the use of the two pressure levels, the phasic activity of the respiratory muscles increased and that, after the pressure support was withdrawn, the levels of electromyographic activity returned to those observed before the intervention.⁽²⁸⁾ The authors of that study attributed the increase in inspiratory muscle effort to the imposition of a pressure gradient in the expiratory phase, which required greater inspiratory muscle effort in an attempt to minimize the pressure difference between the inspiratory and expiratory phases.⁽²⁸⁾ The same authors conducted a study of patients with COPD who received an EPAP of 5 cmH₂O at rest and during exercise.⁽¹¹⁾ They found that the electromyographic activity of the inspiratory muscles, including the scalene muscles, was greater during exercise than that at rest, contributing to the increased sensation of dyspnea during exercise. However, they could not explain the increased sensation of dyspnea and suggested only that the use of EPAP improves the efficiency of ventilation at rest, making respiratory mechanics more efficient and requiring less respiratory effort.⁽¹¹⁾

Another relevant finding of the present study was the significant increase in V_T with the use of EPAP in the control group, which did not occur in the COPD group. This can be explained by the fact that minute ventilation is known to depend on airway resistance, lung compliance, and respiratory muscle efficiency.⁽³⁾ Therefore, the fact that COPD causes destruction of the elastic tissue, with a consequent loss of the

elastic recoil of the lung and rib cage, and increased airway resistance due to accumulation of secretion, together with the significant impairment of respiratory biomechanics caused by lung hyperinflation, might have been responsible for the inability of the respiratory system to increase V_T during the use of EPAP in the COPD group.^(1,2) The present study has certain limitations that merit discussion. The small sample size might have been responsible for the fact that no significant difference in respiratory muscle strength was found between the control and COPD groups. In our study, we did not evaluate the behavior of end-expiratory lung volume, since the use of a PEEP greater than 10 cmH₂O is known to cause a significant increase in lung volume,⁽²⁹⁾ which could result in lung hyperinflation and affect respiratory muscle activity. In addition, a pressure level greater than 10 cmH₂O can cause an increase in the number of emphysematous areas throughout the lung.⁽³⁰⁾ However, the use of lower pressure levels could be sufficient to reduce the electromyographic activity without causing these adverse effects.

In conclusion, our study showed that the use of an EPAP of 15 cmH₂O, applied with a face mask, promoted, after its withdrawal, a decrease in the electromyographic activity of the SCM muscle in healthy subjects and in patients with COPD. However, this did not occur regarding the electromyographic activity of the scalene muscle. This benefit should be considered when this pressure mode is recommended for patients with COPD, because there is usually an increase in the activity of the accessory inspiratory muscles in such patients.

References

- Georgiadou O, Vogiatzis I, Stratakos G, Koutsoukou A, Golemati S, Aliverti A, et al. Effects of rehabilitation on chest wall volume regulation during exercise in COPD patients. *Eur Respir J*. 2007;29(2):284-91.
- Hodge S, Hodge G, Ahern J, Jersmann H, Holmes M, Reynolds PN. Smoking alters alveolar macrophage recognition and phagocytic ability: implications in chronic obstructive pulmonary disease. *Am J Respir Cell Mol Biol*. 2007;37(6):748-55.
- Jones AY, Dean E, Chow CC. Comparison of the oxygen cost of breathing exercises and spontaneous breathing in patients with stable chronic obstructive pulmonary disease. *Phys Ther*. 2003;83(5):424-31.
- Albuquerque AL, Nery LE, Villaça DS, Machado TY, Oliveira CC, Paes AT, et al. Inspiratory fraction and exercise impairment in COPD patients GOLD stages II-III. *Eur Respir J*. 2006;28(5):939-44.
- Yan S, Kaminski D, Sliwinski P. Inspiratory muscle mechanics of patients with chronic obstructive pulmonary disease during incremental exercise. *Am J Respir Crit Care Med*. 1997;156(3 Pt 1):807-13.
- Hudson AL, Gandevia SC, Butler JE. The effect of lung volume on the co-ordinated recruitment of scalene and sternomastoid muscles in humans. *J Physiol*. 2007;584(Pt 1):261-70.
- Campbell EJ. The role of the scalene and sternomastoid muscles in breathing in normal subjects; an electromyographic study. *J Anat*. 1955;89(3):378-86.
- Raper AJ, Thompson WT Jr, Shapiro W, Patterson JL Jr. Scalene and sternomastoid muscle function. *J Appl Physiol*. 1966;21(2):497-502.
- Yokoba M, Abe T, Katagiri M, Tomita T, Easton PA. Respiratory muscle electromyogram and mouth pressure during isometric contraction. *Respir Physiol Neurobiol*. 2003;137(1):51-60.
- Lien TC, Wang JH, Chang MT, Kuo CD. Comparison of BiPAP nasal ventilation and ventilation via iron lung in severe stable COPD. *Chest*. 1993;104(2):460-6.
- van der Schans CP, de Jong W, de Vries G, Kaan WA, Postma DS, Koëter GH, et al. Effects of positive expiratory pressure breathing during exercise in patients with COPD. *Chest*. 1994;105(3):782-9.
- Holland AE, Button BM. Is there a role for airway clearance techniques in chronic obstructive pulmonary disease? *Chron Respir Dis*. 2006;3(2):83-91.
- Su CL, Chiang LL, Chiang TY, Yu CT, Kuo HP, Lin HC. Domiciliary positive expiratory pressure improves pulmonary function and exercise capacity in patients with chronic obstructive pulmonary disease. *J Formos Med Assoc*. 2007;106(3):204-11.
- McCool FD, Rosen MJ. Nonpharmacologic airway clearance therapies: ACCP evidence-based clinical practice guidelines. *Chest*. 2006;129(1 Suppl):250S-259S.
- Miro AM, Pinsky MR, Rogers PL. Effects of the components of positive airway pressure on work of breathing during bronchospasm. *Crit Care*. 2004;8(2):R72-81.
- Narici MV, Roi GS, Landoni L, Minetti AE, Cerretelli P. Changes in force, cross-sectional area and neural activation during strength training and detraining of the human quadriceps. *Eur J Appl Physiol Occup Physiol*. 1989;59(4):310-9.
- Chiti L, Biondi G, Morelot-Panzini C, Raux M, Similowski T, Hug F. Scalene muscle activity during progressive inspiratory loading under pressure support ventilation in normal humans. *Respir Physiol Neurobiol*. 2008;164(3):441-8.
- Miller MR, Hankinson J, Brusasco V, Burgos F, Casaburi R, Coates A, et al. Standardisation of spirometry. *Eur Respir J*. 2005;26(2):319-38.
- Pereira CA, Barreto SP, Simões JG, Pereira FW, Gerstler JG, Nakatani J. Valores de referência para a espirometria em uma amostra da população brasileira adulta. *J Pneumol*. 1992;18(1):10-22.
- American Thoracic Society/European Respiratory Society. ATS/ERS Statement on respiratory muscle testing. *Am J Respir Crit Care Med*. 2002;166(4):518-624.
- Neder JA, Andreoni S, Lerario MC, Nery LE. Reference values for lung function tests. II. Maximal respiratory pressures and voluntary ventilation. *Braz J Med Biol Res*. 1999;32(6):719-27.

22. Hug F, Raux M, Prella M, Morelot-Panzini C, Straus C, Similowski T. Optimized analysis of surface electromyograms of the scalenes during quiet breathing in humans. *Respir Physiol Neurobiol.* 2006;150(1):75-81.
23. De Luca CJ. The Use of Surface Electromyography in Biomechanics. *J Appl Biomech.* 1997;13(2):135-63.
24. Williams KR. Standardizing biomechanical testing in sport. *Res Quart Exercise Sport.* 1987;58:286-7.
25. Weiner P, Magadle R, Beckerman M, Weiner M, Berar-Yanay N. Comparison of specific expiratory, inspiratory, and combined muscle training programs in COPD. *Chest.* 2003;124(4):1357-64.
26. Luce JM, Culver BH. Respiratory muscle function in health and disease. *Chest.* 1982;81(1):82-90.
27. Legrand A, Schneider E, Gevenois PA, De Troyer A. Respiratory effects of the scalene and sternomastoid muscles in humans. *J Appl Physiol.* 2003;94(4):1467-72.
28. van der Schans CP, de Jong W, de Vries G, Postma DS, Koëter GH, van der Mark TW. Effect of positive expiratory pressure on breathing pattern in healthy subjects. *Eur Respir J.* 1993;6(1):60-6.
29. O'Donoghue FJ, Catcheside PG, Jordan AS, Bersten AD, McEvoy RD. Effect of CPAP on intrinsic PEEP, inspiratory effort, and lung volume in severe stable COPD. *Thorax.* 2002;57(6):533-9.
30. Holanda MA, Fortaleza SC, Alves-de-Almeida M, Winkeler GF, Reis RC, Felix JH, et al. Continuous positive airway pressure effects on regional lung aeration in patients with COPD: a high-resolution CT scan study. *Chest.* 2010;138(2):305-14.

About the authors

Dannuey Machado Cardoso

Physiotherapist. Graduate Student in Medicine, *Universidade Federal do Rio Grande do Sul* – UFRGS, Federal University of Rio Grande do Sul – Porto Alegre, Brazil.

Dulciane Nunes Paiva

Adjunct Professor. *Universidade de Santa Cruz do Sul* – UNISC, University of Santa Cruz do Sul – School of Physiotherapy, Santa Cruz do Sul, Brazil.

Isabella Martins de Albuquerque

Assistant Professor. *Universidade de Santa Cruz do Sul* – UNISC, University of Santa Cruz do Sul – School of Physiotherapy, Santa Cruz do Sul, Brazil.

Renan Trevisan Jost

Physiotherapy Student. *Universidade de Santa Cruz do Sul* – UNISC, University of Santa Cruz do Sul – School of Physiotherapy, Santa Cruz do Sul, Brazil.

Andréia Vanessa da Paixão

Physiotherapist. *Universidade de Santa Cruz do Sul* – UNISC, University of Santa Cruz do Sul – School of Physiotherapy, Santa Cruz do Sul, Brazil.