


Sexually Transmitted Infections Lesions Found during Colonoscopies

Alexandre Gomes¹  João Batista Sampaio Netto¹ Ricardo de Oliveira Ayres¹
José Mauro da Silva Rodrigues¹ Ronaldo Antonio Borghesi¹

¹ Surgical Clinic, Faculty of Medical and Biological Sciences, Pontifical Catholic University of São Paulo (FCMS/PUC-SP) Sorocaba, São Paulo, Brazil

Address for correspondence Alexandre Gomes, Ph.D, M.Sc, MD, Surgical Clinic, Faculty of Medical and Biological Sciences, Pontifical Catholic University of São Paulo (FCMS/PUC-SP) Sorocaba, São Paulo, Brazil (e-mail: endoclinic@endoclinic.med.br; agomes@pucsp.br).

J Coloproctol 2023;43(2):75–81.

Abstract

Introduction Anal examination and videoanoscopy (VA) are rarely performed during colonoscopies. In recent years, there has been a considerable increase in lesions of sexually transmitted anal and rectal infections, but these conditions are not noticed or reported during routine colonoscopy.

Objective To raise awareness regarding the fortuitous findings of lesions and sexually transmitted infections (STIs) in colonoscopy exams and to demonstrate that anal examination and VA provide important information and should be routinely performed.

Methods We conducted a descriptive retrospective study in 16,132 patients screened by colonoscopy and VA between 2006 and 2018. Among numerous other findings, the presence of anal condylomata and sexually transmitted retitis or perianal dermatitis was observed. The rates of each finding were calculated, and the patients were subdivided by sex and into age groups by blocks of ten years.

Results Among the 16,132 colonoscopies performed, 26 cases of condyloma (0.16%) and 50 cases of proctitis or perianal dermatitis suspicious for STI (0.33%) were found.

Conclusion Performing anal examination and VA systematically in all routine colonoscopies enabled the identification of numerous anal conditions, including several fortuitous cases of STIs. The study proposes that anal examination and VA should be performed in all routine colonoscopies and, in suspected cases, complementary tests for STIs.

Keywords

- ▶ proctoscopy
- ▶ anal canal
- ▶ colonoscopy
- ▶ STI

Introduction

According to the Brazilian Ministry of Health,¹ at least 10,300,000 (65% of men and 35% of women) Brazilians have had at least 1 sexually transmitted infection (STI). Six STIs are on the rise in Brazil: HIV, syphilis, gonorrhoea, genital

herpes, hepatitis (B and C), and human papillomavirus (HPV; condylomatosis). The most transmissible STI is HPV, and the cumulative incidence throughout life is of 79% for the sexually-active population.² Transmission is greater from women to men, and condom protection is not complete. In 30% of the cases, the infections are associated; therefore,

received
December 10, 2022
accepted after revision
March 7, 2023

DOI <https://doi.org/10.1055/s-0043-1769486>.
ISSN 2237-9363.

© 2023. Sociedade Brasileira de Coloproctologia. All rights reserved.

This is an open access article published by Thieme under the terms of the Creative Commons Attribution-NonDerivative-NonCommercial-License, permitting copying and reproduction so long as the original work is given appropriate credit. Contents may not be used for commercial purposes, or adapted, remixed, transformed or built upon. (<https://creativecommons.org/licenses/by-nc-nd/4.0/>)

Thieme Revinter Publicações Ltda., Rua do Matoso 170, Rio de Janeiro, RJ, CEP 20270-135, Brazil

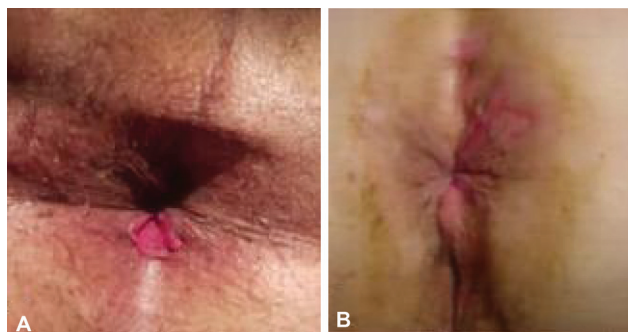


Fig. 1 Primary syphilitic lesions: (A) fissure; (B) perianal dermatitis.

routine research should be carried out, including the six aforementioned STI, as well as, if suspected, chlamydia, donovanosis, and lymphogranuloma venereum. According to the Epidemiological Newsletter of the Health Surveillance Department of the Ministry of Health,¹ there has been an increase in the incidence of syphilis of about 6 thousand times in the last 5 years, mainly in adolescents and young adults, with a registered increase of 40% in the age group between 14 to 19 years. After 10 to 90 days of sexual intercourse, primary lesions such as fissures and hard ulcers may appear (► **Figure 1**), with little pain (hard or primary chancre stage), requiring biopsy with dark-field research in primary and secondary lesions, in addition to the serological tests. The lesions disappear whether treated or not. After about two to three months, syphilitic secondariness occurs (► **Figure 2**).

Sexually transmitted proctitis and perianal dermatitis have an unknown real incidence, and most of cases are little symptomatic. It may present with itching, burning, wet anus, tenesmus, evacuation urgency or bleeding, erythema, edema, secretion, erosions and fissures. On colonoscopy, there is a moderate proctitis in the distal 10 cm, with erosions, a small amount of fibrin, without ulcer. Multiple pathogens are often involved, particularly in patients with acquired immunodeficiency syndrome (AIDS), including HPV, herpes type II, chlamydia (*Chlamydia trachomatis*), gonorrhea, cytomegalovirus (CMV; associated with atypical fissure), moniliasis, mycoplasma, ureaplasma, and syphilis³ (► **Figure 3**).

Anal intraepithelial neoplasia (AIN) is the precursor lesion of anal squamous cell carcinoma^{4,5} (► **Figure 4**); its incidence is low in the general population, but it competes with colon cancer in high-risk groups, particularly those with HIV infection and men who have sex with men.⁶ Individuals with HIV are 28 times more likely to have anal cancer.^{6,7} Inkster and Wu⁸ published a study in which 25 cases of intraepithelial neoplasia of the anal canal were detected in routine colonoscopies from 2008 to 2011.

Thus, screening for AIN and early anal cancer, as well as the treatment of these lesions in specialized centers should be considered in high-risk populations.⁹ Screening is performed using anal swab cytology and high-resolution anoscopy after the application of 3% acetic acid and Lugol solution to the anal canal, with HPV-infected cells seen as white lesions.^{2,10} Early diagnosis provides clear benefits. The treatment consists of topical or ablative therapies.¹¹

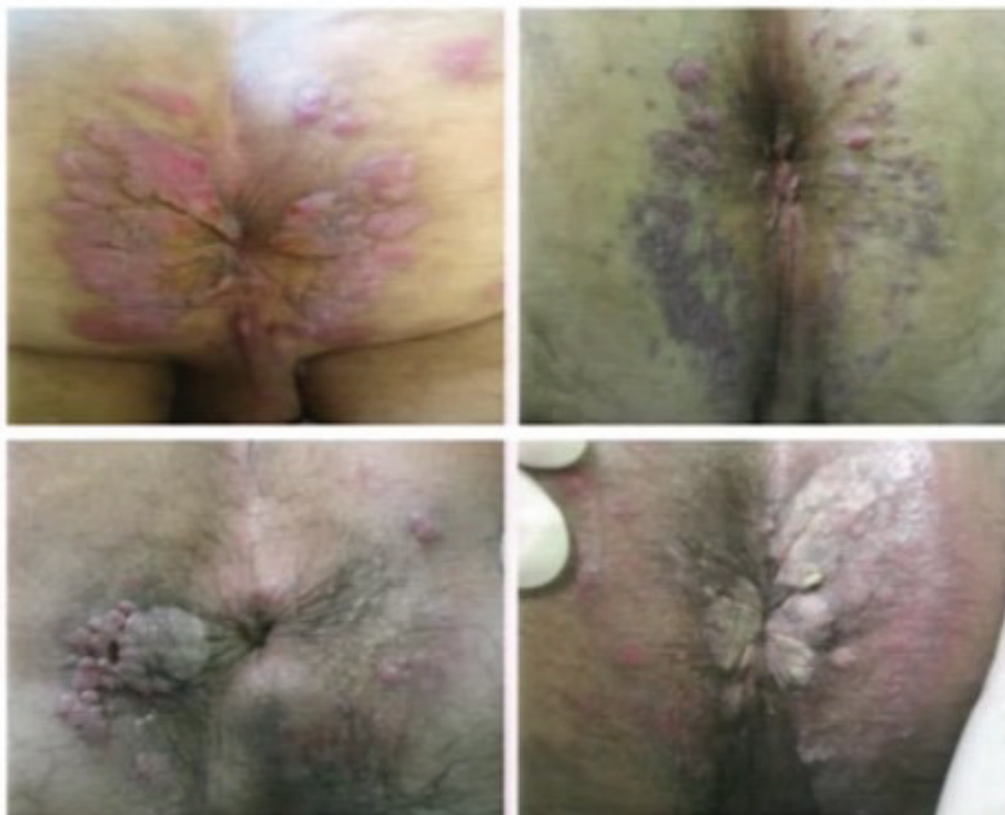

Fig. 2 Secondary syphilitic lesions (flat condyloma).

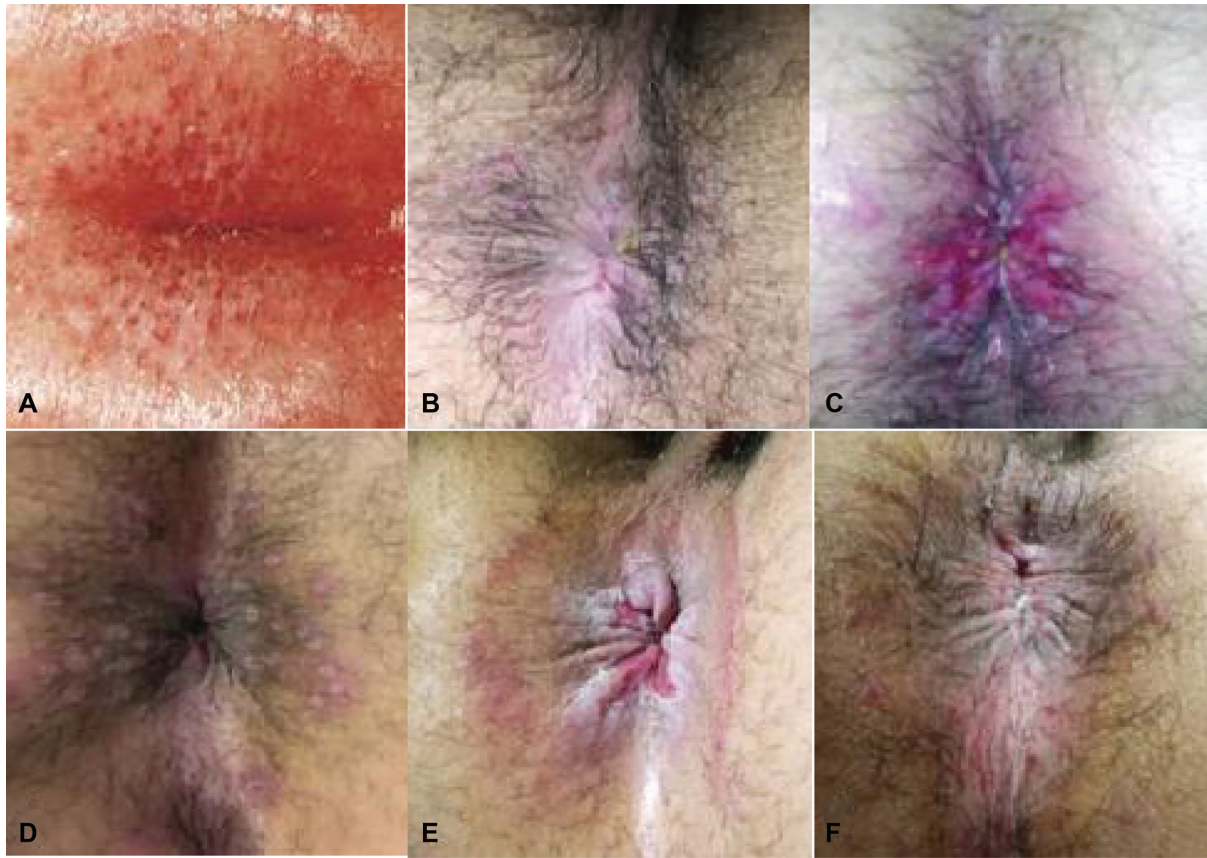

Fig. 3 Sexually transmitted perianal infections (STIs): (A) perianal dermatitis (herpes type II); (B) perianal chlamydial dermatitis; (C,D) perianal herpes; (E) herpes, mycoplasma and gonorrhoea; and (F) mycoplasma and gonorrhoea.

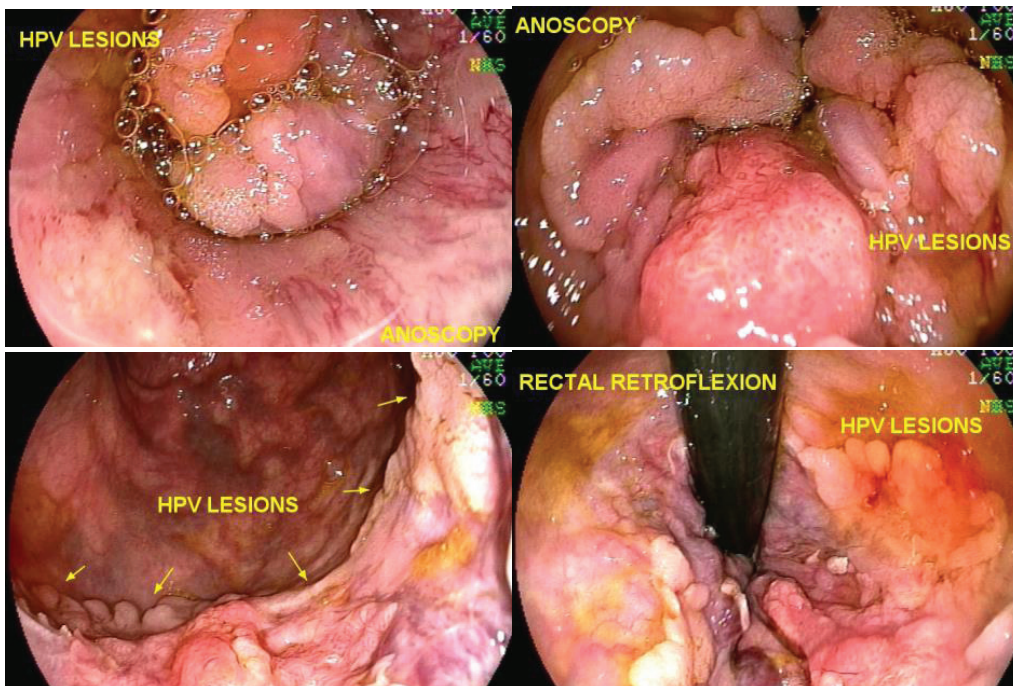


Fig. 4 Anal intraepithelial neoplasia: squamous epithelium with exophytic papillomatosis and high-grade squamous intraepithelial neoplasia with foci of koilocytosis (human papillomavirus, HPV).

Vaccination against HPV appears to reduce the rate of AIN and possibly of anal cancer.²

Methods

The present is a retrospective descriptive study of patients who were referred as outpatients for routine colonoscopy and systematically evaluated including anal examination by videoanoscopy (VA); the findings were submitted to a statistical analysis.

Inclusion Criteria

The patients were referred for colonoscopy and systematically submitted to VA and videocolonoscopy. An admission form was routinely filled out with patient data, the reason for requesting the examination, history of injuries or previous surgeries, and current complaints, including anal symptoms such as pain on defecation, bleeding, difficulty defecating, hemorrhoidal prolapse, incontinence, and pruritus.

All patients included underwent a standardized colon preparation with a liquid diet without fiber two days before the exam, bisacodyl 10 mg the night before, and 750 mL of 10% mannitol 4 hours before the exam. The criterion used for colon preparation conditions was based on the Aronchick scale.^{12,13} Although there are other classifications for colon preparation, such as the Boston classification,¹⁴ which is currently more accepted because it specifies the quality of the preparation in each region of the colon, the Aronchick scale was adopted due to its simplicity of application in relation to the rectum, checking whether the preparation is suitable for the anal examination or not.

Exclusion Criteria

Of the 16,185 colonoscopies evaluated, 53 exams were eliminated, cases in which, for many reasons (25 cases with perineal rectum amputation), the anal exam was not performed or is not included in the report; thus, 16,132 exams remained. The VA was not performed if the preparation of the rectum was classified as inadequate, which the Aronchick scale defines as one containing solid stools. In The Aronchick scale, the grades are as follows : excellent: small amount of clear liquid with clearly visualized mucosa in more than 95% of the path; good: small amount of cloudy liquid without stool interfering with the exam and more than 90% of the mucosa visualized; reasonable: moderate amount of feces that can be aspirated enabling an adequate evaluation of the colon, and the mucosa can be visualized in more than 90%; poor: presence of cloudy liquid and stools preventing an adequate examination, but the examination was completed and visualization of the mucosa was possible in less than 90%; and inadequate: the preparation has to be repeated, the large amount of feces prevents the examination.

Technical Aspects

The research patients underwent anal examination, with inspection of the perianal region through touch (digital anal examination), VA and videocolonoscopy. All examinations

were performed with the patients in the supine or left lateral positions, with non-invasive monitoring of the heart rate and pulse oximetry throughout the procedure, and use of supplemental oxygen if necessary. Intravenous medication for sedation was administered with midazolam (0.05 mg/Kg to 0.1 mg/Kg), fentanyl (0.5 mcg/Kg to 1 mcg/Kg), and propofol (10 mg titration doses for maintenance of sedation as needed).

The devices used were either the Pentax (Pentax Corporation, Tokyo, Japan) or Fujinon (Fujifilm, Tokyo, Japan) videocolonoscopes and a disposable, transparent plastic Kolplast (Itupeva, SP, Brazil) or Plastic Way anoscope.

The patients were submitted to an anal examination and then the colonoscope was introduced in the rectum with aspiration of the liquid content. A careful frontal-view assessment of the rectum, pectineal line, and anal canal was performed, followed by removal of the device. Then, the anoscope was introduced, the anal canal and the perianal region were evaluated with the aid of the videocolonoscope, and the results were recorded. In these procedures, visualization was performed with identification and photographic documentation of polyps, the internal hemorrhoidal plexus, the pectineal line, the anal canal, and the perianal region. After this evaluation, the colonoscopy examination was performed.

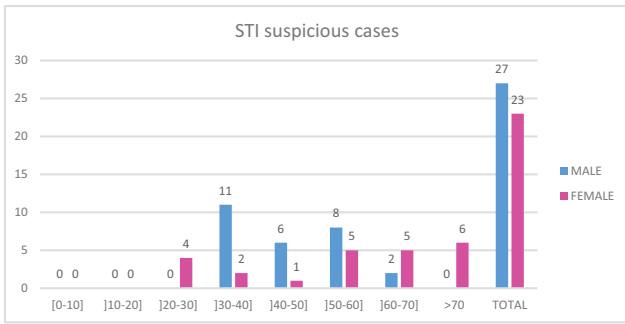
In cases of suspected STI or condyloma lesions, biopsies were performed, and the material was sent for an anatomicopathological study, collection of material for culture or polymerase chain reaction (PCR), in addition to serological tests for HIV, syphilis, herpes, and hepatitis B and C.

Data Storage and Collection

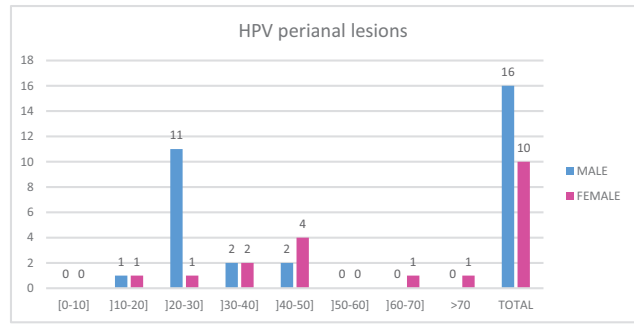
The exam reports and the images obtained were recorded and saved in a database (OCRAM Sistemas Informatizados, Sorocaba, SP, Brazil). The data mined for the composition of the research were extracted from the MySQL Community relational database (open source), version 5.5.40, which is the standard database used by the computer program. This system was developed with the Java programming language, and it was used to capture the photos of the VA exams and compose the respective reports typed by the executing physician from OCRAM software are structured in extensible markup language (XML) format, and follow an XML-Schema according to the norms of the World Wide Web Consortium (W3C), resulting in a well-formed, valid and standardized structure of the VA reports in XML, enabling the mining of terms referring to illnesses to be carried out in a reliable way through the declarative research structured query language (SQL) together with an XML document object model (DOM) parser.

Statistical Analysis

Data regarding age, sex, and diagnosis were described in tables and expressed as mean and maximum and minimum values, and the categorical variables were expressed as numbers and percentages. The VA findings were expressed in graphs according to the distribution by gender and age group.



Graph 2 Distribution of patients with suspicion of STI divided by sex and age groups.



Graph 1 Distribution of patients with perianal condylomatosis divided by sex and age groups.

Results

There were 26 cases of condylomatous lesions (0.16%), with a predominance of male patients, with 16 cases (61.53%), and 10 cases (38.46%) among the female patients (►Graph 1); 1 of the cases was of AIN. We identified 50 cases (0.31%) of proctitis or perianal dermatitis suspicious for STI that were referred for a specialized evaluation (male patients: 54%; female patients: 46%; ►Graph 2). After the tests, two cases of primary syphilis, one case of perianal herpetic dermatitis, one case of gonococcus and one case of anorectal chlamydia were confirmed. The remaining 45 cases with negative tests were treated as nonspecific perianal dermatitis.

Discussion

We found 26 cases of verrucous lesions with AP (anatomopathological examination) showing koilocytosis (condylomatous lesion

– HPV), with a predominance of males (61.53%) over females (38.46%). Fragments for analysis were collected with biopsy tweezers or with the application of local anesthetic and removed with surgical scissors. In some cases, the anal canal and inferior rectum lesions were removed and cauterized with hot biopsy forceps coupled to thermocautery.

A precursor of squamous cell carcinoma, AIN is directly related to the viral incidence of HIV and HPV.⁷ The diagnoses of the precursor lesion and anal cancer require adequate examination of the region and association with anal swab cytology, high-resolution anoscopy, and serological tests. The verrucous lesions observed in the anal examination are biopsied (►Figure 5) and, in the anatomopathological examination, foci of koilocytosis are found, which favors the etiology by HPV, whose search is recommended using the in situ hybridization method.

Anal HPV has a high rate of recurrence, ranging from 22% to 70% within 1 year, and a risk of transformation to cancer

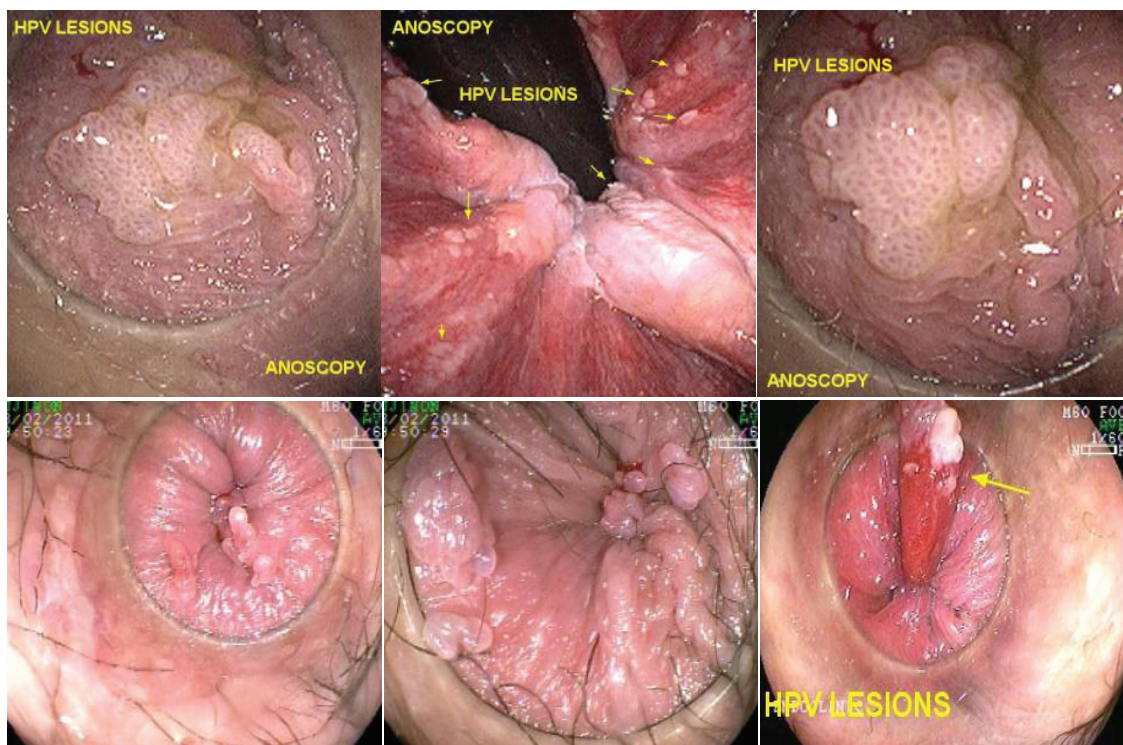


Fig. 5 Verrucous lesions in the anal canal. anatomopathological examination (AP): koilocytosis (HPV).

ranging from 9% to 13%.⁹ Screening is performed using anal swab cytology and high-resolution anoscopy after the application of 3% acetic acid and Lugol solution to the anal canal, with the HPV-infected cells seen as white lesions.^{5,10} Early diagnosis provides clear benefits.

We identified 50 cases (0.31%) of proctitis or dermatitis suspicious for STIs who underwent complementary tests that included anatomopathological examination, secretion culture, scraping with a brush for PCR, and serological tests for HIV, syphilis, herpes, hepatitis B and C (male patients: 54%; female patients 46% of the cases). Of these cases, after the examinations, two were confirmed with primary syphilis in the lower rectum and anal canal, there was one case of perianal herpetic dermatitis, one case of gonococcal anoritis, and one case of anorectal chlamydia; another six HIV-positive patients also had other nonspecific anal lesions, but four of them also had perianal condylomatosis.

However, most cases had an irritant or allergic cause (45 patients; 0.28%), from mucus or fecal residue, and aggravated by the use of chemical products. Dermatitis is usually nonspecific, and its treatment is with topical medications and changes in hygiene and dietary behaviors. Contact dermatitis is the basic mechanism that provides the most common dermatological picture of an inflammatory reaction in the anal and perianal regions. The most frequent causes of primary irritation contact dermatitis are local trauma during hygiene, and the use of toilet paper, perfume, cologne, soap, deodorant, talc, antimycotic ointment, allergenic underwear, the intake of spicy foods, liquid stools, and abusive use of laxatives. The primary perianal dermatological diseases that can be found are: contact dermatitis, seborrheic dermatitis, lichen simplex chronicus, intertrigo, psoriasis, vitiligo, acanthosis nigrans, Darier disease, lichen planus, pemphigus, acne vulgaris, hidradenitis suppurativa, histiocytosis, craurosis, mycoses (candidiasis, tinea cruralis, blastomycosis, actinomycosis, and sporotrichosis), parasitoses (oxyuriasis, scabies, and amoebiasis), bacterial infections (syphilis, donovanosis, chancroid, lymphogranuloma, and tuberculosis), viral infections (herpes simplex, molluscum contagiosum), gynecological diseases (leukorrhea due to trichomoniasis or gonococciasis), systemic diseases (diabetes, Behçet disease, and Hodgkin disease), and actinic lesions or proctological diseases (hemorrhoidal prolapse, perianal fistula, perianal Crohn disease).^{3,15-18}

Although most cases are related to nonspecific proctitis or perianal dermatitis, it is important to bear in mind the possibility of STIs and complement the evaluation with an

anal swab or brush to search for chlamydia and gonorrhea using the hybrid capture technique or PCR and scraping the ulcerated lesions search for syphilis and lymphogranuloma venereum.⁹ In suspected cases, request serology for HIV, syphilis, herpes, and hepatitis B and C.

Anoscopy with Magnification

In the follow-up of these patients with HPV, it is important to perform an anal scraping with a brush in the same way as the gynecological Papanicolaou test.² If an abnormal result is found, high-resolution anoscopy is indicated, which is an examination performed with a colonoscope to evaluate the perianal region, the anal canal, and the distal portion of the lower rectum. An evaluation is performed without dyes at first; then, 3% to 5% acetic acid is used to identify positive acetowhite lesions of the coarse speckled or mosaic type, which can mean AIN.

After acetic acid, Lugol solution is used, which helps to distinguish high- and low-grade squamous intraepithelial and to define their margins.¹⁰ This examination is performed by few specialized centers and has a very long learning curve. Although this evaluation using the colonoscope has become standard, it can be performed with magnification colonoscopy, using the same dyes, acetic acid and Lugol solution, or even using the features of colonoscopes that have magnification with chromoscopy with filters of light (narrow-band imaging, NBI), taking care to expand the evaluation to the perianal region.¹⁹ A work by Oette et al.²⁰ demonstrated that chromoendoscopy performed by VA is equally safe and effective in diagnosing AIN.

Thus, VA using a colonoscope with magnification and technologies with light filters (NBI, flexible spectral imaging color enhancement, FICE) associated with the use of dyes such as acetic acid and Lugol solution can effectively replace the high-resolution VA traditionally performed using a colonoscope in the evaluation and follow-up of neoplastic and preneoplastic lesions of anal condylomatosis (**figure 6**). The evaluation of the perianal region and the anal canal enables the diagnosis, treatment, and follow-up of condylomatosis and premalignant lesions related to HPV.²¹

The treatment of anal HPV is based on three principles: a) reduction of the local viral load with chemical ablation (podophyllin 25%) followed by thermal ablation of residual lesions; b) increase in systemic immunity with tetravalent vaccine; c) increase in local immunity with an immunomodulator (imiquimod 3 times a week for 16 weeks).¹¹

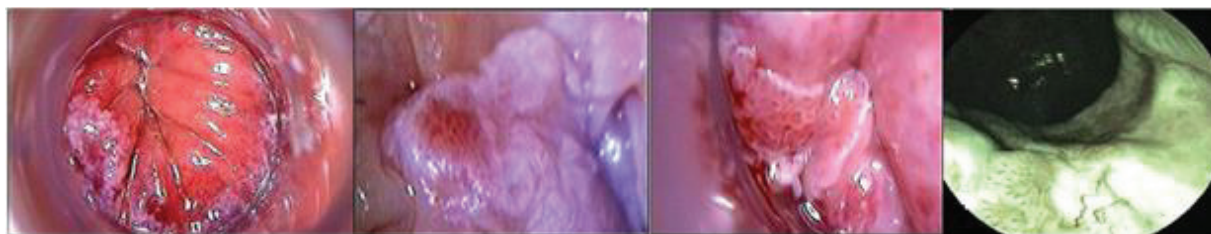


Fig. 6 High-grade intraepithelial neoplasia identified using acetic acid, image magnification and flexible spectral imaging color enhancement (FICE).

Conclusion

The fortuitous finding of STIs in routine colonoscopies is uncommon, but the colonoscopist needs to be aware of the diagnosis of these lesions. In the present study, through anal examination and VA systematically performed during routine colonoscopies in a significant number of cases, we observed a large number of anal disorders and, among them, some cases of lesions and STIs. The present work can help increase the understanding of the importance of evaluating the anal canal during the colonoscopy exam. As anal examination is not performed in most colonoscopies, performing VA expands the diagnosis of anal diseases and adds important information.

Conflict of Interests

The authors have no conflict of interests to declare.

References

- Secretaria de Vigilância em Saúde, Ministério da Saúde. Sifilis. Boletim Epidemiológico. 2017;1-42
- Thiago DSM, Nadal SR, Calore EE, Luís RMN, Manzione CR. Controle local da infecção perianal pelo papilomavírus humano após erradicação dos condilomas acuminados. In: Nadal SR CE, Nadal LRM, Manzione CR, eds. Rev Col Bras Cir 2014;41(02): 087-091
- Mauro RLP. Atlas of Sexually Transmitted Diseases. Syphilis. 2nd ed. Springer; 2018:1-87
- Magalhaes MN, Laura ERB. Anal Canal Squamous Carcinoma. J Coloproctol (Rio J) 2017;37(01):72-79
- Roberts JR, Siekas LL, Kaz AM. Anal intraepithelial neoplasia: A review of diagnosis and management. World J Gastrointest Oncol 2017;9(02):50-61. Doi: 10.4251/wjgo.v9.i2.50
- Wells JS, Holstad MM, Thomas T, Bruner DW. An integrative review of guidelines for anal cancer screening in HIV-infected persons. AIDS Patient Care STDS 2014;28(07):350-357. Doi: 10.1089/apc.2013.0358
- Grulich AE, Poynten IM, Machalek DA, Jin F, Templeton DJ, Hillman RJ. The epidemiology of anal cancer. Sex Health 2012;9(06): 504-508. Doi: 10.1071/SH12070
- Inkster MD, Wu JS. Anal dysplasia detection during routine screening colonoscopy. Surg Case Rep Rev 2018:1-5
- Nadal SR, Calore EE, Nadal LR, Horta SH, Manzione CR. Citologia anal para rastreamento de lesões pré-neoplásicas. [Anal cytology for screening of pre-neoplastic lesions] Rev Assoc Med Bras 2007; 53(02):147-151. Doi: 10.1590/s0104-42302007000200020
- Albuquerque A. High-resolution anoscopy: Uncharted territory for gastroenterologists? World J Gastrointest Endosc 2015;7(13): 1083-1087. Doi: 10.4253/wjge.v7.i13.1083
- Nadal S, Manzione C. Human papillomavirus vaccines. What we must know? Rev Bras Coloproctol 2010;30:237-240
- Sharara AI, Bou Daher H. Bowel Cleansing Strategies After Suboptimal Bowel Preparation. Clin Gastroenterol Hepatol 2019;17 (07):1239-1241. Doi: 10.1016/j.cgh.2018.12.042
- Gurudu SR, Ratuapli S, Heigh R, DiBaise J, Leighton J, Crowell M. Quality of bowel cleansing for afternoon colonoscopy is influenced by time of administration. Am J Gastroenterol 2010;105 (11):2318-2322. Doi: 10.1038/ajg.2010.235
- Massinha P, Almeida N, Cunha I, Tomé L. Clinical Practice Impact of the Boston Bowel Preparation Scale in a European Country. GE Port J Gastroenterol 2018;25(05):230-235. Doi: 10.1159/000485567
- Kränke B, Trummer M, Brabek E, Komericki P, Turek TD, Aberer W. Etiologic and causative factors in perianal dermatitis: results of a prospective study in 126 patients. Wien Klin Wochenschr 2006; 118(3-4):90-94. Doi: 10.1007/s00508-006-0529-x
- Agulló-Pérez AD, Hervella-Garcés M, Oscoz-Jaime S, Azcona-Rodríguez M, Larrea-García M, Yanguas-Bayona JI. Perianal Dermatitis. Dermatitis 2017;28(04):270-275. Doi: 10.1097/DER.0000000000000274
- Daling JR, Weiss NS, Hislop TG, et al. Sexual practices, sexually transmitted diseases, and the incidence of anal cancer. N Engl J Med 1987;317(16):973-977. Doi: 10.1056/NEJM198710153171601
- Isik O, Aytac E, Brainard J, Valente MA, Abbas MA, Gorgun E. Perianal Paget's disease: three decades experience of a single institution. Int J Colorectal Dis 2016;31(01):29-34. Doi: 10.1007/s00384-015-2342-3
- Inkster MD, Wiland HO, Wu JS. Detection of anal dysplasia is enhanced by narrow band imaging and acetic acid. Colorectal Dis 2016;18(01):O17-O21. Doi: 10.1111/codi.13170
- Oette M, Wieland U, Schünemann M, et al. Anal chromoendoscopy using gastroenterological video-endoscopes: A new method to perform high resolution anoscopy for diagnosing intraepithelial neoplasia and anal carcinoma in HIV-infected patients. Z Gastroenterol 2017;55(01):23-31. Doi: 10.1055/s-0042-117646
- Gomes A, Minata MK, Jukemura J, de Moura EGH. Video anoscopy: results of routine anal examination during colonoscopies. Endosc Int Open. 2019 Nov;7(11):E1549-E1562. doi: 10.1055/a-0998-3958. Epub 2019 Nov 11. PMID: 31723578; PMCID: PMC6847703.