



## Original Article

## Retained or expelled staples after transanal stapled surgery: this is the problem!

Alessandro Sturiale<sup>a,\*</sup>, Jacopo Martellucci<sup>b</sup>, Gabriele Naldini<sup>a</sup><sup>a</sup> Cisanello University Hospital, Proctological and Perineal Surgical Unit, Pisa, Italy<sup>b</sup> Careggi University Hospital, Emergency and Mini-invasive Surgery, Florence, Italy

## ARTICLE INFO

## Article history:

Received 31 March 2017

Accepted 4 June 2017

Available online 13 July 2017

## Keywords:

Stapled transanal resection

Haemorrhoids

STARR

ODS

Staples

## ABSTRACT

**Study objective:** The aim is to assess the presence and persistence of the agraphes at the level of staple line after transanal stapled surgery.

**Methods:** From April to December 2016 one-hundred-thirteen patients with variable follow-up (6 months–10 years) were randomly selected among all the patients undergone transanal stapled surgery for haemorrhoidal disease or functional disorders such as obstructed defecation syndrome. Only 87 patients agreed to participate this study. All the patients underwent digital exploration, anoscopy and 360° tridimensional transanal ultrasound.

**Main results:** Different types of stapled transanal surgical procedures were performed: 48 transanal rectal resection with high volume device, 24 stapled haemorrhoidopexy, 8 Double Stapled Haemorrhoidopexy, 7 Transtarr. In 41.4% the staple line was not identified with digital examination or anoscopy and 17.2% of patients have some staples partially expelled inside the lumen. 360° tridimensional transanal ultrasound showed a complete staple line at the ano-rectal junction which appears as an interrupted hyperechoic circular layer.

**Conclusion:** The staples after stapled transanal surgery remain at the level of the staple line independently from the device used by the surgeon leading to the necessity of a shared and adequate language, in fact the shed staples need to be considered as expelled instead of retained.

© 2017 Published by Elsevier Editora Ltda. on behalf of Sociedade Brasileira de Coloproctologia. This is an open access article under the CC BY-NC-ND license (<http://creativecommons.org/licenses/by-nc-nd/4.0/>).

## Grampos retidos ou expelidos em seguida à cirurgia transanal com grampeador: eis aí o problema!

## RESUMO

**Objetivo do estudo:** Avaliar a presença e persistência dos agrafes ao nível da linha de aplicação dos grampos, em seguida à cirurgia transanal com grampeador.

**Métodos:** De abril até dezembro de 2016, 113 pacientes com seguimentos variáveis (6 meses–10 anos) foram aleatoriamente selecionados entre todos os pacientes tratados com cirurgia

## Palavras-chave:

Ressecção transanal com

grampeador

Hemorroidas

\* Corresponding author.

E-mail: [alexstur@yahoo.it](mailto:alexstur@yahoo.it) (A. Sturiale).<http://dx.doi.org/10.1016/j.jcol.2017.06.005>2237-9363/© 2017 Published by Elsevier Editora Ltda. on behalf of Sociedade Brasileira de Coloproctologia. This is an open access article under the CC BY-NC-ND license (<http://creativecommons.org/licenses/by-nc-nd/4.0/>).

STARR  
ODS  
Grampos

transanal com grampos para tratamento de hemorroidais ou de transtornos funcionais, por exemplo, síndrome de evacuação obstruída. Apenas 87 pacientes concordaram em participar do estudo. Todos os pacientes passaram por exploração digital, anoscopia e ultrassonografia transanal tridimensional de 360°.

**Resultados principais:** Foram realizados diferentes tipos de procedimentos cirúrgicos transanais com grameador: 48 ressecções retais transanais com uso de grameador de grande volume, 24 hemorroidopexias com grameador, 8 hemorroidopexias com grampos duplos e 7 procedimentos com grameador Transtar. Em 41,4% dos tratamentos, não foi possível identificar a linha de grameamento com exame digital ou com anoscopia, e em 17,2% dos pacientes alguns grampos foram expelidos para o lúmen. A ultrassonografia transanal tridimensional de 360° revelou uma linha de grameamento completo na junção anorretal, assumindo o aspecto de uma camada circular hiperecoica interrompida.

**Conclusão:** Em seguida à cirurgia transanal com grameamento, os grampos permanecem ao nível da linha de grameamento, independentemente do tipo de grameador usado pelo cirurgião, o que torna necessária uma linguagem compartilhada e adequada; de fato, os grampos soltos devem ser considerados como expelidos, em lugar de retidos.

© 2017 Publicado por Elsevier Editora Ltda. em nome de Sociedade Brasileira de Coloproctologia. Este é um artigo Open Access sob uma licença CC BY-NC-ND (<http://creativecommons.org/licenses/by-nc-nd/4.0/>).

## Introduction

Mechanical stapler is one of the greatest surgical innovation of the last century. It allows to perform quick and easy procedures resulting safe and effective. The pioneer of stapler procedures with his prototype weighted 3.6 kg was Hümer Hült also known as the “father of surgical stapling” in 1908. The technological development passed through several countries and lots of different devices, firstly used for blood vessels and then applied to the bowel too.<sup>1–5</sup> From the initial application in the abdominal open surgery the technology followed the trend of continuous surgical improvement maintaining the same standard levels also in the new laparoscopic approach and it always led to new devices. Stapled surgery for the treatment of haemorrhoidal prolapse, the so-called stapled haemorrhoidopexy (SH), was firstly described by Longo in 1998 as a less painful alternative to the conventional haemorrhoidectomy.<sup>6</sup> Since that moment, there were lots of technological changes, some of them are clearly visible such as the shape and ergonomics while others are less evident but fundamental to improve device performance. A common element to all the different type of stapler is the use of non-magnetic, inert metal staples which may guarantee a long lasting. Lots of study were performed to assess metals properties and they conclude that the best choice is titanium or titanium alloy<sup>7</sup> rather than stainless steel which was used at first. Although it may seem fairly clear the fate of the staples after bowel anastomosis, the surgeons are often not well-informed about this and they use inaccurate terms causing lot of confusion about the procedure, its effects and the possible postoperative complications. The aim of the present study is to assess the presence and persistence of the agraphes at the level of staple line after transanal stapled surgery.

## Methods

From April 2016 to December 2016 one-hundred-thirteen patients with variable follow-up (range: 6 months–10 years)

were randomly selected among all the patients undergone transanal stapled surgery for haemorrhoidal disease or functional disorders such as obstructed defecation syndrome (ODS). They were retrospectively collected through clinical records and then telephone called for an outpatient evaluation. Only 87 patients agreed to undergo this further follow-up not scheduled. All the patients underwent physical examination through digital exploration, anoscopy and 360° tridimensional transanal ultrasound. The evaluation was performed by two experienced surgeons specialized in colorectal and proctological surgery.

## Results

Eighty-seven patients (48 M – 39 F) underwent stapled surgery. Different types of surgical procedures were performed and they were divided as follows: 48 transanal rectal resection with high volume device such as TST STARR+ 36, 24 stapled haemorrhoidopexy (SH) with single PPH device, 8 Double Stapled Haemorrhoidopexy (DSH) with two PPH device, 7 Transtarr with Contour CCS-30. Patients' follow-up before this outpatient evaluation ranged from 6 months to 10 years and it is distributed as follows: 12 patients (12 TST STARR+ 36) at 6 months, 26 patients (26 TST STARR+ 36) at 1 year, 11 (10 TST STARR+ 36, 1 DSH) patients at 3 years, 11 patients (7 DSH, 4 CCS-30) at 5 years, 9 patients (6 PPH, 3 CCS-30) at 7 years and 18 patients (18 SH) at 10 years. In thirty-six patients (41.4%) the staple line was not identified with digital examination or anoscopy. Fifteen patients (17.2%), 13 of them within the first year follow-up, have some staples partially expelled inside the lumen at the level of the staple line identified through both digital exploration and anoscopy (Fig. 1). In nine (10.3%) patients there are little granulomas above partially expelled staples causing sporadic bleeding. 360° tridimensional transanal ultrasound showed in all the patients the presence of an interrupted hyperechoic circular layer at the upper edge of the pubo-rectalis muscle, resulting in a complete staple line at the ano-rectal junction (Fig. 2).

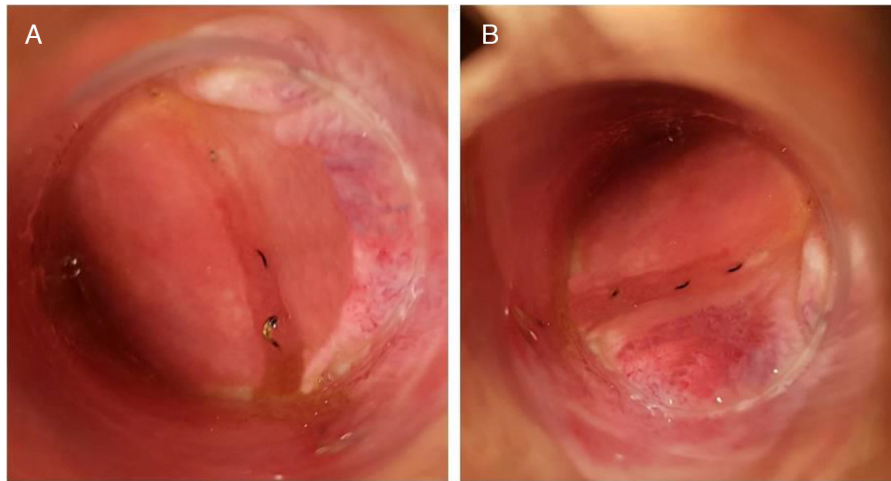


Fig. 1 - (A, B) Anoscopy: partially expelled staples at the level of the stapled line without any sign of inflammation.

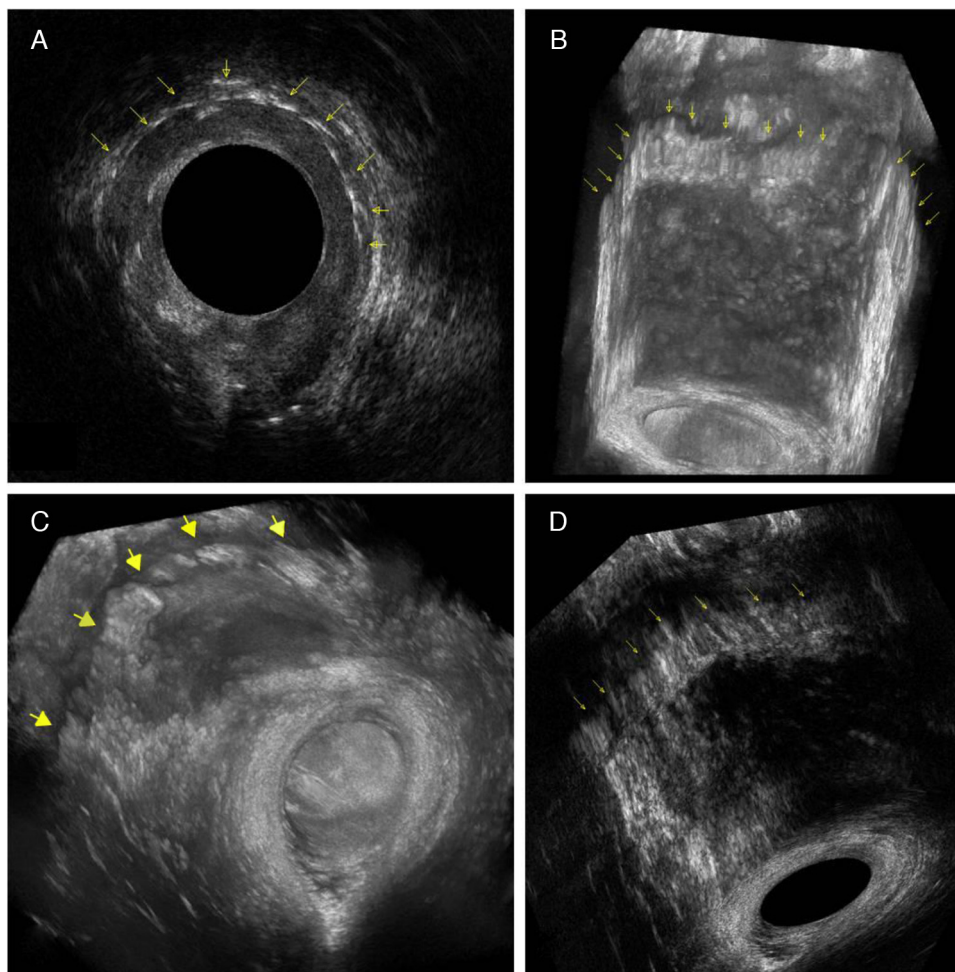


Fig. 2 - 360° tridimensional transanal ultrasound: yellow arrows indicate the staple line. (A) 2D visualization; (B, C) 3D visualization with rendering; (D) 3D visualization.

## Discussion

Starting from the beginning of the last century the technology simplified and made it easier some surgical steps. A central role in this field was played by the mechanical stapler which were used to perform blood vessels or bowel anastomosis.<sup>1,3</sup> In 1998 Longo described the use of a circular stapler to treat the haemorrhoidal prolapse<sup>6</sup> then applied for obstructed defecation syndrome too. After this experience stapled haemorrhoidopexy spread worldwide and the sale of the devices widely increased. The growing surgical innovation and the need to improve the outcome have led to the introduction of the double stapled procedure to resect all the prolapsed tissue which otherwise would not enter in a single device casing.<sup>8</sup> However, in case of multiple suture line there are some weak and fixed points at the level of the crossing sutures. Another consequence of multiple rectal resection is that the rectal prolapse is resected in pieces and it is not symmetrical. Whereby, new dedicated high volume devices were recently introduced to allow a cylindrical rectal resection.<sup>9,10</sup> In all of these different phases of stapled procedure evolution for the treatment of haemorrhoidal disease and ODS too, the common denominator was the fashioning of recto-rectal anastomosis using titanium or titanium alloy agraphes. This type of staples allows the patients to undergo whatever radiological imaging such as CT scan or MRI because they are nonmagnetic and inert and they guarantee to remain in the same site. Although it may be an obvious and simple concept of the staplers use, it is not. In fact, a recent paper reported a survey carried out among 16 surgeons experienced in SH. The authors asked them the fate of the staples. Ten (62.5%) of them answered that they will be shed within 3 months, 3 answered that the staples will be retained inside permanently, 2 answered that only some of them are shed and 1 expressed ignorance about this topic.<sup>11</sup> This is a clarifying study regarding the ignorance and confusion about the fate of the staples used to treat haemorrhoidal prolapse or ODS-related altered anatomy. It also revealed an important issue, approximately 75% of patients undergoing stapled surgery wishes to know more about the technology used to treat their disease.<sup>11</sup> Besides, the presence of partially expelled staples inside the rectal lumen which are not correctly integrated inside the staple line and covered by the mucosal layer may be the cause of some bothersome post-operative symptoms. The spectrum of these symptoms can vary from sporadic bleeding due to the presence of granuloma above the partially expelled staples to chronic pain, inflammatory polyp or even proctitis.<sup>12-15</sup> Only few cases are reported about penile trauma, condom rupture or anal pain during anal intercourse after stapled haemorrhoidopexy.<sup>16-19</sup>

In the present study the association of digital examination, anoscopy and 360° tridimensional transanal ultrasound confirmed that the staples after transanal stapled procedure remain inside the rectal wall at the level of the anastomosis and that sometimes only few of them are completely or partially expelled. Moreover, the long lasting of the staples resulted to be independent from the type of the device chosen by the surgeon (PPH, Contour CCS-30, TST STARR-36).

These results are in keeping with other published papers about stapled procedures in different surgical fields such as abdominal surgery. Nevertheless, nowadays the persistence of the staples inside the abdomen after bowel surgery or inside the thorax after lung resection is not so debated. Two are the possible reasons. Firstly, stapler in abdominal or thoracic surgery is routinely used and they represent only a step of the whole surgical procedure. The use of the mechanical device is not necessary and depends on the situation and anatomical condition, in fact, at present, it has been also demonstrated that stapled anastomosis is comparable to the hand-sewn without any superiority of one over the other.<sup>20</sup> Secondly, in upper GI, colorectal<sup>21</sup> and bariatric<sup>22</sup> surgery the presence and persistence of the staples at the level of the anastomosis is considered as a marker to easily identify it in fluoroscopy or through CT scan and it is used in the post-operative evaluation of dehiscence or leak. On the other hand, the choose of staple procedure for haemorrhoidal disease or ODS represents the whole surgical treatment. An important key point is that the staple line is very close to the external anal verge, around 4 cm, so that the patients themselves may feel it, differently from abdominal or thoracic surgery in which the patients, even if they know, they have not a real perception and awareness of the staples. Another issue, which is not so debated, is related to the anal intercourses after this type of surgery because both the patient and/or his/her partners may experience pain, stiffness or penile trauma. This condition revealed to have an important impact on the quality of life, sexual habits and personal and social sexuality on homo/bisexual and heterosexual population. However, so far the literature lacks a complete and exhaustive study analysing the impact of the different proctologic surgical procedures on anal intercourses.

This background clearly explains why the surgeons need to deepen staples topic, especially for the treatment of benign proctologic disease and also clarify why it was not so deeply analyzed before. The present paper first analyses the real fate of the agraphes in patients with different follow-up, up to 10 years, after transanal stapled surgery. The procedures were performed with different devices to treat haemorrhoidal disease or functional disorders such as obstructed defecation syndrome.

Therefore, it is time to move on and to use a correct and shared medical language. It is not more adequate to speak about retained staples because all the staples or most of them are usually retained, whereby it is more accurate to speak about expelled staples. The expelled staples are those which are partially or completely shed from the staple line. This may be a consequence of an imperfect fire of the machine and for this reason the companies producing stapling devices continuously improve the features of the staplers. In fact, technological innovation leads to the introduction and application of new patented changes, such as permanent parallel control system, allowing a greater stability and balance during the fire. Nevertheless some staples are sometimes partially expelled and they can remain asymptomatic or are the cause of postoperative hassles. This concept has also important implications in the field of forensic medicine regarding compensation of damages after transanal stapled surgery.

Hence, the correct preoperative information of the patients should be based on the explanation of the different aspects

of the chosen procedure which needs to be clearly reported inside the informed consent. It must be performed using precise and specific terms that can be understood by the patients and at the same time did not generate misunderstanding in the assessment done by forensic doctors, lawyers and judges.

## Conclusion

The staples after stapled transanal surgery remain at the level of the staple line independently from the device used. This concept leads to the necessity of a correct language whereby the shed staples need to be called expelled instead of retained. Besides, the knowledge of the device and its related features and possible postoperative consequences is at the base of a correct use of the stapler and it is essential for an adequate management of postoperative complications or troublesome symptoms.

## Conflicts of interest

The authors declare no conflicts of interest.

## REFERENCES

1. United States Surgical Corporation History. International directory of company histories, vol. 34. St. James Press; 2000.
2. Hultl H. II Kongress der Ungarischen Gesellschaft für Chirurgie, Budapest, May, 1908. *Pester Med Chir Presse*. 1909;45:108–10.
3. Robicsek F. The birth of the surgical stapler. *Surg Gynecol Obstet*. 1980;150:579–83.
4. Robicsek F. Development of the surgical stapling device. *Thorac Cardiovasc Surg*. 1993;41:207–15.
5. Robicsek F, Konstantinov I, Humer Hultl: the father of the surgical stapler. *J Med Biogr*. 2001;9:16–9.
6. Longo A. Treatment of haemorrhoid disease by reduction of mucosa and haemorrhoidal prolapse with circular stapling device: a new procedure. In: *Proceedings of the 6th world congress of endoscopic surgery*. 1998.
7. Gentili S, Portigliotti L, Aronici M, Ferrante D, Surico D, Milanesio M, et al. Ultrastructural analysis of different-made staplers' staples. *Minerva Chir*. 2012;67:439–44.
8. Naldini G, Martellucci J, Talento P, Caviglia A, Moraldi L, Rossi M. New approach to large haemorrhoidal prolapse: double stapled haemorrhoidopexy. *Int J Colorectal Dis*. 2009;24:1383–7.
9. Naldini G, Fabiani B, Menconi C, Giani I, Toniolo G, Martellucci J. Tailored prolapse surgery for the treatment of hemorrhoids with a new dedicated device: TST Starr plus. *Int J Colorectal Dis*. 2015;30:1723–8.
10. Reboa G, Gipponi M, Gallo M, Ciotta G, Tarantello M, Caviglia A, et al. High-volume transanal surgery with CPH34 HV for the treatment of III–IV degree haemorrhoids: final short-term results of an Italian multicenter clinical study. *Surg Res Pract*. 2016;2016:2906145.
11. Garg P, Sidhu G, Nair S, Song J, Singla V, Lakhtaria P, et al. The fate and significance of retained staples after stapled haemorrhoidopexy. *Colorectal Dis*. 2011;13:572–5.
12. Fondran JC, Porter JA, Slezak FA. Inflammatory polyps: a cause of late bleeding in stapled hemorrhoidectomy. *Dis Colon Rectum*. 2006;49:1910–3.
13. Pescatori M, Gagliardi G. Postoperative complications after procedure for prolapsed hemorrhoids (PPH) and stapled transanal rectal resection (STARR) procedures. *Tech Coloproctol*. 2008;12:7–19.
14. Menconi C, Fabiani B, Giani I, Martellucci J, Toniolo G, Naldini G. Persistent anal and pelvic floor pain after PPH and STARR: surgical management of the fixed scar staple line. *Int J Colorectal Dis*. 2016;31:41–4.
15. Bruscianno L, Ayabaca SM, Pescatori M, Accarpio GM, Dodi G, Cavallari F, et al. Reinterventions after complicated or failed stapled hemorrhoidopexy. *Dis Colon Rectum*. 2004;47:1846–51.
16. Capomagi A, Mannetta V, Balestrieri A. Circular hemorrhoidectomy using stapler is the gold standard for the treatment of hemorrhoids? Preliminary data regarding 206 consecutive patients. *Ital J Coloproctol*. 1990;2:782–5.
17. Kekez T, Bulic K, Smudj D, Majerovic M. Is stapled hemorrhoidopexy safe for the male homosexual patient? Report of a case. *Surg Today*. 2007;37:335–7.
18. Mlakar B. Should we avoid stapled hemorrhoidopexy in males and females who practice receptive anal sex? *Dis Colon Rectum*. 2007;50:1727.
19. Ravo B, Amato A, Bianco V, Boccasanta P, Bottini C, Carriero A, et al. Complications after stapled hemorrhoidectomy: can they be prevented. *Tech Coloproctol*. 2002;6:83–8.
20. Neutzling CB, Lustosa SA, Proenca IM, da Silva EM, Matos D. Stapled versus handsewn methods for colorectal anastomosis surgery. *Cochrane Database Syst Rev*. 2012:CD003144.
21. Shyn PB, Madan R, Wu C, Erturk SM, Silverman SG. PET/CT pattern analysis for surgical staple line recurrence in patients with colorectal cancer. *AJR Am J Roentgenol*. 2010;194:414–21.
22. Bingham J, Shawhan R, Parker R, Wigboldy J, Sohn V. Computed tomography scan versus upper gastrointestinal fluoroscopy for diagnosis of staple line leak following bariatric surgery. *Am J Surg*. 2015;209:810–4.