



Case Report

Verrucous carcinoma at ileostomy site



Vijay Dhakre*, Sanjay Nagral

Jaslok Hospital and Research Centre, Mumbai, India

ARTICLE INFO

Article history:

Received 12 January 2017

Accepted 1 May 2017

Available online 25 May 2017

Keywords:

Ileostomy

Verrucous carcinoma

Mucocutaneous junction

ABSTRACT

We describe of a case, a 50 year old male who was operated for carcinoma of the descending colon and diverting loop ileostomy, developed a fungating lesion in mucocutaneous junction of ileostomy after one year which on histology revealed to be a Verrucous carcinoma.

© 2017 Sociedade Brasileira de Coloproctologia. Published by Elsevier Editora Ltda. This is an open access article under the CC BY-NC-ND license (<http://creativecommons.org/licenses/by-nc-nd/4.0/>).

Garcinoma verrucoso em local de ileostomia

RESUMO

Descrevemos um caso, homem, 50 anos, que foi operado para carcinoma de cólon descendente e ileostomia em alça para desvio. Transcorrido um ano, o paciente desenvolveu uma lesão vegetante na junção mucocutânea da ileostomia; a histologia revelou ser um carcinoma verrucoso.

© 2017 Sociedade Brasileira de Coloproctologia. Publicado por Elsevier Editora Ltda. Este é um artigo Open Access sob uma licença CC BY-NC-ND (<http://creativecommons.org/licenses/by-nc-nd/4.0/>).

Palavras-chave:

Ileostomia

Carcinoma verrucoso

Junção mucocutânea

Introduction

Complications of stomal site are often encountered by clinicians¹ but neoplasms of stomal sites are very rare.² It can be confused or get obscured by granulation, tissue excoriation or ignorance by health care provider. We share our experience of a rare case of verrucous carcinoma.

Case report

A 50 year old male seropositive for human immunodeficiency virus (HIV) was planned for a loop ileostomy closure after one year of anterior resection for adenocarcinoma of descending colon. Patient had received adjuvant chemotherapy. Patient was also on HAART (highly active anti-retroviral therapy) for HIV infection.

* Corresponding author.

E-mail: vddrvijayd@gmail.com (V. Dhakre).

<http://dx.doi.org/10.1016/j.jcol.2017.05.002>

2237-9363/© 2017 Sociedade Brasileira de Coloproctologia. Published by Elsevier Editora Ltda. This is an open access article under the CC BY-NC-ND license (<http://creativecommons.org/licenses/by-nc-nd/4.0/>).

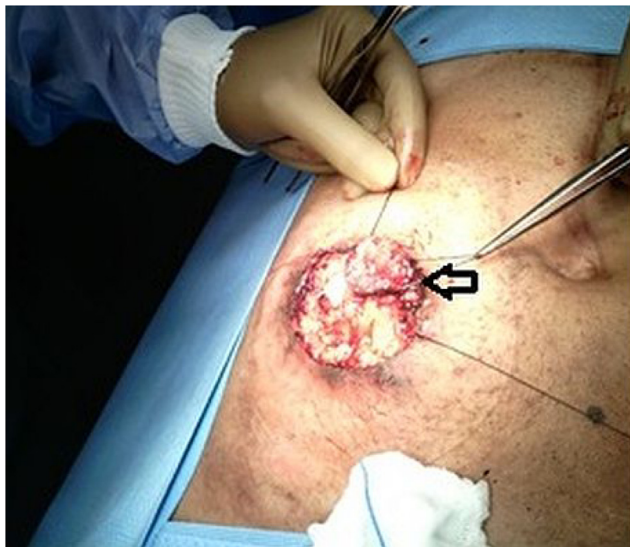

Fig. 1 – Intraoperative ileostomy site with the lesion (black arrow) in the superomedial mucocutaneous junction which is dissected and mobilized.

Before stoma closure CT scan had shown normal distal bowel and no evidence of recurrence. Three months prior to the closure; patient had reported oozing of blood from the stomal site. A local examination revealed an area of hypergranulation which was attributed to chronic irritation and was left alone.

During the surgery we noticed a small fungating mass on the right lateral edge of the mucocutaneous site (Fig. 1). In view of suspicion of malignancy a wide local resection of the loop ileostomy was performed, keeping a margin of 2 cm over the skin and abdominal wall layers (Fig. 2).

Patient is well after six months after surgery without evidence of recurrence.

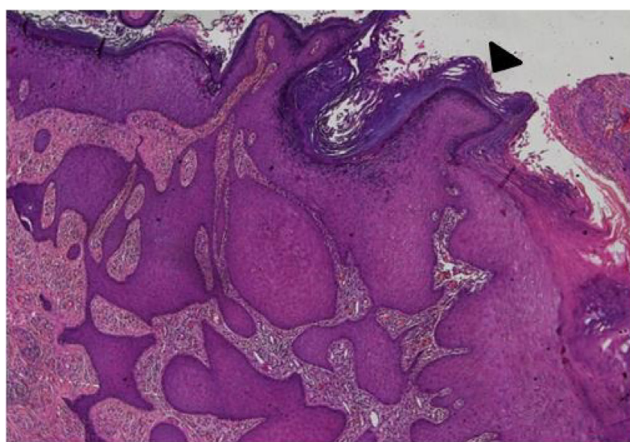


Fig. 2 – Marked acanthosis with broad bulbous process (black arrow head). The bulbous rete processes “push” deep into the lamina propria so that the base of the lesion is below the adjacent basement membrane.

Discussion

Complications of stoma are well described and include stomal herniation, prolapse of stoma, retraction, skin excoriation, intestinal obstruction, stenosis, abscess, fistula, diarrhoea, urinary calculus, ileitis, and inflammatory polyps.¹ Development of malignancy at ileostomy is rare² Suarez et al. estimated the incidence of ileostomy carcinomas in patients with ileostomy for various indications in the UK to be 2 to 4 per 1000 ileostomies. Squamous cell carcinoma (SSC) have been described commonly in HIV positive patients at mucocutaneous junctions specially anorectal junction.³ However to our knowledge VC has not being described at the ileostomy site, although there are reports of SCC.

Till date only a few cases of SCC at ileostomy have been described.⁴ Ulcerative colitis was the most common underlying condition; Farshid in their review described timing of lesion from ileostomy fashioning was in the range of 26 years to 54 years. In our case this time was very short (12 months).

Maw et al.⁵ had mentioned in their case series of 44 stomal neoplasms; described 40 adenocarcinomas and four squamous cell carcinoma, but no VC variant was described. They described of ileostomy neoplasm associated with Crohn's disease, familial adenomatous polyposis and ulcerative colitis. They postulated that chronic irritation predisposed the stoma to malignant changes. They discussed a strong association in patient with chronic diseases like ulcerative colitis or primary sclerosing cholangitis making it a high risk group for ileostomy neoplasms. The chronic irritation theory is supported by the fact that majority of stomal carcinoma have been described only in long standing permanent stomas.⁶ In the setting of HIV, human papilloma virus (HPV) infection is well known to predispose to carcinomas. Viral interactions in HPV can predispose to VC.⁶ In our case though the immunohistochemical analysis for HPV was negative. The E6/E7 viral oncoproteins of HPV are proved to inactivate the tumour suppressor gene like p53 and pRb which in turn lead to the cell proliferation and eventually turning them in to malignant cells. Highly active anti-retroviral therapy (HAART) modulating the immune is also taken into account while considering interactions of these viruses.⁷

Overall risk of carcinomas in HIV patients is more than in general population.⁷ Moreover associations of HIV – non-Hodgkin's lymphoma (NHL) at ileostomy site specifically because of microtraumatism and locally present antigen stimulation and activation has been discussed in their work by Levecq et al.³

Also it is pertinent to mention activation of signalling pathways like Akt/mTOR which can get activated and is also known to cause VC in oral malignancy.⁸

Conclusion

Peristomal carcinoma is a rare entity. VC (a rare form of SCC) may arise as a lesion from an ileostomy. A clinician must suspect malignancy when there is a hypergranulation or mass like lesion at ileostomy site. Immunodeficiency conditions like HIV

should be considered a high risk group for such rare forms of malignancy.

Conflicts of interest

The authors declare no conflicts of interest.

Acknowledgements

Dr Vijay Dhakre designed and wrote up the article with review of literature and procuring the data, Dr Sanjay Nagral finalized the article and literature review.

REFERENCES

1. Attanoos R, Billings P, Hughes L, Williams G. Ileostomy polyps, adenomas, and adenocarcinomas. *Gut*. 1995;37:840–4.
2. Suarez V, Alexander-Williams J, O'Connor J, Campos A, Fuggle J, Thompson H, et al. Carcinoma developing in ileostomies after 25 or more years. *Gastroenterology*. 1988;95:205–8.
3. Levecq H, Hautefeuille M, Hoang C, Galian A, Hautefeuille P, Rambaud JC. Primary stomal lymphoma. An unusual complication of ileostomy in a patient with transfusion-related acquired immune deficiency syndrome. *Cancer*. 2006;65:1028–32.
4. Farshid E, Metin N, Rangasamy S. Squamous cell carcinoma at an ileostomy site – Fiftyfour years following colectomy for ulcerative colitis: a case report and literature review. *Int J Surg Case Rep*. 2013;4:678–80.
5. Quah HM, Samad A, Maw A. Ileostomy carcinomas a review: the latent risk after colectomy for ulcerative colitis and familial adenomatous polyposis. *Colorectal Dis*. 2005;7: 538–44.
6. Tonna J, Palefsky JM, Rabban J, Campos GM, Theodore P, Ladabaum U. Esophageal verrucous carcinoma arising from hyperkeratotic plaques associated with human papilloma virus type 51. *Dis Esophagus*. 2010;23:E17–20.
7. Righetti E, Ballon G, Ometto L, Cattelan AM, Menin C, Zanchetta M, et al. Dynamics of Epstein-Barr virus in HIV-1-infected subjects on highly active antiretroviral therapy. *AIDS*. 2002;16:63–73.
8. Chaisuparat R, Limpiwatana S, Kongpanitkul S, Yodsanga S, Jham BC. The Akt/mTOR pathway is activated in verrucous carcinoma of the oral cavity. *J Oral Pathol Med*. 2016;45:581–5.