



Original Article

Laser pilonidotomy — a new approach in management of complex pilonidal sinus disease: an exploratory study



Ashwin Porwal ^{a,*}, Paresh Gandhi ^b, Deepak Kulkarni ^c

^a Consultant Colorectal Surgeon, Healing Hands Clinic, Pune, India

^b Consultant Surgeon, Healing Hands Clinic, Pune, India

^c Consultant Proctologist and Enterologist, Healing Hands Clinic, Pune, India

ARTICLE INFO

Article history:

Received 8 September 2019

Accepted 6 October 2019

Available online 1 November 2019

Keywords:

Pilonidal sinus

Pilonidal cyst

Sacrococcygeal pilonidotomy

Laser pilonidoplasty

Recurrent pilonidal sinus

ABSTRACT

Background: The treatment of pilonidal sinus disease still remains challenging mainly because of multiple factors responsible for wound healing and its recurrence. With recent advances in surgical field, use of laser found to be an effective technique in the destruction of a pilonidal cyst. Laser Pilonidotomy is a new promising technique.

Methodology: An exploratory study was planned with the Aim, to evaluate a new technique for the excision of pilonidal sinus. Objectives were to investigate its effectiveness in terms of operation time, healing time, and the duration of hospitalization, resumption of normal activity the degree of postoperative complications and rate of recurrence and patient's satisfaction. All the patients with pilonidal sinus were categorized and laser pilonidotomy was planned for patients satisfying inclusion criteria. Data collected in pre-structured, pre-tested proforma and analyzed using SPSS.

Results: Mean duration of Procedure was 33 min (SD = 11), mean duration of Hospital Stay was 12 h (SD = 3), resumption of normal activity within 4 days (SD = 2), mean duration for Complete Wound Healing by secondary intention 6 Weeks (SD = 1.25). Among complications, infection reported in 1.08%. The difference between the mean pre and post-operative VAS score was statistically highly significant ($p < 0.0001$). Recurrence rate was 3.24%. Success rate was 96.75% and Overall patient's satisfaction was 97.84%.

Conclusion: Laser Pilonidotomy is effective in destruction of a pilonidal cyst with good success rate, fewer complications and with high patient's satisfaction.

© 2019 Sociedade Brasileira de Coloproctologia. Published by Elsevier Editora Ltda. This is an open access article under the CC BY-NC-ND license (<http://creativecommons.org/licenses/by-nc-nd/4.0/>).

* Corresponding author.

E-mail: drashwinporwal@healinghandsclinic.co.in (A. Porwal).

<https://doi.org/10.1016/j.jcol.2019.10.007>

2237-9363/© 2019 Sociedade Brasileira de Coloproctologia. Published by Elsevier Editora Ltda. This is an open access article under the CC BY-NC-ND license (<http://creativecommons.org/licenses/by-nc-nd/4.0/>).

Pilonidotomia a laser — uma nova abordagem no tratamento da doença do seio pilonidal complexo: um estudo exploratório

R E S U M O

Palavras-chave:

Seio pilonidal
Cisto pilonidal
Pilonidotomia sacrococcígea
Pilonidoplastia a laser
Seio pilonidal recorrente

Justificativa: O tratamento da doença do seio pilonidal ainda permanece desafiador, principalmente devido a vários fatores responsáveis pela cicatrização das feridas e sua recorrência. Com os recentes avanços no campo cirúrgico, o uso do laser mostrou ser uma técnica eficaz na destruição de um cisto pilonidal. A pilonidotomia a laser é uma nova técnica promissora.

Metodologia: Foi planejado um estudo exploratório com o objetivo de avaliar uma nova técnica para a excisão de seio pilonidal. Os objetivos foram investigar sua eficácia quanto aos tempos de operação, de cicatrização, de internação e de retomada da atividade normal, além do grau de complicações pós-operatórias, a taxa de recorrência e o índice de satisfação do paciente. Todos os pacientes com seio pilonidal foram categorizados, e a pilonidotomia a laser foi planejada para os pacientes que satisfizessem os critérios de inclusão. Os dados foram coletados em forma pré-estruturada e pré-testada e analisados usando o SPSS.

Resultados: O tempo médio do procedimento foi de 33 min (DP=11), o tempo médio da internação hospitalar foi de 12 horas (DP=3), o tempo médio de retomada da atividade normal foi de 4 dias (DP=2) e o tempo médio de cicatrização completa por intenção secundário foi de 6 semanas (DP=1,25). Entre as complicações, infecção foi observada em 1,08%. A diferença entre as médias do escore EVA pré e pós-operatório foi estatisticamente significativa ($p < 0,0001$). A taxa de recorrência foi de 3,24%. A taxa de sucesso foi de 96,75% e o índice de satisfação geral do paciente foi de 97,84%.

Conclusão: A pilonidotomia a laser é eficaz na destruição de um cisto pilonidal com boa taxa de sucesso, menos complicações e com alta satisfação do paciente.

© 2019 Sociedade Brasileira de Coloproctologia. Publicado por Elsevier Editora Ltda. Este é um artigo Open Access sob uma licença CC BY-NC-ND (<http://creativecommons.org/licenses/by-nc-nd/4.0/>).

Introduction

Pilonidal sinus disease is a chronic inflammation resulting from invasive hair into skin, mostly seen in sacrococcygeal natal cleft and usually presented by inflammation, abscess and sinus formation.¹ During the Second World War, pilonidal disease very commonly appeared in jeep drivers, Proctologist Louis Buie described it as, “jeep disease”.² The prevalence in Asia and Africa is less as compared to Europe and north America.³

Men of age 16–25 years are seen to be more prone for this condition.^{4,5} The onset of disease in adolescent can be correlated with pubertal hormonal effect as well as skin and hair changes. The familial tendency and genetic predisposition have also been reported. The condition is usually seen associated with obese^{6,7} and hirsute individuals who experience profuse sweating and have a sedentary lifestyle^{2,8} Local irritation or trauma has been reported as contributing factor while lack of personal hygiene does not appear to contribute.⁹

Clinical presentation may vary from asymptomatic inflammation, acute abscess to chronic condition characterised by complications like multiple sinus tracks.^{1,10,11}

It is an acquired condition in which hair, due to movements of buttock, is invaded into the skin of natal cleft¹² the foreign body reaction provoked by the broken or overturned hair leads to hair filled abscess cavity. This folliculitis is characterised by

mid line pits. During the period of chronic abscess and epithelial tube development from normal hair follicles, the disease may affect more than one follicle and lead to lateral fistulization outside the midline.^{13,14} The condition, though not life threatening, is socially embarrassing and adversely affect the quality of life of patients.¹

The ideal treatment for a pilonidal sinus varies according to the clinical presentation of the disease. For acute pilonidal abscess physicians focus more on conservative management while surgical management is required in chronic and complex or recurrent disease. Although the supporters of non-operative or conservative management point out that regardless of the therapy used, the pilonidal disease resolves after the age of 40 years. The parameter for the treatment choice are the stage of disease, the attitude of the patient toward the disease, patient's compliance and the preference of the surgeon.¹² Apart from many techniques available simple incision, excision, plastic surgery techniques & marsupialization are the most commonly used.¹⁵ It is a stubborn condition, disappointingly so for patient and surgeon alike.

Ideally, the method used to treat the patient should satisfy following goals:

- Wound healing with a low risk of recurrence;
- Short hospitalisation;
- Maximal patient comfort;
- Low morbidity, with few wound-management problems;
- Early resumption to normal daily activity.

Laser pilonidotomy is a new technique where ablation of the sinus tract is done by using radial laser fiber, one or two or maximum three 1 cm incisions are made to prevent collection of fluid and help efficient drainage, thus allowing faster wound healing with secondary intention with minimal recurrence rate and negligible pain.

Methodology

An Exploratory prospective study was planned with the aim, to evaluate a new technique for the treatment of pilonidal sinus — Laser Pilonidotomy. Objectives were to investigate its effectiveness in terms of operation time, healing time, and the duration of hospitalization, the degree of postoperative complications and rate of recurrence. An approval from the institutional ethical committee was obtained to conduct this study.

Patients suffering from pilonidal sinus disease reported at Healing hands Clinic, Pune from January 2013 to December 2017 were included. Patients were excluded from this study if any of the following was found:

- Pilonidal Sinus abscess with;
- Human immunodeficiency virus positive patients;
- Patients on cancer chemotherapeutic drugs;
- Patients on immunosuppressant therapy.

Furthermore, uncooperative or mentally ill patients were excluded. All eligible study subjects were categorized as per the classification suggested by Guner et al.¹⁴

Stage I: Single pit in the midline, no lateral extension.

Stage II: >1 pits in the midline, no lateral extension.

Stage IIa: 2–3 pits in the midline.

Stage IIb: >3 pits in the midline.

Stage III: Midline pit/pits plus lateral extension in one direction.

Stage IV: Midline pit/pits plus lateral extension in both directions (Stage R: Recurrent PSD following any type of treatment).

Laser Pilonidotomy was the procedure planned for all patients.

The procedure was fully and clearly explained to patients who also provided an informed consent before operation.

All patients were evaluated by clinical examination including digital rectal examination and a complete patient history was taken. Baseline investigations were performed to all patients including CBC, blood urea/sugar, hepatitis, full chemistry and coagulation profile.

The procedure:

Preoperative Preparation: Shaving the back;

Intra-operatively, patients were put on the operating table in Jackknife position;

The operative Procedure: All cases of laser Pilonidotomy were performed under local anaesthesia.

Step 1

Thorough evaluation of the lower back right from the Anal Verge to mid back.

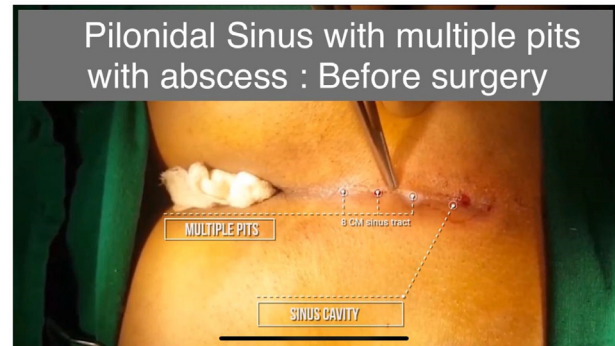
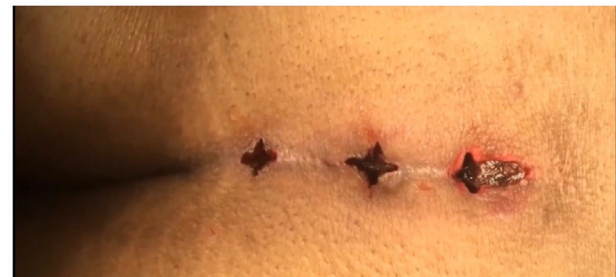

Fig. 1 – Tracing the sinus cavity.



Immediately after Laser Pilonidotomy

Fig. 2 – Debridement of sinus cavity.

Identify all the pits and associated abscess cavities. Missing one of the branches sinus tract or abscess cavity is common cause of recurrence (Fig. 1).

Step 2

Crisscross incision is taken over the abscess cavity. Debride it well.

Identify its connection with sinus.

Step 3

Try to scoop the sinus tract as much as possible (Fig. 2).

Use Radial Fibre to debride the sinus tract and abscess wall. Keep the setting at 8 W with 1470 nm diode laser. Deliver around 100J of energy per centimeter, withdraw the fiber by one centimeter and deliver another 100J of energy per centimeter till the entire length is debrided.

Step 4

Squeeze the fluid and muck out after laser debridement.

Flush it with normal saline and hydrogen peroxide.

Step 5

Make one crisscross incision at natal cleft for drainage through the pit.

If the Pilonidal Sinus is more than 4 cm long, make one additional crisscross incision in the centre of the sinus tract to prevent collection in the recovery period.

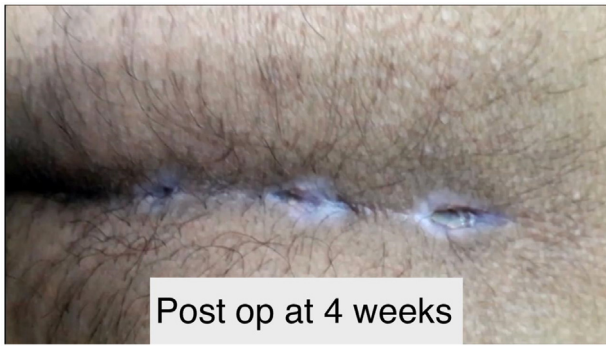

Fig. 3 – Post operative after 4 weeks.

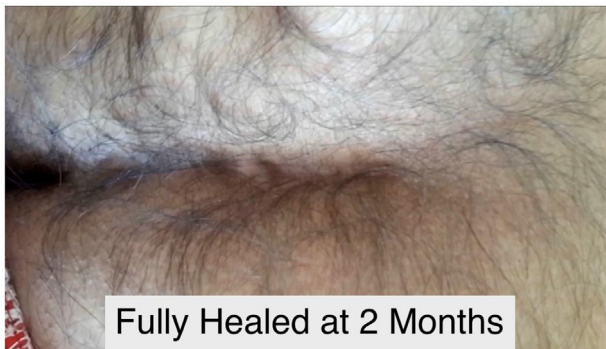


Fig. 4 – Fully healed sinus.

Step 6

Hemostasis achieved. Wound is kept open for drainage. No dressing. Patient is asked to use sanitary pad over it to absorb the drainage.

Follow up

- 1st follow up: Between 4–6 days;
- 2nd follow up: Between 12–17 days;
- 3rd follow up: 35–45 days (Figs. 3 and 4).

The wound is squeezed to drain the collection during follow up. Also it is ensured that the wound do not close prematurely at 2–3 wks.

The post-operative outcome was evaluated in terms of operation time, healing time, and the duration of hospitalization, the degree of postoperative complications and rate of recurrence. VAS score was used to evaluate pain while overall patient’s satisfaction was assessed by using Likert’s scale. All study subjects were followed for 12 months. The data collected was analyzed using statistical package SPSS (version 25).

Results

As per Table 1, out of total 228 cases reported, majority (87.72%) were male. As per age distribution age group 18–35 has reported maximum number of cases (76.44%). The minimum age reported was 13 years in both female and male while maximum age reported was 44 and 68 respectively. The mean age was 26.82 in females (SD=8.43) and 27.21 in males

Table 1 – Age and sex wise distribution of study subjects.

Age	Female	Male	Total
N	28 (12.28%)	200 (87.72%)	228
Mean	26.82	27.21	27.16
SD	8.43	8.03	8.06
Max	44	68	68
Min	13	13	13

Table 2 – Background characteristics.

Sr n ^o	Characteristics	Number	Percentage
1	Occupation		
	Businessman	15	6.58%
	Doctor	6	2.63%
	Employed @ IT	62	27.19%
	Housewife	7	3.07%
	Student	102	44.74%
	Other	36	15.79%
2	Body Mass Index		
	<25	42	18.42%
	25–30	172	75.44%
	>30	14	6.14%
	BMI Mean = 26.14; SD = 3.09.		
3	Duration of complaints		
	<3 Months	97	42.54%
	3 Months – 1 Year	81	35.53%
	1–5 Year	34	14.91%
	>5 Year	16	7.02%
	Mean Duration		
	10.97 = months;		
	SD = 13.81 Months;		
	Range 7 Day – 6 Year.		
4	Presence of abscess drainage history		
	Yes	49	21.49%
	No	179	78.51%
5.	Most common presentation		
	1. Discharge	228	100%
	2. Pain	136	59.65%

(SD=8.03). Majority of patients were students (44.74%) followed by IT sector employee (27.19%). 75.44% patients were overweight. Mean duration of complaints was 10.97 months with range 7 days to 6 years. In most of the cases (78.51%) there was no history of abscess drainage. Discharge was presenting symptom in all cases (Table 2). Majority of patients were Stage III (54.39%) followed by Stage R (16.67%) and in most of the cases the recurrence was after flap surgery.

The outcome of Procedure is given in Table 3; local anaesthesia was used in all cases. Mean duration of procedure was 33.32 min (SD=6.49), duration of hospital stay was 12.25 h (SD=3.61), resumption of normal activity is 2.26 days (SD=0.62), mean duration for Complete Wound Healing by secondary intention was 6.44 weeks (SD=1.25). Among post-operative complications, infection (0.88%), collection (6.58%), Hypertropic scar (1.32%) and recurrence was reported in 2.63% of cases.

Post-operative follow up on day 5 and at 2 weeks is very important to prevent collection within the wounds. Patients who missed the follow up developed collection in the wound usually at 3–4 weeks due to premature closure of the skin wound. These patients presented with mild pain and swelling.

Table 3 – Outcomes of procedure.

Sr n ^a		Mean	SD	Rang
1	Duration of pocedure (Min)	33.32	6.49	12-65
2	Duration of Hospital Stay (Hr)	12.25	3.61	8-26
3	Resumption of normal activity (Day)	2.26	0.62	2-5
4	Complete Wound Healing by secondary intention occurs after (week)	6.44	1.25	5-12
5	Wound complications	N	%	
	1. Infection	2	0.88%	
	2. Collection	15	6.58%	
	a) Stage III	3	1.32%	
	b) Stage IV	4	1.75%	
	c) Stage R	8	3.51%	
	3. Dehiscence	0	0.00%	
	4. Tip necrosis	0	0.00%	
	5. Hypertropic scar	3	1.32%	
7	Recurrence	6	2.63%	

Table 4 – VAS score analysis.

	Pre-operative	Day 1	Day 3	Day 7	p-Value
Mean	7.11	5.74	3.93	1.96	<0.0001
SD	1.15	1.15	0.93	0.54	

*t-test was used to calculate significant diff between pre-operative and after 7 days of surgery VAS Score.

Table 5 – Patients satisfaction index (scale in 1-5).

Score	Number of patients	Percentage (%)
1	0	0%
2	0	0%
3	6	2.63%
4	34	14.91%
5	188	82.46%
Total	228	

*Likert Scale/Score Assessment: 1, very dissatisfied; 2, dissatisfied; 3, Ok; 4, satisfied; 5, very satisfied.

The collection was drained under local anaesthesia on OPD basis by widening the skin incision.

Patients who developed discharge from the surgery site after 6 months from the surgery were labeled as recurrent cases. They were operated again with laser Pilonidotomy under local anaesthesia. Eventually they recovered well. All he patients were followed for 12 months. Overall success rate was 97.37%.

The difference between the mean pre-operative VAS score and VAS score on Day 1, 3 and 7 was statistically highly significant ($p < 0.0001$) (Table 4). In overall satisfaction, 98.25% of patients were highly satisfied (Table 5).

Discussion

Pilonidal sinus is a chronic inflammatory condition that affects young and healthy individuals mostly. It is not a life threatening disease but affects productivity of a person as this chronic condition has tendency to recur. Even though it is an extensively researched entity with clear aetiopathogenesis, a definitive management is still a challenge.

A number of surgeries have been listed in literature. Surgical treatment is frequently complicated by: 1) Surgical Site Infection (SSI); 2) delayed or failed wound healing; 3) pain and protracted convalescence; and 4) recurrence of disease.¹⁶ Recurrence is the main drawback reported in surgical procedures while flap surgeries have reported lesser recurrence as compared to classic excision. In recent years, reports of laser epilation in the pilonidal sinus disease have shown beneficial effect by decreasing the risk of recurrent Pilonidal sinus disease.^{7,13,17}

In the present study, majority of the patients were male (87.72%) and from the most productive age group, i.e. 20-35 years and the mean age was 26.82 in females (SD=8.43) and 27.21 in males (SD=8.03). Studies conducted by Khan et al.,¹⁸ Priyadarshi,¹⁹ Kement et al.²⁰ showed similar finding, while mean age was 27.16 in study conducted by Nada et al.¹

Maximum number of respondents was students followed by IT industry employees, 7.08% were obese and almost 75% were overweight. Occupation and lifestyle play an important role in causation and recurrence of PSD. Studies conducted by Priyadarshi,¹⁹ Çubukçu²⁹ also observed similar findings. A review study conducted by Hosseini²⁷ stated similar findings. Most of the patients (54.39%) were in Stage III (midline pits with one lateral extension) followed by recurrent stage (16.67%). The mean duration of symptoms was 10.97 months (SD=13.8) and 49 (21.49%) had history of previous drainage. For decades, standard definitive care has consisted of excision with either secondary healing or primary closure of the wound; these approaches were originally derived largely from military hospital experience with "Jeep riders' disease".^{16,21,22} There are innumerable reported approaches to the surgical management of PD, raging in complexity from simple drainage to intricately designed multi-flap closures.¹⁶

There is a definitive trend towards less invasive procedures for the treatment of pilonidal disease, with equivalent or better outcomes compared with classic excision.¹⁶ Laser pilonidoplasty is one of the effective treatment in which he energy delivered by laser causes the destruction of the sinus epithelium and the simultaneous obliteration of the tract.

A retrospective series of 40 patients treated with the FILAC™ radially laser probe between 2014 and 2015 documented

an 87.5% success rate with 2.9% recurrence. The mean follow-up period was 234 days. Four patients presented with complications: 2 hematomas (5%) and 2 abscesses (5%), which were all medically treated.^{16,23}

A retrospective review of 70 patients that underwent epilation utilizing the Sharplan laser probe included patients with acute abscesses as well as those with inflamed or chronic pilonidal disease.^{16,24} Their technique involved a small incision overlying the diseased area, hair removal and curettage and instillation of hydrogen peroxide. The laser probe was then used on the affected tissue. The small wound was packed and patients were followed for an average of 12 months. The overall recurrence rate was 11.4%. Of these recurrences, half were treated with another laser procedure while 4% went on to wide local excision. Complications included pain, bleeding, and skin bridging in 5.7% of patients.

A retrospective series of 37 patients who underwent Nd:YAG laser treatment from 2006 to 2009 included patients who underwent laser treatment of pits at 1 month intervals for an average of 5.1 months. At follow-up, 28 of the 37 patients (75.7%) reported no symptoms without additional interventions, and 30 patients (81%) were symptom-free after further laser treatment and minimal surgery. The median follow-up time was 15.2 months. Some patients described temporary soreness and redness at the site of laser treatment.^{16,25}

Recurrence is the main concern in the management of PSD. Previously it was thought that the remnant of sinus tract after surgery could be the cause of recurrence in most of the cases but the recent research has stated that it could be related to acquisition of new disease.²⁶

Many of the cases of pilonidal sinus disease show tendency of repeated infection and collection of fluid. Developing post-operative infection and presence of secondary sinus are also risk factors for recurrence.^{27,28}

In laser pilonidotomy procedure, a laser was used to ablate the sinus tract and multiple incisions were taken (Fig. 3) to prevent collection and facilitate drainage of fluid collected, if any, during the follow up period. This helped in management of recurrent cases as well.

The duration of procedure was 33.32 min (SD = 6.49), mean duration of hospital stay was 12.25 h (SD = 3.61), resumption of normal activity was within 2 days (SD = 0.62), mean duration for complete wound healing was about 6 weeks (SD = 1.25) and overall satisfaction was 98.25%. The procedure is less invasive with short duration of hospitalization and early resumption of daily routine. The systematic review conducted by Grabowski et al.¹⁶ stated that less invasive procedures are generally preferred by patients over wide excision in terms of time to return to work, overall satisfaction, and quality of life. Post-operative complications were negligible. Only 0.88% reported infection which was treated. Collection of fluid was reported in 8.11% of cases, most of them were recurrent cases with history of surgical procedures, mostly flap surgery. The collection was drained during follow up. The multiple incisions taken helped in draining the fluid and faster wound healing. The recurrence rate was 2.63% which is much lesser than that with the flap procedures²⁸ as well as those with use of laser.^{25,26} Similar recurrence was seen in a Belgian retrospective study conducted by Dessily et al.²⁴ where laser pilonidoplasty was done in 40 patients.

In the present study, we found that the procedure, laser pilonidotomy is effective in complete wound closure and fast wound healing with relatively low risk of recurrence. It has added benefits of short period of hospitalization, no painful dressings, low post-operative morbidity, and early resumption to normal daily activity. Overall maximum patient comfort with 97.37% of success rate.

Conclusion

Laser Pilonidotomy is a simple, minimally invasive procedure which can be easily performed under local anaesthesia. It is associated with short duration of hospitalization, negligible pain, minimal complications and early resumption to work. The overall patient's satisfaction and success rate of Laser pilonidotomy is good. Considering the negligible recurrence rate, this procedure can be offered as an effective treatment of pilonidal sinus, especially Complex & Recurrent cases. Though a long term follow up study with controlled modifiable risk factors is highly recommended.

Conflicts of interest

The authors declare no conflicts of interest.

Acknowledgement

Authors would like to thank Dr. Rizwan Khan, General Surgeon, HHC Baner, for assistance in preparing this video and Dr. Swapna S Kadam, Consultant, Healing Hands Clinical Research, Pune for the review and suggestions. We would also like to thank the team of Healing Hands Clinic.

REFERENCES

- Nada M, Said TM. Pilonidal sinus excision: new vision. *Surgery Curr Res.* 2016;6:274.
- Buie LA. Classic articles in colonic and rectal surgery. 1890-1975: Jeep disease (pilonidal disease of mechanized warfare). *Dis Colon Rectum.* 1982;25:384–90.
- Chijiwa T, Suganuma T, Takigawa T, Edogawa S, Inoue K, Yanagida S, et al. Pilonidal sinus in Japan maritime self-defense force at Yokosuka. *Mil Med.* 2006;171:650–2.
- Karydakos GE. New approach to the problem of pilonidal sinus. *Lancet.* 1973;2:1414–5.
- Clothier PR, Haywood IR. The natural history of the post anal (pilonidal) sinus. *Ann R Coll Surg Engl.* 1984;66:201–3.
- Bascom J. Surgical treatment of pilonidal disease. *BMJ.* 2008;336:842–3.
- Menzel T, Dorner A, Cramer J. Excision and open wound treatment of pilonidal sinus. Rate of recurrence and duration of work incapacity. *Dtsch Med Wochenschr.* 1997;122:1447–51.
- Kronborg O, Christensen K, Zimmermann-Nielsen C. Chronic pilonidal disease: a randomized trial with a complete 3-year follow-up. *Br J Surg.* 1985;72:303–4.
- Sondenaa K, Andersen E, Nesvik I. Patient characteristics and symptoms in chronic pilonidal sinus disease. *Int J Colorectal Dis.* 1995;10:39–42.
- Surrell JA. Pilonidal disease. *Surg Clin North Am.* 1994;74:1309–15.

11. Loganathan A, Arsalani Zadeh R, Hartley J. Pilonidal disease: time to reevaluate a common pain in the rear! *Dis Colon Rectum*. 2012;55:491–3.
12. <http://bestpractice.bmj.com/bestpractice/monograph/1146/basics/pathophysiology.html>.
13. Bascom J, Bascom T. Failed pilonidal surgery: new paradigm and new operation leading to cures. *Arch Surg*. 2002;137:1146–50, discussion 1151.
14. Guner A, Cekic AB, Boz A, Turkyilmaz S, Kucuktulu U. A proposed staging system for chronic symptomatic pilonidal sinus disease and results in patients treated with stage-based approach. *BMC Surg*. 2016;16:18.
15. Varnalidis I, Ioannidis O, Paraskevas G, Papapostolou D, Malakozis SG, Gatzos S, et al. Pilonidal sinus: a comparative study of treatment methods. *J Med Life*. 2014;7:27–30.
16. Grabowski J, Oyetunji TA, Goldin AB, Baird R, Gosain A, Lal DR, et al. The management of pilonidal disease: A systematic review. *J Pediatr Surg*. 2019, <http://dx.doi.org/10.1016/j.jpedsurg.2019.02.055> [Epub ahead of print].
17. Gandhi JA, Shinde PH, Pandrowala SA, Digarse RD. A modified surgical approach to sacrococcygeal pilonidal disease: our experience. *Int Surg J*. 2016;3:1831–6.
18. Khan A. Prognostic factors of pilonidal sinus. *J Med Sci*. 2006;14:40–3.
19. Priyadarshi S, Dogra BB, Nagare K, Rana KV, Sunkara R, Kandari A. A comparative study of open technique and Z-plasty in management of pilonidal sinus. *Med J DY Patil Univ*. 2014;7:574–8.
20. Kement M, Oncel M, Kurt N, Kaptanoglu L. Sinus excision for the treatment of limited chronic pilonidal disease: results after a medium-term follow-up. *Dis Colon Rectum*. 2006;49:1758–62.
21. Nesselrod JP. Pilonidal disease; a plea for simplification of its surgical management. *Q Bull Northwest Univ Med Sch*. 1946;20:407–10.
22. Fitzpatrick EB, Chesley PM, Oguntoye MO, Maykel JA. Pilonidal disease outcomes following surgery on a military population: how far have we really come? *J Surg Res*. 2013;179:339.
23. Dessily M, Charara F, Ralea S, Allé JL. Pilonidal sinus destruction with a radial laser probe: technique and first Belgian experience. *Acta Chir Belg*. 2017;117:164–8.
24. Klin B, Heller ON, Kaplan I. The use of the CO₂ laser in pilonidal sinus disease: preliminary results of an ambulatory prospective study. *J Clin Laser Med Surg*. 1990;8:31–7.
25. Lindholt-Jensen CS, Lindholt JS, Beyer M, Lindholt JS. Nd-YAG laser treatment of primary and recurrent pilonidal sinus. *Lasers Med Sci*. 2012;27:505–8.
26. Tekin A. A simple modification with the Limberg flap for chronic pilonidal disease. *Surgery*. 2005;138:951–3.
27. Hosseini SV, Rezazadehkermani M, Roshanravan R, Muzhir Gabash K, Aghaie-Afshar M. Pilonidal disease: review of recent literature. *Ann Colorectal Res*. 2014;2:e19705.
28. Colov EP, Bertelsen CA. Short convalescence and minimal pain after out-patient Bascom's pit-pick operation. *Dan Med Bull*. 2011;58:A4348.
29. Cubukçu A, Gönüllü NN, Paksoy M, Alponat A, Kuru M, Ozbay O. The role of obesity on the recurrence of pilonidal sinus disease in patients, who were treated by excision and Limberg flap transposition. *Int J Colorect Dis*. 2000;15:173–5.