



Technical notes

Rectal prolapse repair via vaginal route

Héber de Oliveira Morsch^{a,*}, Iuri Martin Goemann^b

^aDepartment of Obstetrics and Gynecology, Fundação Hospitalar de Rolante, Rolante, RS, Brazil

^bCollege of Medicine, Universidade Federal do Rio Grande do Sul (UFRGS), Porto Alegre, RS, Brazil

ARTICLE INFO

Article history:

Received 8 August 2012

Accepted 9 December 2012

Keywords:

Rectal prolapse

Genital dystopia

Surgical technique

Minimally invasive surgery

Vaginal surgery

Palavras-chave:

Prolapso retal

Distopia genital

Técnica cirúrgica

Cirurgia minimamente invasiva

Cirurgia vaginal

ABSTRACT

Many elderly patients have concomitant anorectal, urological and gynecological symptoms involving multiple perineal structures, which require the surgeon to operate in different areas of his specialty in order to correct different dystopias in a single procedure. We describe a technique for total rectal prolapse correction offering low surgical risk for patients presenting with this pathology along with pelvic floor defects. We used a simple, minimally invasive technique, which showed complete success in the postoperative follow-up. The patients showed no peri- and post-operative complications and were discharged briefly after the procedure. Although it was a small sample, there was no case of rectal prolapse recurrence with the technique described. With the procedure described here, the treatment of rectal prolapse is possible with concomitant pelvic reconstruction in a single procedure, which is an interesting approach for elderly patients commonly affected by both diseases, as these patients often have other comorbidities that increase the perioperative risk.

© 2013 Elsevier Editora Ltda. All rights reserved.

Reparo do prolapso retal via vaginal

R E S U M O

Muitos pacientes idosos possuem concomitância de sintomas anorretais, urológicos e ginecológicos, envolvendo múltiplas estruturas perineais e obrigando o cirurgião a atuar em áreas diversas à sua especialidade para que possa corrigir diferentes distopias em um único procedimento. Descrevemos aqui uma técnica de correção de prolapso total de reto que oferece baixo risco cirúrgico a pacientes que se apresentam com tal patologia juntamente com defeitos do assoalho pélvico. Utilizamos uma técnica simples, minimamente invasiva e que demonstrou sucesso total no acompanhamento pós operatório. Os pacientes não apresentaram intercorrências peri- e pós- operatórias, e tiveram breve tempo de internação hospitalar após o procedimento. Embora em amostra pequena, não obtivemos nenhum caso de recorrência do prolapso retal com a técnica descrita. Com o procedimento aqui descrito, é possível o tratamento do prolapso retal concomitante à correção da distopia genital em um único procedimento sendo tal abordagem interessante na população idosa comumente afetada pelas duas patologias, uma vez que tais pacientes frequentemente apresentam outras comorbidades que aumentam o risco perioperatório.

© 2013 Elsevier Editora Ltda. Todos os direitos reservados.

* Corresponding author.

E-mail: hebermorsch@brturbo.com.br (H.O. Morsch)

Introduction

Currently, the advances of gynecological surgery in the field of pelvic reconstruction have been remarkable. Genital dystopias are treated in order to reposition the anatomical structures into its original places, avoiding as much as possible unnecessary removal of organs. These procedures are becoming less invasive and risky, and the results are showing aesthetic, functional, and anatomical improvement.^{1,2}

Changes in female pelvic floor are often complex. Several studies have found an increased prevalence of evacuative symptoms in patients with genital dystopias, especially pelvic organ prolapse and exertion-induced urinary incontinence.³⁻⁵ Many elderly patients have concomitant anorectal, urological, and gynecological symptoms involving multiple structures, which require the surgeon, or even gynecologist, to act in different areas of his specialty in order to provide the patient with a real solution to his problem. Most of these patients are evaluated and treated individually, sometimes undergoing two or more surgical procedures, which significantly increases the risk of complications and morbidity, as it is the elderly population that is usually affected by these diseases.

Total rectal prolapse repair is surgical, and various techniques have been developed, basically involving transabdominal or perineal approaches.^{6,7} Although different procedures have been described, there is no single method that has excelled others.^{7,8} Moreover, there are few studies evaluating the surgical approach of both genital dystopias and anorectal prolapse and, therefore, there are no recommendations for an optimal treatment of these patients. Lately, abdominal rectopexy has been advocated as the treatment of choice for total rectal prolapse, particularly after the emergence of laparoscopic techniques,⁹ which benefit the elderly who often is at high risk for performing open surgery.

In spite of the various techniques developed to correct rectal prolapse, the recurrence rate is still high. Some studies show recurrence rates of up to 47%.¹⁰ Thus, it would be interesting to have a minimally invasive technique that offers low surgical risk for patients with rectal prolapse, with or without genital dystopia. Techniques for rectal prolapse repair via transvaginal route have been described, but with a high recurrence rate.^{11,12} We describe a technique used to treat some patients who presented to our clinic with total rectal prolapse and pelvic floor defects. We use a simple, minimally invasive technique with complete success in the postoperative follow-up.

Objective

Describe a new surgical technique for rectal prolapse management via vaginal route.

Operative description

The surgery begins as a posterior colpoperineoplasty, with the opening and dissection of the posterior vaginal wall to access the rectovaginal space (inverted-t incision). The rectum wall is exposed, and rectocele and enterocele is repaired if necessary.

The levator ani muscle is penetrated bilaterally toward the ischial spines giving access to the pararectal space. The identification and bilateral exposure of sacrospinous ligaments are performed. A synthetic mesh measuring approximately 2 cm has one of its ends attached to the sacrospinous ligament with suture (we used polygalactin # 1). The mesh is transversely passed over the rectum while the other end is brought to the contralateral sacrospinous ligament. With the index finger, the surgeon places the free end of the mesh in contact with the sacrospinous ligament, adjusting the mesh on the rectum and checking for excess mesh at the end, which should be removed to adjust the mesh on the rectum without looseness.

The fixation of this end of the mesh on sacrospinous ligament is performed the same way as on the other side (Fig. 1). The prolapsed rectum is placed in its normal position. The levator ani muscles are tightly approximated to the rectum at midline. The bulbospongiosus muscles are also approximated at midline, leaving no room over the rectum. Finally, the superficial transverse perineal muscles are approximated at middle line, completing the reconstruction of a thick and resistant perineal body. If some rectal prolapse still persists, a rectal traction inside the vagina is performed to place it below the mesh, and the surgery is completed with the vaginal mucosa closure.

Discussion

The repair technique for rectal prolapse described above proved to be safe, simple, and minimally invasive. The patients had no peri- and postoperative complications and required a brief hospital stay after the procedure. Although it was a small sample, there was no case of rectal prolapse recurrence with the technique described.

With the procedure described here, the treatment of rectal prolapse is possible with concomitant pelvic reconstruction in a single procedure, which is an interesting approach for elderly patients commonly affected by both diseases, as these patients often have other comorbidities that increase the perioperative risk.

Conclusion

In conclusion, we propose a minimally invasive technique with the use of mesh for rectal prolapse repair. Other studies will help to determine more accurately the effectiveness of

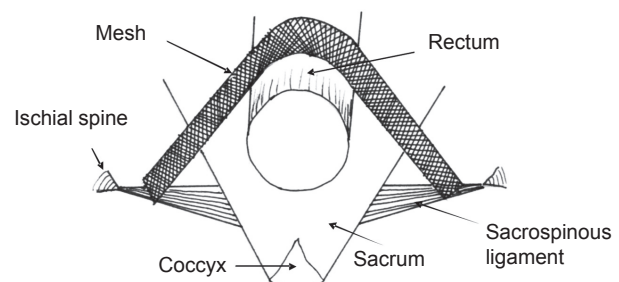


Fig. 1 – Schematic representation of mesh positioning during the surgical rectal prolapse repair via vaginal route.

this new surgical technique compared to the techniques currently used for rectal prolapse repair.

Conflict of interest

The authors declare no conflict of interest.

Acknowledgements

We would like to thank Dr. Angelica Pedroso Rodrigues for her assistance in the surgical procedures and the Fundação Hospitalar de Rolante, in the name of its Director Dr. Vilmar Moron, where the procedures were performed.

REFERENCES

1. Novel JL. Surgical Technique for the Treatment of Female Stress Urinary Incontinence: Transobturator Vaginal Tape Inside-Out. *European Urology* 2003;44:724-30.
2. Takacs EB, Kobashi KC. Minimally Invasive Treatment of Stress Urinary Incontinence and Vaginal Prolapse. *Urol Clin N Am* 2008;35:467-76.
3. Lawrence JM, Lukacz ES, Nager CW. Prevalence and cooccurrence of pelvic floor disorders in community-dwelling women. *Obstet Gynecol* 2008;111:678-85.
4. Gonzales-Argentè FX, Jain A, Noguerras JJ. Prevalence and severity of urinary incontinence and pelvic genital prolapse in females with anal incontinence or rectal prolapse. *Dis Colon Rectum* 2001;44:920-6.
5. Jelovsek JE, Barber MD, Paraiso MF, Walters MD. Functional bowel and anorectal disorders in patients with pelvic organ prolapse and incontinence. *Am J Obstet Gynecol* 2005;193:2105-11.
6. Wu JS. Rectal Prolapse: A Historical Perspective *Curr Probl Surg* 2009;46:602-716.
7. Karulf RE, Madoff RD, Goldberg SM. Rectal prolapse. *Curr Probl Surg* 2001;38:771-832.
8. Madiba TE, Baig MK, Wexner SD. Surgical management of rectal prolapse. *Arch Surg* 2005;140:63-73.
9. Cuesta MA, Borgstein PJ, de Jong D, Meijer S. Laparoscopic rectopexy. *Surg Laparosc Endosc* 1993;3:456-8.
10. DiGiuro G, Ignjatovic D, Brogger J, Bergamaschi R. How accurate are published recurrence rates after rectal prolapse surgery? A meta-analysis of individual patient data. *Am J Surg* 2006;191:773-8.
11. Maes U, Rives JD. An operation for complete prolapse of the rectum. *Surg Gynecol Obstet* 1926;42:594-9.
12. McCann FJ. Note on an operation for the cure of prolapse of the rectum in the female. *Lancet* 1928;1:1072-3