



Case Report

A combination treatment of transanal total mesorectal excision and Turnbull–Cutait abdominoperineal pull-through procedure for a low rectal cancer

Suleyman Utku Celik ^{a,*}, Omer Arda Cetinkaya ^b, Furkan Atakan Akin ^b,
Stéfano do Amaral Fiúza ^c, Ibrahim Ethem Gecim ^b

^a Gulhane Training and Research Hospital, Clinic of General Surgery, Ankara, Turkey

^b Ankara University School of Medicine, Department of General Surgery, Ankara, Turkey

^c Hospital Adventista Silvestre, Rio de Janeiro, RJ, Brazil

ARTICLE INFO

Article history:

Received 14 August 2018

Accepted 26 November 2018

Available online 21 December 2018

Keywords:

Colorectal cancer

Delayed coloanal anastomosis

Transanal total mesorectal excision

Turnbull–Cutait procedure

Palavras-chave:

Anastomose coloanal tardia

Câncer colorretal

Excisão total do mesorreto transanal

Técnica de Turnbull–Cutait

ABSTRACT

Surgical treatment for low rectal cancer has changed dramatically during the preceding several decades, and the optimal surgical approach remains incompletely developed. Transanal total mesorectal excision is likely the most promising approach for the dissection of the distal part of the mesorectum in a manner that allows for a technically easy and oncologically safe operation. Long after it was first described, the Turnbull–Cutait abdominoperineal pull-through procedure has recently been reintroduced in surgical practice for the treatment of patients with complex anorectal conditions. The current report describes a case of distal rectal cancer involving successful surgical treatment with a combination of the two aforementioned methods and patient discharge without a diverting stoma.

© 2018 Sociedade Brasileira de Coloproctologia. Published by Elsevier Editora Ltda. This is an open access article under the CC BY-NC-ND license (<http://creativecommons.org/licenses/by-nc-nd/4.0/>).

Um tratamento combinando a excisão total do mesorreto por via transanal e o “pull-through” abdominoperineal de Turnbull–Cutait para câncer de reto baixo

RESUMO

O tratamento cirúrgico para o câncer de reto baixo mudou drasticamente durante as últimas décadas, mas uma abordagem cirúrgica de excelência ainda continua incompletamente desenvolvida. A excisão total do mesorreto por via transanal parece ser a abordagem mais promissora para a dissecação da parte distal do mesorreto de forma a assegurar uma cirurgia

* Corresponding author.

E-mail: s.utkucelik@hotmail.com (S.U. Celik).

<https://doi.org/10.1016/j.jcol.2018.11.004>

2237-9363/© 2018 Sociedade Brasileira de Coloproctologia. Published by Elsevier Editora Ltda. This is an open access article under the CC BY-NC-ND license (<http://creativecommons.org/licenses/by-nc-nd/4.0/>).

oncológicamente segura com uma técnica simples. Muito depois de sua descrição, o *pull-through* abdominoperineal de Turnbull-Cutait tem sido reintroduzido na prática cirúrgica para o tratamento de pacientes com enfermidades anorretais complexas. Este relato descreve um caso de câncer de reto baixo que se beneficiou de um tratamento cirúrgico bem sucedido a partir da combinação das duas técnicas supracitadas com o paciente recebendo alta hospitalar sem ostomia de proteção.

© 2018 Sociedade Brasileira de Coloproctologia. Publicado por Elsevier Editora Ltda. Este é um artigo Open Access sob uma licença CC BY-NC-ND (<http://creativecommons.org/licenses/by-nc-nd/4.0/>).

Introduction

The management of adenocarcinomas in the lower rectum poses major challenges in terms of local tumor control and sphincter preservation.¹ Lower tumor sites are associated with more difficult surgical dissections, higher rates of morbidity, and poorer outcomes.² A diverting stoma is constructed in many cases involving low rectal anastomoses and reduces mortality, morbidity, and re-operation rates; however, the construction of a diverting stoma does not reduce the anastomotic leakage rate and necessitates a second hospital stay and additional surgery, with considerable patient management costs.³ Although stoma closure is regarded as a simple procedure, morbidity and even mortality are associated with this surgery.⁴

The Turnbull-Cutait (T-C) abdominoperineal pull-through procedure with delayed coloanal anastomosis (DCA) has recently been reintroduced in surgical practice, more than 50 years after this approach was first described.⁵ This procedure avoids stomas, reduces anastomotic leakage and presacral abscesses, and improves sphincter function preservation.^{5,6} Furthermore, advances in surgical techniques with the adoption of total mesorectal excision (TME) for rectal cancer have reduced local recurrence rates and improved oncological and functional outcomes.⁷ The introduction of transanal single-port surgery led to the transanal TME (TaTME) technique, in which the rectum is dissected transanally according to TME principles. Research has demonstrated that this technique for low and mid rectal cancer has potential benefits, including a low rate of circumferential resection margin (CRM) involvement, a low morbidity rate as a result of avoiding extraction wounds in most patients, and a higher number of sphincter-saving rectal resections that do not compromise oncological outcomes.^{7,8}

Here, we describe a case of rectal cancer located 3 cm from the anal margin in a 55 year-old female and its treatment via a two-stage process involving TaTME followed by colonic pull-through and a DCA procedure.

Case report

A 55 year-old woman presented to our clinic with a 2 week history of constipation and rectal bleeding. A digital rectal examination revealed an irregular mass in the anal canal located 3 cm from the anal verge. The only significant aspect of the patient's prior medical history was hypertension.

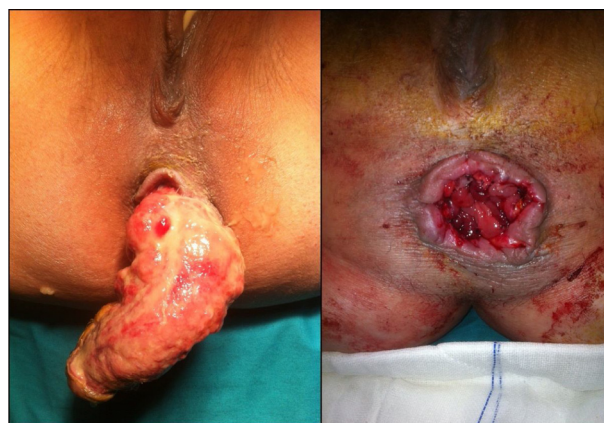

Fig. 1 – On the tenth day after the initial surgery, the exteriorized segment was amputated, and delayed coloanal anastomosis was performed.

Laboratory findings, including tumor markers, were unremarkable. A colonoscopy revealed an irregular ulcerated mass with hyperemia and ulceration located 3 cm from the anal verge. Biopsy confirmed the presence of adenocarcinoma of the rectum. An ¹⁸F-fluorodeoxyglucose-positron emission tomography/computed tomography scan obtained after neoadjuvant chemoradiotherapy revealed partial progression of the lesion with no distant metastasis.

After the aforementioned assessments, the patient underwent TaTME followed by a T-C DCA procedure in two surgical stages. The first stage involved intersphincteric resection in which the rectum was dissected transanally according to TME and exteriorization of the proximal colon was performed with no stoma. On the tenth day after the first-stage procedure, amputation of the exteriorized segment and DCA were performed, using a perineal transanal approach (Fig. 1). During the time between stages, the stump was enveloped in saline-soaked gauze, its viability was visually assessed daily, and the patient was fully ambulatory and resumed a low-residue diet to reduce the volume of feces passing through the pulled-through colonic stump. Pathologic examination revealed that the tumor was 4 mm from the lateral margin and more than a centimeter from the distal margin.

Despite a prolonged hospital stay and a temporary decline in quality of life, the patient has now been followed up regularly for 6 months and is currently disease-free, with no sphincter dysfunction and no stoma (Fig. 2). The patient had no low anterior resection syndrome (LARS) with the score of

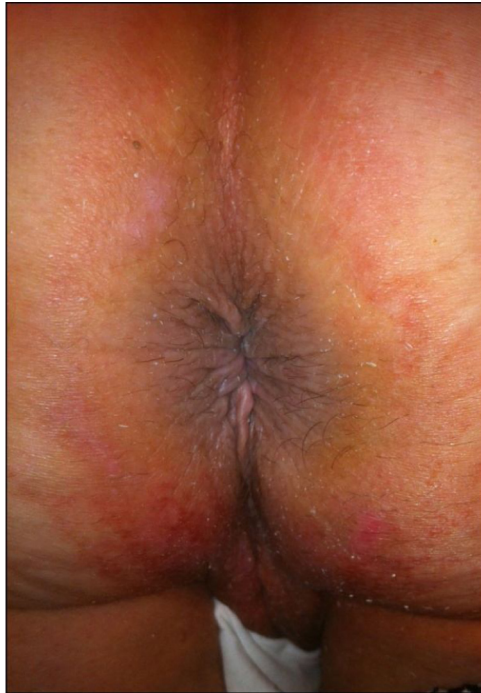


Fig. 2 – A follow-up image at three months after surgery that reveals a well-healed anastomosis with no sphincter dysfunction.

7 and had normal urogenital function (no urinary or sexual dysfunction). In addition, the patient's Wexner incontinence score was 3 at last follow-up.

Discussion

Colorectal cancer is a common type of malignancy and remains the third most common cause of cancer death worldwide.⁹ Surgery is the cornerstone of curative therapy for patients with resectable rectal adenocarcinoma. Tumors in the upper and middle rectum can be managed via anterior resection, coloanal anastomosis and preservation of the anal sphincter with TME. However, surgical treatment for low rectal cancer is controversial.¹ These challenges are illustrated by rates of abdominoperineal resection (APR) in rectal cancer cases, which vary from 5% to 55% in the United Kingdom depending on institution and area.^{1,10}

Over the past 100 years, due to an increased understanding of the pathophysiology of rectal cancer, improved technology, and surgical innovations, surgical treatment for rectal cancer has evolved from APR to various surgical options and novel techniques, including sphincter-sparing procedures such as low anterior resection (LAR) or ultralow anterior resection with TME, transanal endoscopic microsurgery with local excision, and T-C pull-through with DCA.^{11,12} Currently, TME has become the gold standard for the treatment of rectal cancer because relative to other approaches, TME produces substantially improved local recurrence and survival.^{8,13}

TaTME is a promising approach for the dissection of the distal part of the mesorectum and is now the focus of considerable interest. To date, this technique appears to be feasible,

technically easy, and oncologically safe in the treatment of rectal cancer.^{7,13} Compared with other techniques, TaTME with dissection upwards from the bottom also increases specimen quality and decreases the risk of adverse injury by ensuring that an adequate view of the lower part of the mesorectum is obtained during the operation.¹³ Moreover, with this approach, 2 year local recurrence is observed at a low rate of approximately 0%–5%.⁷ A transanal approach to rectal dissection allows for wider resection margins and increases the rate of sphincter-saving procedures.^{7,8,13} In a recent study, Denost et al. evaluated 100 patients with low rectal cancer who had undergone a sphincter-saving procedure (“open” transanal rectal dissection or laparoscopic abdominal low rectal dissection). The rate at which a positive CRM was obtained was significantly lower in the transanal group than in the laparoscopic group (4% vs. 8%, $p=0.025$).¹⁴ This difference is crucial because the retrieval of lymph nodes a less important pathological variable than mesorectum quality and CRM.¹³

T-C pull-through with DCA was first described by Turnbull and Cutait for the treatment of rectal cancer, Hirschsprung's disease, and megacolon in Chagas disease. The T-C procedure has not typically been preferred for the treatment of low pelvic anastomoses since advanced stapler technology can now be effectively applied. Current indications for the T-C procedure include a previous failed anastomosis, an irradiated pelvis, chronic inflammation with complex fistulae connecting the rectum to surrounding organs, or a reoperated pelvis with a chronic infection that causes ongoing sepsis.^{6,11} This procedure theoretically reduces anastomotic leaks and improves sphincter function preservation because it allows for adhesion between the serosa of the distal colonic segment and the anal canal. The avoidance of a permanent stoma is the most significant benefit of this procedure because stoma closure can involve morbidity or even mortality.^{4,5} However, up to 75% of patients after a sphincter-sparing procedure (i.e. LAR) can experience difficulties in bowel function such as fecal incontinence, increased intestinal gas, emptying difficulties, and urinary or sexual dysfunction which are collectively known as LARS and this may impact their quality of life. Functional results of the patients can be evaluated using scoring systems including Wexner incontinence score and LARS score.^{6,11,15} Although some degree of improvement can be elicited in patients, some symptoms can persist for years postoperatively.¹¹

Jarry et al. reported a 2% leak rate and a 6% pelvic abscess rate when the T-C DCA procedure was utilized for the primary management of distal rectal carcinoma.¹⁵ In 2009, Remzi et al. reported a prospective case-matched study that compared a mixed cohort of 44 patients undergoing salvage or primary DCA with 88 patients undergoing immediate anastomosis; significantly lower rates of anastomotic leaks (3% vs. 7%; $p<0.05$) and pelvic abscesses (0% vs. 5%; $p<0.05$) were observed with DCA than with immediate anastomosis. The two groups exhibited comparable levels of bowel function, which was evaluated using the Wexner score, and quality of life, which was evaluated using SF-36.⁶

In the current study, a procedure that combines TaTME with T-C DCA without a diverting stoma is presented. The main advantage of this combined technique was that the avoidance of a covering stoma significantly improved the

patient's quality of life and led to better oncological and functional outcomes. This approach also allowed the patient to receive early chemotherapy. However, relative to other approaches, this combined procedure was associated with a longer operating time and a prolonged hospital stay. In addition, LARS and Wexner scores indicated that no severe bowel dysfunction was observed after the surgical interventions.

In conclusion, TaTME combined with the T–C DCA procedure can prevent future complications and allow for the preservation of gastrointestinal continuity with acceptable functional and quality-of-life results for the majority of patients.

Conflicts of interest

The authors declare no conflicts of interest.

REFERENCES

- Rullier E, Denost Q, Vendrely V, Rullier A, Laurent C. Low rectal cancer: classification and standardization of surgery. *Dis Colon Rectum*. 2013;56:560–7.
- Law WL, Chu KW. Anterior resection for rectal cancer with mesorectal excision: a prospective evaluation of 622 patients. *Ann Surg*. 2004;240:260–8.
- Hüser N, Michalski CW, Erkan M, Schuster T, Rosenberg R, Kleeff J, et al. Systematic review and meta-analysis of the role of defunctioning stoma in low rectal cancer surgery. *Ann Surg*. 2008;248:52–60.
- Cipe G, Erkek B, Kuzu A, Gecim E. Morbidity and mortality after the closure of a protective loop ileostomy: analysis of possible predictors. *Hepatogastroenterology*. 2012;59:2168–72.
- Hallet J, Bouchard A, Drolet S, Milot H, Desrosiers E, Lebrun A, et al. Anastomotic salvage after rectal cancer resection using the Turnbull–Cutait delayed anastomosis. *Can J Surg*. 2014;57:405–11.
- Remzi FH, El Gazzaz G, Kiran RP, Kirat HT, Fazio VW. Outcomes following Turnbull–Cutait abdominoperineal pull-through compared with coloanal anastomosis. *Br J Surg*. 2009;96:424–9.
- Muratore A, Mellano A, Marsanic P, De Simone M. Transanal total mesorectal excision (taTME) for cancer located in the lower rectum: short- and mid-term results. *Eur J Surg Oncol*. 2015;41:478–83.
- Fernández-Hevia M, Delgado S, Castells A, Tasende M, Momblan D, Díaz del Gobbo G, et al. Transanal total mesorectal excision in rectal cancer: short-term outcomes in comparison with laparoscopic surgery. *Ann Surg*. 2015;261:221–7.
- Wu J. Rectal cancer staging. *Clin Colon Rectal Surg*. 2007;20:148–57.
- Morris E, Quirke P, Thomas JD, Fairley L, Cottier B, Forman D. Unacceptable variation in abdominoperineal excision rates for rectal cancer: time to intervene? *Gut*. 2008;57:1690–7.
- Bordeianou L, Maguire LH, Alavi K, Sudan R, Wise PE, Kaiser AM. Sphincter-sparing surgery in patients with low-lying rectal cancer: techniques, oncologic outcomes, and functional results. *J Gastrointest Surg*. 2014;18:1358–72.
- Marwan K, Staples MP, Thursfield V, Bell SW. The rate of abdominoperineal resections for rectal cancer in the State of Victoria, Australia: a population-based study. *Dis Colon Rectum*. 2010;53:1645–51.
- Kang L, Chen WH, Luo SL, Luo YX, Liu ZH, Huang MJ, et al. Transanal total mesorectal excision for rectal cancer: a preliminary report. *Surg Endosc*. 2015;30:2552–62.
- Denost Q, Adam JP, Rullier A, Buscaïl E, Laurent C, Rullier E. Perineal transanal approach: a new standard for laparoscopic sphincter-saving resection in low rectal cancer, a randomized trial. *Ann Surg*. 2014;260:993–9.
- Jarry J, Faucheron JL, Moreno W, Bellera CA, Evrard S. Delayed colo-anal anastomosis is an alternative to prophylactic diverting stoma after total mesorectal excision for middle and low rectal carcinomas. *Eur J Surg Oncol*. 2011;37:127–33.