



Case report

## New surgical approach of retrorectal cystic hamartoma using transanal minimally invasive surgery (TAMIS)



Pablo Colsa Gutiérrez\*, Mahgol Kharazmi Taghavi, Rocío Daniela Sosa, Angel Pelayo Salas, Victor Jacinto Ovejero, Jose Luis Ruiz, Jose Manuel Gutiérrez Cabezas, Alfredo Ingelmo Setián

Service of General and Gastrointestinal Surgery, Sierrallana Regional Hospital, Cantabria, Spain

ARTICLE INFO

Article history:

Received 15 March 2014

Accepted 11 August 2014

Available online 6 September 2014

Keywords:

Cystic hamartoma

Tailgut cyst

Retrorectal tumor

Minimally-invasive surgical procedures

ABSTRACT

**Introduction:** Tailgut cysts or cystic hamartomas are rare developmental tumors of the pre-sacral space. Their true incidence is not well known but we must think on it when we have a patient with a multicystic uncapsulated tumor at presacral space. Tailgut cysts are often asymptomatic, and in other cases present with chronic perineal pain, constipation or rectal tenesmus. They must be treated to avoid complications such as infections (perianal fistula or abscess) and malignant degenerations (usually adenocarcinoma).

**Case report:** One patient with anal pain was diagnosed with a perianal abscess. He was operated but at the second month review a MRI revealed a multilocular lesion in the presacral suggesting the presence of a retrorectal cystic hamartoma.

An elective operation was performed by endoanal surgical approach using TAMIS. En bloc resection of the cyst was achieved with safe margins. The pathology result reported retrorectal cystic hamartoma. The patient was asymptomatic with no signs of recurrence in subsequent controls.

Our experience, despite being based on one case, is evidence that TAMIS (Transanal Minimally Invasive Surgery) allows a minimally invasive dissection with similar benefits as the use of TEM/TEO devices.

© 2014 Sociedade Brasileira de Coloproctologia. Published by Elsevier Editora Ltda. All rights reserved.

### Nova abordagem cirúrgica do hamartoma cístico retrorretal usando cirurgia transanal minimamente invasiva (TAMIS)

R E S U M O

**Introdução:** Tail gut cysts ou hamartomas císticos são tumores raros de desenvolvimento do espaço pré-sacral. Sua verdadeira incidência não é bem conhecida, mas devemos pensar

Palavras-chave:

Hamartoma cístico

\* Corresponding author.

E-mail: [Pablocolsa@hotmail.com](mailto:Pablocolsa@hotmail.com) (P.C. Gutiérrez).

<http://dx.doi.org/10.1016/j.jcol.2014.08.004>

2237-9363/© 2014 Sociedade Brasileira de Coloproctologia. Published by Elsevier Editora Ltda. All rights reserved.

Tailgut cyst  
Tumor retrorretal  
Procedimentos cirúrgicos  
minimamente invasivos

nele quando temos um paciente com um tumor uncapsulated multicística no espaço pré-sacral. Hamartomas císticos são muitas vezes assintomáticas, em outros casos, apresenta-se com dor perineal crônica, constipação ou tenesmo retal. Eles devem ser tratados para evitar complicações, como infecções (fístula perianal ou abscesso) e degenerações malignas (geralmente adenocarcinoma).

*Relato de Caso:* Um paciente com dor anal foi diagnosticado com um abscesso perianal. Ele foi operado, mas na revisão do segundo mês uma ressonância magnética revelou uma lesão multilocular no pré-sacral, sugerindo a presença de um hamartoma cístico retrorretal.

Uma operação eletiva foi realizada por abordagem cirúrgica endoanal usando TAMIS. A resseção em bloco do cisto foi conseguido com margens seguras. O resultado do exame patológico relatou hamartoma cístico retrorretal. O paciente encontrava-se assintomático, sem sinais de recidiva em controles posteriores.

A nossa experiência, apesar de ser baseado em um dos casos, as provas que TAMIS (cirurgia transanal minimamente invasiva) permite um esvaziamento minimamente invasivo com benefícios similares como o uso de dispositivos de MET/TEO.

© 2014 Sociedade Brasileira de Coloproctologia. Publicado por Elsevier Editora Ltda.

Todos os direitos reservados.

## Introduction

Retrorectal cystic hamartomas are rare congenital tumors derived from the regression of the tailgut, which normally regresses during the seventh or eighth week of the embryonic phase.<sup>1</sup>

Most hamartomas are non-symptomatic retrorectal multicystic masses and usually appear in middle-aged women. Surgery is required to treat hamartomas. Multiple surgical approaches have been described, primarily due to location of the tumor and attendant difficulties.

We present a case of a retrorectal hamartoma cystic in a young male patient, who debuted with a perianal abscess and was surgically treated using a transanal approach. We conclude with an examination of clinical series and reviews found in the literature using the PubMed electronic database.

## Case report

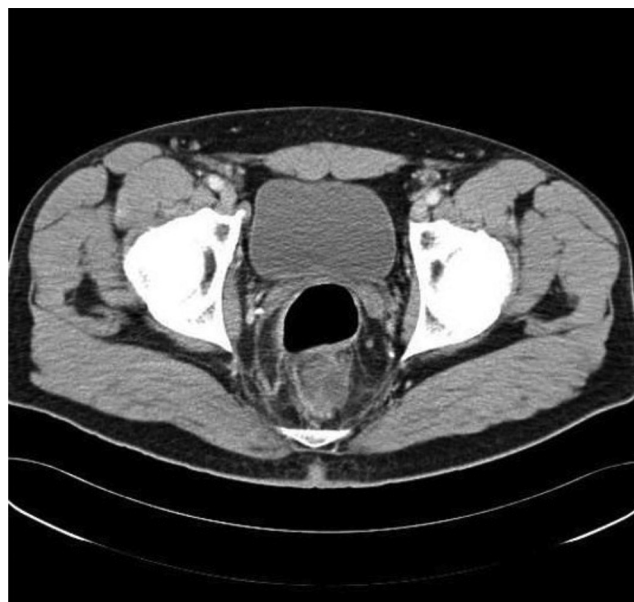A 24-year-old male arrived at the emergency room complaining of anal pain that worsened over several months. He had previously received ambulatory care, where he was diagnosed with an anal fissure and treated symptomatically. Despite treatment, the patient continued to complain of anal pain.

The patient had been treated in the emergency room on two prior occasions. On the second occasion, he suffered from a 38 °C fever and anal incontinence, which progressed to liquid overnight.

On physical examination, the patient's abdomen was soft and painless; the DRE (digital rectal examination) was not possible because of pain.

A pelvic CT scan was reported as a heterogeneous hypodense image of 3 cm × 3 cm × 6 cm in the recto-sacrum space compatible with an over the levator ani muscle abscess (Fig 1).

The patient was diagnosed with a perianal abscess and decided to operate. Using an endoanal surgical approach,

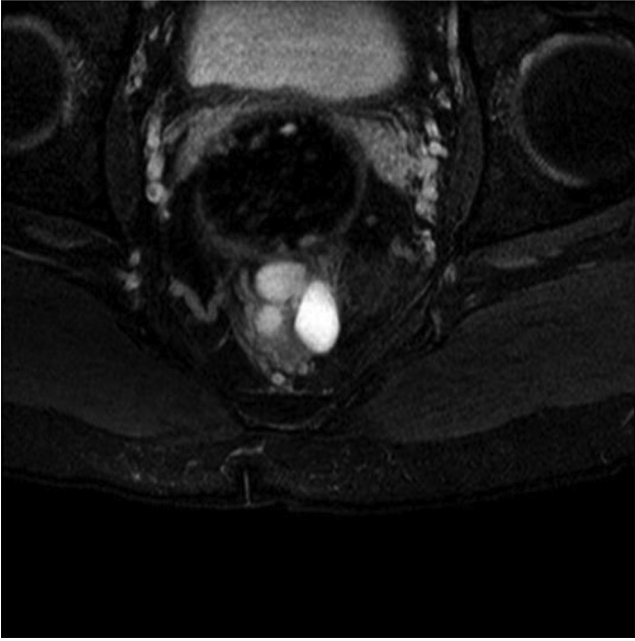


**Fig. 1 – Heterogeneous hypodense image in the recto-sacrum space compatible with abscess in pelvic CT scan.**

palpation discovered a fluctuating cystic mass on, and extracted a transparent, odorless and mucoid substance.

The patient was seen in consultation one week after surgery. Despite being feverless, the patient still complained of discomfort on defecation and tenesmus. Subsequent examinations were scheduled in order to continue the study.

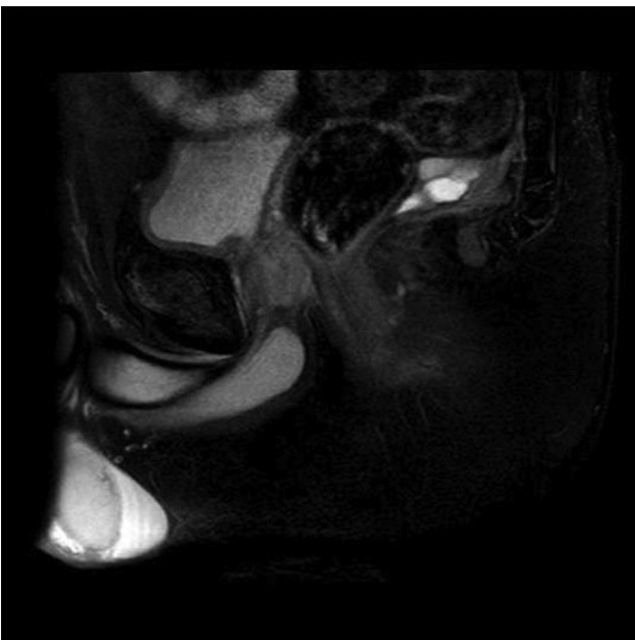
At the second month review the wound was closed. An MRI revealed a multilocular lesion of 3 cm × 3.5 cm × 1.7 cm in the presacral space with hyperintense signal in T2 and hypointense signal in T1, suggesting the presence of a mucoid content cyst (Figs. 2 and 3). These findings, along with the information obtained during the previous surgery, led us to



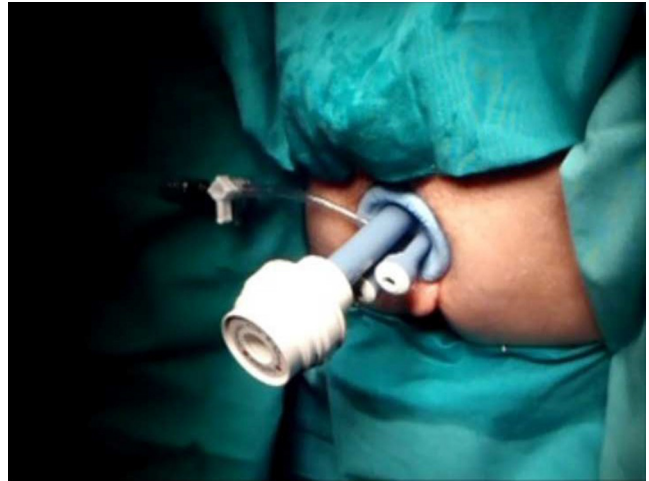
**Fig. 2 – MRI revealed a multilocular cystic mass in the presacral space.**

consider whether the patient suffered from a retrorectal cystic hamartoma.

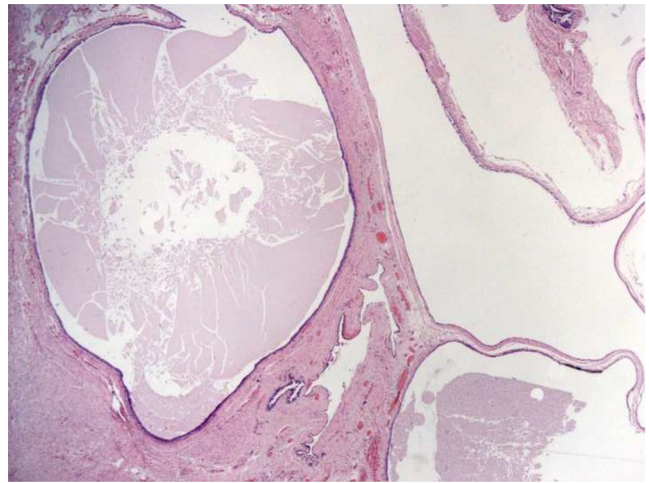
An elective operation was performed. Given the previous history, we chose an endoanal surgical approach using TAMIS (Fig. 4). En bloc resection of the cyst was achieved with safe margins. The pathology result reported retrorectal cystic hamartoma (Fig. 5). The patient was discharged on the second day following the operation, and was asymptomatic with no signs of recurrence in subsequent controls.



**Fig. 3 – Sagittal T2-weighted magnetic resonance scan suggested the presence of a mucid content cyst.**



**Fig. 4 – Endoanal surgical approach using TAMIS (Transanal Minimally Invasive Surgery).**



**Fig. 5 – The pathology result reported different types of epithelia without crypts or villi surrounded by a discontinuous muscle layer.**

## Discussion

### Retrorectal tumors

The Pre-sacrum or retrorectal space is located between the rectum, the pre-sacrum fascia, the lateral ligaments, the peritoneal reflection, and the Waldeyer fascia. It usually contains structures derived from neuroectoderm, notochord, gut and embryological remnants.

The true incidence of embryonal tumors in the retrorectal space is not known because reported findings tend to be incidental to findings of asymptomatic lesions.

Predominance in females has been subject to considerable debate, with some claims that this finding could be due to regular gynecological and pelvic examinations.<sup>2,3</sup>

These tumors are mostly inflammatory lesions and developmental cysts,<sup>4</sup> but in this group we also find cystic hamartoma.

## Tailgut cysts

The tailgut cyst or cystic hamartoma is a tumor of the presacral space that was first described in 1885 by Middeldorf.<sup>5</sup> They derived from an embryonic remnant of the primitive bowel, as Hjerstad et al. postulated in the largest case review done to date.<sup>6</sup> If Hjerstad is correct, the anal margin merges with the primitive gut (tailgut) above its distal end. The outcome of this merger is a bag with squamous cubical epithelium in the presacral space.<sup>4,7</sup> Normally, this vestige regresses during embryonic development, but when this does not happen, a cystic hamartoma appears.

Patient symptoms vary and are related to the location, size, mass, and therefore infections of the cyst. Most tailgut cysts are asymptomatic findings during a clinical examination for other reasons (CTscan, MRI, Endorectal ultrasound, etc.) For some authors, 50% of hamartomas present with chronic perineal pain, constipation, rectal tenesmus (as we present in our case report), rectal bleeding or urinary rate changes. Fever, or signs of perianal suppuration in the perineum, suggests fistula, abscess and complications from cyst infection.<sup>6,8,9</sup> This is why many patients are diagnosed from retrorectal abscesses or from multiple interventions for recurrent perianal fistula.

## Diagnosis

On physical examination, most patients have palpable mass on DRE, which is a key consideration for any diagnosis. There is a sensibility that varies between 97%<sup>10</sup> and 75%<sup>2</sup> described for the DRE. In our case, the clinical picture debuted as a complication of infection that led to an initial misdiagnosis of a high perirectal abscess. Rectal examination was painful and whitish content oriented to the suspected diagnosis. A colonoscopy allowed examination of endoluminal injury, but barium enema was ineffective as no additional information is given. Imaging tests can sometimes be helpful, because the presence of a multicystic tumor, circumscribed and uncapulated at a presacral space level, leads to cystic hamartoma diagnoses as well. Within imaging tests we described the use of endoscopy, MRI or CT and eco-endoanal<sup>4</sup>; endoanal ultrasound is not useful. It only allows identification of the nature of the cyst (jelly type or watery type) and its relation to the surrounding areas.<sup>11</sup>

The CT shows a mass with clear edges and reveals liquid or soft tissue content. One rarely finds calcifications inside the thin wall.<sup>11</sup> In the case of a complicated cyst due to infection or malignization, we usually find uneven margins.<sup>1,11</sup>

The MRI imaging is important to determine the multiple cyst character of the tailgut and its relation to the adjacent structures. Typically the cyst will be hypointense in T1w and hyperintense in T2w sequence, and heterogeneous content can also be seen resulting from the mucine, proteic material or intracystic hemorrhage.<sup>11-13</sup> The T2 sequence of a cyst showing tracts inside is also characteristic of a hamartoma, as Kim et al. describes and similar to our case.<sup>12</sup> Another finding is the presence of a little peripheral cyst accompanying the hamartoma.<sup>7</sup> It is important to determine the uni- or multi-lobular nature of the cyst because this establishes the differential diagnosis between hamartoma or multilobular cystic lymphangioma versus other pre-sacrum cysts.

In any event, we should avoid the biopsy of the lesion because of a high risk of its local dissemination and its low outcome for diagnosis confirmation.

In our case, we drained the cyst through the anal lumen which did not avoid the lesion's reproduction two months later.

Once the surgical piece has been processed, pathology will show different types of epithelia without crypts or villi surrounded by a discontinuous muscle layer (Fig. 5). Super-infected cysts usually present wall fibrosis and loss of definition in the epithelial lining.

## Treatment

Treatment is based on complete resection of the lesion to avoid recurrence, infection or malignant degeneration.

The approach to the retrorectal space is latero-sacral, abdominal or perineal.

The latero-sacral parasacroccigeal approach is the most used one, because it allows a good exposition of the anus and the levator ani muscle plan.

The abdominal approach, either laparotomy or laparoscopy, is indicated only when large tumors are present or if the tumors grow upwards instead of downwards toward the pelvic area. The abdominal laparoscopic approach gives us the advantage of a finer mesorectum dissection. The perineal access is done with the patient in lithotomy position. Incision is performed on the perineal raphe to reach the retrorectal space. However all of these techniques have a high rate of morbidity.<sup>14,15</sup>

In the past few years, the use of endoanal procedures using TEM/TEO devices has increased to avoid morbidity.<sup>3,16-18</sup> However accessibility to these devices is restricted because of high cost and difficult learning curves.<sup>19</sup>

The TAMIS (Transanal Minimally Invasive Surgery) achieves similar benefits as the use of TEM/TEO devices.<sup>20</sup> TAMIS uses a single site device, like SILS (Covidien), which is lubricated and located in the anal canal manually. It has three sites where we can introduce two 5 mm and one 10 mm trocars (Fig. 4). The CO<sub>2</sub> gas goes through the single site device cannula, being careful not to exceed 18 mm Hg. In our series we use a 5 mm and 30 grades angulated optic and conventional laparoscopic material.

Both techniques try to reach a reasonable resection with the least amount of damage possible.

In this way, TAMIS has proven to be a reliable alternative to TEM/TEO with the same benefits at a lower cost.

## Conclusions

The tailgut is a tumor located in the presacral space. We must think of it as a perianal abscess with atypical characteristics. It can be complicated with perianal chronic fistula or malignization, underscoring the importance of complete resection. For this approach, several techniques have been described here. We conclude that TAMIS allows a minimally invasive high-quality dissection at a lower cost when compared to TEM.



---

## Conflicts of interest

The authors declare no conflicts of interest.

## REFERENCES

---

- Johnson AR, Ros PR, Hjerstad BM. Tailgut cyst: diagnosis with CT and sonography. *Am J Roentgenol.* 1986;147:1309–11.
- Buchs N, Taylor S, Roche B. The posterior approach for low rectal tumors in adults. *Int J Colorectal Dis.* 2007;22:381–5.
- Zoller S, Joos A, Dinter D, Back W, Horisberger K, Post S, Palma P. Retrorectal tumors: excision by transanal endoscopic microsurgery. *Rev Esp Enferm Dig.* 2007;99:547–50.
- Killingworth C, Gadacz TR. Tailgut cyst (retrorectal cystic hamartoma): report of a case and review of the literature. *Am Surg.* 2005;71:666–73.
- Middledorpf K. Zur Kenntniss der angeborenen sacralgeschwulst. *Virchows Arch.* 1885;101:37–44.
- Levert LM, Van Rooyen W, Van Den Bergen H. Cysts of the tailgut. *Eur J Surg.* 1996;162:149–52.
- Yang DM, Park CH, Jin W, Chang SK, Kim JE, Choi SJ, et al. Tailgut cyst: MRI evaluation. *Am J Roentgenol.* 2005;184:1519–23.
- Williams LS, Rojiani AM, Quisling RG, Mickle JP. Retrorectal cyst hamartomas and sacral dysplasia: MR appearance. *Am J Neuroradiol.* 1998;19:1043–5.
- La Quaglia MP, Feins N, Erakis A, Hendren WH. Rectal duplications. *J Pediatr Surg.* 1990;25:980–4.
- Jao SW, Beart Jr RW, Spencer RJ. Retrorectal tumors: mayor clinic experience, 1960–1979. *Dis Colon Rectum.* 1985;28:644–52.
- Prasant P, Uttam G, Peacock M. Retrorectal hamartoma: a ‘tail’ of two cysts. *Indian J Radiol Imaging.* 2010;20(May): 129–31.
- Kim MJ, Kim WH, Kim NK, Yun MJ, Park YN, Lee JT, et al. Tailgut cyst: multilocular cystic appearance on MRI. *J Comput Assist Tomogr.* 1997;21:731–2.
- Moulopoulos LA, Karvouni E, Kehagias D, Dimopoulos MA, Gouliamos A, Vlahos L. MR imaging of complex tail-gut cysts. *Clin Radiol.* 1999;54:118–22.
- Parks AG. A technique for excising extensive villous papillomatous changes in the lower rectum. *Proc R Soc Med.* 1968;61:441–2.
- Mellgren A, Sirivongs P, Rothenberger DA, Madoff RD, Garcia-Aguilar J. Is local excision adequate therapy for early rectal cancer? *Dis Colon Rectum.* 1999;43:1064–71.
- Palma P, Freudenberg S, Samuel S, Posts S. Transanal endoscopic microsurgery: indications and results after 100 cases. *Colorectal Dis.* 2004;6:350–5.
- Duek SD, Kluger Y, Grunner S, Weinbroum AA, Khoury W. Transanal endoscopic microsurgery for the resection of submucosal and retrorectal tumors. *Surg Laparosc Endosc Percutan Tech.* 2013;23:66–8.
- Serra Aracil X, Gómez Díaz C, Bombardó Junca J, Mora López L, Alcántara Moral M, Ayguavives Garnica I, Navarro Soto S. Surgical excision of retrorectal tumour using transanal endoscopic microsurgery. *Colorectal Dis.* 2010;12: 594–5.
- Van den Boezem PB, Kruyt PM, Stommel MW, Tobon Morales R, Cuesta MA, Sietses C. Transanal single-port surgery for the resection of large polyps. *Dig Surg.* 2011;28:412–6.
- Larach SW. Transanal endoscopic microsurgery (TEM) and transanal minimally invasive surgery (TAMIS). *Cir Esp.* 2012;90:418–20.