



# Journal of Coloproctology

www.jcol.org.br



## Original article

# Perineal colostomy: an option in the treatment of inferior rectal and anal canal cancer

Luciano P. Nogueira da Gama, Sander Dias Mota\*, Thiago de Almeida Flauzino, Flávia Lemos Moura Ribeiro, Giovanni José Zucoloto Loureiro, Rossini Cipriano Gama

Vitória Apart Hospital, Serra, ES, Brazil

### ARTICLE INFO

#### Article history:

Received 23 October 2013

Accepted 23 December 2013

#### Keywords:

Rectal cancer

Perineal colostomy

Colostomy

### ABSTRACT

**Introduction:** The surgical treatment of anorectal cancer is considered a challenging topic. Colostomy, temporary or permanent, can be a serious limiting factor with respect to the quality of life of cancer patients. Our goal is to study the clinical and surgical experience in patients with anorectal cancer, in whom we proceeded to abdominoperineal resection with a perineal colostomy at the anterior border of the incision resulting from the amputation of the rectum.

**Methods:** The medical records of patients undergoing abdominoperineal resection with perineal colostomy from January 1st, 1998 to July 1st, 2012 were analyzed retrospectively. **Results:** Twenty-seven patients were studied; 15 (55.56%) were male and 12 (44.44%) females, with a mean age of 56.3 years. The average length of hospital stay was 7.4 days. Complications included four (14.8%) prolapses of the perineal colostomy, which were surgically treated after the sixth month postoperatively, two (7.4%) partial suture dehiscescences of the perineal colostomy, treated with hyperbaric oxygen therapy, two (7.4%) stenoses of the perineal colostomy, treated with dilation, two (7.4%) incisional hernias and one (3.7%) urinary incontinence.

**Conclusion:** The perineal colostomy is a relatively new proposition, with acceptable morbidity rates. We understand that the perineal colostomy dismisses the use of a collection device, leaves no odor and allows the periodic application of enemas for colon cleansing, which prevents stoma incontinence. Another advantage is to enable the patient's return to a good social and work interaction; thus, it will be possible his (her) reintroduction into society.

© 2014 Sociedade Brasileira de Coloproctologia. Published by Elsevier Editora Ltda.

All rights reserved.

\* Corresponding author.

E-mail: sandereludi@hotmail.com (S.D. Mota).

2237-9363/\$ - see front matter. © 2014 Sociedade Brasileira de Coloproctologia. Published by Elsevier Editora Ltda. All rights reserved.

<http://dx.doi.org/10.1016/j.jcol.2013.12.004>

## Colostomia perineal: uma opção no tratamento do câncer do reto inferior e canal anal

### R E S U M O

**Palavras-chave:**  
Câncer de reto  
Colostomia perineal  
Colostomia

**Introdução:** O tratamento cirúrgico do câncer da região retoanal é considerado um tema desafiador. A colostomia, temporária ou definitiva, pode ser um sério limitador da qualidade de vida de pacientes oncológicos. Nosso objetivo é estudar a experiência clínico-cirúrgica em pacientes portadores de câncer retoanal, nos quais realizamos a amputação abdominoperineal e associamos uma colostomia perineal na borda anterior da abertura resultante da amputação do reto.

**Métodos:** Foram analisados, de forma retrospectiva, os prontuários de pacientes submetidos a amputação abdominoperineal do reto com colostomia perineal, no período de 01/01/1998 a 01/06/2012.

**Resultados:** Foram estudados 27 pacientes, 15 (55,56%) pacientes eram do sexo masculino e 12 (44,44%) do sexo feminino. com a idade média de 56,3 anos. O período médio de internação foi de 7,4 dias. As complicações incluem 4 (14,8%) prolapsos da colostomia perineal, as quais foram tratadas cirurgicamente após o sexto mês de pós-operatório, 2 (7,4%) deiscências parciais da sutura da colostomia perineal tratadas com oxigenioterapia hiperbárica, 2 (7,4%) estenoses da colostomia perineal, tratadas com dilatação, 2 (7,4%) hérnias incisionais e 1 (3,7%) incontinência urinária.

**Conclusão:** A colostomia perineal trata-se de uma proposição relativamente nova, com índices aceitáveis de morbidade. Entendemos que a colostomia perineal dispensa o uso de dispositivo coletor, não tem odor, permite que sejam feitas lavagens intestinais periódicas para limpeza do cólon, o que evita incontinência do estoma. Outra vantagem consiste em resgatar o paciente para um bom convívio social e laboral, buscando desta forma, reintroduzi-lo na sociedade.

© 2014 Sociedade Brasileira de Coloproctologia. Publicado por Elsevier Editora Ltda.

Todos os direitos reservados.

## Introduction

Colorectal cancer is a worldwide problem, with an annual incidence of about 1 million cases with a mortality of approximately 500,000 patients, while malignant tumors of the anus and anal canal are rare, not exceeding 2% of all tumors of large intestine. These are diseases associated with high healing rates when diagnosed early and when an appropriate radical treatment is done.<sup>1,2</sup>

The surgical treatment of anorectal cancer is considered a challenging topic, being cause of great motivation among coloproctologists. Colostomy, temporary or permanent, can be a serious limiting factor of the quality of life in cancer patients.<sup>1,2,3</sup> Despite the high rates of morbidity and mortality, its treatment involves the carrier of the disease, available technical conditions, tumour variations, experience of the surgical team and, beyond that, the awaiting of results after the treatment.

The recommended surgery by Ernest Miles in 1908 for treatment of anorectal cancer had complications around 40% and consisted in abdominoperineal rectal resection with permanent terminal colostomy in the abdominal area.<sup>4-7</sup>

Over the years, the emergence of staplers plus radiotherapy and chemotherapy caused many patients to get rid of an surgery that, in every way, is aggressive and mutilating. Fortunately, the number of cases has been decreasing every year, but those anorectal tumours which had not responded well to initial treatment remained with indication for radical surgical treatment.

In 1991, Prof. Alcino Lázaro da Silva, in an attempt to reduce the social, familial and marital marginalization, sexual difficulties, elimination of gases and lack of control in the emptying of the colon, called for the realization of the perineal colostomy with use of artifices to obtain some degree of continence or greater containment of faeces, thus seeking to reintroduce the patient in society.<sup>4,8,7</sup>

## Objective

If the surgeon noted some negative aspect in colostomy; if this procedure resulted in multiple serious complications; if the attempts to avoid such surgery were useless; if the experiences of continent colostomy were fruitless; if the irrigation is innocuous; or if somehow the attempts to create digestive rings (sphincters) help the patient, it should be left at the discretion of the surgeon the option for a new strategy — perineal colostomy.

Therefore, our goal was to study the clinical-surgical experience in patients with anorectal cancer, in whom we accomplished abdominoperineal resection with an associated perineal colostomy at the anterior border of the opening resulting from the amputation of rectum.

## Material and methods

Over the last decade, the coloproctology service of Apart Victoria Hospital and Hospital Santa Casa de Misericórdia de

Vitoria in Espirito Santo, Brazil, has been carrying out Miles surgeries with implantation of perineal colostomy and monitoring those patients treated with this operation.

Medical records of 30 patients who underwent abdominoperineal resection of rectum with perineal colostomy advocated by Prof. Acino Lázaro da Silva,<sup>4,7</sup> operated in our coloproctology service at Apart Victoria Hospital and Hospital Santa Casa de Misericórdia de Vitoria in Espirito Santo, Brazil, from January 1st, 1998 to July 1st, 2012, were analyzed retrospectively. Three patients who died of causes unrelated to cancer during the follow-up were not included in our study. Thus, 27 patients took part in the present study. Twenty-four (88.88%) patients had adenocarcinoma of the lower rectum, two (7.41%) patients had squamous cell carcinoma of the anal canal and one (3.7%) patient had extensive villous adenoma with high-grade dysplasia located in the lower rectum.

Fifteen (55.56%) patients were male and 12 patients (44.44%) female. The age ranged from 37 to 87 years, with a mean age of 56.3 years. Of these, 20 (74.07%) were white and 07 (25.93%) were brown.

The patients' diagnosis was established by rectosigmoidoscopy and colonoscopy with biopsy for patients with tumors of the lower rectum and anal canal. After confirmation of malignancy, all were staged with computed tomography of upper abdomen, pelvis and chest. According to the TNM Classification System of the Malignant Tumours,<sup>9</sup> patients with remote metastases (any T, any N, M1) and with those tumours directly invading other organs or structures and/or perforating peritoneal viscera (T4) were not treated with Alcino's technique.

Abdominoperineal resection with perineal colostomy, advocated by Professor Dr. Alcino Lázaro da Silva and published in 1991, was the technique proposed, and was used in almost all patients<sup>4,7</sup> after the introduction of a technical variation which will be described below.

Upon completion of the abdominoperineal resection according to all surgical and oncological principles, we started doing a perineal colostomy. To do so, a strict homeostasis of the pelvic region was needed. Then the transverse colon, hepatic flexure and left colon were mobilized in order to get good vascular viability and an adequate length of the colon to reach the perineum without any traction. In some cases, it was necessary to establish ligation of the middle colic artery. The next step consisted in building three circumferential valves at a distance of 10 cm from the distal edge of the colon and between valves.<sup>4,7</sup>

In the first six patients, the valves were constructed at a distance of 10 cm, but the presence of soiling was observed. We chose to reduce the distance between valves, using instead an interval of 5 cm from the distal edge of the colon. With these new measures, the soiling improved.

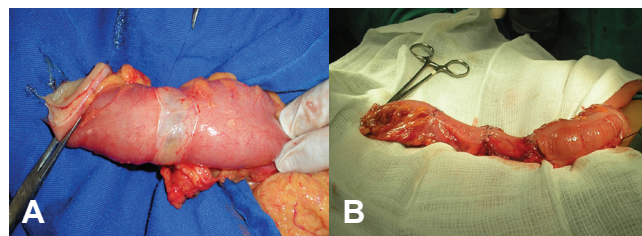
For the construction of the valves, a circular seromyotomy of almost 360° was produced, always trying to preserve the mucosa and mesocolon, in order not to affect the vasculature. Further, invaginant sutures were applied with simple stitches using 3-0 polypropylene, for the purpose of creating a valve to act as fecal containment apparatus<sup>4,7</sup> (Fig. 1 A and B).

After the construction of the valves and evaluation of the vascular feasibility, the colon was mobilized down to the

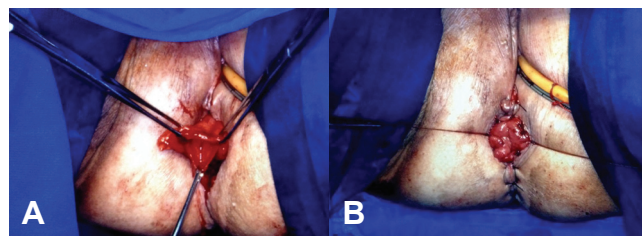
pelvis until reaching the perineum, where the colon was fixed to the skin in the form of a colostomy (Fig. 2 A and B). This diminished the dead space of the pelvis and positioned the bladder at the most anatomical way. A calibrous suction drain should be placed through the abdominal route, being located in the pelvic cavity; this device must be maintained for a period of 48 to 72 hours. Finally, we proceeded with the closure of the abdominal cavity.

In female patients with invasion of the posterior vaginal wall, the reconstruction should respect its anatomy; optionally, the anterior wall of the lowered colon may be used to reconstruct the posterior wall of vagina.<sup>4,7,8</sup>

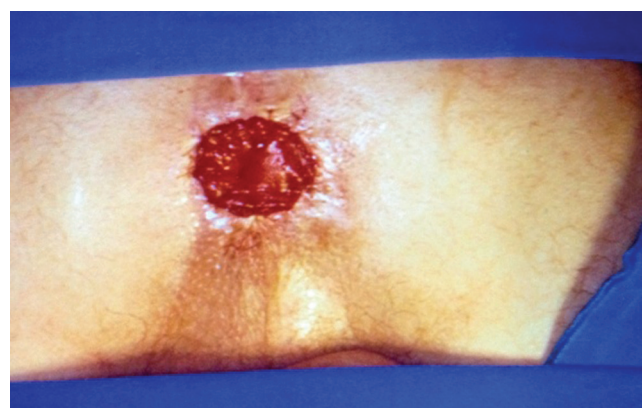
During the first 30 days after surgery, all patients are instructed to remain in orthostatic and/or decubitus position, thus avoiding the sitting position in order not to compromise the perineal colostomy implanted on the perineum. The end result can be seen in Fig. 3, and due to this relative immobility in bed, a prophylaxis for deep vein thrombosis was done over a period of 14 days in all patients.



**Fig. 1 – A, Seromyotomy. B, Final appearance of manufacture of valves**



**Fig. 2 – A, Colon lowered into the perineum. B, Suture of the colon in the perineum.**



**Fig. 3 – Perineal colostomy.**

## Results

The period of hospitalization ranged from six to 10 days, averaging 7.4 days. Morbidities, including all complications, were present in eight patients (29.62%). The complications included four (14.8%) perineal colostomy prolapses, which were surgically treated after the sixth month postsurgically, two (7.4%) partial suture dehiscences of the perineal colostomy, treated with hyperbaric oxygen therapy, two (7.4%) stenoses of the perineal colostomy, treated with dilation, two (7.4%) incisional hernias and one (3.7%) urinary incontinence.

As our study covers an extended period of time, 15 (55.55%) patients did not undergo neoadjuvant therapy; of these, 13 (86.66%) were referred for adjuvant treatment, while of the other 12 (44.44%) patients who underwent neoadjuvant therapy,<sup>10</sup> only six (50%) underwent adjuvant treatment. It was observed that two (7.4%) patients presented complete pathological response to neoadjuvant therapy, i.e., signs of cancer in the surgical specimen were not found.

After undergoing abdominoperineal amputation of the rectum with abdominal colostomy, one patient developed massive paracolostomic hernia. After this, it was not possible for this patient to get along with abdominal colostomy. A reversion of abdominal colostomy to perineal colostomy, with surgical correction of the paracolostomic hernia, was proposed and successfully performed.

Despite the contribution of valves to the fecal continence, our patients are instructed to follow a constipating diet; besides, they should use loperamide and intestinal irrigation, instituted from the 30th day after surgery with one to two liters of warm water. The local hygiene is done under the guidance of medical and nursing staff, consisting of cleaning with water and neutral soap, followed by application of a cotton or absorbent towel, in order to capture the mucus eliminated by mucosa.

By now, four (14.81%) patients are not resorting to enema or antidiarrheals; however, they are able to evacuate naturally. The remainder (23 patients) practice autoirrigation twice a week and keep a constipating diet; for 15 (55.55%) of these patients, medication with loperamide 1 to 2 times/day is needed.

In the follow-up of these patients, only one (3.7%) of them had recurrence affecting the retroperitoneal lymph nodes, that was treated with retroperitoneal lymphadenectomy. The monitoring of this case has been done for five years in an out-patient basis. The remainder are periodically monitored, with no recurrences to date.

## Discussion

A proper preparation of a stoma is vital for the quality of life of the patient; for this reason, the physician must explain the procedure in detail, the reasons for this choice, and whether this will be a temporary or a permanent stoma, explaining the possible complications and the necessary care in the handling and maintenance of the stoma.

Psychosocial and sexual aspects of ostomy patients are relevant in the routine of their life. For the adaptation of the

patient in the face of this new context, a multidisciplinary participation comprised of physicians, nurses, psychologists and stomatherapists, which must be skilled professionals in handling the stomata, is required. Furthermore, they should promote measures and stoma care right from the pre-operative period.<sup>11</sup>

The continent perineal colostomy is an alternative in cases of rectoanal resection, positioning the colon down to the pelvis with perineum externalization, where the fixation is done, like a neo-anus, thus avoiding the abdominal colostomy.

As noted, the morbidities are acceptable and may be treated without major complications. The peri- and postoperative mortality rates were very low in our study.

Patients who undergo neoadjuvant therapy are benefited with downstaging and downsizing, allowing complete resection of tumours and longer life expectancy, compared with those who were not treated with neoadjuvant therapy. Currently, with the advent of neoadjuvant therapy, the number of amputations is decreasing year after year, as it is possible in some cases to promote sphincter preservation, enabling very low resections and reconstructions through coloanal anastomoses.

The perineal colostomy created by Prof. Alcino Lazaro da Silva diminished the number of complications related to abdominal colostomy (for instance, paracolostomic hernia, depression or prolapse of colostomy, presence of odor, and dermatitis, among others). Moreover, there is no need to use a collection bag, which somehow increases the costs to the patient and to the healthcare system.

This is a relatively new proposition, with acceptable morbidity rates; but so far no study has been published with a significant number of patients for comparison of results. And for the establishment of this technique as a method of choice, it is necessary to perform functional studies on perineal colostomy and on systematic assessments of the degree of satisfaction of these patients, compared with patients with abdominal colostomy.

But it is noteworthy that the perineal colostomy circumvents the use of a collection device, removes the odor, and allows the periodic application of enemas for colon cleansing, which prevents stoma incontinence. Another advantage is the patient's return to social life and to work, thereby seeking his (her) reintegration into society.

## Conflicts of interest

The authors declare no conflicts of interest.

## REFERENCES

1. Cruz GMG. Câncer nos Cóloons. Livro Texto "Coloproctologia", Volume II – "Coloproctologia – Propedêutica Nosológica", Editora Revinter, Rio de Janeiro, RJ, ISBN C85-7309-335-8, 1999; VII; 055: 835-879.
2. Instituto Nacional do Câncer (INCA), Ministério da Saúde. Estimativas 2010. Incidência de Câncer no Brasil. Disponível em: <http://www.inca.gov.br/estimativa/2010>.
3. World Gastroenterology Organisation. International Digestive Cancer Alliance (IDCA) Practice Guidelines: Triagem do Câncer Colorretal. 2007.

4. Silva AL. Amputação abdômino-perineal com colostomia perineal. *Rev bras Colo-Proct*, 1991; 11(3):105-108.
5. Miles WE. A method of performing abdominoperineal excision for carcinoma of the rectum and the terminal portion of the pelvic colon. *Lancet* 1908; 2:1812-13 (dec).
6. Barata AM. Considerações sobre estomas entéricos – Parte I: aspectos históricos e seu planejamento. *Rev Port Colo-Proct*, 2009; 1:34-37.
7. Silva AL. Tratamento do cancer retoanal. São Paulo: Editora Atheneu, 1998.
8. Silva AL. Amputação abdômino-perineal mais colostomia paravaginal no tratamento do câncer retoanal. *Rev bras Colo-Proctol*, 2009; 29(4):497-500, out-dez.
9. TNM classification of malignant tumors. 5. New York: Wiley; 1997. pp. 66–69.
10. Habr-Gama A, de Souza PM, Ribeiro U Jr, et al. Low rectal cancer: Impact of radiation and chemotherapy on surgical treatment. *Dis Colon Rectum*. 1998;41:1087–1096.
11. Rocha JJR. Estomias intestinais – (ilestomias e colostomias) e anastomoses intestinais. *Medicina (Ribeirão Preto)* 2011;44(1):51-6.