



## Inflammatory myopathies in childhood: correlation between nailfold capillaroscopy findings and clinical and laboratory data

Ana K. S. Nascif,<sup>1</sup> Maria T. R. A. Terreri,<sup>2</sup> Cláudio A. Len,<sup>2</sup>  
Luis E. C. Andrade,<sup>3</sup> Maria O. E. Hilário<sup>4</sup>

### Abstract

**Objective:** Nailfold capillaroscopy is an important tool for the diagnosis and follow-up of patients with rheumatic diseases, in particular dermatomyositis and scleroderma. A relationship has been observed in adults between improved capillaroscopic findings and reduced disease activity. Our aim was to correlate disease activity (clinical and laboratory data) and nailfold capillaroscopy findings in 18 patients with inflammatory myopathies.

**Methods:** This prospective study included 13 juvenile dermatomyositis patients (Bohan and Peter criteria) (mean age of 8.8 years) and five patients with overlap syndrome (mean age of 15.7 years). We evaluated disease activity (skin abnormalities and muscle weakness, muscle enzymes and acute phase reactants) and its correlation with nailfold capillaroscopy findings (dilatation of isolated loops, dropout of surrounding vessels and giant capillary loops). We used a microscope with special light and magnification of 10 to 16X.

**Results:** Eighteen patients underwent a total of 26 capillaroscopic examinations, seven of them on two or more occasions (13 were performed during the active disease phase and 13 during remission). Twelve of the 13 examinations performed during the active phase exhibited scleroderma pattern and 8 of the 13 examinations performed during remission were normal. Therefore, in 20 of the 26 examinations clinical and laboratory data and nailfold capillaroscopy findings correlated ( $p = 0.01$ ).

**Conclusions:** Nailfold capillaroscopy is a non-invasive examination that offers satisfactory correlation with disease activity and could be a useful tool for the diagnosis and follow-up of inflammatory myopathies.

*J Pediatr (Rio J). 2006;82(1):40-5: Nailfold capillaroscopy, juvenile dermatomyositis, inflammatory myopathies, children.*

### Introduction

As juvenile idiopathic inflammatory myopathies are a relatively heterogenous group of diseases that have muscle involvement as a factor in common. Juvenile dermatomyositis (JDM) is the most common idiopathic

inflammatory myopathy in childhood and is characterized by acute and chronic multisystemic alterations with non-suppurative lymphocytic inflammation of the skeletal musculature, the skin and the gastrointestinal tract. The juvenile form is associated with vascular disease that affects the small vessels: capillaries, venules and small arterioles.<sup>1</sup>

The etiology of JDM is unknown. The pathogenesis of this disease does, however, involve autoimmune processes; cell-mediated immune system abnormalities and the presence of immunocomplexes have been described.<sup>2-6</sup>

The clinical course of JDM is variable and correlates with the severity of the vascular disease.<sup>7</sup> The majority of children follow a single cycle of a non-progressive clinical course that lasts months and ends in complete remission,<sup>8-10</sup> although exacerbations with partial remission can take place. Some patients present a

1. Pós-graduanda, Universidade Federal de São Paulo (UNIFESP), São Paulo, SP, Brasil.
2. Professor assistente, Departamento de Pediatria, UNIFESP, São Paulo, SP, Brasil.
3. Professor adjunto, Departamento de Medicina, UNIFESP, São Paulo, SP, Brasil.
4. Professora adjunta, chefe da Disciplina de Alergia, Imunologia Clínica e Reumatologia, Departamento de Pediatria, UNIFESP, São Paulo, SP, Brasil.

Manuscript received Apr 19 2005, accepted for publication Aug 24 2005.

**Suggested citation:** Nascif AK, Terreri MT, Len CA, Andrade LE, Hilário MO. Inflammatory myopathies in childhood: correlation between nailfold capillaroscopy findings and clinical and laboratory data. *J Pediatr (Rio J)*. 2006;82:40-5.

chronic or persistent form whose duration is measured in years.<sup>11-12</sup>

Diagnoses of JDM is based on criteria defined by Bohan & Peter.<sup>13</sup> There may be concurrence between myositis and scleroderma, which is known as overlap syndrome, or manifestations of cutaneous involvement may occur in the absence of muscular involvement, known as amyopathic dermatomyositis.<sup>14,15</sup>

The microangiopathy characteristic of inflammatory myopathies can be confirmed by nailfold capillaroscopy (NFC). This is a noninvasive examination in which the capillary bed is studied with an optical microscope with a magnification of 10 to 16 times.<sup>16,17</sup> Several articles have described capillaroscopy findings in the various forms of collagenosis, such as JDM, scleroderma, mixed connective tissue disease (MCTD), overlap syndrome and Raynaud's syndrome.<sup>18-27</sup> Patients with JDM, scleroderma, mixed connective tissue disease (MCTD) or overlap syndrome exhibit typical capillaroscopy findings. Scleroderma pattern (SD) reflects the degree of severity of microangiopathic involvement and therefore of disease activity as well. It is characterized by the presence of dilatation (ectasia) of isolated loops or giant capillaries and avascular lesions indicating capillary deletion. The presence of branched capillaries has been described as a feature of JDM that differentiates it from the microangiopathy observed in systemic sclerosis. According to several different studies, microangiopathy severity is related to disease prognosis and there is an association between the degree of capillary alterations and chronic forms of the disease and ulcerative complications.<sup>24,25,28</sup> There is just one article in the literature that has associated capillaroscopy findings with clinical and laboratory assessments of JDM disease activity.<sup>24</sup> Other studies have demonstrated that capillaroscopy findings occur irrespective of disease activity, but correlate with the more severe and persistent forms.<sup>25</sup>

Our study objectives were to assess patients with JDM and with both myositis and scleroderma (overlap) and to correlate clinical and laboratory manifestations of disease activity with NFC findings.

## Material and methods

Thirteen JDM patients and five with overlap syndrome being seen at the Pediatric Rheumatology clinic at our institution during the period from May 1998 to May 2003 were studied. Diagnoses of JDM were made based on criteria defined by Bohan & Peter (Table 1).<sup>13</sup> The diagnoses of the five patients with overlap syndrome of myositis with scleroderma was based on clinical and histological characteristics.

Clinical and laboratory evidence of disease activities was obtained by review of medical records, noting the following parameters: typical cutaneous alterations

**Table 1** - Criteria used for the diagnosis of juvenile dermatomyositis (JDM)

- 
- Proximal and symmetric muscle weakness.
  - Cutaneous alterations: heliotrope with periorbital edema and red-purple erythema; proximal skinfold vasculitis (Gottron's papules).
  - Elevation of serum levels of one or more skeletal muscle enzymes: creatine phosphokinase, glutamic-oxaloacetic transaminase, lactic dehydrogenase and aldolase.
  - Electromiography showing myopathy and degeneration signs.
  - Muscle biopsy showing histologic evidence of necrosis and inflammation.
- 

Source: Bohan & Peter.<sup>13</sup>

(Gottron's papules, heliotrope and nailfold hyperemia) and/or muscle weakness (muscle history and scores), and/or increase in muscle enzymes (creatin phosphokinase - CPK, lactic dehydrogenase - LDH, aldolase and glutamic-oxalacetic transaminase - GOT) and inflammatory test results (erythrocyte sedimentation rate - ESR). The muscle strength scale was a modified version of The Childhood Myositis Assessment Scale with possible scores ranging from 0 to 62.<sup>29</sup>

Nailfold capillaroscopy was performed using an optical microscope with magnification of 10 and 16 times, equipped with a scaled rule on the direct objective to allow the number of capillaries per millimeter to be counted. The fingers were examined (with the exception of the thumbs). EPI-fluorescence was provided by a tungsten incandescent lamp and a drying oil was applied to the area of the nailfold in order to obtain skin diaphanization. Patients were instructed not to manipulate their cuticles for one month prior to the examination in order to avoid traumas. All examinations were performed by the same researcher (M.T.R.A.T.) who was blind to the level of disease activity. The parameters analyzed were: microhemorrhages, capillary enlargement (ectasia and giant capillaries), morphological abnormalities (branching) and level of dropout. The number of microhemorrhages was assessed by counting micro-petechiae, and their distribution was given greater weight when in a diffuse pattern. Capillary ectasia was defined as the presence of capillary loops dilatated by four or more times in comparison with the others. Giant capillaries were defined as aneurysms with loops more than 10 times the normal size. Branched capillaries were defined as those with small branchings in many directions. The level of dropout was measured as follows: level 0 - no dropout; level 1 - one or two unconnected areas of dropout; level 2 - more than two unconnected areas; level 3 - extensive or confluent areas of dropout. The mean for each parameter for each patient was calculated by dividing the sum of the values observed for each finger by the number of fingers examined, i.e.

eight. Examination findings were considered abnormal if ectasia or giant capillaries were observed, if there was any dropout and/or if there were diffuse hemorrhages in two or more fingers. Scleroderma pattern (SD) was defined as the presence of capillary ectasia or giant capillaries and avascular lesions indicating capillary dropout.

All patients and controls gave their informed consent to participation in the study, which had itself received prior approval from the Ethics Committee at the *Hospital São Paulo*.

Student's t test for two independent samples with equal variance (Morettin) was used to compare the means of quantitative variables across the two groups (active or inactive disease). Then equality of variance had been previously tested using the Levene test.

Fisher's exact test was used to study the association between categorical variables and disease activity/inactivity.

We set the level of significance at 5%.

## Results

Eighteen patients underwent a total of 26 capillaroscopic examinations, seven of them on two or more occasions. Thirteen of these were performed during the active disease phase and 13 during remission. The mean age of the 13 patients with JDM at the time of examination was 8.8 years, 10 were female, 11 were Caucasoid. One of the patients exhibited amyopathic dermatomyositis. The mean age of the five patients with overlap syndrome at the time of evaluation was 15.7 years and three of them were female and three Caucasoid.

Ten of the examinations performed during the active phase exhibited cutaneous alterations (10/13 had Gottron's papules, 8/13 heliotrope and 3/13 skinfold vasculitis). None of the patients examined during the inactive phase of the disease presented cutaneous alterations, which was a significant difference between the two groups ( $p = 0.001$ ). Muscle weakness was reported in 8/13 of the examinations of active disease sufferers, with a mean score of 17.2, being statistically more frequent than for the inactive disease group ( $p = 0.011$ ). Just one patient with inactive disease exhibited muscle weakness, scoring 10. Muscle enzyme levels were elevated on 11/13 occasions that NFC was performed during disease activity (4/13 CPK, 11/13 LDH, 1/4 aldolase and 6/13 GOT). Just two of the inactive disease patients exhibited increased muscle enzyme levels (CPK and LDH). Increases muscle enzyme levels were statistically more common among the active disease group than the inactive one ( $p = 0.001$ ). Increases in ESR took place on 4/13 occasions on which NFC was performed during the active phase, with no statistical difference from the inactive disease group.

Cutaneous abnormalities were present in the great majority of the active phase children and were associated with muscle involvement (weakness and/or elevated enzyme levels) in 70% of cases ( $p = 0.043$ ).

The clinical and laboratory data relating to the patients with JDM and overlap syndrome, in active or inactive phases, are shown in Table 2.

We observed that the level of dropout was statistically higher in the active disease group ( $p = 0.031$ ).

Capillaroscopy findings are shown in Table 3.

Twelve of the 13 active phase exams found SD Pattern (the presence of ectasia or giant capillaries and capillary dropout), i.e. they were abnormal. Just five of the 13 inactive phase examinations found significant abnormalities compatible with SD (high level of dropout). However, 5/8 inactive phase patients exhibited some degree of dropout, although on just one finger (three patients), low level of dropout (one patient) or improved dropout level compared to an examination during the active phase (one patient), thereby demonstrating an association between clinical and capillaroscopic observations. Some patients had discrete ectasia (mean of 3.11/ patient) but with little or no dropout. Twenty of the 26 examinations, therefore, demonstrated a correlation between clinical and/or laboratory evidence of activity and capillaroscopy findings ( $p = 0.01$ ).

Nailfold capillaroscopy was performed twice or more for seven patients. Five of these patients progressed from the active to the inactive phase. Two of these had NFC results that were initially abnormal and normalized later, one improved without findings becoming normal and in two there were no alterations.

Figure 1 shows nailfold capillaroscopy of a patient with JDM and visible scleroderma pattern (16 times magnification).

## Discussion

Our findings show that patients with active disease progress with persistent capillaroscopy findings that denote SD Pattern. We observed that capillary dropout offered the greatest statistical difference for separating active from inactive patients and that it is the most important variable for characterizing SD Pattern. The variables, capillary ectasia, giant capillaries and branched capillaries may not have demonstrated statistical differences because they reflect the neovascularization that is characteristic of recovery from microangiopathy. In contrast with scleroderma, in which capillaroscopy findings, particularly dropout, are not dynamic, patients with JDM can exhibit involution of the injuries in a matter of months during the inactive phase of the disease. This was clearly observed among our patients, amongst whom we found a statistical

**Table 2 -** Distribution of patients with juvenile dermatomyositis and overlap syndrome according to the disease activity and clinical and laboratory data

	<b>Active disease (n = 13)</b>	<b>Inactive disease (n = 13)</b>	<b>p</b>
Active cutaneous alterations	10	0	0.001*
Muscle weakness	8	1	0.011*
Elevation of muscle enzymes	11	2	0.001*
Increase in ESR	4	1	0.32

\* Fisher's exact test.

ESR = erythrocyte sedimentation rate.

**Table 3 -** Distribution of patients with juvenile dermatomyositis and overlap syndrome according to the disease activity and capillaroscopy findings

	<b>Active disease (n = 13)</b>	<b>Inactive disease (n = 13)</b>	<b>p</b>
Microhemorrhages †	19.35/10 = 1.93	15.6/9 = 1.73	0.803
Ectasia †	52.2/11 = 4.70	28/9 = 3.11	0.293
Giant capillaries †	3.9/8 = 0.48	1.3/5 = 0.26	0.263
Branching †	10.1/8 = 1.26	8/8 = 1.00	0.618
Level of dropout †	29.7/12 = 2.47	19.3/10 = 1.93	0.031*

\* Student *t* test.

† Sum of the mean values of each patient divided by the number of patients.

correlation between capillaroscopy findings and disease activity. The fact that we did not observe improvement in NFC findings in two patients who were assessed in both phases may be due to the time passed between the two examinations being insufficient for capillaroscopy findings to have improved. Nevertheless, it is important to remember that the capillaroscopy method is an examination of great value, but can exhibit limitations in certain cases.

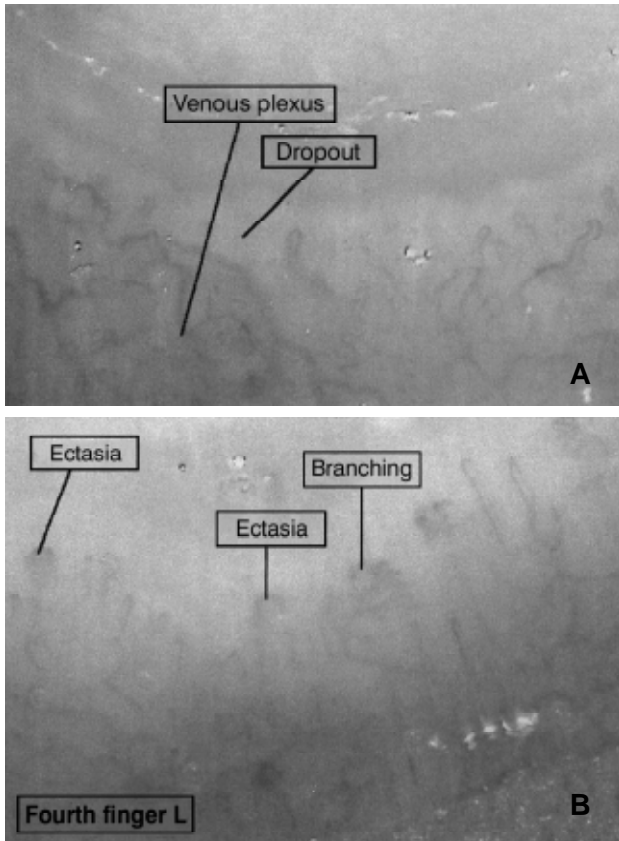
Silver & Maricq assessed nine JDM patients and found correlations between capillaroscopy findings and the clinical course of the disease. Seven of these nine patients progressed to the persistent form of the disease and exhibited severe microvascular alterations that fluctuated, but never normalized. The other two patients had the monocyclic or transitory form of the disease with less severe capillary involvement which normalized concurrently with involution of Gottron's papules and normalization of muscle strength and enzymes.<sup>24</sup>

Autoimmune rheumatic diseases such as JDM and other diseases associated with JDM (such as overlap syndrome) predominantly involve small vessel vascular disease, with vascular alterations taking place in the muscles, skin and diverse organs.<sup>1</sup>

Cutaneous alterations were present in the great majority of children with active disease and there was a significant association with muscle involvement (weakness and/or increased enzymes) in 70% of cases.

Three of the eleven patients with active disease had increased muscle enzyme levels, although without compromise to strength. This may be because abnormal laboratory findings appear earlier than clinical ones and appropriate treatment impedes progression to muscle weakness.

Just two of the inactive disease patients exhibited increased muscle enzymes, without active cutaneous abnormalities or muscle weakness, for which reason they



**Figure 1** - Nailfold capillaroscopy of a patient with JDM and visible scleroderma pattern with dropout and ectasia (16 times magnification)

were defined as inactive. One of these had abnormal capillaroscopy. Just one patient with inactive disease exhibited muscle weakness with a score of 10, which was attributed to sequelae from muscle atrophy secondary to myositis.

As was expected, we observed an increased frequency of cutaneous alterations, muscle weakness and elevated muscle enzyme levels in the group of active disease patients.

The ESR test did not prove to be sensitive for evaluating inflammatory myopathy, as has been described in the literature.<sup>30</sup>

The NFC is established as a noninvasive method capable of detecting vascular inflammation in capillaries. Its use has been indicated for the diagnosis of certain autoimmune rheumatic diseases, and for their prognosis.<sup>21,23,27</sup>

Nevertheless, few authors have found a correlation between capillaroscopy findings and disease activity.<sup>24</sup> During infancy this finding is even less defined.

Capillaroscopy findings pass through definite stages. With the capillary inflammatory process, these vessels are

burst and diffuse microhemorrhages take place before dropout. In an attempt to make up for the lost vessels, the remaining vessels increase in size and dilated capillary loops and giant capillaries appear. With remission of the inflammatory condition, neovascularization takes place, new vessels are formed and the areas of dropout disappear. With this last stage, capillary morphology is recuperated, as was observed in our sample.

Summing up, NFC is a noninvasive examination that offers a good correlation with JDM activity and can be used as an additional instrument for the evaluation of patients with active and recurrent forms of the disease.

### References

1. Banker BQ. Dermatomyositis of childhood, ultrastructural alterations of muscle and intramuscular blood vessels. *J Neuropathol Exp Neurol.* 1975;34:46-75.
2. Whitaker JN. Inflammatory myopathy: a review of etiologic and pathogenetic factors. *Muscle Nerve.* 1982;5:573-92.
3. Denman AM. Inflammatory disorders of muscle. Aetiology. *Clin Rheum Dis.* 1984;10:9-33.
4. Currie S, Saunders M, Knowles M, Brown AE. Immunological aspects of polymyositis. The in vitro activity of lymphocytes on incubation with muscle antigen and with muscle cultures. *Q J Med.* 1971;40:63-84.
5. Miller ML, Lantner R, Pachman LM. Natural and antibody-dependent cellular cytotoxicity in children with systemic lupus erythematosus and juvenile dermatomyositis. *J Rheumatol.* 1983;10:640-2.
6. Whitaker JN, Engel WK. Vascular deposits of immunoglobulin and complement in idiopathic inflammatory myopathy. *N Engl J Med.* 1972;286:333-8.
7. Crowe WE, Bove KE, Levinson JE, Hilton PK. Clinical and pathogenetic implications of histopathology in childhood polydermatomyositis. *Arthritis Rheum.* 1982;25:126-39.
8. Sullivan DB, Cassidy JT, Petty RE, Burt A. Prognosis in childhood dermatomyositis. *J Pediatr.* 1972;80:555-63.
9. Rose AL. Childhood polymyositis. A follow-up study with special reference to treatment with corticosteroids. *Am J Dis Child.* 1974;127:518-22.
10. Sullivan DB, Cassidy JT, Petty RE. Dermatomyositis in the pediatric patient. *Arthritis Rheum.* 1977;20(Suppl):S327-31.
11. Bowyer SL, Blane CE, Sullivan DB, Cassidy JT. Childhood dermatomyositis: factors predicting functional outcome and development of dystrophic calcification. *J Pediatr.* 1983;103:882-8.
12. Spencer CH, Hanson V, Singesen BH, Bernstein BH, Kornreich HK, King KK. Course of treated juvenile dermatomyositis. *J Pediatr.* 1984;105:399-408.
13. Bohan A, Peter JB. Polymyositis and dermatomyositis. *N Engl J Med.* 1975;292:344-7.
14. Euwer RL, Sontheimer RD. Amyopathic dermatomyositis (dermatomyositis sine myositis). Presentation of six new cases and review of the literature. *J Am Acad Dermatol.* 1991;24:959-66.
15. Schmid MH, Trueb RM. Juvenile amyopathic dermatomyositis. *Br J Dermatol.* 1997;136:431-3.
16. Maricq HR. Wide-field capillary microscopy. *Arthritis Rheum.* 1981;24:1159-65.
17. Terreri MT, Andrade LE, Puccinelli ML, Hilario MO, Goldenberg J. Nailfold capillaroscopy: normal findings in children and adolescents. *Semin Arthritis Rheum.* 1999;29:36-42.
18. Dolezalova P, Young SP, Bacon PA, Southwood TR. Nailfold capillary microscopy in healthy children and in childhood rheumatic diseases: a prospective single blind observational study. *Ann Rheum Dis.* 2003;62:444-9.
19. Ohtsuka T. Quantitative analysis of nailfold capillary abnormalities in patients with connective tissue diseases. *Int J Dermatol.* 1999;38:757-64.

20. Scheja A, Elborgh R, Wildt M. Decreased capillary density in juvenile dermatomyositis and in mixed connective tissue disease. *J Rheumatol.* 1999;26:1377-81.
21. Scheibel I, Brenol JC. Capilaroscopia em crianças: utilidade diagnóstica nas doenças difusas do tecido conjuntivo. *Rev Bras Reumatol.* 1998;38:78-82.
22. Caleiro MT. Diagnostic contribution and current concepts in nailfold capillary microscopy in rheumatology. *Rev Hosp Clin Fac Med Sao Paulo.* 1997;52:104-10.
23. Kabasakal Y, Elvins DM, Ring EF, McHugh NJ. Quantitative nailfold capillaroscopy findings in a population with connective tissue disease and in normal healthy controls. *Ann Rheum Dis.* 1996;55:507-12.
24. Silver RM, Maricq HR. Childhood dermatomyositis: serial microvascular studies. *Pediatrics.* 1989;83:278-83.
25. Ganczarczyk ML, Lee P, Armstrong SK. Nailfold capillary microscopy in polymyositis and dermatomyositis. *Arthritis Rheum.* 1988;31:116-9.
26. Nussbaum AI, Silver RM, Maricq HR. Serial changes in nailfold capillary morphology in childhood dermatomyositis. *Arthritis Rheum.* 1983;26:1169-72.
27. Maricq HR, Spencer-Green G, LeRoy EC. Skin capillary abnormalities as indicators of organ involvement in scleroderma (systemic sclerosis), Raynaud's syndrome and dermatomyositis. *Am J Med.* 1976;61:862-70.
28. Spencer-Green G, Crowe WE, Bove KE, Levinson JE. Correlation of muscle angiopathy with nailfold capillary abnormalities in childhood dermatomyositis. *Bibl Anat.* 1981;20:702.
29. Lovell DJ, Lindsley CB, Rennebohm RM, Ballinger SH, Bowyer SL, Giannini EH, et al. Development of validated disease activity and damage indices for the juvenile idiopathic inflammatory myopathies. II. The Childhood Myositis Assessment Scale (CMAS): a quantitative tool for the evaluation of muscle function. The Juvenile Dermatomyositis Disease Activity Collaborative Study Group. *Arthritis Rheum.* 1999;42:2213-9.
30. Cassidy JT, Petty RE. Juvenile Dermatomyositis. In: Cassidy JT, Petty RE, editors. *Textbook of pediatric rheumatology.* 4th ed. Philadelphia: W. B. Saunders Co.; 2001. p. 465-94.

## Correspondence:

Maria T. R. A. Terreri  
Rua Loefgreen, 2381/141, Vila Clementino  
CEP 04040-004 – São Paulo, SP – Brazil  
Tel.: +55 (11) 9459.6226  
E-mail: [alergia.reumato@terra.com.br](mailto:alergia.reumato@terra.com.br)