
Reexpansion pulmonary edema*

EDUARDO HENRIQUE GENOFRE¹, FRANCISCO S. VARGAS², LISETE R. TEIXEIRA³,
MARCELO ALEXANDRE COSTA VAZ³, EVALDO MARCHI³

Reexpansion pulmonary edema (RPE) is a rare, but frequently lethal, clinical condition. The precise pathophysiologic abnormalities associated with this disorder are still unknown, though decreased pulmonary surfactant levels and a pro-inflammatory status are putative mechanisms. Early diagnosis is crucial, since prognosis depends on early recognition and prompt treatment. Considering the high mortality rates related to RPE, preventive measures are still the best available strategy for patient handling. This review provides a brief overview of the pathophysiology, diagnosis, treatment, and prevention of RPE, with practical recommendations for adequate intervention. (**J pneumol** 2003; 29(2):101-6)

Key words – Pulmonary edema. Pleura. Pleural effusion. Pneumothorax.

Abbreviations used in this article

RPE – Reexpansion pulmonary edema

IL-8 – Interleukin 8

MCP – 1 – Monocytes chemotactic protein

TNF – Tumoral necrosis factor

HISTORY

The first reference to respiratory failure after pleurocentesis, with emptying of large liquid volumes, was made by Pinault, in 1853, following the removal of three liters of pleural liquid^(1,2). From this finding, a new clinical condition was defined, called reexpansion pulmonary edema (RPE), which, despite being rare, occurs as a complication of the fast expansion of the collapsed lung after emptying of the pleural cavity. The first well-documented report was presented by Foucart in 1875^(3,4).

Cases published in the end of the 19th and beginning of the 20th centuries associate RPE with the

accidental application of high negative pressure, reaching 760 mmHg. In 1905, the term “albumin sputum” was coined by Hartkey⁽⁵⁾. The term was suggested as a consequence of the presence of a large amount of tracheal secretion in patients submitted to the fast removal of large volume of liquids, either by pleurocentesis or pleural drainage under negative pressure (vacuum)^(6,7).

In 1958, Carlson and colleagues described the first EPR case following pneumothorax drainage. Between 1958 and 1999 only 60 cases were published to the best of our knowledge, confirming the rare occurrence of the clinical condition, which can often be fatal^(8,9).

* Work carried out at the Respiratory Disease Unit, Department of Pneumology – Instituto do Coração (INCor) – Faculdade de Medicina da Universidade de São Paulo, São Paulo, SP.

1. Physician, Graduate student of Pneumology – FMUSP.

2. Full Professor of Pneumology – FMUSP.

3. Assistant Professor of Pneumology – FMUSP.

Mailing address - Eduardo Henrique Genofre, Av. dos Três Poderes, 405 – 05514-000 – São Paulo, SP. Tel./fax (11) 3082-7040/(11) 3721-3427; e-mail: ehgenofre@uol.com.br

Received for publication on 12/2/02. Accepted after revision on 2/17/03.

INTRODUCTION

In the 70's attention was paid to reexpansion pulmonary edema, providing the opportunity to raise several hypothesis to explain its occurrence, among which is emphasized the reduction of surfactant production and bronchial obstruction^(4,10-12); being only the former currently accepted.

In 1979, Mahajan and co-workers demonstrated that edema resulted from a combination of alterations as a consequence of fast blood flow during the reexpansion, thus abruptly increasing the lung capillary pressure leading to liquid and protein overflow into the alveoli and pulmonary interstice⁽³⁾.

In 1982, Mariand and Glauser published a study confirming the hypothesis of protein overflow into the alveoli. In this study the index of protein in the tracheal secretion of cardiogenic (0.5) and reexpansion (0.85) pulmonary edema was evaluated. The highest influence in cardiac patients came from increased hydrostatic pressure, causing the protein index to be much lower than in lung patients, suggesting that capillary permeability was compromised in the latter group⁽⁷⁾.

Alert to these associated factors, Sprung and Elser (1983) proposed that the speed, volume and level of negative pressure used in liquid removal should be watched to avoid the development of reexpansion, since all these factors were equally important for RPE to occur⁽¹³⁾.

In the mid 80's, Paylin and colleagues studied the hypotension observed in these patients. In this study, carried out with reexpansion edema following pleurocentesis, with removal of 1,500 ml of pleural liquid, the authors observed that the volume of tracheal liquid recovered could reach 2,000 ml. They also complemented their study evaluating the lung weight at the necropsy, reporting that the weight increased up to 3 times compared to a normal lung (approximately 600 g)⁽¹⁴⁾.

In 1988, Mahfood et al. published an extensive review that became a reference for the study of reexpansion edema. These authors defined several criteria for this condition, characterizing it as being the consequence of hypoxemia and alveolus-capillary mechanical lesion due to a prolonged lung collapse, occurring independently from the technique used for pleural emptying on either pleural effusion or pneumothorax (pleural suction, Heimlich valve, water stamp or positive pressure ventilation)⁽⁷⁾.

This study changed the research focus and the role of some inflammatory mediators began to be evaluated. The first publication on this topic was a case

report by Nakamura et al., in 1994, demonstrating the involvement of polymorphonuclear, interleukin-8 (IL-8) and the monocyte chemotactic protein (MCP-1), in the genesis and maintenance of RPE⁽¹⁵⁾.

In a second and also extensive review published in 1997, Trachiotis and colleagues demonstrated that 83% of the reexpansion pulmonary edema cases occurred in patients with prolonged pulmonary collapse. Another interesting finding is that pleural suction was not used in 33% of the edema cases, raising the hypothesis that negative pressure may not be as crucial as the degree and speed of reexpansion⁽⁹⁾.

More recent experimental studies were performed in rabbits, making this condition easier to understand, since its occurrence is rare. Nakamura and co-workers⁽¹⁶⁾ and Sakao and colleagues⁽¹⁷⁾ confirmed, in an animal model, what had already been shown in humans in 1994, demonstrating the inflammatory participation of polymorphonuclear, IL-8 and MCP-1, also ruling out the interference of TNF (tumoral necrosis factor), both on the genesis and on the maintenance of the process.

Between 1958 and 1985, only 60 cases of RPE were described, according to a review written by Mahfood and colleagues being 93% of the cases unilateral, 6.7% bilateral and only 0.3% contra-lateral⁽⁷⁾. In this sample, seven cases were the consequence of pleural effusion (Table 1) and 53 occurred after pneumothorax (by different pulmonary reexpansion techniques).

PATHOPHYSIOLOGY

Several studies were performed in order to clear out the pathophysiological aspects of RPE. Although its occurrence is rare in view of the high mortality rate, appropriate understanding of the mechanisms involved in the genesis and evolution of this condition may contribute to its prevention.

Its pathogenesis is certainly multifactorial⁽⁵⁾. Several factors may be involved in the process, especially pulmonary collapse with more than 72 h of evolution^(1,18). This component apparently generates permeability alterations and lung capillary pressure, as well as surfactant loss; there are, however, other factors including emptying and expansion techniques employed^(7,13) (Table 2).

Therefore, we can define reexpansion edema as the being caused by two main entities: alteration of capillary permeability⁽⁷⁾, the most important in this process and increase of hydrostatic pressure⁽³⁾.

CHART 1						
Case reports of reexpansion edema caused by pleural effusion emptying ⁽⁷⁾						
Author/year	N	Age (years)/gender	Duration of symptoms (days)	Effusion volume (L)	Onset of symptoms	Outcome
Trapnell, 1970	2	56/M	090	3.0	Hours	Solution
		58/M	-	2.0	Immediate	Solution
Buczko, 1981	1	59/F	014	3.0	5 min	Solution
Sprung, 1981	1	22/F	042	1.3	2 h	Death
Marland, 1982	1	49/F	120	1.0	1 h	Death
Smith/1983	1	-	-	3.5	-	-
Milne/1983	1	21/F	021	4.5	Immediate	Solution

The alteration of capillary permeability has two basic causes. In the first one - vascular predominance, the voluminous and prolonged collapse (defined in the literature as being longer than 72 h and larger than 1,500 ml) causes local hypoxemia, lesioning the capillary wall and reduces the production of surfactant. Hypoxemia and capillary lesion produce the release of inflammatory mediators (IL-8, MCP-1, nitric oxide, polymorphonuclear and free radicals), which perpetuate the microvascular lesion, also altering the capillary permeability ^(1,5,14,16,17,19,20).

The role of the mediators of local inflammation on the genesis and maintenance of reexpansion pulmonary edema is not clear. The presence of neutrophils in the alveolar space seen by Nakamura and colleagues (1994) in the bronchial-alveolar wash suggests an active role of this cell component, either by direct oxidative lesion or by production of local inflammation mediators, such as IL-8 and leukotrienes ⁽¹⁵⁾.

In the second cause - alveolar predominance, capillary permeability is increased by the alteration of the alveolar-capillary barrier produced by mechanical lesion of the alveolus, induced either by surfactant reduction (due to hypoxemia) or by pulmonary reexpansion-induced abrupt alveolar distension ⁽⁷⁾.

Pulmonary reexpansion results not only in alveolar alteration, but it also makes the great and fast blood flow to increase the lung capillary pressure leading to increased hydrostatic pressure ⁽³⁾.

Vascular permeability, altered by the capillary and alveolar lesion and associated to the increased hydrostatic pressure, leads to liquid and protein overflow into the interstice and alveoli, thus characterizing reexpansion pulmonary edema ⁽¹⁰⁾.

Figure 1 shows a schedule of RPE pathophysiology.

CHART 2
Risk factors for the development of reexpansion pulmonary edema
<ul style="list-style-type: none"> - Chronicity of collapse - Volume of effusion - Reexpansion technique - Pulmonary vascular permeability - Bronchial obstruction - Loss of surfactant - Alteration of the pulmonary artery pressure

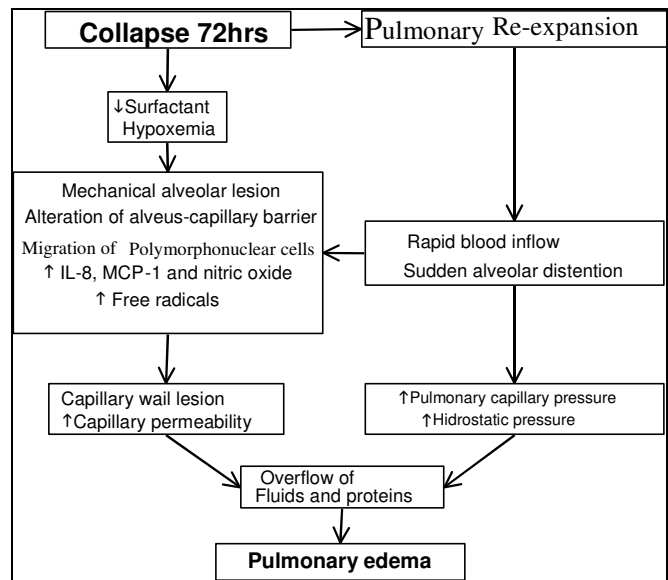


Figure 1 – Pathophysiology of reexpansion pulmonary edema

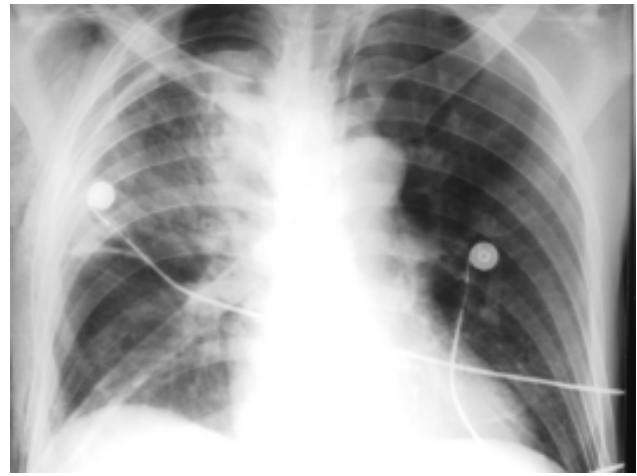
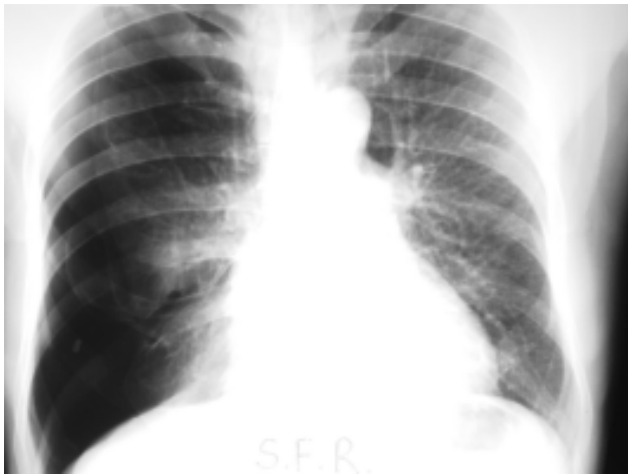
Figure 2 – Right spontaneous hypertensive pneumothorax with evolution longer than 48 h in a COPD patient. Approximately 12 h after the drainage, the patient presented clinical features compatible with acute pulmonary edema. At the control X-ray, the presence of unilateral reexpansion pulmonary edema is noticeable, with predominant opacity at the right upper lobe, air bronchogram and cissural and pleural effusion.

RISK FACTORS

Based on studies performed and on the understanding of the pathophysiology, it is possible to characterize the risk factors that may always be recalled for an efficient prevention.

The first factor to be considered is the time of evolution of the pleural effusion (longer than 72 h), associated to the estimated volume (more than 1,500 ml)^(2,3,10,11,19,21).

Pulmonary hypertension must be considered, since there are great alterations of lung alveolar dynamics. Similarly, hypoxemia, as a basal characteristic of the patient, makes oxygen supplementation necessary during and after the procedure, in case there is evidence of gasimetric deterioration⁽²²⁾.

Cardiovascular diseases have gained ever-growing importance, since their incidence has increased. In addition, in the presence of different levels of myocardial contractility deficiency, hemodynamic repercussions that may take place after emptying pleural liquid tend to aggravate⁽¹⁴⁾.

Pulmonary or other organ-related diseases contribute to the elevated general risk, insofar as they alter or hinder the pulmonary and cardiovascular compensation, since the organism needs to compensate the alterations caused by the several factors responsible for RPE.

DIAGNOSIS

The basis for reexpansion pulmonary edema diagnosis includes the history, clinical presentation and radiological features⁽³⁾.

RPE symptoms usually appear in the first two hours after pulmonary reexpansion, and may last for 24 to 48 h, disappearing after five to seven days⁽³⁾.

The symptoms vary from complete absence or presence of minimum symptoms (where the alterations can only be seen on the thorax X-ray) to more prominent symptoms; this array of signs and symptoms depend on the severity and extension of the edema^(1,4,14,23,24).

Among the general symptoms and signs fever, nausea and vomit, tachycardia and hypotension may take place^(23,24).

From the respiratory point of view, the patient can show dyspnea of diverse intensities, thoracic pain, cough associated or not with abundant pink and foamy sputum, cyanosis and, mainly, presence of stertors at pulmonary auscultation^(14,23).

The radiological evidence is the pulmonary edema with interstitial opacity, consolidations, air bronchogram and evidence of lung clefts^(2,8) and of Kerley's "B" lines⁽²⁵⁾ (Figure 2).

The evolution of reexpansion pulmonary edema is variable, and may occur from a spontaneous resolution to a lethal respiratory failure. The mortality evaluated in a reference review study showed 11 casualties in 53 documented cases (21%). Although the daily practice does not show such a remarkable mortality, these data is an alert for the severity of the problem⁽⁷⁾.

In view of the clinical and radiological features, as well as its evolution, it is important to make the differential diagnosis with the cardiogenic pulmonary edema, pulmonary infection or pneumonitis, especially in immunosuppressed patients⁽³⁾.

TREATMENT

Treatment consists of support measures and is based on oxygen supplementation, as well as in ventilatory support, either by invasive or non-invasive ways, associated to hemodynamic support using, for instance, Swan-Ganz catheter monitorization, thus leading to volume reposition, use of inotropic agents and even diuretics ^(2,26).

Several strategies are mentioned in the literature trying to reduce RPE morbidity-mortality, as for instance, placing the patient in lateral decubency with the affected side up ⁽⁹⁾ or occlusion of the affected side pulmonary artery with a balloon catheter ^(3,19).

PREVENTION

Its prevention is still based on careful pleural emptying procedures, without standards to avoid RPE evolution (Figure 3).

The first step is to observe the already mentioned risk factors for each patient, correcting and compensating these factors. In pulmonary hypertension or severe hypoxemic patients submitted to thoracentesis or pleural drainage, it is recommended a slow emptying and oximetry monitorization and oxygen administration, if necessary.

The intra-pleural pressure and the total liquid volume in the pleural cavity must be assessed in large effusions in which pleural thickening occurs and intra-pleural pressure tends to be more negative than in voluminous effusions, though without pleural impairment ⁽²¹⁾.

The volume to be withdrawn varies according to each author. Several studies suggest that the ideal volume in each procedure should not be more than 1,000 ml, especially if the evolution of the effusion is longer than 72 h ^(2,7,10,19,21). However, Mahajan and colleagues ⁽³⁾ and Trapnel and Thurston ⁽¹¹⁾ suggest a safe limit of 1,500 ml. A strategy to avoid RPE is the monitoring of pleural pressure during cavity emptying up to the maximum -20 cmH₂O ^(2,21), thus reaching higher volumes (approximately up to 5,000 ml per thoracentesis) ⁽²¹⁰⁾.

The clinical symptoms during the emptying of the pleural effusion (or of the pneumothorax), such as persistent cough ⁽³⁾, thoracic pain or dyspnea ⁽²⁾, must be considered as an indication of the need to halt the pleural cavity's content withdrawal, because they may indicate a reduction of intra-pleural pressure lower than -20 cmH₂O, even reaching -50 cmH₂O during therapeutic thoracentesis ⁽²¹⁾.

It is important to emphasize that these symptoms and signs do not directly mean reexpansion edema; however, individually or not and, especially associated to withdrawn volumes above 1,500 ml, they serve as an alert to stop the procedure.

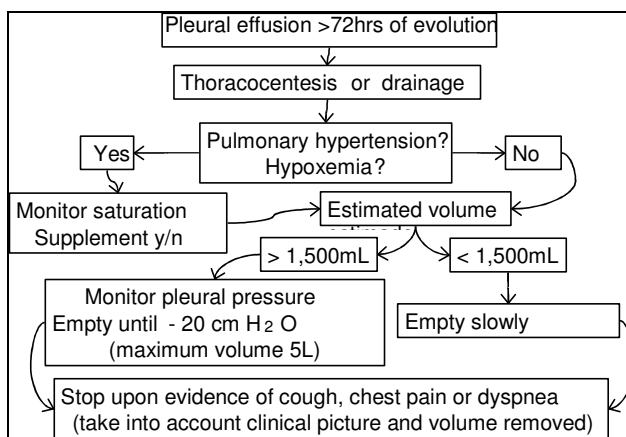


Figure 3 – Orientation algorithm of the approach to pleural effusion and prevention of reexpansion pulmonary edema.

During pleural drainage, use of water stamp minimizes the risk of reexpansion pulmonary edema, mainly if the pulmonary collapse is longer than three days. The negative pressure in pleural drainage, used in some situations, should be employed only after 24 to 48 h of the drainage, thus avoiding the risk of RPE ⁽²²⁾.

FUTURE PERSPECTIVE

Observing the new perspectives in the study of pathophysiology, the use of new drugs has been sought as a way to avoid and, if necessary, treat reexpansion edema.

The purpose is to use these drugs in the diagnostic hypothesis during the initial symptom phases, protecting or reducing the risk of developing of lesions that induce to RPE.

Some drugs routinely used in the clinical practice have been employed individually and even empirically, such as non-hormone anti-inflammatory drugs (indomethacin and ibuprofen) and prostaglandin analogues (misoprostol) ⁽⁹⁾, searching for anti-inflammatory and cell protecting effects.

Therapy research is directed to the inflammatory approach and animal studies have been carried out for this purpose. Evaluation of the role of interleukins points out to a pre-treatment with IL-8 neutralizing antibody, which is possibly applicable as an approach to reexpansion edema, making the pulmonary lesion less intense, since its use, according to some authors, reducing the pulmonary lesion that takes place in alveolitis associated to immunocomplex, endotoxin-induced pleurisia, an acute pulmonary lesion from aspiration of acids associated to endotoxemia.

The use of monoclonal antibodies against IL-8 in experimental studies in rabbits prevented neutrophil infiltration and acute pulmonary lesion induced by the reperfusion ischemia process, suggesting that its use in

high risk patients could be an effective protective therapy⁽¹⁶⁾.

CLINICAL IMPORTANCE

It is essential that professionals involved in drainage or pleural puncture procedures are aware of a possible

occurrence of RPE after emptying of the pleural cavity. Considering the high risk of mortality, it is necessary to take the required care to avoid this rare, though potentially severe condition, as well as earlier and more aggressive therapeutic measures be taken when there is a clinical or radiological suspicion.

REFERENCES

1. Kernodle DS, DiRaimondo CR, Fulkerson WJ. Reexpansion pulmonary edema after pneumothorax. *South Med J* 1984;77:318-22.
2. Heller BJ, Grathwohl K. Contralateral reexpansion pulmonary edema. *South Med J* 2000;93:828-31.
3. Mahajan VK, Simon M, Huber GL. Reexpansion pulmonary edema. *Chest* 1979;75:192-4.
4. Ratliff JL, Chavez CM, Jamchuck A, Forestner JE, Conn JH. Re-expansion pulmonary edema. *Chest* 1973;64:654-6.
5. Shanahan MX, Monk I, Richards HJ. Unilateral pulmonary oedema following re-expansion of pneumothorax. *Anaesth Intensive Care* 1975; 3:19-30.
6. Ziskind MM, Weill H, George RA. Acute pulmonary edema following the treatment of spontaneous pneumothorax with excessive negative intrapleural pressure. *Am Rev Respir Dis* 1965;92:632-6.
7. Mahfood S, Hix WR, Aaron BL, Blaes P, Watson DC. Reexpansion pulmonary edema. *Ann Thorac Surg* 1988;45:340-5.
8. Ragozzino MW, Greene R. Bilateral reexpansion pulmonary edema following unilateral pleurocentesis. *Chest* 1991;99:506-8.
9. Trachiotis GD, Vricella LA, Aaron BL, Mix WR. Reexpansion pulmonary edema. *Ann Thorac Surg* 1997;63:1205-6.
10. Sprung CL, Lowenherz JW, Baier H, Manser MJ. Evidence for increased permeability in reexpansion pulmonary edema. *Am J Med* 1981;71:497-500.
11. Trapnel DH, Thurston JGB. Unilateral pulmonary oedema after pleural aspiration. *Lancet* 1970;1:1367-9.
12. Childress ME, Moy G, Mottram M. Unilateral pulmonary edema resulting from treatment of spontaneous pneumothorax. *Am Rev Respir Dis* 1971;104:119-21.
13. Sprung CL, Elser B. Reexpansion pulmonary edema. *Chest* 1983; 84:788.
14. Pavlin JD, Raghu G, Rogers TR, Cheney FW. Reexpansion hypotension. A complication of rapid evacuation of prolonged pneumothorax. *Chest* 1986;89:70-4.
15. Nakamura H, Ishizaka A, Sawafuji M, Urano T, Fujishima S, Sakamaki F, et al. Elevated levels of interleukin-8 and leukotriene B4 in pulmonary edema fluid of a patient with reexpansion pulmonary edema. *Am J Respir Crit Care Med* 1994;149:1037-40.
16. Nakamura M, Fujishima S, Sawafuji M, Ishizaka A, Oguma T, Soejima K, et al. Importance of interleukin-8 in the development of reexpansion lung injury in rabbits. *Am J Respir Crit Care Med* 2000;161:1030-6.
17. Sakao Y, Kajikawa O, Martin TR, Nakahara Y, Hadden WA 3rd, Harmon CL, et al. Association of IL-8 and MCP-1 with the development of reexpansion pulmonary edema in rabbits. *Ann Thorac Surg* 2001; 71:1825-32.
18. Miller WC, Toon R, Palat H. Experimental pulmonary edema following re-expansion of pneumothorax. *Am Rev Resp Dis* 1973;108:664-6.
19. Matsuura Y, Nomimura T, Murakami H, Matsushima T, Kakehashi M, Kajihara H. Clinical analysis of reexpansion pulmonary edema. *Chest* 1991;100:1562-6.
20. Suzuki S, Tanita T, Koike K, Fujimura S. Evidence of acute inflammatory response in reexpansion pulmonary edema. *Chest* 1992;101:275-6.
21. Light RW, Jenkinson SG, Minh V, George RB. Observations on pleural pressures as fluid is withdrawn during thoracentesis. *Am Rev Respir Dis* 1980;121:799-804.
22. Light RW. *Pleural diseases*. 4th ed. Philadelphia: Lippincott Williams & Wilkins; 2001.
23. Jatene FB, Bechara M, Carvalho CR, Jatene MB, Tranchesini B, Ramirez JA, et al. Edema agudo de pulmão, não cardiogênico, pós-reexpansão. *Rev Paul Med* 1986;104:327-8.
24. Fanning J, Lettieri L, Piver MS. Fatal recurrent reexpansion pulmonary edema. *Obstet Gynecol* 1989;74:495-7.
25. Humphreys RL, Berne AS. Rapid re-expansion of pneumothorax. A cause of unilateral pulmonary edema. *Radiology* 1970;96:509-12.
26. Sewel RW, Fewel JG, Grover FL, Arom KV. Experimental evaluation of reexpansion pulmonary edema. *Ann Thorac Surg* 1978;26:126-32.