




The Journal of Venomous Animals and
Toxins including Tropical Diseases
ISSN 1678-9199
Journal homepage www.jvat.org



Effects of copaiba oil on dermonecrosis induced by *Loxosceles intermedia* venom

Mara Fernandes Ribeiro^{1,*} , Felipe Leite de Oliveira², Aline Moreira Souza³, Thelma de Barros Machado⁴, Priscilla Farinhas Cardoso⁵, Andrea Patti Sobrinho⁶, Angélica Silveira Nascimento¹, Cláudio Maurício Vieira de Souza⁵, Sabrina Calil Elias¹

¹Laboratory of Pharmacology, Department of Pharmacy and Pharmaceutical Administration, School of Pharmacy, Fluminense Federal University, Niterói, RJ, Brazil.

²Laboratory for Cellular Proliferation and Differentiation, Institute of Biomedical Sciences, Federal University of Rio de Janeiro, Rio de Janeiro, RJ, Brazil.

³Laboratory for Veterinary Clinical Pathology, Department of Pathology and Veterinary Clinics, School of Veterinary Medicine, Fluminense Federal University, Niterói, RJ, Brazil.

⁴Laboratory of Physicochemical Quality Control, Department of Pharmaceutical Technology, School of Pharmacy, Fluminense Federal University, Niterói, RJ, Brazil.

⁵Laboratory of Arthropods, Scientific Directorship, Vital Brazil Institute, Niterói, RJ, Brazil.

⁶Biotherium, Scientific Directorship, Vital Brazil Institute, Niterói, RJ, Brazil.

Article Info

Keywords:

Loxosceles intermedia
venom
skin lesion
copaiba oil
topical treatment

ABSTRACT

Background: Accidents caused by spiders of the genus *Loxosceles* constitute an important public health problem in Brazil. The venom of *Loxosceles sp* induces dermonecrosis at the bite site and systemic disease in severe cases. Traditional medicine based on plant-derived products has been proven to reduce the local effects of envenomation. The present study verified the healing effects of copaiba oil on lesions induced by the venom of *L. intermedia*.

Methods: Cutaneous lesions were induced on the backs of rabbits by intradermal injection of *L. intermedia* venom. Copaiba oil was applied topically 6 hours after injection; the treatment was repeated for 30 days, after which animal skins were removed and processed for histopathological analysis. Blood samples were also collected before and 24 hours after venom inoculation to measure the hematological parameters.

Results: Compared to the control group, the platelet count was reduced significantly in all groups inoculated with venom, accompanied by a decreased number of heterophils in the blood. The minimum necrotic dose (MND) was defined as 2.4 µg/kg. Topical treatment with copaiba oil demonstrated a differentiated healing profile: large skin lesions were observed 10 days after venom inoculation, whereas formation of a thick crust, without scarring was observed 30 days after venom inoculation. Histopathological analysis showed no significant difference after treatment. Nevertheless, the copaiba oil treatment induced a collagen distribution similar to control skin, in marked contrast to the group that received only the spider venom injection.

Conclusions: We conclude that copaiba oil may interfere in the healing process and thus propose it as a possible topical treatment for cutaneous lesions induced by *L. intermedia* venom.

* Correspondence:

maraferrandesribeiro@gmail.com

<https://dx.doi.org/10.1590/1678-9199-JVATITD-1493-18>

Received: 23 August 2018; Accepted: 01 February 2019; Published online: 25 April 2019



On-line ISSN 1678-9199 © The Author(s). 2019 Open Access This article is distributed under the terms of the Creative Commons Attribution 4.0 International License (<http://creativecommons.org/licenses/by/4.0/>), which permits unrestricted use, distribution, and reproduction in any medium, provided you give appropriate credit to the original author(s) and the source, provide a link to the Creative Commons license, and indicate if changes were made. The Creative Commons Public Domain Dedication waiver (<http://creativecommons.org/publicdomain/zero/1.0/>) applies to the data made available in this article, unless otherwise stated.

Background

The venom of spiders belonging to the genus *Loxosceles* produces a characteristic set of symptoms known as loxoscelism. Currently, loxoscelism has been hypothesized to be a multifactorial process involving a direct action of venom on the inflammatory response [1–6]. The main characteristic of envenomation is dermonecrosis at the bite site that is manifested initially by direct and degenerative effects of the venom components on the cell membrane, basement membrane, and extracellular matrix resulting in drastic tissue damage [7].

The early phase of loxoscelism is highlighted by local edema and erythema within 6 hours of the spider bite. Subsequently, the lesion evolves into an ecchymotic area about 24 to 36 hours after the accident. After 5 to 7 days, the necrotic lesion reaches maximum area and develops a dry crust; it is occasionally associated with secondary infection. The necrotic scab falls off 2 to 3 weeks after the accident, leaving an ulcer. The terminal evolution of loxoscelism can induce severe intravascular hemolysis associated with acute anemia, jaundice, and hemoglobinuria of varying degrees. Fatalities are rare, but frequently correlated with acute renal failure [8, 9].

Treatment of loxoscelism is still a controversial subject. The effectiveness of the antivenom serum in neutralizing local effects varies in different therapeutic approaches, especially for the skin lesion [10]. Therefore, there is no consensus as to its efficacy in reversing the local effects, while the ideal interval between the bite and its management that results in good recuperation from the injury. However, antivenom serum is indicated at any time in the case of hemolysis [11, 12].

The low efficacy of the treatment has been attributed to poor understanding of action mechanisms of *Loxosceles* venom [13]. Several treatment protocols that have been proposed and tested for bites by *L. intermedia* include dapsone, corticosteroids, antibiotics, and antivenom. Dapsone limits neutrophil migration and infiltration at the site of the bite [14]; corticosteroids produce a potent anti-inflammatory effect [15]; and antibiotics prevent secondary infections [16]. However, this polytherapy is not completely effective in reducing skin lesions and restoring the affected tissue. In many situations, dermonecrosis is so extensive that it requires skin grafts [9].

The strategies already employed to treat skin lesions include phytotherapy and popular medicinal plant products. Indeed, the effectiveness of some herbal agents used in traditional medicine has been evaluated and confirmed by researchers worldwide [17, 18]. For instance, specialists in wound healing have shown great interest in the use of copaiba oil, a popular medicine in Brazil, extracted from trees of the genus *Copaifera* (Leguminosae-Caesalpinioideae family) to treat scarring [19, 20, 21]. Its property of healing wounds and ulcers is attributed to the presence of medicinally important active components [22]. Copaiba oil is popularly used, especially in the Amazon, as an anti-inflammatory, healing, and antiseptic product that can be administered orally, topically, or vaginally [19]. This oil stands out for its therapeutic properties not only in the Amazon region, but

also in northeastern Brazil. Moreover, it is also exported owing to its broad indications for such diseases as cystitis, bronchitis, chronic diarrhea, rheumatism, and psoriasis [23–26].

Sesquiterpene hydrocarbons are the major compounds derived from *Copaifera* oleoresins, the most dominant one being β -caryophyllene, which accounts for more than 90% of the total composition [27]. Sesquiterpenes are responsible for many of the pharmacological activities of copaiba oleoresins. However, some studies correlate increased anti-inflammatory activity with the presence of high levels of diterpenes [28, 29].

No study exists on the potential use of plants with healing effects as therapeutic tools for local manifestations induced by the venom of *Loxosceles sp.* In this context, any scientific evidence describing the healing effects of plant derivatives on skin lesions by loxoscelism would pave the way for the development of topical medicines with wide applicability and benefits for those injured by *Loxosceles* spiders. Thus, the present study evaluated the healing effects of copaiba oil on dermonecrosis induced by the venom of *L. intermedia*, also known as the brown spider.

Methods

L. intermedia Venom

The venom of *L. intermedia* was obtained from the Laboratory of Arthropods of Instituto Vital Brazil from adult specimens of *L. intermedia*. The spiders were made to fast for a week followed by extraction of the crude venom.

Animals

Adult male albino rabbits (*Oryctolagus cuniculus*), weighing 2.5 ± 3.0 kg, were used for *in vivo* tests. These were obtained from the animal colony at the Vital Brazil Institute. All rabbits were fed food and water *ad libitum* under a 12-hour light–dark cycle at $22 \pm 2^\circ\text{C}$ throughout the experiment. Venom of *L. intermedia* was injected intradermally into the back of rabbits to induce cutaneous lesions.

Plant Material

The *Copaifera spp.* oil (copaiba oil) was acquired from a pool of individuals from eastern Amazon ($2^\circ 08' 14''$ – $2^\circ 12' 26''$ S and $48^\circ 47' 34''$ – $48^\circ 14'$ W, at an elevation of 16 m above sea level), state of Pará, Brazil. The oil was extracted using the method followed by the local population: Drilling of the trunk of the *Copaifera* tree and insertion of a PVC cannula, through which the oil flows. After the extraction is finished, the hole is sealed with the use of clay. A total of 1 mL of copaiba oil was administered topically at the site of injury.

Gas Chromatography–Mass Spectrometry Analysis of Sesquiterpenes in *Copaifera spp.* Oleoresin

The sesquiterpenes present in the *Copaifera spp.* oleoresin were analyzed in a gas chromatograph coupled to a mass spectrometer

(GC-MS, QP2010SE; Shimadzu). The following chromatographic conditions were used: Rtx-5 capillary column (30 m × 0.25 mm × 0.25 μM MMID); helium as carrier gas at a flow rate of 1.5 mL/minute, oven temperature maintained at 120°C for 2 minutes followed by an increase of 3°C/minute to 160°C for 2 minutes. It was then increased by 8°C/minute to a final temperature of 290°C for 5 minutes; injector temperature of 270°C; and detector temperature of 290°C, operating at 40 to 400 m/z scan mode with electron impact of 70 eV. A volume of 1.0 μL with 1:20 split ratio was injected into the column. The results obtained from analysis of retention times of peaks in the sesquiterpene chromatograms were compared to the data reported in the literature. We also compared the fragmentation spectra of sesquiterpenes with similarity over 90% to those contained in the NIST Library 05.

Minimum Necrotic Dose Determination

To determine the minimum necrotic dose (MND), rabbits were divided into three groups, each consisting of four rabbits. The backs of these rabbits were first shaved, following which they were inoculated with increasing doses of venom (1.2, 2.4, and 12.0 μg/kg). Cutaneous lesions were observed at 6, 24, and 72 hours after injection. The MND was defined as the lowest dose of venom capable of inducing a necrotic area of at least 1 cm² in 72 hours in 100 % of animals.

Experimental Groups

The animals were separated into three groups ($n = 4$ per group) as follows: control, venom, and venom plus topical copaiba oil treatment. Each group underwent the same routine observation adopted for calculating the MND. The control group received an intradermal injection of 200 μL of physiologic saline solution (PSS). All other groups received intradermal injection of *L. intermedia* venom at twice the MND determined in a final volume of 200 μL. Topical application of copaiba oil was carried out 6 hours after venom injection and repeated daily for 30 days. Each application using 1 mL of the product completely covered the wound area. During other days of treatment, the remaining product was removed with saline jets, without compromising the newly formed tissue. After washing with 0.9% saline, the product was applied as described above. On days 3, 10, and 30 after the spider venom inoculation and respective treatments, animals were euthanized in a CO₂ chamber, and skin samples were obtained from the lesioned sites for histopathological analysis according to the procedures described below.

Blood Analysis

At the beginning of the experiments, blood was collected from rabbits' ear vein (time 0), prior to inoculation of venom or PSS. After 24 hours, a fresh blood sample was collected from all animals to measure hematological parameters, such as total leukocytes and platelets, using an automatic counter (CC530-CELM). Differential counting was performed on hematological glass slides.

Macroscopic Lesion Analysis

Macroscopic lesions were analyzed by measuring the wound area. For this, photomicrographs of the lesions were obtained at 0 and 6 hours, and 1, 3, 10, 15, and 30 days after venom inoculation to monitor the healing process. These images were generated using a digital camera (Sony Cyber-Shot DSC-W350, 14.1 mega pixels), which was kept at a constant distance from the tripod base. The injury area was evaluated using the software Image-Pro (unpaid).

Histopathological Analysis and Skin Processing

Animal skins in the control group and the venom group, containing the venom-induced lesion area, were removed and processed for histopathological analysis. All samples were fixed in 10% paraformaldehyde in a phosphate buffer (pH 7.4) for 48 hours and subsequently dehydrated in increasing concentrations of ethanol. These were next embedded in paraffin, sectioned and placed on slides (5 microns) where they were stained with hematoxylin-eosin and picosirius red.

Total Collagen Determination

To quantify the total collagen present in the samples, hydroxyproline was measured using the adapted methodology recommended by the Association of Analytical Communities (AOAC). The skin was macerated and then hydrolyzed with 1 mL of 6 M hydrochloric acid per 0.01 g of skin (maximum 0.08 g) for 4 hours at 130°C. In a separate tube, 1 mL of chloramine T and 5 μL of skin hydrolysate were mixed and maintained at room temperature for 20 minutes. Then, 1 mL of perchloric aldehyde (15 g of dimethylaminobenzaldehyde, 60 mL of n-propanol, 26 mL of 60 % perchloric acid, and n-propanol to complete the volume to 100 mL) was added and stored at 60 °C for 15 minutes. Chloramine T is oxidized by hydroxyproline to pyrrole, which, in turn, reacts with perchloric aldehyde to form a red-purple complex, the absorbance of which could be measured at 550 nm. The quantification of samples was performed by interpolating the absorbance results obtained using the linear regression equation of the standard curve ($y = 0.5972x + 0.0142/R = 0.99$).

Statistical Analysis

Data are expressed as mean ± standard error. The Student's *t* test was employed to analyze data from the two groups. For analysis of the various groups and temporal procedures, we used ANOVA, followed by Bonferroni's post-test. Linear regression was employed to design curves. *P*-values < 0.05 were considered statistically significant.

Results

Analysis of Sesquiterpenes and Diterpenes Present in Copaiba Oil

The qualitative and quantitative analysis of oleoresin led to the identification of 24 peaks of sesquiterpenes and diterpenes that

represented slightly more than 50 % of the total composition (Table 1). The major compounds found in the sample were the sesquiterpenes α -bergamotene (7.04 %) and β -caryophyllene (11.48 %). Other compounds frequently present in copaiba

oleoresins in the range of 1 to 5% included copaene (1.61 %), α -curcumene (4.62 %), and β -humulene (3.05 %). The major diterpenes found in the copaiba oil were kaur-16-ene (1.4 %), kaurenoic acid (2.0 %), and cativic acid (2.25 %) (Table 1).

Table 1. Sesquiterpenes and Diterpenes identified in the *Copaifera* oleoresin, compared with the literature and fragmentation

spectrum. It was possible to identify peaks of 24 compounds that represent little more than 50 % of the total composition. The major compounds found were the sesquiterpenes α -bergamotene (7.04 %) and β -caryophyllene (11.48 %). Some compounds frequently presents in copaiba oleoresins were found at 1 to 5 %, including Copaene (1.61 %), α -curcumene (4.62 %) and β -humulene (3.05 %). The major diterpenes found in the copaiba oil were Kaur-16-ene (1.4 %), kaurenoic acid (2 %) and Cativic acid (2.25 %).

Compounds	Retention Index	Composition (%)
Cyclosativene	1125	0,82
Copaene	1221	1,61
α -cedrene	1403	4,18
α -zingiberene	1451	0,40
α -cubebene	1344	1,56
δ -selinene	1481	0,47
β -Caryophyllene	1494	11,48
α -bergamotene	1430	7,04
α -guaiene	1490	1,32
β -farnesene	1440	0,75
α -caryophyllene	1579	2,48
α -curcumene	1524	4,62
β -humulene	1574	3,05
γ -cadinene	1435	0,31
δ -cadinene	1469	1,39
Bergamotol	1673	0,58
α -bisabolene	1625	0,83
Guaiol	1614	0,27
Aromadendrene	1380	0,42
α -caryophyllene	1579	0,74
β -bisabolene	1619	0,3
Kaur-16-ene	1789	1,4
Cativic acid	2016	2,25
Kaurenoic acid	2050	2
Total of identified substances		50,27

Minimum Necrotic Dose Determination (MDN)

The MDN was defined as 2.4 $\mu\text{g}/\text{kg}$, because this was the lowest venom dose capable of inducing a necrotic area of at least 1 cm^2 in 72 hours in 100 % of animals (data not shown).

L. intermedia Venom Reduced Platelet and Heterophil Count

A significant reduction in the number of platelets was observed in all groups inoculated with *L. intermedia* venom (4.8 $\mu\text{g}/\text{kg}$)

as compared with the control group (Figure 1A). Although the number of total leukocytes did not differ significantly between the groups (Figure 1B), a notable reduction in the number of heterophils in the blood of the animals inoculated with *L. intermedia* venom was reported. Treatment of animals with copaiba oil curbed the reduction in heterophil count induced by spider venom (Figure 1C). No significant difference was observed between the groups analyzed with respect to lymphocytes (Figure 1D).

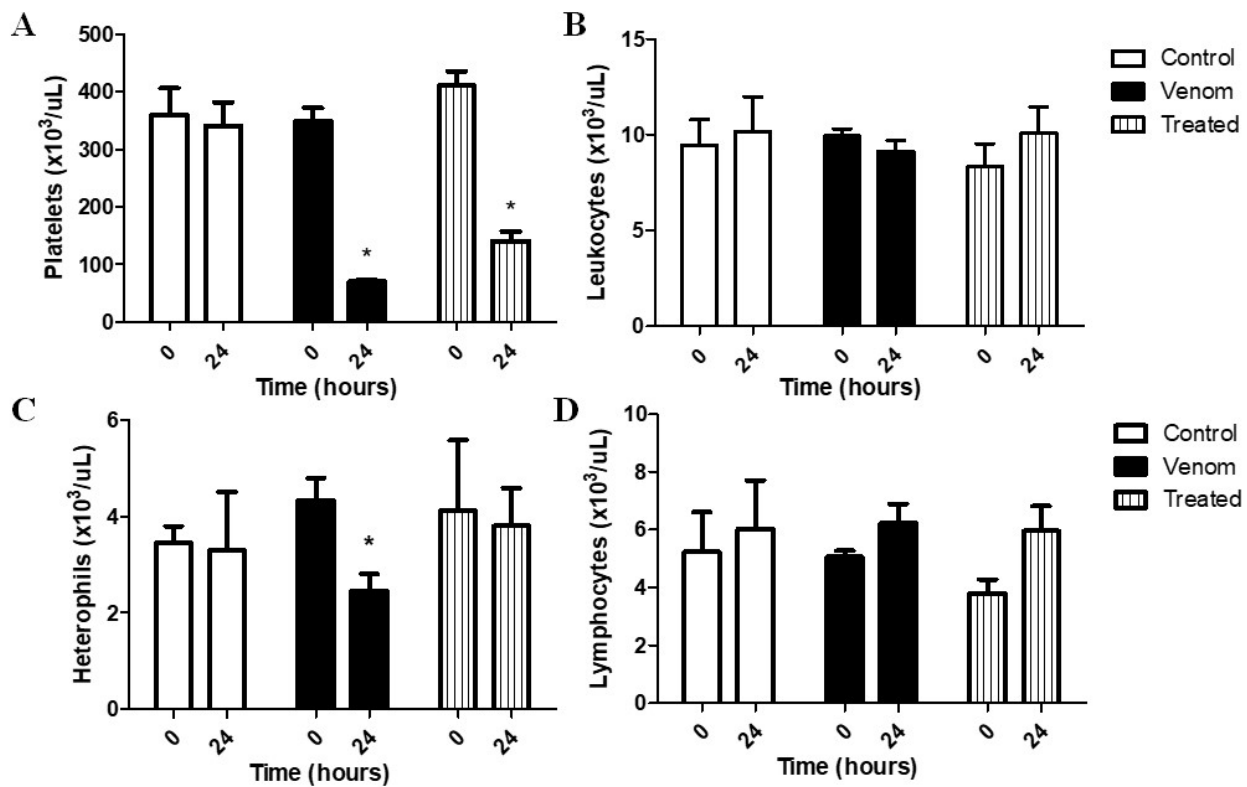


Figure 1. Effect of treatment with copaiba oil after *Loxosceles intermedia* venom injection on blood cells. Platelets (a) and heterophils (c) count showed significant reduction after venom injection (4.8 $\mu\text{g}/\text{kg}$). The treatment was efficient in inhibiting the decrease of heterophils in the blood 24 hours after venom inoculation * $p < 0.05$ / ANOVA. However, groups inoculated with venom and treated with copaiba oil showed no significant difference from the control group at total leukocyte (b) and lymphocyte count (d). $n = 4$ animals per experimental group.

Topical Treatment with Copaiba Oil and Effects on Cicatrization

Rabbits were evaluated for the effects of venom injected intradermally (4.8 $\mu\text{g}/\text{kg}$). Macroscopic analysis of skin lesions formed after inoculation of venom revealed typical dermonecrosis in all animals, however with different healing profiles. Topical application of copaiba oil induced formation of a thick but limited crust at the site of venom inoculation, without the presence of scarring at 30 days after venom inoculation (Figure 2A). For the animals that received topical treatment with copaiba oil, smaller lesions with mild erythema were observed after 3 days. Ten days after venom injection, the lesion area of the group receiving copaiba oil treatment was larger than that of the untreated group (Figure 2B).

L. intermedia Venom Induced Local Skin Inflammation, Muscular Necrosis, and Hemorrhaging

For histopathological evaluation, the skins were removed from rabbits 3, 10, and 30 days after venom inoculation. In control animals, PSS had no effect on histopathological parameters on the mentioned days (Figure 3A, D, G). Animals inoculated with the venom showed heavy bleeding, thickening of dermis and epidermis, and presence of intense inflammatory infiltrate 30 days after injection (Figure 3B). These animals presented intravascular

clots as well. The group inoculated with venom followed by treatment with copaiba oil also showed heavy bleeding, with inflammatory infiltrate and lesions on the epidermis (Figure 3C). On day 10 after venom injection, a significant inflammatory infiltrate in the muscular tissue was observed (Figure 3E, F). Furthermore, treated animals showed crucial tissue redefinition between papillary and reticular dermis (Figure 3F), an important histological aspect absent in the untreated group (Figure 3E). At day 30 after venom inoculation, dermis and epidermis had regained their integrity, with regeneration of muscle tissue and persistent inflammatory infiltrate (Figure 3H). Interestingly, animals inoculated with venom and treated with copaiba oil showed similarities with control groups, including integrity of all layers of the skin, high number of hair follicles, and sparse dermal inflammatory infiltrate (Figure 3G, I).

Copaiba Oil Treatment Reduced Collagen Production

Optical microscopy analysis did not reveal significant differences with respect to collagen fiber deposition in all groups (Figure 4A, C). Polarized light microscopy was employed to analyze the distribution of collagen types I (red) and III (green) following picosirius red staining. A large collagen deposit was detected in the venom-inoculated group 30 days after venom injection, in comparison with control and copaiba-treated

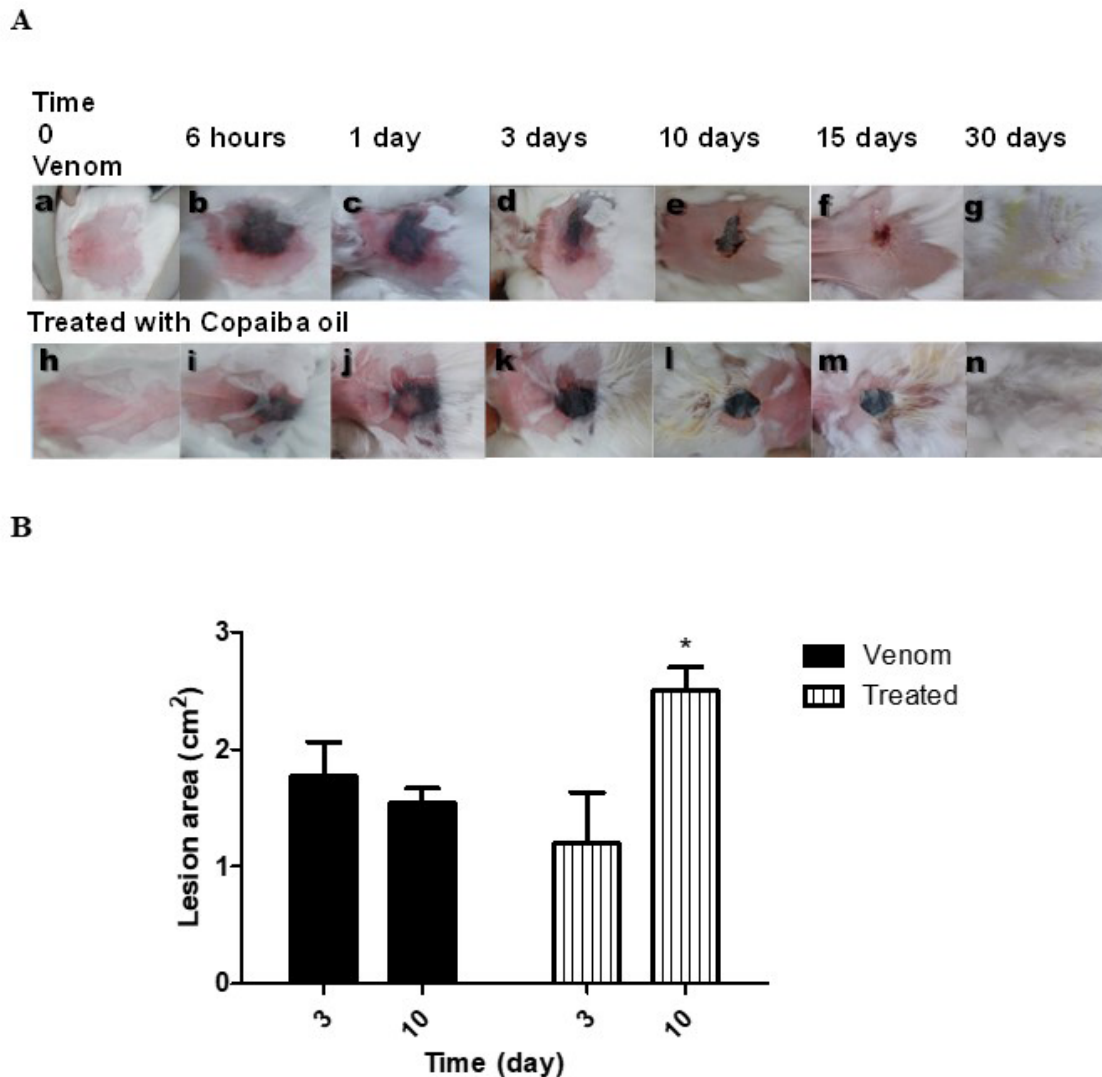


Figure 2. Evolution of the lesion 30 days after *Loxosceles intermedia* venom injection. Macroscopic comparison of animals that received only the venom, compared to those treated with copaiba oil after venom inoculation showed lesions with smaller area and with mild erythema. The copaiba oil induced a formation of thicker crust more delimited, without the presence of scarring on the skin (a). Ten days after venom injection the lesion area of the group that received the treatment with copaiba oil was larger than the untreated group (b). n = 4 animals per experimental group.

animals (Figure 4G, I). Type I and type III collagen fibers were frequently observed in the control group (Figure 4J). The venom-induced significant changes in the dermis and type I collagen fibers were predominantly noted in this group (Figure 4K). Copaiba oil treatment restored the mixed profile of collagen fibers, such that both red and green stains were observed, similar to control groups (Figure 4L).

Total collagen was measured by quantification of hydroxyproline. All animals showed similar hydroxyproline levels on day 3 after venom exposure and respective treatments. However, 30 days after venom injection, hydroxyproline levels were significantly increased in comparison with the control group. Treatment with copaiba oil at this stage did reduce the hydroxyproline levels in comparison to the venom group although these were still elevated when compared with the control group (Figure 4M).

Discussion

The oleoresin of *Copaifera* is widely used in Brazilian traditional medicine as an anti-inflammatory and healing agent [20]. However, evidence on its effectiveness and protective roles in treating injuries caused by *Loxosceles* spider bite is scarce. The results of the present study demonstrated the efficacy of topical application of copaiba oil in healing of dermonecrosis caused by injection of brown spider venom. We suggest that copaiba oil exerts its therapeutic effects on skin lesions induced by *L. intermedia* venom through various morphological changes, consequently leading to repair of damaged skin.

Distinct compounds identified in copaiba oleoresin are potentially responsible for some of the pharmacological properties, for example, β -caryophyllene, characterized by anti-inflammatory, antibacterial, anti-edema, antifungal, and

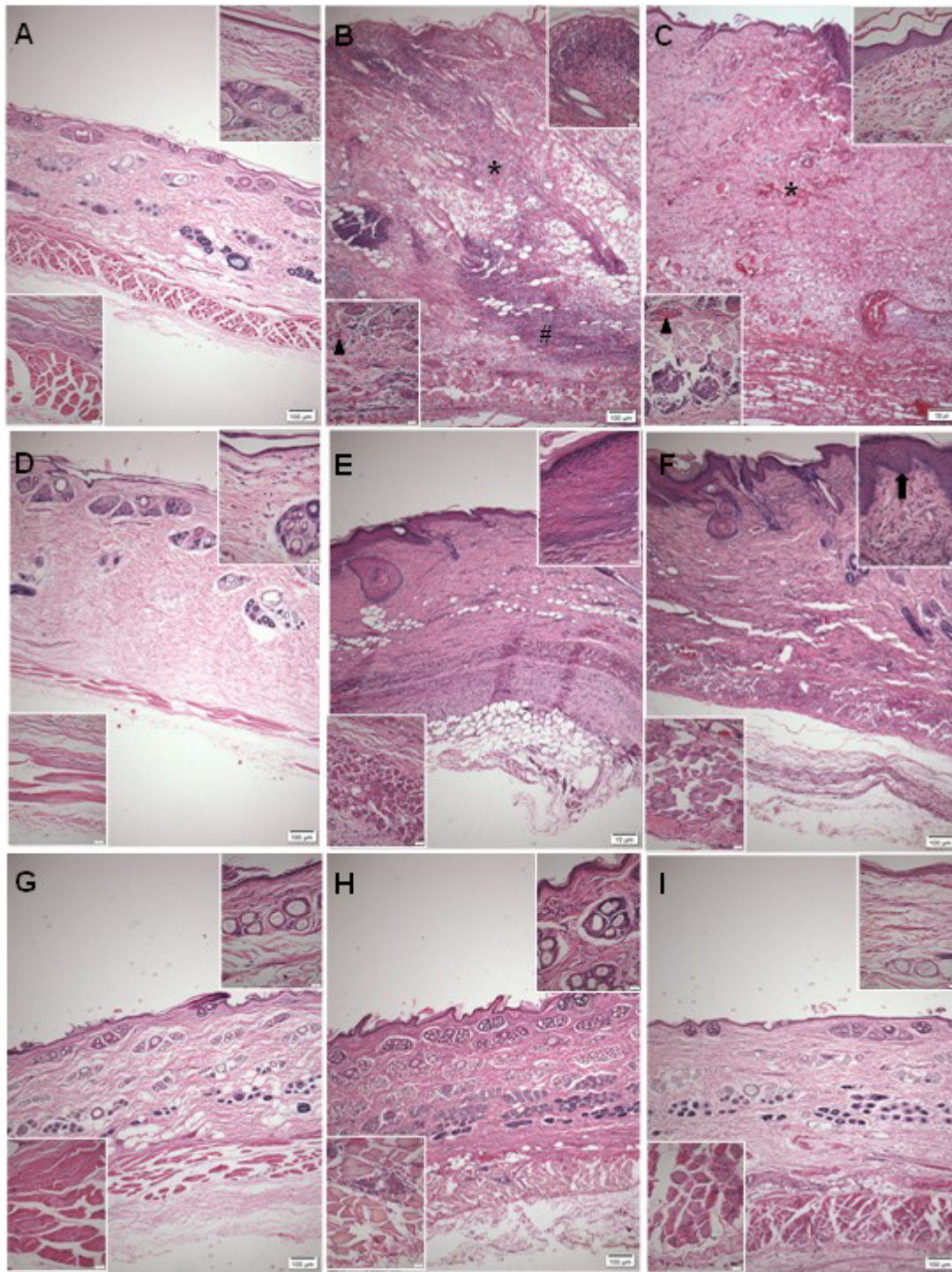


Figure 3. Photomicrographs of the skin of rabbits 3, 10 and 30 days after *L. intermedia* venom inoculation in the back. The control group presented integrity of the skin layers (**a/d/g**). In the animals that received venom injection (4.8 µg/kg) heavy bleeding in the dermis (*), epidermal thickening (upper insert - **b**), the presence of intense inflammatory infiltrate in muscle (lower insert - **b**) and hypodermis tissue (#) and blood vessels with clot () were observed 3 days after inoculation (**b**). In animals inoculated with venom and treated with copaiba oil, bleeding (*), injury of the epidermis (upper insert - **c**) and inflammatory infiltrates in muscle tissue (lower insert - **c**) were observed 3 days after venom inoculation (**c**). After 10 days, the dermal thickness was reduced in venom group (**e**), but the epidermis remained thick (upper insert - **e**); on the other hand, in the treated group, dermal thickness was reduced (**f**), but redefinition was detected between papillary and reticular dermis (upper insert - **f**). After 30 days of regeneration of the dermis, epidermis (upper insert - **h**) and muscle tissue, marked by the presence of central nuclei (inferior insert - **h**) after 30 days in the venom group (**h**); the treated group also showed regeneration of dermis, epidermis (upper insert - **i**) and muscle tissue (lower insert - **i**), marked by an increase in the number of hair follicles (**i**). n = 4 animals per experimental group.

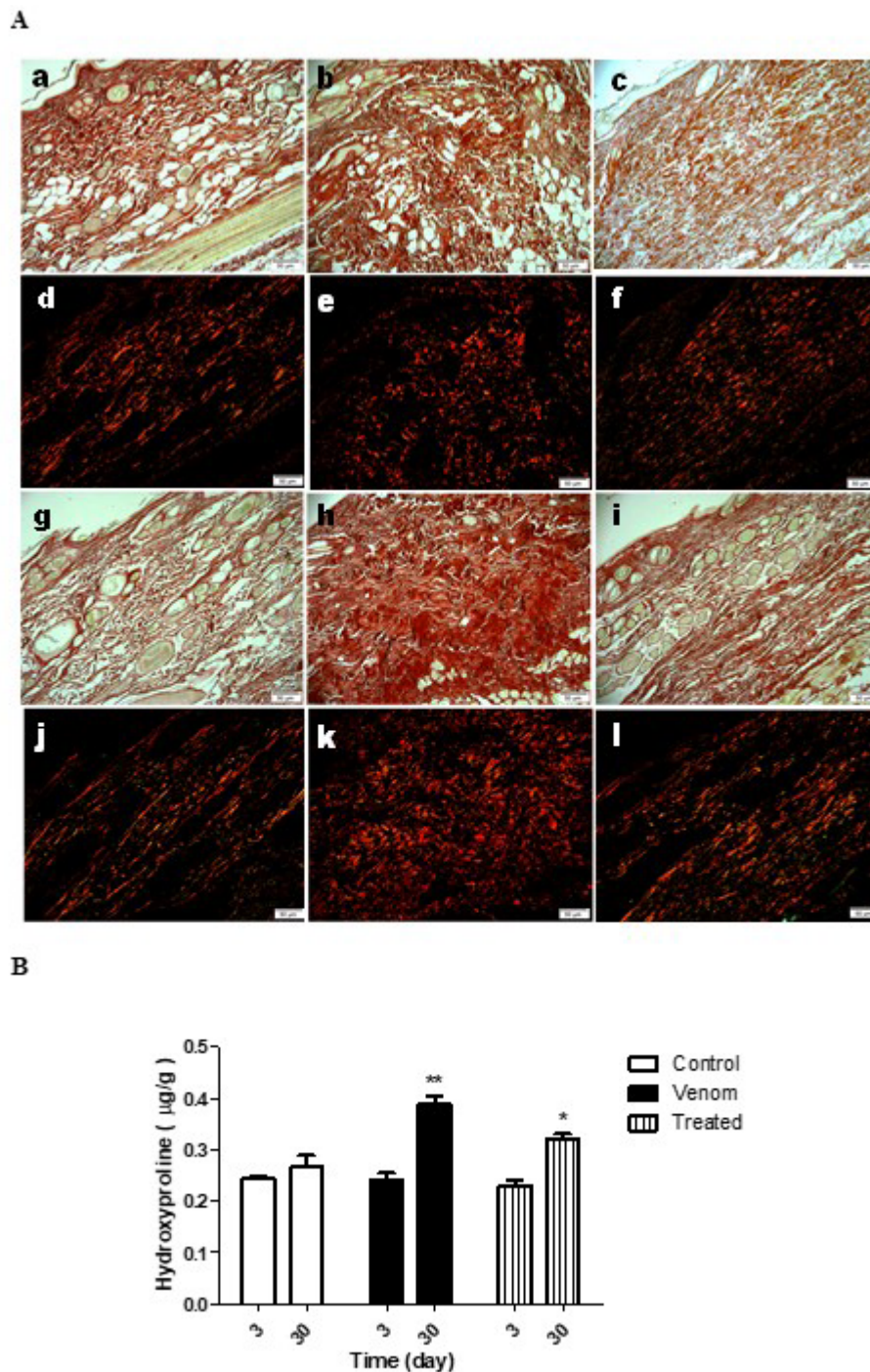


Figure 4. Photomicrographs of collagen on skin of rabbits 3 and 30 days after inoculation of *L. intermedia* venom in the back. Picrosirius red staining under optical light reveals total collagen as red, polarized light collagen type I as red fibers and collagen type III as green fibers. The control animals presented normal distribution of collagen types on the skin at 3 (a - a/d) and 30 days (a - g/j), and did not differ in total collagen quantification by hydroxyproline (b). The animals inoculated with venom at 4.8 µg/kg did not differ at day 3 post-inoculation compared to the control group (a - b/e) but showed increase of collagen deposition at 30 days (a - h/k), quantified by hydroxyproline (b * $p < 0.001$ / ANOVA). The animal group inoculated with venom and treated with copaiba oil showed no difference at day 3 (a - c/f), but at 30 days presented less intense increase of collagen (a - i/l), quantified by hydroxyproline (b * $p < 0.05$ / ANOVA). n = 4 animals per experimental group.

antipsoriatic effects [21, 30, 31]. Other compounds present in copaiba oleoresin (viscous fluid) include kaurene and labdane diterpenoids, having broad-spectrum biological activities, as previously reported, including potential anti-inflammatory, antimicrobial, antitumor, and larvicidal properties [22, 28, 29].

Rabbit models show a high similarity to clinical events related to *Loxosceles* envenomation in humans, such as occurrence of intravascular coagulation causing occlusions of venules and arterioles that result in tissue hypoxia [32]. Intravascular coagulation can occur in the lungs, liver, and kidneys [7], when

the venom reaches the systemic circulation. In severe cases, it may progress to death resulting from kidney failure [33]. The abrupt reduction in platelet count observed in venom-inoculated groups could not be countered by the application of copaiba oil after 24 hours. Reduced platelet count and increased fibrinogen synthesis are the first systemic responses of rabbits to injection of *Loxosceles* spider venom, approximately 12 hours after envenomation [12], a response very similar to that noted in humans.

Cellular changes in the bone marrow and peripheral blood of rabbits after exposure to *L. intermedia* venom have been reported. Thrombocytopenia is an important clinical sign during the diagnosis of *L. intermedia* spider envenomation [11]. Thrombocytopenia and a high number of heterophils were detected in the bloodstream of venom-inoculated rabbits, which were directly related to histopathological findings obtained from skin biopsies [34]. Evaluation of leukocyte mobilization and biochemical parameters in the blood of rabbits revealed that platelet functions and blood coagulation showed a time-dependent trend at 3, 24, 48, 72, and 120 hours after *Loxosceles* envenomation. These levels were associated with initial leukopenia and thrombocytopenia, posterior leukocytosis, platelet aggregation, elevation of fibrinogen levels, and reduction of coagulation factor VII [35]. Increase in leukocytes and heterophils occurred at 72 hours, the same time at which red blood cells declined [12].

On the other hand, in the current study, blood collected 24 hours after inoculation of spider venom from *L. intermedia* did not show significant differences in the cellularity of total leukocytes in any group. A significant reduction of heterophils was shown after venom injection but not after treatment with copaiba oil. Diminution in the number of circulating heterophils after 24 hours may be related to an acute inflammatory response, considering that these cells are found at the injury site within a few hours after venom injection and are reduced in blood circulation after 24 hours, as also observed in mice [1]. Together, these results indicated a lesser migration of heterophils to the skin and possible protective effect associated with reduced heterophilic response after venom injection and treatment with copaiba oil. These results imply that copaiba oil has the potential to partially control the inflammatory response, once heterophil levels in blood circulation decrease.

Histopathological analysis of the skin obtained from venom-inoculated rabbits demonstrated swelling of dermal endothelial cells [36], followed by deposition of intravascular fibrin, endothelial thickening, vasodilation and inflammatory cell infiltration, predominantly by polymorphonuclear cells [37]. Moreover, 24 hours after venom administration, a massive infiltration of leukocytes and platelets, bleeding, and thrombus formation at the site of venom inoculation were observed [35]. Long-term exposure to venom induces necrosis of myofibrils and infiltration of leukocytes, damaging the skeletal muscle. This, in turn, causes severe destruction of the epidermal integrity and necrosis of the connective tissue enriched with collagen

fibers near the epidermis — the last events observed during the development of dermonecrotic injury in rabbits [5].

Wound healing is a complex process. Major shortcomings in this process may occur in the early stages, producing severe edema, reducing vascular proliferation, and decreasing cellular elements, such as leukocytes, macrophages, and fibroblasts [38]. Studies on the healing property of copaiba oil have concentrated on the resin phase owing to the presence of diterpenes, but cellular and molecular mechanisms of its potential therapeutic actions are poorly understood. In the present study, no acceleration of the healing process was observed in any animal group. However, the venom group demonstrated an adherent crust that broke away before 30 days of monitoring. This feature was not observed when animals received copaiba oil; in contrast, these animals showed a larger area of injury, at the 10th day, which may plausibly account for the scar formation observed in the venom group.

The need for precision in tissue healing is impaired by the speed of repairing the tissue damage, without aggravating it. In this context, what occurs most often is the formation of scars, where the tissue will lose its function [39]. Thus, the ideal treatment of wounds should also value the quality of the healing process, for which the deposition of collagen is vital for recovering the lost cell mass in the lesion, thus refilling the damaged tissue. However, exaggerated deposition of collagen can cause fibrosis and impair the formation of functional tissue [40]. After 30 days, the animals treated with copaiba oil presented a distribution of collagen fibers more similar to the control group, which demonstrates a higher quality of healing. If the distribution of collagen is closer to that in the control, it is indicative that the skin is more resistant to possible lesions, thus exerting its function of protecting the organism. Our results demonstrated that copaiba oil promoted the regeneration of type III collagen fibers, with a collagen-fiber distribution similar to the normal skin of the animal. It can be inferred that copaiba oil may improve the process of skin regeneration, but further studies should be done to evaluate the structure of this tissue.

Conclusions

The increasing number of accidents caused by brown spider bites in recent years has become a major public health concern in Brazil. Thus, the study of the actions of both venom and drugs has gained extreme importance to better manage envenomation and to provide proper treatment. The present work demonstrated the potential of copaiba oil to interfere in and curb the progression of spider-bite-induced dermonecrosis. The results described herein suggest that treatment with copaiba oil may modify scarring via deposition of collagen, thereby stimulating the growth of hair follicles and regeneration of muscle tissues. In addition, we now report that copaiba oil efficiently inhibits the heterophil reduction in the blood after venom injection. In light of the broad-spectrum applications of copaiba oil and its economic importance in Brazil, the present study encourages further research to elucidate its effects on wound healing.

Acknowledgements

The author acknowledges the support by Universidade Federal Fluminense and Instituto Vital Brazil.

Abbreviations

Not applicable.

Availability of data and material

All data generated or analyzed during this study are included in this published article.

Funding

This research was supported by grants from FAPERJ. Moreover, this publication was supported in part by the Coordination for the Improvement of Higher Education Personnel (CAPES) through “Programa Editoração CAPES” – call No. 3/2016, grant No. 0722/2017, record No. 88881.142062/2017-01 and by the National Council for Scientific and Technological Development (CNPq) and Coordination for the Improvement of Higher Education Personnel (CAPES) through “Programa Editorial CNPq/CAPES” call No. 18/2018, grant No. 404770/2018-5.

Competing interests

The authors declare that they have no competing interests.

Authors' contributions

MFR carried out the conception and design of the study, the acquisition, analysis and interpretation of the data and the drafting of the manuscript. FLO carried out analysis and interpretation of data and helped to draft the manuscript. PFC, APS and ASN participated in acquisition of data, histological analysis and interpretation of data. AMS and TBM participated in experimental design and helped draft the manuscript. CMVS conceived the study, and participated in its design and coordination. SCE conceived the study, and participated in its design and coordination and helped to draft the manuscript. All authors read and approved the final manuscript.

Ethics approval

All animal procedures were performed in accordance with protocols approved by the Ethics Committee on Animal Use of the Vital Brazil Institute (protocol no. 01/2013).

Consent for publication

Not applicable.

References

- Ribeiro MF, Oliveira FL, Monteiro-Machado M, Cardoso PF, Guillarducci-Ferraz VV, Melo PA, et al. Pattern of inflammatory response to *Loxosceles intermedia* venom in distinct mouse strains: a key element to understand skin lesions and dermonecrosis by poisoning. *Toxicon*. 2015;96:10-23.
- Corrêa MA, Okamoto CK, Goncalves-de-Andrade RM, van den Berg CW, Tambourgi DV. Sphingomyelinase D from *Loxosceles laeta* venom induces the expression of MMP7 in human keratinocytes: contribution to dermonecrosis. *PLoS One*. 2016;11(4):e0153090.
- Tambourgi DV, Paixao-Cavalcante D, Goncalves de Andrade RM, Fernandes-Pedrosa Mde F, Magnoli FC, Paul Morgan B, et al. *Loxosceles* sphingomyelinase induces complement-dependent dermonecrosis, neutrophil infiltration, and endogenous gelatinase expression. *J Invest Dermatol*. 2005;124(4):725-31.
- Nowatzki J, de Sene RV, Paludo KS, Veiga SS, Oliver C, Jamur MC, et al. Brown spider venom toxins interact with cell surface and are endocytosed by rabbit endothelial cells. *Toxicon*. 2010;56(4):535-43.
- Gremski LH, Trevisan-Silva D, Ferrer VP, Matsubara FH, Meissner GO, Wille AC, et al. Recent advances in the understanding of brown spider venoms: from the biology of spiders to the molecular mechanisms of toxins. *Toxicon*. 2014;83:91-120.
- Chaves-Moreira D, Senff-Ribeiro A, Wille ACM, Gremski LH, Chaim OM, Veiga SS. Highlights in the knowledge of brown spider toxins. *J Venom Anim Toxins incl Trop Dis*. 2017;23:6. doi: 10.1186/s40409-017-0097-8.
- Futrell JM. Loxoscelism. *Am J Med Sci*. 1992;304(4):261-7.
- Cacy J, Mold JW. The clinical characteristics of brown recluse spider bites treated by family physicians: an OKPRN Study. Oklahoma Physicians Research Network. *J Fam Pract*. 1999;48(7):536-42.
- Delasotta LA, Orozco F, Ong A, Sheikh E. Surgical treatment of a brown recluse spider bite: a case study and literature review. *J Foot Ankle Surg*. 2014;53(3):320-3.
- Isbister GK, Fan HW. Spider bite. *Lancet*. 2011;378(9808):2039-47.
- Pauli I, Puka J, Gubert IC, Minozzo JC. The efficacy of antivenom in loxoscelism treatment. *Toxicon*. 2006;48(2):123-37.
- Pauli I, Minozzo JC, da Silva PH, Chaim OM, Veiga SS. Analysis of therapeutic benefits of antivenin at different time intervals after experimental envenomation in rabbits by venom of the brown spider (*Loxosceles intermedia*). *Toxicon*. 2009;53(6):660-71.
- Barbato KC, Lira MS, Araujo CA, Pareja-Santos A, Távora BC, Prezotto-Neto JP, et al. Inflammatory mediators generated at the site of inoculation of *Loxosceles gaucho* spider venom. *Toxicon*. 2010;56(6):972-9.
- Swanson DL, Vetter RS. Bites of brown recluse spiders and suspected necrotic arachnidism. *N Engl J Med*. 2005;352(7):700-7.
- da Silva PH, da Silveira RB, Appel MH, Mangili OC, Gremski W, Veiga SS. Brown spiders and loxoscelism. *Toxicon*. 2004;44(7):693-709.
- Paixao-Cavalcante D, van den Berg CW, Goncalves-de-Andrade RM, Fernandes-Pedrosa Mde F, Okamoto CK, Tambourgi DV. Tetracycline protects against dermonecrosis induced by *Loxosceles* spider venom. *J Invest Dermatol*. 2007;127(6):1410-8.
- Strauch MA, Tomaz MA, Monteiro-Machado M, Ricardo HD, Cons BL, Fernandes FF, et al. Antiphidic activity of the extract of the Amazon plant *Humirianthera ampla* and constituents. *J Ethnopharmacol*. 2013;145(1):50-8.
- De Oliveira EC, Fernandes CP, Sanchez EF, Rocha L, Fuly AL. Inhibitory effect of plant *Manilkara subsericea* against biological activities of *Lachesis muta* snake venom. *Biomed Res Int*. 2014;2014:408068.
- Cascon V, Gilbert B. Characterization of the chemical composition of oleoresins of *Copaifera guianensis* Desf., *Copaifera duckei* Dwyer and *Copaifera multijuga* Hayne. *Phytochemistry*. 2000;55(7):773-8.
- Cavalcanti Neto AT, Theodora TPA, Pereira SLS, Turatt E. Comparative evaluation between copaiba oil-resin and chlorhexidine digluconate on wound healing. *Histological study in rats*. *Rev Odontol UNESP*. 2005;34(2):107-12.
- Ricardo LM, Dias BM, Múggee FLB, Leite VV, Brandão MGL. Evidence of traditionality of Brazilian medicinal plants: The case studies of *Stryphnodendron adstringens* (Mart.) Coville (barbatimão) barks and *Copaifera* spp. (copaiba) oleoresin in wound healing. *J Ethnopharmacol*. 2018;219:319-36.
- Veiga Jr VF, Pinto AC. O gênero *Copaifera* L. *Quím Nova*. 2002;25(2):273-86.
- Gelmini F, Beretta G, Anselmi C, Centini M, Magni P, Ruscica M, et al. GC-MS profiling of the phytochemical constituents of the oleoresin

- from *Copaifera langsdorffii* Desf. and a preliminary *in vivo* evaluation of its antipsoriatic effect. *Int J Pharm.* 2013;440(2):170-8.
24. Campos C, de Castro AL, Tavares AM, Fernandes RO, Ortiz VD, Barboza TE, et al. Effect of free and nanoencapsulated copaiba oil on monocrotaline-induced pulmonary arterial hypertension. *J Cardiovasc Pharmacol.* 2016;69(2):79-85.
 25. Otaguiri ES, Morguette AEB, Biasi-Garbin RP, Morey AT, Lancheros CAC, Kian D, et al. Antibacterial combination of oleoresin from *Copaifera multijuga* Hayne and biogenic silver nanoparticles towards *Streptococcus agalactiae*. *Curr Pharm Biotechnol.* 2016;18(2):177-90.
 26. Motta EV, Lemos M, Costa JC, Banderó-Filho VC, Sasse A, Sheridan H, et al. Galloylquinic acid derivatives from *Copaifera langsdorffii* leaves display gastroprotective activity. *Chem Biol Interact.* 2017;261:145-55.
 27. da Trindade R, da Silva JK, Setzer WVN. *Copaifera* of the Neotropics: A Review of the Phytochemistry and Pharmacology. *Int J Mol Sci.* 2018;19(5):pii: E1511.
 28. Leandro LM, Vargas Fde S, Barbosa PC, Neves JK, da Silva JA, da Veiga-Junior VF. Chemistry and biological activities of terpenoids from copaiba (*Copaifera* spp.) oleoresins. *Molecules.* 2012;17(4):3866-89.
 29. de S Vargas F, D O de Almeida P, Aranha ES, de A Boleti AP, Newton P, de Vasconcellos MC, et al. Biological activities and cytotoxicity of diterpenes from *Copaifera* spp. Oleoresins. *Molecules.* 2015;20(4):6194-210.
 30. Pieri FA, Mussi MCM, Fiorini JE, Moreira MAS, Schneedorf JJM. Bacteriostatic effect of copaiba oil (*Copaifera officinalis*) against *Streptococcus mutans*. *Braz Dent J.* 2012;23(1):36-8.
 31. Santos AO, Ueda-Nakamura T, Dias Filho BP, Veiga Junior VF, Pinto AC, Nakamura CV. Antimicrobial activity of Brazilian copaiba oils obtained from different species of the *Copaifera* genus. *Mem Inst Oswaldo Cruz.* 2008;103(3):277-81.
 32. Zanetti VC, da Silveira RB, Dreyfuss JL, Haoach J, Mangili OC, Veiga SS, et al. Morphological and biochemical evidence of blood vessel damage and fibrinogenolysis triggered by brown spider venom. *Blood Coagul Fibrinolysis.* 2002;13(2):135-48.
 33. Abdulkader RC, Barbaro KC, Barros EJ, Burdmann EA. Nephrotoxicity of insect and spider venoms in Latin America. *Semin Nephrol.* 2008;28(4):373-82.
 34. da Silva PH, Hashimoto Y, dos Santos FA, Mangili OC, Gremski W, Veiga SS. Hematological cell findings in bone marrow and peripheral blood of rabbits after experimental acute exposure to *Loxosceles intermedia* (brown spider) venom. *Toxicon.* 2003;42(2):155-61.
 35. Tavares FL, Sousa-e-Silva MC, Santoro ML, Barbaro KC, Rebecchi IM, Sano-Martins IS. Changes in hematological, hemostatic and biochemical parameters induced experimentally in rabbits by *Loxosceles gaucho* spider venom. *Hum Exp Toxicol.* 2004;23(10):477-86.
 36. Veiga SS, Zanetti VC, Franco CR, Trindade ES, Porcionatto MA, Mangili OC, et al. *In vivo* and *in vitro* cytotoxicity of brown spider venom for blood vessel endothelial cells. *Thromb Res.* 2001;102(3):229-37.
 37. Smith CW, Micks DW. The role of polymorphonuclear leukocytes in the lesion caused by the venom of the brown spider, *Loxosceles reclusa*. *Lab Invest.* 1970;22(1):90-3.
 38. Han G, Ceilley R. Chronic wound healing: a review of current management and treatments. *Adv Ther.* 2017;34(3):599-610.
 39. Gurtner GC, Werner S, Barrandon Y, Longaker MT. Wound repair and regeneration. *Nature.* 2008;453(7193):314-21.
 40. Mori HM, Kawanami H, Kawahata H, Aoki M. Wound healing potential of lavender oil by acceleration of granulation and wound contraction through induction of TGF- β in a rat model. *BMC Complement Altern Med.* 2016;16:144.