

RESEARCH

Open Access

Effects of atropine and propranolol on lung inflammation in experimental envenomation: comparison of two buthidae venoms

Hadjer Saidi, Sonia Adi-Bessalem, Djelila Hammoudi-Triki and Fatima Laraba-Djebari*

Abstract

Background: Previous works had shown that scorpion venom induced neurotransmitter elevation and an inflammatory response associated with various anatomo-pathological modifications. The most dangerous scorpions species in Algeria responsible for these effects are *Androctonus australis hector* (Aah) and *Androctonus amoreuxi* (Aam).

Results: Comparison of the physiopathological effects induced by the two venoms showed differences in the kinetic of cytokine release and in lung injury.

The lung edema was only observed in response to Aah venom and it was correlated with cell infiltration. In order to better understand the involved mechanism in inflammatory response, we used two antagonists, atropine (non-selective muscarinic antagonist) and propranolol (β adrenergic antagonist), which lead to a decrease of cell infiltration but has no effect on edema forming.

Conclusion: These results suggest another pathway in the development of lung injury following envenomation with Aam or Aah venom.

Keywords: Scorpion venoms, Cytokines, Lung inflammation, Acetylcholine, Atropine, Propranolol

Background

Scorpion envenomation is a serious problem common to many countries. In Algeria the most dangerous scorpion species are *Androctonus australis hector* (Aah), *Buthus occitanus tunetanus* (Bot) and *Androctonus amoreuxi* (Aam). Scorpion venoms are known to stimulate the autonomic nervous system simultaneously with release of tissue and medulla catecholamine [1-4]; induce an inflammatory response characterized by increase of cytokines, prostaglandines, leukotrienes, and platelet activated factor (PAF) in sera associated with inflammatory cell infiltration in tissues, especially lung [5-8].

Lung edema is the main cause of death after scorpion stings [9-11]. Its pathogenesis could be due to a non-cardiogenic effect following activation of inflammatory cascade and/or due to a cardiogenic effect [6,12-15].

Catecholamine may induce pulmonary edema via both hemodynamic and inflammatory mechanisms, by augmenting the IL-6 level [16]. The autonomic effects on inflammation are not restricted to catecholamine since the use of muscarinic antagonists may prevent some of the underlying cellular inflammatory responses in the lungs in addition to reducing smooth muscle contraction and mucus secretion [17,18]. Furthermore, the muscarinic antagonist, atropine significantly reduces neutrophil influx in lungs [19]. These polynuclear cells migrate into the lungs as a direct response to various proinflammatory stimuli and might contribute to many disorders such as acute respiratory distress syndrome (ARDS) [20,21]. The present study is designed to investigate the mechanism by which venoms of two scorpions, found in Algeria and belonging to the same genus *Androctonus*, lead to lung inflammation by using atropine and propranolol.

* Correspondence: flaraba@hotmail.com

USTHB, Faculty of Biological Sciences, University of Sciences and Technology
Houari Boumedienne, BP 32 El Alia, Bab Ezzouar, 16111 Algiers, Algeria

Methods

Biological materials

Venoms

Lyophilized venoms of *Androctonus australis hector* and *Androctonus amoreuxi*, with respective LD₅₀ of 0.85 and 0.75 mg/kg, were obtained from the Pasteur Institute of Algeria.

Animals

Male NMRI mice (20 ± 2 g), provided by the Pasteur Institute of Algeria, were used for all experiments. The animals were kept under controlled environment and received food and water *ad libitum*. The experimental protocol was in accord with the guidelines for the care of laboratory animals published by the European Union.

Non-biological materials

Chemical products and reagents used in these experiments were purchased from Sigma (USA), Merck (Germany) or Panreac (Spain). Pharmaceutical products were acquired from other firms, the atropine sulfate from Renaudin (France) and the propranolol from AstraZeneca (France).

Effect of *Androctonus amoreuxi* venom on cytokine levels

Groups of mice were injected by subcutaneous (s.c.) route with a sublethal dose of Aam venom dissolved in saline solution; control mice received 0.2 mL of saline solution alone. Mice were bled at several moments and sera were separated and stored at -20°C.

Cytokines were measured by specific sandwich ELISA, using cytokine Amersham kits for IL-1β, IL-6, and IL-10 according to the manufacturer's instructions. Binding of biotinylated monoclonal antibodies was detected using streptavidin-biotinylated horseradish peroxidase complex and 3, 3', 5, 5' tetramethylbenzidine (TMB). Samples were quantified by comparison with standard curves of recombinant mouse cytokines. The lower limits of detection were 3 pg/mL (IL-1β), 7 pg/mL (IL-6) and 12 pg/mL (IL-10).

Effects of venoms on lung tissue

The effects of a sublethal dose of the two venoms, Aam and Aah, in the presence or absence of antagonists on lungs were evaluated by: estimation of myeloperoxidase activity as a marker of neutrophilia and histological study. Atropine sulfate (1 mg/kg) was injected intraperitoneally (i.p. route) 30 minutes before venoms and propranolol (0.1 mg/kg) was injected by the same route at two moments, 15 minutes before and 15 minutes after venom administration.

Myeloperoxidase activity

Three hours after envenomation by Aam or Aah venom, the removed lungs were homogenized in Tris-HCl buffer 50 mM, pH 6.6, then centrifuged at 6000 rpm for 30 minutes. The first supernatant (S1) was conserved at 4°C and the second supernatant (S2) was recovered after three freeze-thaw cycles of the pellet followed by its centrifugation at the above mentioned buffer conditions, rate and duration. One hundred microliters of S1 and 100 μL of S2 were added to 300 μL of chromogene substrate (0.167 mM O-dianisidine prepared in Tris-HCl 50 mM; pH 6.6 and H₂O₂ 8.8 mM) and the resulting mixture was read at the absorbance of 460 nm after one minute of incubation at room temperature.

Histological study

Lungs were fixed in 4% formaldehyde for 48 hours at room temperature, dehydrated in ethanol, cleared in xylene and embedded in paraffin. Histological sections (3-μm thick) were cut and stained with hematoxylin-eosin (H&E) for microscopic examination (Motic Digital Microscope PAL system).

Statistical analysis

The obtained data were expressed as mean ± SD and analyzed by ANOVA with the significance level defined as p < 0.05.

Results

Effect of Aam and Aah venoms on cytokine release

In the present study, the sera of mice envenomed by Aam displayed an increase of proinflammatory cytokines (IL-1β and IL-6). The comparison between Aam and Aah showed that the IL-1β level was more important in response to Aah venom (60 ± 12 pg/mL) versus (22.85 ± 2.15 pg/mL) (Figure 1 – A), while the maximum release of IL-6 was detected 60 minutes after Aam injection (237.66 ± 20.5 pg/mL), 180 minutes after administration of Aah venom (56 ± 2.89 pg/mL) followed by a significant elevation at 1440 minutes only in mice envenomed with Aam venom (Figure 1 – B).

In addition to the production of proinflammatory cytokines, the Aam and Aah venoms induced a significant release of an anti-inflammatory cytokine (IL-10). A biphasic profile was observed in response to Aam, the first peak measured at 60 minutes (162 ± 16.35 pg/mL), the second one at 360 minutes (104 ± 10.22 pg/mL), whereas only one peak was observed at 60 minutes (562.5 ± 59.3 pg/mL) in response to Aah venom (Figure 1 – C). Elevation of this cytokine was also reported in mice envenomed with *Centruroides noxius* venom [22].

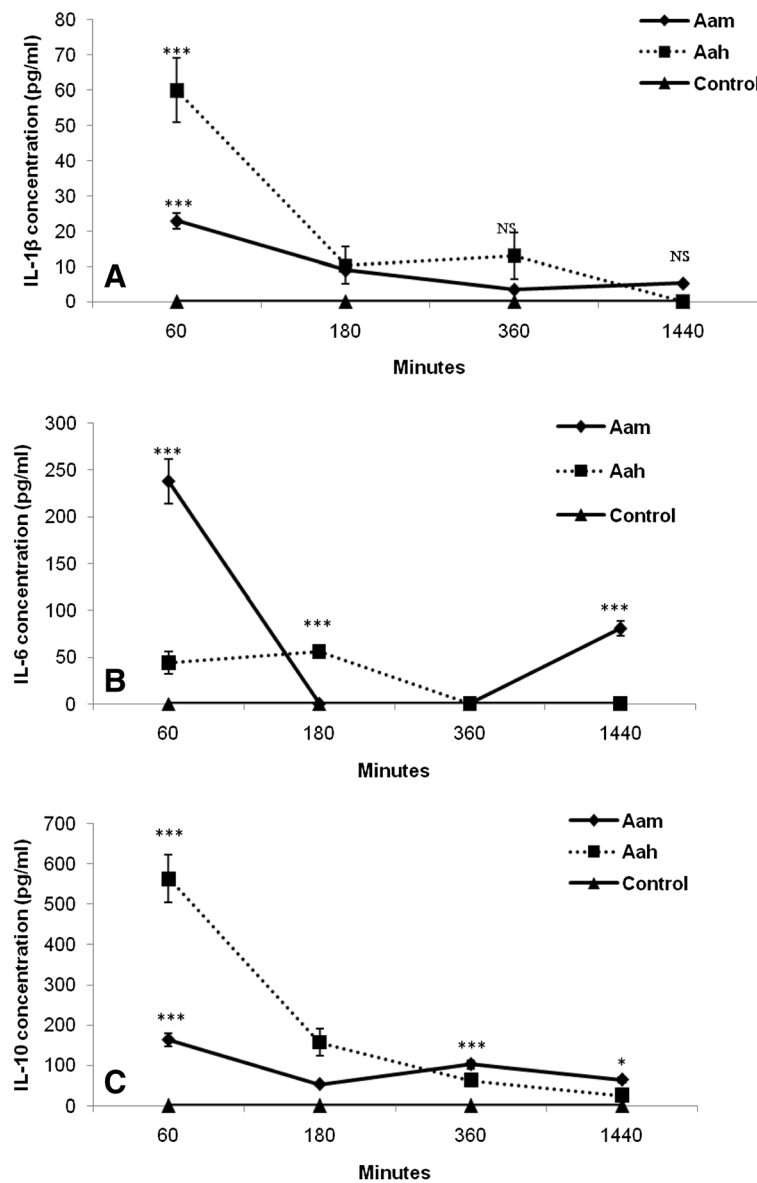


Figure 1 Kinetic of cytokines release in sera following Aam or Aah injection. (A) IL-1 β , (B) IL-6, (C) IL-10 * $p < 0.05$, ** $p < 0.01$, *** $p < 0.001$, NS: not significant, compared to control.

Myeloperoxidase activity

Rapid accumulation in lungs of neutrophils in response to any proinflammatory stimulus is one of the first recognizable events in the pathogenesis of many pulmonary diseases [23,24]. Neutrophil recruitment into lungs was evaluated by myeloperoxidase activity in this study, the two venoms induced neutrophil infiltration with more pronounced effect when Aam venom was injected (0.902 ± 0.071) versus (0.474 ± 0.033) (Figure 2).

The increase of pulmonary MPO activity was also observed in mice envenomed with Aah and *Tityus serrulatus* venoms [25,26].

Antagonists' effectiveness in reducing neutrophil influx depended on the venom injected; in comparison to propranolol, atropine significantly prevented neutrophil recruitment in the presence of Aam venom and showed the same effect in response to Aah venom (Figure 2).

Lung histology

Lung tissue micrographs from mice envenomed by Aam or Aah showed hemorrhage, thickening of the interalveolar septa with a high accumulation of inflammatory cells (Figure 3 – A1, A'1, B1, B'1). These effects are more pronounced in response to Aah venom which showed,

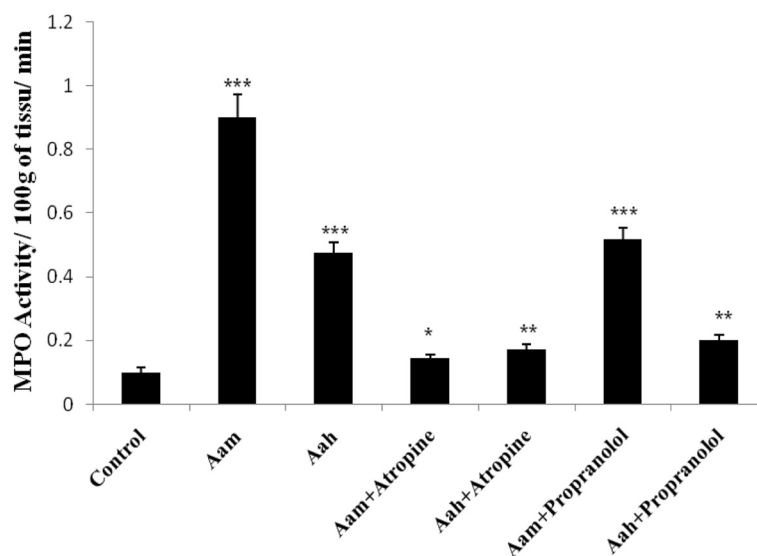


Figure 2 Effect of *Androctonus amoreuxi* and *Androctonus australis hector* venoms on myeloperoxidase activity in the presence or absence of atropine (At) and propranolol (Pr). * $p < 0.05$, ** $p < 0.01$, *** $p < 0.001$.

in addition to these anatomopathologic modifications, some edematous area (Figure 3 – B1).

Administration of atropine, a non-selective muscarinic antagonist or propranolol, a β adrenergic antagonist prior to the venom administration showed that atropine is more effective than propranolol at preventing inflammatory cell influx (Figure 3 – A2, B2, A3, B3). The lung edema observed in response to Aah venom was augmented in mice pretreated by the two antagonists (Figure 3 – B2, B'3).

Discussion

Several studies emphasized the relevance of proinflammatory cytokines in the pathophysiological manifestations of scorpion envenomation and showed their correlation with severity [27-30].

The results of the present study showed that Aam and Aah venoms induced the release of proinflammatory cytokines IL-1 β and IL-6. This finding is in agreement with previous studies that indicate an increase in circulating inflammatory cytokines after envenoming with several scorpion venoms such as *Tityus serrulatus*, *Tityus discipans*, *Centruroides noxius*, *Leiurus quinquestriatus quinquestriatus* and *Buthus occitanus* [7,22,27-29,31-33].

Cytokine levels differed significantly, with Aam venom inducing an earlier increase of IL-6 compared to Aah venom. This result can be explained by the high early level of anti-inflammatory cytokine (IL-10) in response to Aah venom. Indeed IL10 is known to play a modulatory role, down-regulating multiple aspects of immune and inflammatory responses through the regulation of

the proinflammatory cytokines (IL-1 β , IL-6 and TNF- α) [34,35].

The discrepancy in neutrophil influx observed in response to the Aam and Aah venoms may be attributable to their different levels of IL-6 release. This result is supported by previous data which showed that proinflammatory cytokines are responsible for leukocyte recruitment by inducing the elevation of chemokines and expression of adhesion molecules such as ICAM-1 and VLA-4 in endothelial cells [36]. The increase of chemokines might result in the binding of acetylcholine to muscarinic receptors [37,38].

Administration of atropine or propranolol prior to envenomation reduced neutrophilia in the lungs. This result suggests an inflammatory effect of both muscarinic and β adrenergic stimulation, as reflected in the ability of each antagonist to reduce neutrophil recruitment; which depends on the venom injected. Atropine was more effective than propranolol in preventing neutrophil influx following Aam injection. This observation is probably related to the amount of neurotransmitter released with a predominance of cholinergic stimulation in the presence of Aam venom.

This cholinergic predominance could explain in part the absence of an edematous area in lungs of mice envenomed by Aam venom, since the binding of Ach to muscarinic receptors decreases cardiac contraction, whereas excessive catecholamine release might give rise to left ventricular dysfunction that, in turn, may form lung edema [14,15,39-43]. Lung edema observed in pheochromocytoma patients or induced experimentally by catecholamine was prevented by pretreatment with α

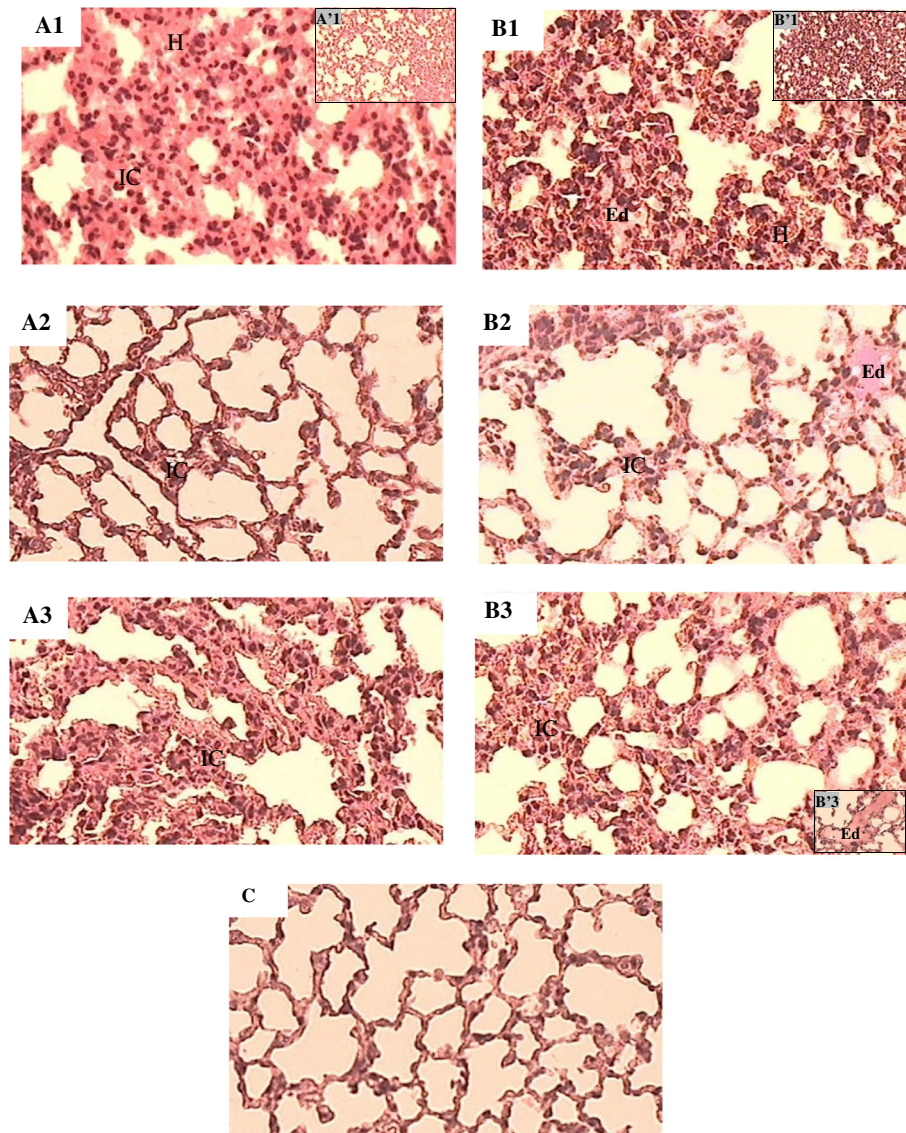


Figure 3 Effects of *Androctonus amoreuxi* and *Androctonus australis Hector* venoms on pulmonary parenchyma. (A1 and B1) Magnification of 400x, (A'1 and B'1) magnification of 100x, in the presence of atropine (A2, B2) or propranolol (A3, B3 and B'3), (C) control injected with saline. A: alveolus, E: edema, H: hemorrhage, IC: inflammatory cells, Hematoxylin-Eosin.

adrenergic blockers [16,44-47]. However our study showed that pulmonary edema subsequent to Aah venom was not reduced by propranolol or atropine. A similar effect was observed following propranolol administration in patients with pheochromocytoma [48]. Ismail [49] explained the effect of atropine by the accentuation of arterial hypertension.

The present comparison of lung micrographs between Aam and Aah also showed that an edematous area is observed only in response to Aah venom which induced a more important leukocyte infiltration in alveolar walls. These data are supported by previous studies which reported that edema formation in scorpion envenomation is attributable in part to activation of the inflammatory

cascade and the release of lipid-derived mediators of inflammation, including PAF, leukotrienes and prostaglandins secreted after activation of mast cells by neuropeptides such as substance P [6,12,13].

The influx of inflammatory cells into pulmonary parenchyma was reduced by atropine and propranolol. These results are similar to other studies which ascribed inflammatory effects to β adrenergic stimulation, thus indicating that most inflammatory cells express functional muscarinic receptors and showed that atropine administration inhibits the migration of leucocytes towards the site of inflammation, and blocked increase of leucocytes in splenic venous blood in response to carbacholine [50-56].

Conclusion

In conclusion, the comparative study of inflammatory response induced by Aam and Aah venoms showed not only the role of the neuroendocrine-immune axis in the development of lung inflammation with more important parasympathetic involvement in envenomed mice by Aam, but also that the role of atropine or propranolol in reducing inflammatory cells influx is independent of their effect on lung edema formation. The variability of venoms must be elucidated before an efficient treatment can be developed.

Competing interests

The authors declare no conflicts of interest.

Authors' contributions

All authors collaborated in this work; they read and approved the final manuscript.

Acknowledgements

Authors are highly thankful to ATSS (ex ANDRS) and PNR for financial assistance; acknowledge professor Ziani-Mameri Saadia (anatomopathologist in Beni Messous' hospital) and Bekkari Nadja for their contribution.

Received: 2 October 2012 Accepted: 20 November 2012

Published: 9 April 2013

References

- Patterson RA: Physiological action of scorpion venom. *AmJ Trop Med Hyg* 1960, **9**(4):410–414.
- Ismail M, Osman OH, Ibrahim SA, el-Asmar MF: Cardiovascular and respiratory responses to the venom from the scorpion *Leiurus quinquestriatus*. *East Afr Med J* 1972, **49**(4):275–281.
- Ismail M, Osman OH, el-Asmar MF: Pharmacological studies of the venom from the scorpion *Buthus minax* (L. Koch). *Toxicon* 1973, **11**(1):15–20.
- Ismail M, Osman OH, Gumaa KA, Karrar MA: Some pharmacological studies with scorpion (*Pandinus exitalis*) venom. *Toxicon* 1973, **12**(1):75–82.
- Freire-Maia L, de Matos IM: Heparin or a PAF antagonist (BN-52021) prevents the acute pulmonary oedema induced by *Tityus serrulatus* scorpion venom in the rat. *Toxicon* 1993, **31**(9):1207–1210.
- De-Matos IM, Talvani A, Freire-Maia L, Teixeira MM: Evidence for the role of mast cells in the lung edema induced by *Tityus serrulatus* venom in rats. *Toxicon* 2001, **39**(6):861–867.
- Fukuhara YD, Reis ML, Dellalibera-Joviliano R, Cunha FQ, Donadi EA: Increased plasma levels of IL-1beta, IL-6, IL-8, IL-10 and TNF-alpha in patients moderately or severely envenomed by *Tityus serrulatus* scorpion sting. *Toxicon* 2003, **41**(1):49–55.
- Adi-Bessalem S, Hammoudi-Triki D, Laraba-Djebari F: Pathophysiological effects of *Androctonus australis hector* scorpion venom: tissue damages and inflammatory response. *Exp Toxicol Pathol* 2008, **60**(4–5):373–380.
- Campos JA, Silva OA, Lopes M, Freire-Maia L: Signs symptoms and treatment of severe scorpion sting in children. *Toxicon* 1979, **17**(1):19.
- Goyffon M, Vachon M, Broglio N: Epidemiological and clinical characteristics of the scorpion envenomation in Tunisia. *Toxicon* 1982, **20**(1):337–344.
- Hering ES, Jurca M, Vichi FL, Azevedo-Marques MM, Cupo P: 'Reversible cardiomyopathy' in patients with severe scorpion envenoming by *Tityus serrulatus*: evolution of enzymatic, electrocardiographic and echocardiographic alterations. *Ann Trop Paediatr* 1993, **13**(2):173–182.
- de Matos IM, Rocha OA, Leite R, Freire-Maia L: Lung edema induced by *Tityus serrulatus* scorpion venom in the rat. *Comp Biochem Physiol* 1997, **118**(2):143–148.
- Matos IM, Souza DG, Seabra DG, Freire-Maia L, Teixeira MM: Effects of tachykinin NK1 or PAF receptor blockade on the lung injury induced by scorpion venom in rats. *Eur J Pharmacol* 1999, **376**(3):293–300.
- Gueron M, Margulis G, Sofer S: Echocardiographic and radionuclide angiographic observations following scorpion envenomation by *Leiurus quinquestriatus*. *Toxicon* 1990, **28**(9):1005–1009.
- de Mazzei Dávila CA, Dávila DF, Donis JH, de Bellabarba GA, Villareal V, Barboza JS: Sympathetic nervous system activation, antivenin administration and cardiovascular manifestation of scorpion envenomation. *Toxicon* 2002, **40**(9):1339–1346.
- Rassler B, Reibig C, Briest W, Tannapfel A, Zimmer HG: Catecholamine-induced pulmonary edema and pleural effusion in rats alpha- and beta- adrenergic effects. *Respir Physiol Neurobiol* 2003, **135**(1):25–37.
- Profita M, Giorgi RD, Sala A, Bonanno A, Riccobono L, Mirabella F, et al: Muscarinic receptors, leukotriene B4 production and neutrophilic inflammation in COPD patients. *Allergy* 2005, **60**(11):1361–1369.
- Udem BJ, Kollarik M: The role of vagal afferent nerves in chronic obstructive pulmonary disease. *Proc Am Thorac Soc* 2005, **2**(4):355–360.
- McQueen DS, Donaldson K, Bond SM, McNeilly JD, Newman S, Bartona NJ, et al: Bilateral vagotomy or atropine pre treatment reduces experimental diesel-soot induced lung inflammation. *Toxicol Appl Pharmacol* 2007, **219**(1):62–71.
- Rolanld H, Ingram JR: Syndrome de détresse respiratoire aigue de l'adulte. In *Harrison- Principes de médecine interne*. Edited by Wilson JD, Braunwald E, Isselbacher KJ, Petersdorf RG, Martin JB, Fauci AS, Root RK. Paris: Medicine Sciences Flammarion; 1992:1122–1125.
- Wagner JG, Roth RA: Neutrophil migration mechanisms, with an emphasis on the pulmonary vasculature. *Pharmacol Rev* 2000, **52**(3):349–374.
- Petricevich VL: Balance between pro- and anti-inflammatory cytokines in mice treated with *Centruroides noxius* scorpion venom. *Mediators Inflamm* 2006, **2006**(6):1–11.
- Worthen GS, Nick JA: In *Pulmonary diseases and disorders*. Edited by Fishman AP. New York: Mac Graw-Hill; 1998:325.
- Nick JA, Young SK, Brown KK, Avdi NJ, Arndt PG, Swatt BT, et al: Role of p38 mitogen activated protein kinase in murin model of pulmonary inflammation. *J Immunol* 2000, **164**(4):2151–2159.
- Coelho FM, Pessini AC, Coelho AM, Pinho VS, Souza DG, Arantes EC, et al: Platelet activating factor receptors drive CXC chemokine production, neutrophil influx and edema formation in the lungs of mice injected with *Tityus serrulatus* venom. *Toxicon* 2007, **50**(3):420–427.
- Adi-Bessalem S, Mendil A, Hammoudi-Triki D, Laraba-Djebari F: Lung immunoreactivity and airway inflammation: Their assessment after scorpion envenomation. *Inflammation* 2012, **35**(2):501–508.
- Meki AR, Mohey El-Dean ZM: Serum interleukin-1β, interleukin-6, nitric oxide and α1 antitrypsin in scorpion envenomed children. *Toxicon* 1998, **26**(12):1851–1859.
- Hammoudi-Triki D, Ferquel E, Robbe-Vincent A, Bon C, Choumet V, et al: Epidemiological data, clinical admission gradation and biological quantification by ELISA of scorpion envenomations in Algeria: effect of immuno-therapy. *Trans R Soc Trop Med Hyg* 2004, **98**(4):240–250.
- Abdel Haleem AA, Meki AR, Noaman HA, Mohamed ZT: Serum levels of IL6 and its soluble receptor, TNF-α and chemokine RANTES in scorpion envenomed children: their relation to scorpion envenomation outcome. *Toxicon* 2006, **47**(4):437–444.
- Sofer S, Gueron M, White RM, Lifshitz M, Apte RN: Interleukin-6 release following scorpion sting in children. *Toxicon* 1996, **34**(3):389–392.
- D'Suze G, Moncada S, González C, Sevcik C, Aguilar V, Alagón A: Relationship between plasmatic levels of various cytokines, tumor necrosis factor, enzymes, glucose and venom concentration following *Tityus* scorpion sting. *Toxicon* 2003, **41**(3):367–375.
- Andrade MV, Lisboa FA, Portugal AL, Arantes RM, Cunha-Melo JR: Scorpion venom increases mRNA expression of lung cytokines. *Comp Biochem Physiol A Mol Integr Physiol* 2007, **146**(4):581–587.
- Abdoon N, Fatani A: Correlation between blood pressure, cytokines and nitric oxide in conscious rabbits injected with *Leiurus quinquestriatus quinquestratus* scorpion venom. *Toxicon* 2009, **54**(4):471–480.
- Bogdan C, Vodovotz Y, Nathan C: Macrophage deactivation by IL-10. *J Exp Med* 1991, **174**(6):1549–1555.
- Fiorentino DF, Zlotnik A, Mosmann TR, Howard M, O'Garra A: IL-10 inhibits cytokine production by activated macrophages. *J Immunol* 1992, **147**(11):3815–3822.
- Voronov E, Apte RN, Sofer S: The systemic inflammatory response syndrome related to the release of cytokines following severe envenomation. *J Venom Anim Toxins* 1999, **5**(1):19–23.
- Koyama S, Rennard SI, Robbins RA: Acetylcholine stimulates bronchial epithelial cells to release neutrophil and monocyte chemotactic activity. *Am J Physiol* 1992, **262**(4 Pt 1):L466–L471.

38. Profita M, Bonanno A, Siena L, Ferraro M, Montalbano AM, Pompeo F, et al: **Acetylcholine mediates the release of IL-8 in human bronchial epithelial cells by a NFkB/ERK-dependent mechanism.** *Eur J Pharmacol* 2008, **582**(1-3):145-153.
39. Parthasarathy PR, Venkaiah B: **Histopathological study on the effect of venom from the scorpion *Heterometrus fulvipes*.** *Ind J Path Microbiol* 1986, **29**(2):155-158.
40. Gueron M, Ovsyscher I: **What is the treatment for the cardiovascular manifestations of scorpion envenomation?** *Toxicon* 1987, **25**:121-124.
41. Gueron M, Ilia R, Sofer S: **The cardiovascular system after scorpion envenomation a review.** *Clin Toxicol* 1992, **30**(2):245-258.
42. Bucarechi F, Baracat EC, Nogueira RJ, Chaves A, Zambrone FA, Fonseca MR, et al: **Comparative study of severe scorpion envenomation in children caused by *Tityus bahiensis* and *Tityus serrulatus*.** *Rev Inst Med Trop Sao Paulo* 1995, **37**(4):331-336.
43. Gueron M, Ilia R: **Non- cardiogenic pulmonary oedema after scorpion envenomation: a true antity?** *Toxicon* 1996, **34**(4):393-395.
44. Ferrari W, Baggio G, Guarini S: **Studies on epinephrine-induced lung edema in the rat. I. Selective α 1-adrenoceptor involvement.** *Arch Int Pharmacodyn Ther* 1986, **281**(1):89-99.
45. Tauzin-Fin P, Hilbert G, Krol-Houdek M, Gosse P, Maurette P: **Mydriasis and acute pulmonary oedema complicating laparoscopic removal of pheochromocytoma.** *Anaesth Intensive Care* 1999, **27**(6):646-649.
46. Van Iperen CE, Giezen J, Kramer WL, Lips CJ, Bartelink AK: **Acute dyspnoea resulting from pulmonary oedema as the first sign of a pheochromocytoma.** *Respiration* 2001, **68**(3):323-326.
47. Rassler B, Barth W, Zimmer HG: **Transient pleural effusion in norepinephrine-stimulated rats.** *Basic Res Cardiol* 2001, **96**(5):265-273.
48. Sloan EM, Thompson BT: **Propranolol-induced pulmonary edema and shock in a patient with pheochromocytoma.** *Arch Intern Med* 1984, **144**(1):173-174.
49. Ismail M: **The scorpion envenoming syndrome.** *Toxicon* 1995, **33**(7):825-858.
50. Sandberg G: **Leucocyte mobilization from the guinea pig spleen by muscarinic cholinergic stimulation.** *Experientia* 1994, **50**(1):40-43.
51. Chi DS, Qui M, Krishnaswamy G, Li C, Stone W: **Regulation of nitric oxide production from macrophages by lipopolysaccharide and catecholamines.** *Nitric Oxide* 2003, **8**(2):127-132.
52. Gosens R, Zaagsma J, Grootte Bromhaar M, Nelemans A, Meurs H: **Acetylcholine: a novel regulator of airway smooth muscle remodelling?** *Eur J Pharmacol* 2004, **500**(1-3):193-201.
53. Gwilt CR, Donnelly LE, Rogers DF: **The non-neuronal cholinergic system in the airways: an unappreciated regulatory role in pulmonary inflammation?** *Pharmacol Ther* 2007, **115**(2):208-222.
54. Tan KS, Nacklely AG, Satterfield K, Maixner W, Diatchenko L, Flood PM: **Beta2 adrenergic receptor activation stimulates pro-inflammatory cytokine production in macrophage via PKA- and NF kappaB - independent mechanisms.** *Cell Signal* 2007, **19**(2):251-260.
55. Razani-Boroujerdi S, Behl M, Hahn FF, Pena-Phillipides JC, Sopor ML: **Role of muscarinic receptors in the regulation of immune and inflammatory responses.** *J Neuroimmunol* 2008, **194**(1-2):83-88.
56. Wessler I, Kirkpatrick CJ: **Acetylcholine beyond neurons: the non-neuronal cholinergic system in humans.** *Br J Pharmacol* 2008, **154**(8):1558-1571.

doi:10.1186/1678-9199-19-8

Cite this article as: Saidi et al.: Effects of atropine and propranolol on lung inflammation in experimental envenomation: comparison of two buthidae venoms. *Journal of Venomous Animals and Toxins including Tropical Diseases* 2013 **19**:8.

Submit your next manuscript to BioMed Central and take full advantage of:

- Convenient online submission
- Thorough peer review
- No space constraints or color figure charges
- Immediate publication on acceptance
- Inclusion in PubMed, CAS, Scopus and Google Scholar
- Research which is freely available for redistribution

Submit your manuscript at
www.biomedcentral.com/submit

