

## PROSTATIC CRYPTOCOCCOSIS - A CASE REPORT

**CHANG M. R. (1), PANIAGO A. M. M. (2), SILVA M. M. (3), LAZÉRA M. S. (4),  
WANKE B. (4)**

(1) Department of Pharmacy-Biochemistry, Federal University of Mato Grosso do Sul (UFMS), Campo Grande, Mato Grosso do Sul State, Brazil; (2) Department of Internal Medicine, UFMS, Campo Grande, Mato Grosso do Sul State, Brazil; (3) Medicine Program, University for Development of the State and the Pantanal Region (UNIDERP), Campo Grande, Mato Grosso do Sul State, Brazil; (4) Mycology Service Evandro Chagas Institute of Clinical Research (IPEC), Oswaldo Cruz Foundation (FIOCRUZ), Rio de Janeiro, Rio de Janeiro State, Brazil.

**ABSTRACT:** Cryptococcosis is a systemic mycosis usually affecting immunodeficient individuals. In contrast, immunologically competent patients are rarely affected. Dissemination of cryptococcosis usually involves the central nervous system, manifesting as meningitis or meningoencephalitis. Prostatic lesions are not commonly found. A case of prostate cryptococcal infection is presented and cases of prostatic cryptococcosis in normal and immunocompromised hosts are reviewed. A fifty-year-old HIV-negative man with urinary retention and renal insufficiency underwent prostatectomy due to massive enlargement of the organ. Prostate histopathologic examination revealed encapsulated yeast-like structures. After 30 days, the patient's clinical manifestations worsened, with headache, neck stiffness, bradypsychia, vomiting and fever. Direct microscopy of the patient's urine with China ink preparations showed capsulated yeasts, and positive culture yielded *Cryptococcus neoformans*. This fungus was later isolated from cerebrospinal fluid and blood cultures, demonstrating thus its dissemination. The patient was discharged after 27 days in hospital and, despite a regimen of amphotericin B, he died four months later. This case points to cryptococcosis as a possible cause of prostatic disease and reinforces the importance of communication between the medical team and pathology and microbiology laboratories aiming at a more accurate diagnosis and successful treatment.

**KEY WORDS:** Cryptococcosis, *Cryptococcus*, immunocompetent patient, cryptococcal prostatitis

**CONFLICTS OF INTEREST:** There is no conflict.

**CORRESPONDENCE TO:**

MARILENE R. CHANG: Rua Uricuri, 582, Vila Olinda, 79060-040, Campo Grande-MS, Brasil. Phone: 67 3345 3195. Email: [marirchang@yahoo.com.br](mailto:marirchang@yahoo.com.br).

## INTRODUCTION

Cryptococcosis is an important cause of life-threatening meningoencephalitis in immunocompromised patients, especially those with HIV infection, as well as apparently immunocompetent individuals. The infection is caused by two species of encapsulated yeasts of the *Cryptococcus neoformans* complex, *C. neoformans* (serotypes A, D, and AD) and *C. gattii* (serotypes B and C). Both species differ in genotype, phenotype, epidemiology, as well as in their geographic distribution and natural habitat (7). While *C. neoformans* usually infects immunocompromised patients (1, 3, 8), *C. gattii* prevails as a primary endemic mycosis in apparently immunocompetent individuals (9, 10) living in tropical and subtropical regions. In Brazil, opportunistic cryptococcosis by *C. neoformans* predominates in the South, Southeast and Central-Western regions. However, in the North and Northeastern regions, the primary infection by *C. gattii* in otherwise healthy individuals predominates (4).

The infection is usually acquired through inhalation of airborne propagules, generally without or with mild respiratory manifestations and from this site the fungus may disseminate to other organs, mainly the central nervous system (CNS).

Although the prostate is often affected by *C. neoformans* in immunodepressed hosts, the anatomic-pathologic picture in this organ has been scarcely described (Table 1), suggesting that its incidence is underestimated (3, 15). In the present case, the differential diagnosis included nodular prostatic hyperplasia, abscess, cancer, tuberculosis and syphilis.

## CASE REPORT

A 54-year-old man from Campo Grande, the capital of the state of Mato Grosso do Sul, with no significant morbid antecedents, was admitted to the University Hospital of the Federal University of Mato Grosso do Sul (UFMS) on March 7<sup>th</sup>, 2001, presenting severe urinary retention. Laboratory tests confirmed renal insufficiency (serum creatinine = 7.0mg/dl), characterized as post-renal. Ultra-sound scan showed enlargement in the prostatic volume (4.1 X 4.8 X 5.2cm) with an estimated weigh of 53g (normal=20g). Subjected to trans-vesical prostatectomy, he recovered uneventfully and was discharged on March 17<sup>th</sup>. The histopathologic exam of the prostate revealed multi-cystic surface, with an extensive inflammatory process, predominantly exudative, and large areas of necrosis, in which several yeast

structures were found, some of which showing single budding and presenting bright halo suggestive of capsule (Figure 1).

Less than 3 weeks later, on April 5<sup>th</sup>, he was admitted again complaining of migraine, vomiting and fever, symptoms that quickly worsened accompanied by a drop in the conscience level, suggesting cryptococcal meningoencephalitis in addition to his prostate cryptococcosis. Urine, cerebrospinal fluid (CSF) and blood samples were collected for mycological exams. Direct microscopy with India ink of urine and CSF detected capsulated yeast cells (2). Cultivation of all samples (urine, CSF and blood) on Sabouraud dextrose agar (SDA) with and without antibiotics (chloramphenicol and gentamicin), at 30°C and 37°C, showed growth of *C. neoformans*, evidencing the spread of the disease. The identification of cultures was based on biochemical proofs, the species was determined by canavanine-glycine-bromothymol blue – CGB test (6) and the serotype was determined by the slide agglutination test (Crypto Check latron RM-304K kit; latron Laboratories, Tokio, Japan), characterizing them as *C. neoformans* serotype A.

The leukocyte count of CSF was 138 cells/mm<sup>3</sup> with predominance of lymphocytes (73.0%) and showed hypoglycorrachia (13.0mg/dl). Anti-HIV antibody assays (Microparticle Enzyme Immunoassay - AxSYM instrument - Abbott Laboratories, and Dot Immuno Assay) were negative. Chest radiograph and brain computerized tomographic scanning did not present abnormalities. Antifungal treatment was instituted with amphotericin B, with initial dosis of 0.7mg/kg/day. The patient presented clinical improvement and subsequent cultures of urine and CSF were negative. On August 5<sup>th</sup>, still under treatment with a total dosis of 1.8g amphotericin B, he presented again neurological manifestations with papilla-edema and paraparesis of the lower limbs. CSF leukocyte count increased to 667 cells/mm<sup>3</sup> with predominance of polymorphonuclear cells (91%); brain computerized tomographic scanning (CTS) revealed the presence of discretely enhanced nodules. Latex agglutination to *Haemophilus influenzae* B, *Neisseria meningitidis* A, B and C, *Escherichia coli* K1, and *Streptococcus pneumoniae*, as well as CSF direct microscopy with India ink, bacterioscopy and culture were all negative. However, culture for fungi demonstrated growth of *C. neoformans*. The patient did not respond to the treatment with ceftriaxone and amphotericin B and died on August 13<sup>th</sup>, 2001.

Table 1. Reports of cryptococcosis cases with prostatic involvement. Revision from 1996 to 2006.

Reference	Age (years)	Presentation	Other organs	Diagnosis methods	Concomitant diseases	Evolution
Rubião <i>et al.</i> , (13)	54	Prostatism	Lung	Histopathology, prostate biopsy	None	Discharge
Hinchey & Someren, (5)	63	Prostatism	None	Prostate biopsy, urine culture	Diabetes mellitus, tuberculosis	Discharge
Lief & Sarfarazi, (8)	36	Prostatism	CNS	Direct exam, CSF culture, histopathology, prostate biopsy	AIDS	Discharge
Milchgrub <i>et al.</i> , (11)	59	Prostatism	None	Histopathology, prostate biopsy	None	Discharge
Adams <i>et al.</i> , (1)	55	Prostatism	None	Histopathology, prostate biopsy, urine culture	AIDS	Discharge
Lima <i>et al.</i> , (9)	32	Prostatism	None	Histopathology, necropsy	AIDS, tuberculosis	Death
Yip <i>et al.</i> , (17)	71	Prostatism	CNS	Blood culture, CSF culture, prostate biopsy	Myasthenia Gravis, diabetes	Death
Caballes & Caballes, (3)	64	Prostatism	CNS	Histopathology, prostate biopsy	Diabetes	Discharge
Sharma <i>et al.</i> , 2000 (15)	52	Prostatism	CNS	Histopathology, aspirate of prostatic nodule	Chronic lymphocytic leukemia, tuberculosis	Discharge
Siddiqui <i>et al.</i> , 2005 (16)	51	Prostatism	None	Blood culture, prostate biopsy, urine	Diabetes, hypothyroidism	Discharge
Seo <i>et al.</i> , 2006 (14)	75	Prostatism	None	Histopathology, prostate biopsy	Alcoholic cirrhosis	Discharge

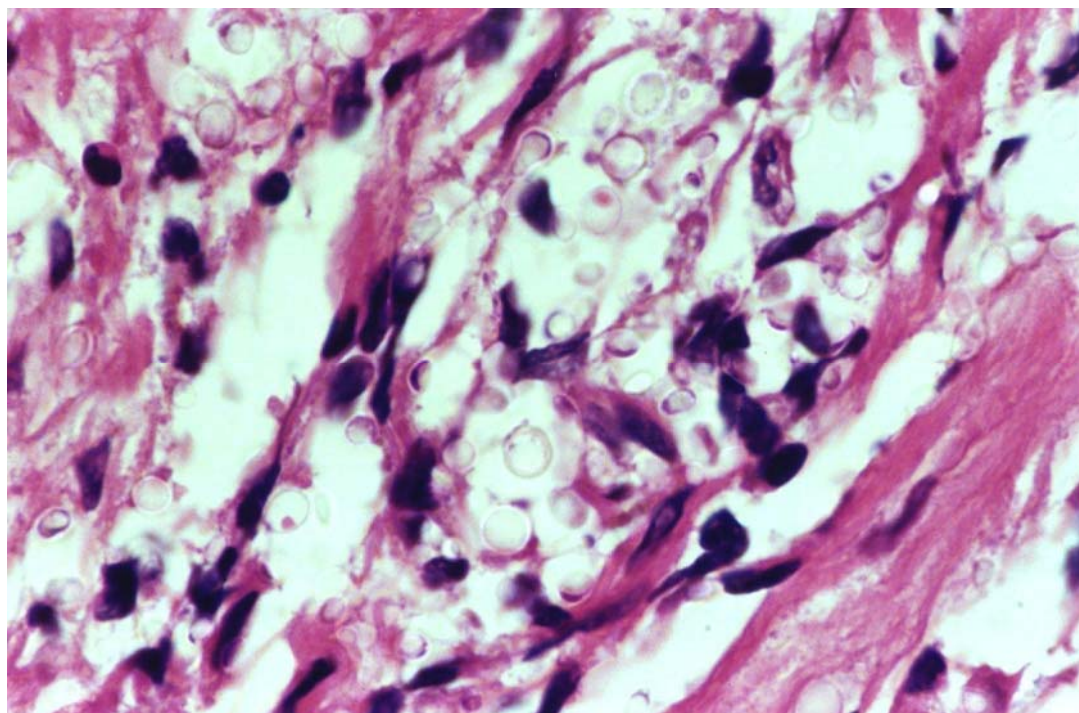


Figure 1. Histological section of prostate, presenting a great number of yeast-like structures, with no inflammatory reaction (HE 1000X)

## DISCUSSION

The clinical presentation of cryptococcosis varies according to the body site and the host immunological status. In most cases it is diagnosed due to a meningoencephalitis, followed by pulmonary and less frequently by other forms like skin, bones and joints. In fact, *C. neoformans* can infect any organ of the human body (6).

Cryptococcosis is worldwide an important life-threatening systemic mycosis in HIV-infected patients, in whom the prostate has been considered an important focus of maintenance of mycosis (1, 8, 9). On the other hand, it is considered unusual in individuals with no predisposing risk factor (10), and the prostate is not a usual site of cryptococcal infection (11,14,16). Prostatic involvement has been described in transplant recipients subjected to long-lasting immunosuppressive drug schedules (15, 17). Caballes and Caballes evaluated the cell immunity in such a case demonstrating a suggestive deficit in CD4 cells (3).

We emphasize the importance of carrying out a complete mycological examination of biopsy material or prostatic aspirate (11, 14) in order to isolate and correctly identify the agent. Histopathologic test may detect fungal structures only suggestive of *C.*

*neoformans*, as these yeast-like structures often are capsule-deficient and morphologically deteriorated. Thus, depending on the utilized staining technique, they may be mistaken as agents of systemic mycoses as *Paracoccidioides brasiliensis* and *Histoplasma capsulatum*, which are also endemic in Brazil (11).

In many occasions, more often than not, the fungus is detected only incidentally, in necropsies or examination of surgical tissues (8, 9). The occurrence of prostatic cryptococcosis, therefore, may be underestimated, especially in apparently immunocompetent individuals. The confirmation of the diagnosis, as in the present case, was obtained through the observation of capsulated yeast-like structures in the urine under direct microscopy with India ink preparations (2) and isolation of the fungus on Sabouraud dextrose agar medium (6). As urine is an easily collectable specimen, it has been shown remarkable positivity in the cases of disseminated cryptococcosis (12).

The identification of the culture isolated in the present case proved to be *C. neoformans* serotype A, the most frequently found (6). It is likely that, in this case, the prostatic lesion was concomitant to the dissemination of the fungus and that the initially oligosymptomatic meningoencephalitis was clinically overlooked. Another possibility to be considered is that the prostatic lesion subjected to surgical management may have caused systemic dissemination of the fungus, similarly to the interpretation of other authors in the few reports described (3, 15).

In conclusion, we propose that cryptococcosis should be considered a differential diagnosis of prostatic diseases, in order to reach earlier diagnosis and treatment and better prognoses.

## REFERENCES

- 1 ADAMS JR., MATA JA., CULKIN DJ. Acquired immunodeficiency syndrome manifesting as prostate nodule secondary to cryptococcal infection. *Urology*, 1992, 39, 289-91.
- 2 BENHAM RW. Cryptococci, their identification by morphology and serology. *J. Infec. Dis.*, 1935, 57, 255-74.
- 3 CABALLES RL., CABALLES JR RA. Primary cryptococcal prostatitis in an apparently uncompromised host. *Prostate*, 1999, 39, 119-22.
- 4 CORREA MPSC., OLIVEIRA EC., DUARTE RRBS., PARDAL PPO., OLIVEIRA FM., SEVERO LC. Cryptococcosis in children in the state of Pará, Brasil. *Rev. Soc. Bras. Med. Trop.*, 1999, 32, 505-8.
- 5 HINCHEY WW., SOMEREN A. Cryptococcal prostatitis. *Am. J. Clin. Pathol.*, 1981, 75, 257-60.
- 6 KWON-CHUNG KJ., BENNETT JE. Cryptococcosis. In: KWON-CHUNG KJ., BENNETT JE. Eds. *Medical mycology*. Philadelphia: Lea & Febiger, 1992: 397-446.
- 7 KWON-CHUNG KJ., VARMA A. Do major species concepts support one, two or more species within *Cryptococcus neoformans*? *FEMS Yeast Res.*, 2006, 6, 574–87.
- 8 LIEF M., SARFARAZI F. Prostatic cryptococcosis in acquired immune deficiency syndrome. *Urology*, 1986, 28, 318-9.
- 9 LIMA MA., SANTOS JAM., LAZO J., SILVA-VERGARA ML., SANTOS LAM., SANTOS VM. Infecção por *Cryptococcus* limitada à próstata em paciente aids com micobacteriose disseminada. Relato de necrópsia. *Rev. Soc. Bras. Med. Trop.*, 1997, 30, 501-5.
- 10 LOPES JO., COSTA JM., STREHER LA., CLOCK C., PINTO MS., ALVES SH. Criptococose não associada à AIDS no Rio Grande do Sul: relato de oito casos e revisão da literatura sul-riograndense. *Rev. Soc. Bras. Med. Trop.*, 1997, 30, 369-72.
- 11 MILCHGRUB S., VISCONTI E., AVELLINI J. Granulomatous prostatitis induced by capsule-deficient cryptococcal infection. *J. Urol.*, 1990, 143, 365-6.
- 12 PINTO JÚNIOR VL., GALHARDO MCG., LAZERA M., WANKE B., REIS RS., PEREZ M. Criptococose associada à AIDS. A importância do cultivo da urina no seu diagnóstico. *Rev. Soc. Bras. Med. Trop.*, 2006, 39, 230-2.
- 13 RUBIÃO PE., GONTIJO J., MAGALHÃES MM. Prostatite micótica (criptococócica) simulando câncer de próstata. Relato de um caso. *O Hospital*, 1966, 70, 1327-36.

14 SEO IY., JEONG HJ., YUN KJ., RIM JS. Granulomatous cryptococcal prostatitis diagnosed by transrectal biopsy. *Int. J. Urol.*, 2006, 13, 638-9.

15 SHARMA N., VARMA S., VARMA N., KUMARI S., CHAKRABORTY A. Cryptococcal prostatitis in a patient with chronic lymphocytic leukemia. *J. Assoc. Physicians India*, 2000, 48,1015-6.

16 SIDDIQUI TJ., ZAMANI T., PARADA JP. Primary cryptococcal prostatitis and correlation with serum prostate specific antigen in a renal transplant recipient. *J. Infect.*, 2005, 51,153-7.

17 YIP SK., CHENG C., WONG MY., TAN BH., SIM CS., LIM SH. Cryptococcal prostatic abscess in an immunocompromised patient: a case report and review of the literature. *Ann. Acad. Med. Singapore*, 1998, 7, 873-6.