

SCHISTOSOMA MANSONI: STRUCTURAL DAMAGE AFTER TREATMENT WITH OXAMNIQUINE

AGEU MAGALHÃES FILHO*, MARIA ELIANE BEZERRA DE MELO*, PAULO ANTÔNIO PADOVAN** & ISAIRAS PEREIRA PADOVAN**

* Centro de Pesquisas Aggeu Magalhães – FIOCRUZ, Caixa Postal 7472, Recife, PE, Brasil ** Laboratório de Imunopatologia Keizo Asami (LIKA) – UFPE – Campus da UFPE, 50739 Recife, PE, Brasil

The effects of a single dose (100 mg/kg-body weight of mouse) of oxamniquine on the worm's tegument and paranchyma in relation to the process of immunological granulomatous reaction of the host's liver are described under light and electron microscopy (EM). The lesions caused by the drug are sequentially and simultaneously described in form of swelling, surface bulble and disruption with erosions. Ulceration in the tubercles with loss of spines is often more extensive and severe in male worms and concentration of host's mononuclear cells is observed. The possible role of host's immune response is discussed.

The morphological alteration induced by oxamniquine in *Schistosoma mansoni* recovered from experimentally infected mice, were reported by Khon et al. (1979). Later (1982) the same authors described significant structural alterations in worms removed from mice 1 to 10 days after treatment with the drug by removed from mice 1 to 10 days after treatment with the drug by scanning and transmission microscopy. Other investigators also reported corresponding worms damage using schistosomicidal compounds amoscanate (Voge, 1980) and praziquantel (Shaw & Erasmus, 1983; 1987).

The changes in the tegument and sub-tegumental tissues of adults worms, has led the opinion that *in vivo* damage to the tegumental surface results in the schistosome losing its immunological "disguise". However, these experiments with worms perfused from mesenterics vessels suggested that parts of the continued tegumental damage may be due to the effects of host immune factors. The aim of the present investigation is to study the histological and ultrastructural damage produced by the drug (oxamniquine) on the worms and the role of the host's immune response to the mechanism of the parasites absorption in the liver.

MATERIALS AND METHODS

80 male mice, from our laboratory (Swiss Webster-out bred) colony, were infected by tail immersion with 120 cercarias, obtained from *Biomphalaria glabrata* snails, infected with a

local strain of *Schistosoma mansoni*. Nine weeks later, the mice were submitted to a single (100 mg/kg weight) with one dose of oxamniquine, by gastric intubation. The mice were then sacrificed at intervals of 24-48-72-96h and 5-10-15 and 30 days, after treatment. The worms were recovered from the liver vessels (24 to 96 h) and fixed in glutaraldehyde and osmium tetroxide, imbedding in epoxy and examined by JEOL-100cx-II at 80 kv. Others were dissected, mounted in aluminium stribs, sputered with gold and examined by JEOL scanning (T-200 at 15 kv).

Liver sections were taken, at 24 to 30 days intervals, formaline fixed and processed for routine paraffine, and stained by HE and PAS technique, for the light microscope examination. Worms removed from control untreated mice, as well as tissue sections from liver, were examined as the same above described methods.

RESULTS

Light microscopy

The structure of the untreated control worms's tegument and parenchymal tissue, remained normal. A single oral dose of oxamniquine in treated worms produced a variety of structural changes of the tegument and sub-tegumental tissues, in male and female, with some differences between the worms or individually.

At 24 h, post treatment, the light microscopic changes were located most in the tegument, as a hyaline swelling of the membrane with some vacuolation formed in the tegumental surface. At this stage the correspondent portal spaces were infiltrated with host's cells.

At 48 h, besides those lesions, parts of the outer tegument were completely absent, and host's cells attached to the worms surface. The PAS, method stained the remanents segments of the tegument. Small vesicles were formed in sub-tegumental tissue, they were of different sizes and a diffuse enlargement of intercellular spaces of the structure was invariably present in all worms, giving to the parenchymal tissue a swelling vacuolation, like hydropic degeneration.

At this stage, the adherent host's cells increased in number and the worms's surface become all involved by multiple layers of mononuclear's cells, and eosinophilics granulocytes were also present. From this stage on (72-96 h) a granulomatous formation took place and the progressive hydropic infiltration of worms was more intensive, with parenchymal cells presenting nuclear pycnosis and/or fragmentation. Some parasites were identified because they were all infiltrated by the host's fagocytting cells.

From 10 to 15 days, most worms had desintegrated and were reduced to small membranous amorphous fragments in the center of granulomatous trombosed vessels. The vessel's walls were not visible, therefore as the process progressed, the amorphous fragments were absorbed and the endothelial line could be distinguished. At the last period of time (30 days) worms material was no more inside the granuloma and the vessel's walls presented an interesting aspect, epithelioid cells arranged like a ring figure disposed along the endothelial layer. No fibrous tissue was formed nor collagen fibers were seen at the local tissue post granuloma.

Scanning and transmission eletron microscopy

Worms were recovered at intervals of 24-48-72 and 96 h, post-treatment by dissecting portal vessels from treated and control mice. The ultrastructure of control worms, remained normal as described by Morris & Thereadgold (1968). 24 h post treatment the drug induced tegumental changes ranged from vacuolation,

swelling, wrinkling between the tubercules and in the sukera.

At 48 h post-treatment, parts of the dorsal surface between the spined tubercules showed extensive swelling, while erosions of the surface layer and loss of the spines tubercles was less extensive. In others worms, or even in differents regions of the more severely damaged worms, varying degrees of shrinkage and constriction of the tegument were also found. Vacuolation of the basal membrane was common in some worms and disrupted tegumental surface gave an ulcerative aspect in the tubercule's surface. In those disrupted areas of the tegument surface host's cells had become attached and started to invade the worms.

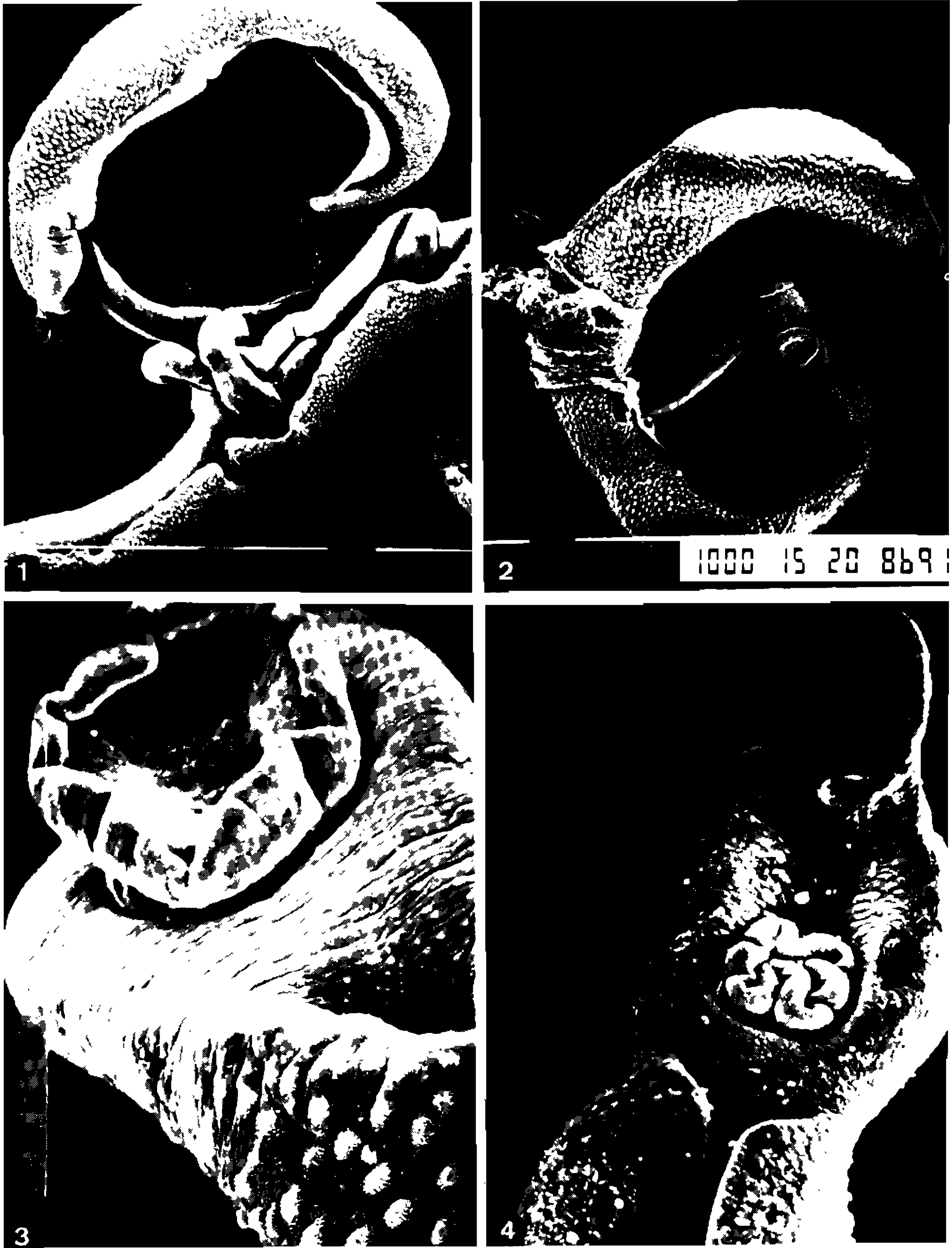At 72-96 h, recovered worms showed increased amount and more extensive surface damage, the worms had lost completely their outer tegument and became trapped in the portal vein and invaded by host's cells.

DISCUSSION

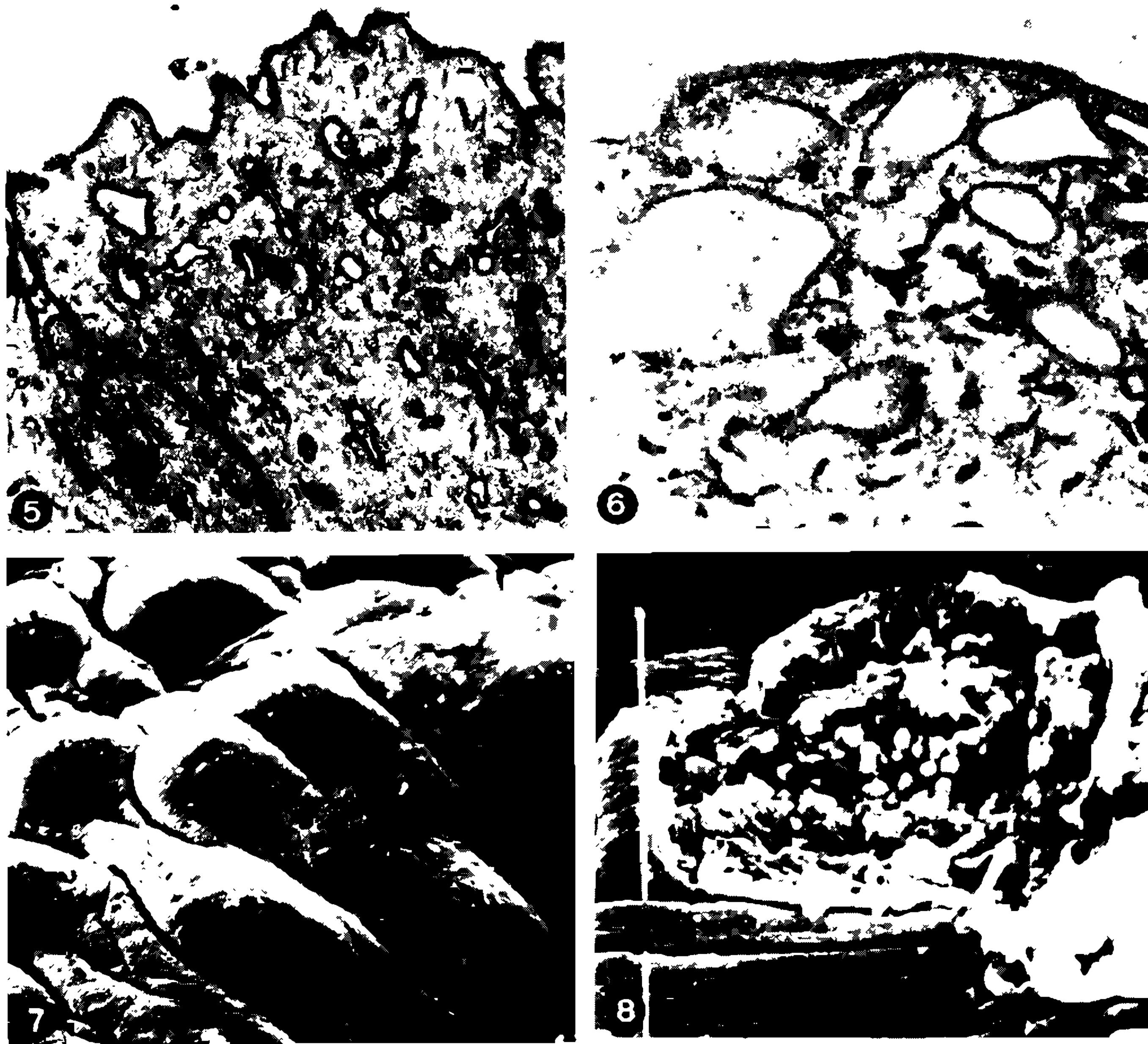
The present study confirms previous studies, (Khon et al. 1979; 1982) with oxamniquine, (Shaw & Erasmus 1983; 1987) with praziquantel and (Voge & Bueding, 1980) using schistosomicidal amoscate.

The sequential damage recognizable by EM as a result with different drugs, are primarily tegumental swelling, constriction, blebbing and collapse of sensory bulbes, disruption of tubercles with loss of spine and ulceration.

Comparing these findings to the present study in *Schistosomas* that had been dislocated from mesenteric veins to the liver they showed tegumental changes followed by host's mononuclear cells, entered the vacuolised surface during the first 5 days. Tegumental damage is apparently very rapid after a single dose of oxamniquine. The tegumental damage causes loss of host's antigens incorporated, as a mean of "disguising". Its presence according to many authors, (Smither et al., 1969) after transference of adult worms to another sensitized animal (Sogandaris-Bernall, 1976; Magalhães Filho et al., 1984; Yong et al., 1983) using schistosomicidal drugs, has been reported. The drug also inducing such alterations as swelling and hydropic degeneration suggest the possibility of a disruption of the osmotic balance in inpaired transport.



Scanning electron micrographs — Fig. 1: normal worms — (46x). Fig. 2: general view of worms showing accumulation of membranous material around the surface with host cells — (46x). Fig. 3: ventral sucker with pronounced swelling of surface, 72 h after treatment — (360x). Fig. 4: ventral face of male worm with profound alterations on the entire surface and swelling of ventral sucker, 96 h after treatment — (250x).



Transmission and scanning electron micrographs – Fig. 5: part of the tegument of a female worm showing normal pattern – (30.000x). Fig. 6: tegument of 48 h treated worm showing dilated channels, with vacuolation and diffuse edema – (60.000x). Fig. 7: dorsal surface of male worm showing lost of spine bosses. Arrow indicating ulceration, 72 h p/treatment – (1.100x). Fig. 8: ulceration of surface with host cells attached and invading the parasite, 96 h p/treatment – (3.400x).

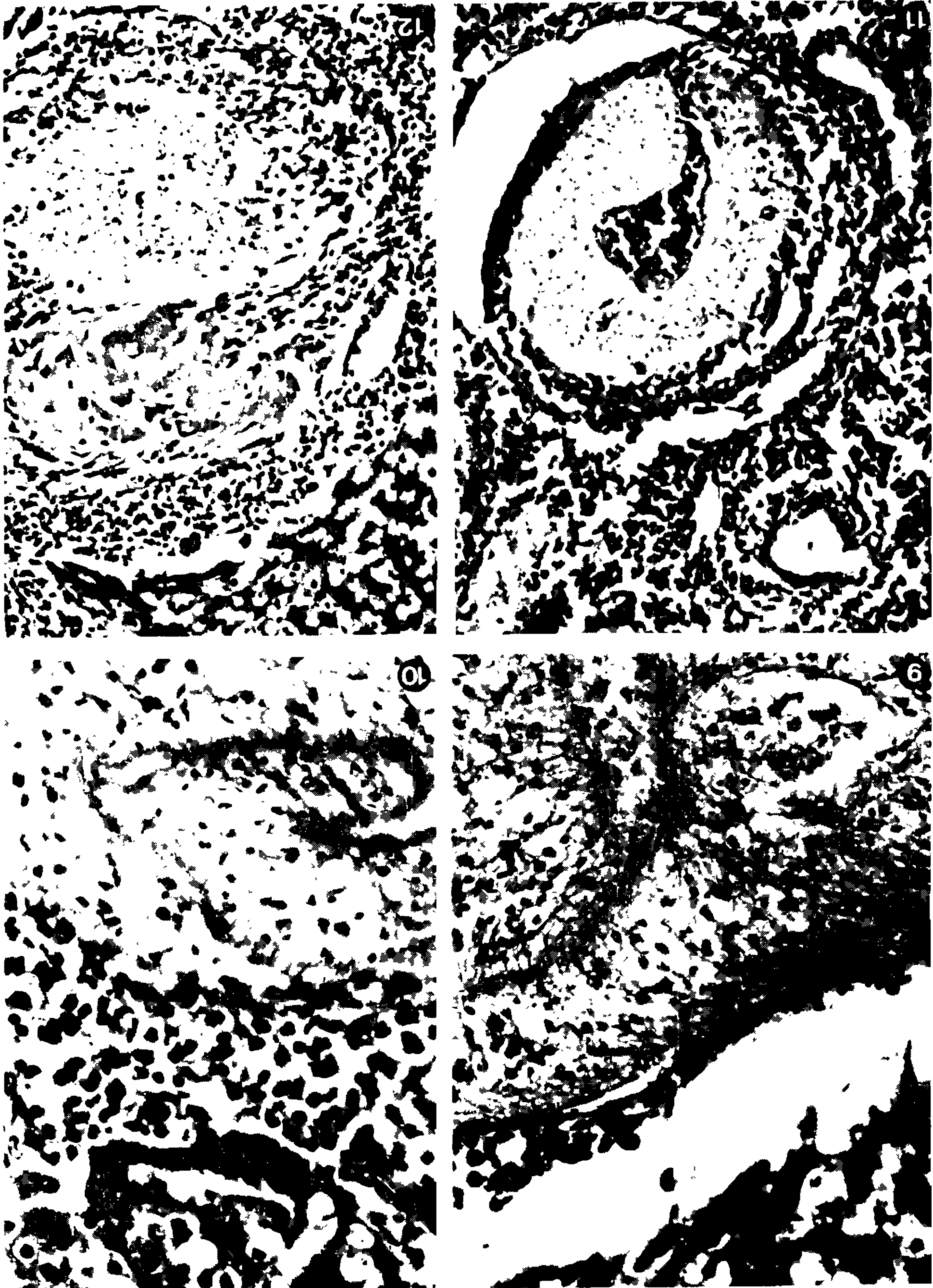
According to our findings host's response apparently initiates early, just following the tegumental damage. The granulomatous response around the degeneration worms is a cell mediated reaction, by mononuclears and granulocytic cells.

Shaw & Erasmus (1987) reported a process of tegumental repair in worms long term *in vivo* after praziquantel treatment. This finding confirms the degenerative drug-induced process, leading to the secondary immunological

response, the death and phagocytic absorption of worms.

One can speculate that the subsequent worm desintegration recognizable by nuclear cells pycnosis or cariorexis, will depend on the ability of phagocytic cells of the reactive granulomatous response.

Further studies on the mechanisms of these drug-induced surface alteration and its dynamics are being continued in this laboratory.



Light microscope aspects of liver stained by Hematoxylin-Eosine – Fig. 9: host cells starting adherence to the worm's tegument showing parenchymal hydropic infiltration, 48 h p/treatment – (1.200x). Fig. 10: worms showing advanced hydropic degeneration showing nuclear damage and host cell phagocytes 96 h p/treatment – (1.200x). Figs. 11 and 12: different aspects and stages of granulomas with host cells in process of parasites absorption, showing preservation of endothelial cells – (300x).

CONCLUSIONS

- a) Our findings comparing to other authors, in the post-treatment literature, indicates that *Schistosoma's* drug-induced lesions have to be considered as a hydrotic degeneration, also named as vacuolar degeneration.
- b) The pathology indicates it as a metabolic disturbance resulting from the loss of osmotic balance and ionic equilibrium.
- c) The nature of this phenomenon is a long term death of worms on the contrary of the rapid death of cells in coagulated necrosis.
- d) The importance of this, in fact has been demonstrated by a sequence of events that can eventually lead the worm to death (nuclear damage of cells) or back to regeneration, like was well demonstrated by Shaw & Erasmus (1987), recently.
- e) The host's immunological response is therefore what will decided the above directions for the final event.

ACKNOWLEDGEMENTS

This is to gratefully thank the assistance of Dr Marco Aurélio Canedo CPqAM – FIOCRUZ, for providing mice, and Rafael Ribeiro Padilha and Miss Allana E. Nascimento for the help in the EM techniques, under the auspices of the LIKA-JICA.

REFERENCES

- KHON, A.; SERAPIÃO, C. J.; KATZ, N. & DIAS, E. P., 1979. Ação da Oxamniquine sobre o *Schistosoma mansoni* em camundongos experimentalmente infectados. *Rev. Inst. Med. Trop. São Paulo*, 21: 217-227.
- KHON, A.; LOPEZ-ALVARES & KATZ, N., 1982. Transmission and scanning electron microscopical studies in the tegument of male *Schistosoma mansoni*, after oxamniquine treatment. *Ann. Parasitol. Paris*, 57: 285-291.
- MAGALHÃES-FILHO, A.; BEZERRA DE MELO, M. E. & TELES-PONTES, N., 1984. Granulomatous in mice liver for absorption of *Schistosoma mansoni* worms, after treatment with oxamniquine. *Ann. Acad. Sciences, São Paulo*, v. II: 119-127.
- MORRIS, G. P. & THEREADGOLD, L. T., 1968. Ultrastructure of tegument of the adult *Schistosoma mansoni*. *J. Parasitol.*, 54: 15-27.
- SHAW, M. K. & ERASMUS, D. A., 1983. *Schistosoma mansoni*: dose-related tegumental surface changes after treatment *in vivo* with praziquantel. *Z. Parasitenkd.*, 69: 643-653.
- SHAW, M. K. & ERASMUS, D. A., 1987. *Schistosoma mansoni*: structural damage and tegumental repair after *in vivo* treatment with praziquantel. *Parasitology*, 94: 243-254.
- SMITHERS, S. R.; TERRY, R. J. & HOCLEY, D. J., 1969. Host antigens in schistosomiasis. *Proc. Royal Society – Series B*, 171: 483-494.
- SOGANDARIS-BERNAL, F., 1976. Immunoglobulins attached to and in the integument of adult *Schistosoma mansoni*, Sambon 1907, from first infection of C F mice. *J. Parasitol.*, 62: 22-226.
- VOGE, M. & BUEDING, E., 1980. *Schistosoma mansoni*: tegumental surface alterations induced by subcurative doses of the schistosomicide amoscantate. *Exp. Parasitol.*, 50: 221-259.
- YONG, W. K., 1983. Acquisitions of Host proteins by the tegument of *Schistosoma mansoni* recovered from rats. *Z. Parasitenkd.*, 69: 53-60.