

Therapy of Tungiasis: a Double-blinded Randomized Controlled Trial with Oral Ivermectin

Jörg Heukelbach^{*/+}, Sabine Franck^{**}, Hermann Feldmeier^{*/**}

Departamento de Saúde Comunitária, Faculdade de Medicina, Universidade Federal do Ceará, Rua Prof. Costa Mendes 1608, 5º andar, 60430-140 Fortaleza, CE, Brasil *Fundação de Educação e Saúde Mandacaru, Fortaleza, CE, Brasil **Institute for Infection Medicine, Department of Microbiology, Charité University of Medicine, Berlin, Germany

Tungiasis is an ectoparasitosis causing considerable pathology in endemic areas. Standard therapy consists of removing the embedded parasite with a sterile needle. There is no effective chemotherapy at hand. To fill this gap, a double-blinded randomized controlled trial with oral ivermectin was conducted. A total of 54 individuals (27 in the placebo group, 27 in the ivermectin group) was followed up for seven days. They presented a total of 192 lesions. Patients received either ivermectin (300 µg/kg body weight at a single dose, repeated after 24 h) or placebo. Outcome measures included the clinical stage of lesion, presence of erythema, pain, itching, signs of viability of the parasite, and total lysis of flea. The ratio of fleas with total lysis per total number of fleas was slightly higher in the ivermectin group; however, this difference was not statistically significant. There was no significant difference in any of the other outcome measures between the treatment and the placebo group. The results show that oral ivermectin is without any clinically significant efficacy against embedded sand fleas at the dose given.

Key words: tungiasis - *Tunga penetrans* - therapy - ivermectin - randomized controlled trial - Brazil

Tungiasis, an ectoparasitosis caused by the penetration of the female sand flea *Tunga penetrans* into the epidermis, is endemic in South America, the Caribbean and sub-saharan Africa and a scourge for many resource-poor populations (Heukelbach et al. 2001). In Brazil, tungiasis occurs from the far north of the country to the state of Rio Grande do Sul in the south (Heukelbach et al. 2001). However, the disease is neglected by health care providers and the scientific community (Heukelbach et al. 2002, 2003b). By consequence, there are few valid data on the usefulness of chemotherapeutic interventions (Ade-Serrano et al. 1982, Heukelbach et al. 2003a).

Standard therapy of tungiasis consists of removing the embedded flea with a sterile needle and disinfection of the remaining sore (Heukelbach et al. 2001). Surgical extraction of the flea, though, is not an easy task, as it requires a skilled hand and good eye-sight. The procedure is painful for the patient and children often scream when their lesions are manipulated by a carer. If strict hygiene is not applied and appropriate instruments are not at hand (which is the rule in resource-poor settings and wholly impossible in children who may harbour more than a hundred fleas), attempts to remove the fleas often do more harm than good (Feldmeier et al. 2003). Hence, there is a clear need for a safe, simple and effective drug treatment, particularly in heavily infested individuals. One

case report suggests that oral ivermectin given at a single dose of 200 µg/kg body weight clears embedded sand fleas from the skin (Saraceno et al. 1999). Additionally, there are several anecdotal reports of health care providers about the efficacy of oral ivermectin for the treatment of tungiasis (Heukelbach, pers. commun.). To base these observations on a scientific rationale, we conducted a double-blinded randomized placebo-controlled trial with oral ivermectin.

PATIENTS AND METHODS

Patients were recruited from three shantytowns on the outskirts of Fortaleza (capital of the state of Ceará) where the disease is endemic, namely Morro de Sandra's, Favela das Placas, and Luxou. The areas are close one to another and share similar socio-economic characteristics. Infested individuals were identified with the help of community leaders of the respective shantytowns. Tungiasis was diagnosed and staged according to the recently developed Fortaleza classification (Eisele et al. 2003). To be eligible for the trial, an individual had to have at least one lesion in stage II or stage III, which corresponds to a developing female flea that has penetrated fully and a mature, egg-expelling flea, respectively (Eisele et al. 2003). The stage and the exact localization of each lesion were documented on a graphic record sheet. Individuals < 5 years of age, < 15 kg body weight, with chronic neurological or hepatic diseases as well as pregnant/breastfeeding women were not eligible for the trial.

To prevent confounding due to re-infestation, the patients were transferred to a mountain resort some 40 km away for a period of 8 days, a time period during which stage II lesions develop into stage III lesions (Eisele et al. 2003). Tungiasis has never been observed in the relatively cool and humid environment of the resort.

Patients were allocated to the ivermectin or placebo group by blocked randomization (blocks of six subjects

Financial support: Deutsches Komitee Ärzte für die Dritte Welt, Capes/Daad Probral academic exchange program, Solvay Farma S.A. (São Paulo, Brazil)

Corresponding author: Fax: +55-85-3278.3093. E-mail: samsa@mcanet.com.br

Received 2 August 2004

Accepted 14 October 2004

each). Patients, investigators and the auxiliary nurse were blinded with respect to the treatment given. None of the investigators involved in the design or realization of the trial had access to the code book before finalization of the trial. Coded ivermectin and placebo tablets were supplied by a pharmaceutical producer of ivermectin (Solvay Farma S.A., São Paulo, Brazil). Treatment consisted of two doses of 300 µg/kg body weight ivermectin or placebo given 24 h apart.

The patients were examined immediately before as well as once per day during six days after treatment. All clinical examinations were performed by the same investigator (SF). The lesions were examined thoroughly with a magnifying glass. The following variables were used as outcome measures and noted for each lesion: clinical stage of lesion according to the Fortaleza classification (Eisele et al. 2003), presence of erythema, pain, itching, total lysis of flea, and vital signs (flea's faeces, eggs, pulsation). Total lysis of the flea was defined as the clearance of an embedded flea or its carcass from the skin either by tissue repair mechanisms or by falling out. Faeces, eggs and pulsation of the embedded fleas were identified when present and considered as clear indicators for the flea's viability (Eisele et al. 2003). Before examination, the feet were washed with tap water. Patients were asked for the presence of itching and pain associated with embedded sand fleas and, if present, to grade their complaints into weak, moderate or severe for each of the lesions. Swallowing of ivermectin/placebo tablets was controlled. Adverse events were assessed at each follow-up examination.

To estimate the sample size, a clinically significant efficacy was defined as a difference of the ratios of fleas with total lysis per total number of fleas of 0.3 in the ivermectin group as compared to 0.6 in the placebo group at any of the follow-up examinations. Conclusively, 63 viable lesions in each treatment arm are necessary to detect a clinical difference with a power of 90 to 95% significance level. Considering possible loss to follow-up, in each group, 30 patients were randomized with a total of 192 viable tungiasis lesions.

Data were entered twice into a database using version 6.04d of the Epi Info software package (Centers for Disease Control and Prevention, Atlanta, GA) and checked for errors that could have occurred during their entry. In the analysis, morphological aspects of the lesions were

compared in each treatment group rather than comparing the outcome measures in individual patients. Relative frequencies were compared between treatment groups using the chi-squared test. The Wilcoxon rank sum test was used to compare ordinal data between the two groups.

RESULTS

Descriptive characteristics of the study groups are depicted in the Table. Both treatment arms consisted of 30 patients. Six patients (three of the ivermectin group and of the placebo group, respectively) were lost to follow-up as they felt homesick and asked to leave the mountain resort after two days. These were excluded from data analysis. Parasite load of those lost to follow-up was similar to the remaining study participants. There were no drop-outs in follow-up in the remaining 54 study participants. The total number of lesions followed up was 103 in the ivermectin arm and 89 in the placebo arm. There was no statistically significant difference in age ($p = 0.5$) or the number of lesions per patient between the treatment groups ($p = 0.8$). There were more males in the placebo group; however, the difference was not statistically significant ($p = 0.06$).

The Figure presents the proportion of lesions showing total lysis of the flea in relation to the total number of lesions in each treatment arm. The ratio was slightly higher in the ivermectin group for the days of follow-up indicating some insecticidal activity of the drug. However, the difference never gained statistical significance ($p > 0.3$ in all cases).

Both treatment groups were also compared with respect to the other outcome measures such as itching and pain but again there was no statistically significant difference between the two groups at any time point of the follow-up.

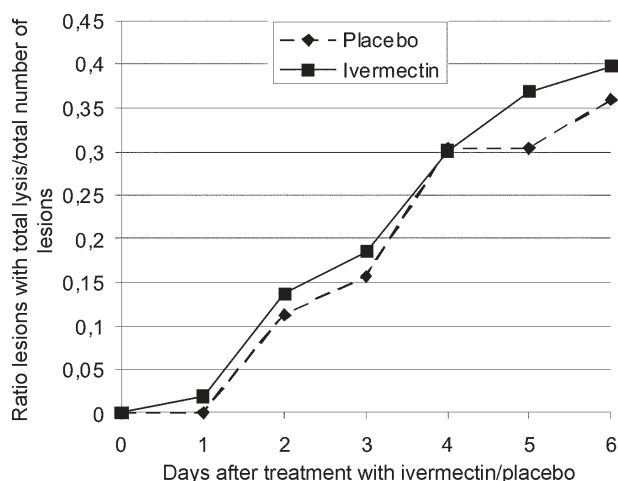
Adverse events were reported in 12 cases. In the treatment group 3 patients complained of headache, 2 of abdominal pain and 1 of sore throat. In the placebo group, 3 patients complained of headache and 3 of itching.

DISCUSSION

Ivermectin is a comparatively cheap drug, and its use has been suggested in individuals infected with intestinal helminths and ectoparasites when specific diagnoses are difficult to establish due to lack of appropriate health infrastructure (Heukelbach & Feldmeier 2004, Heukelbach

TABLE
Characteristics of study participants

	Ivermectin group	Placebo group
Number of individuals randomized	30	30
Number of individuals followed-up for 6 days	27	27
Age (median and range)	12 (5-17)	12 (6-34)
Sex (males/females)	11/16	18/9
Number of lesions per patient (median and range)	3 (1-10)	3 (1-10)
Total number of lesions before treatment:		
Stage II	29	30
Stage III	74	59
Total number of lesions evaluated	103	89



Ratio of lesions with total lysis of the ectoparasite/total number of lesions in the placebo (n = 89) and ivermectin (n = 103) group.

et al. 2004). A few open and blinded trials have shown a high efficacy of the drug for scabies (Chouela et al. 1999, Madan et al. 2001, Brooks & Grace 2002, Buffet & Dupin 2003), head lice (Glaziou et al. 1994), and cutaneous larva migrans (Caumes 2003) with no significant adverse events. Ivermectin is contraindicated for children younger than five years of age or less than 15 kg body weight because of the ongoing uncertainty of possible neuro-toxicity of the drug and in view of the not yet fully developed blood-brain barrier in small children (Edwards 2003). However, preliminary data indicate that ivermectin is excellently tolerated also by children of less than five years of age (del Mar Saez-De-Ocariz et al. 2002). Thus, such a broad-spectrum antiparasiticide drug is of considerable benefit in mass treatment campaigns in populations concomitantly infected with various species of intestinal helminths and ectoparasites (Heukelbach et al. 2004).

Using an appropriate study design, we were unable to confirm anecdotal reports on the efficacy of ivermectin in tungiasis (Saraceno et al. 1999). A previous trial reported some efficacy of topical ivermectin as compared to a topical placebo lotion and a control group without any treatment (Heukelbach et al. 2003a). In this study, the relatively small effect of the drug on sand fleas was explained by the type of application: it was assumed that not sufficient quantity of the active compound would reach the embedded flea by topical application. However, as in our trial the dose given orally (2 x 300 µg/kg body weight) was considerably higher than the dose administered for intestinal helminthiasis, scabies, pediculosis, and cutaneous larva migrans (usually 200 µg/kg body weight) we think that even a higher dose would not significantly improve the efficacy of ivermectin on embedded sand fleas.

The results of our study underline the importance of randomized controlled trials to conclude on the therapeutic efficacy of drugs. In northeast Brazil many dermatologists claim a good efficacy of ivermectin in tungiasis and support their notion by anecdotal observations. In fact,

hitherto a single published case report suggests an effect of ivermectin (Saraceno et al. 1999). Similarly, other authors suggest oral thiabendazole to be effective against embedded sand fleas (Valença et al. 1972, Cardoso 1981). Probably the effect observed by these authors is due to the fact that patients were severely infested and were hospitalized and thereby taken out from the endemic area, consequently preventing re-infestation. According to their developmental stage, fleas will die anyway after two to three weeks independently whether the patient is treated or not (Eisele et al. 2003).

The only randomized controlled trial in tungiasis with an oral drug has been realized more than 20 years ago with niridazole, an anti-schistosomal compound with severe neurological adverse events, which has been taken from the market since long (Ade-Serrano et al. 1982). In this study, the therapeutic efficacy of niridazole was claimed to be very good. However, the outcome measures were not well defined and the study showed other methodological problems which limit the interpretation of results.

The reduced prevalence of tungiasis observed in an endemic community after selective mass treatment with ivermectin may be explained by seasonal variation in transmission dynamics rather than intrinsic activity of the drug on *T. penetrans* (Heukelbach et al. 2004).

Our study did not show any significant difference between oral ivermectin and a placebo at the dose chosen. This may be attributable to the relative small number of patients treated, however the study size was sufficient to detect a clinical significant difference between treatment and placebo group with a high power.

Recently, a small case series using a natural repellent on the basis of coconut and jojoba oil showed an impressive regression of clinical pathology in patients severely infested by prevention of re-infection (Schwalfenberg et al. 2004). It is conceivable that in endemic communities the use of an effective repellent would be a better approach to reduce tungiasis-associated morbidity than treatment after infestation has occurred.

ACKNOWLEDGEMENTS

Ivermectin and placebo were provided free of charge by Solvay Farma, São Paulo, Brazil. To Vania Andrade dos Santos and Antonia Valéria Assunção Santos. The data form part of a medical thesis by SF.

REFERENCES

- Ade-Serrano MA, Olomolehin OG, Adewunmi A 1982. Treatment of human tungiasis with niridazole (Ambilhar): a double-blind placebo-controlled trial. *Ann Trop Med Parasitol* 76: 89-92.
- Brooks PA, Grace RF 2002. Ivermectin is better than benzyl benzoate for childhood scabies in developing countries. *J Paediatr Child Health* 38: 401-404.
- Buffet M, Dupin N 2003. Current treatments for scabies. *Fundam Clin Pharmacol* 17: 217-225.
- Cardoso A 1981. Generalized tungiasis treated with thiabendazole. *Arch Dermatol* 117: 127.
- Caumes E 2003. Treatment of cutaneous larva migrans and *Toxocara* infection. *Fundam Clin Pharmacol* 17: 213-216.
- Chouela EN, Abeldano AM, Pellerano G, La Forgia M, Papale RM, Garsd A, Balian MC, Battista V, Poggio N 1999.

- Equivalent therapeutic efficacy and safety of ivermectin and lindane in the treatment of human scabies. *Arch Dermatol* 135: 651-655.
- del Mar Saez-De-Ocariz M, McKinster CD, Orozco-Covarrubias L, Tamayo-Sanchez L, Ruiz-Maldonado R 2002. Treatment of 18 children with scabies or cutaneous larva migrans using ivermectin. *Clin Exp Dermatol* 27: 264-267.
- Edwards G 2003. Ivermectin: does P-glycoprotein play a role in neurotoxicity? *Filaria J* 2 (Suppl. 1): S8.
- Eisele M, Heukelbach J, van Marck E, Mehlhorn H, Meckes O, Franck S, Feldmeier H 2003. Investigations on the biology, epidemiology, pathology and control of *Tunga penetrans* in Brazil: I. Natural history of tungiasis in man. *Parasitol Res* 90: 87-99.
- Feldmeier H, Eisele M, Saboia-Moura RC, Heukelbach J 2003. Severe tungiasis in underprivileged communities: case series from Brazil. *Emerg Infect Dis* 9: 949-955.
- Glaziou P, Nguyen LN, Moulia-Pelat JP, Cartel JL, Martin PM 1994. Efficacy of ivermectin for the treatment of head lice (*Pediculosis capitis*). *Trop Med Parasitol* 45: 253-254.
- Heukelbach J, Feldmeier H 2004. Ectoparasites – The underestimated realm. *Lancet* 363: 889-891.
- Heukelbach J, Mencke N, Feldmeier H 2002. Cutaneous larva migrans and tungiasis: the challenge to control zoonotic ectoparasitoses associated with poverty. *Trop Med Int Health* 7: 907-910.
- Heukelbach J, de Oliveira FA, Hesse G, Feldmeier H 2001. Tungiasis: a neglected health problem of poor communities. *Trop Med Int Health* 6: 267-272.
- Heukelbach J, Eisele M, Jackson A, Feldmeier H 2003a. Topical treatment of tungiasis: a randomized, controlled trial. *Ann Trop Med Parasitol* 97: 743-749.
- Heukelbach J, van Haeff E, Rump B, Wilcke T, Moura RC, Feldmeier H 2003b. Parasitic skin diseases: health care-seeking in a slum in north-east Brazil. *Trop Med Int Health* 8: 368-373.
- Heukelbach J, Winter B, Wilcke T, Muehlen M, Albrecht S, Oliveira FAS, Kerr-Pontes LR, Liesenfeld O, Feldmeier H 2004. Selective mass treatment with ivermectin to control intestinal helminthiases and parasitic skin diseases in a severely affected population. *Bull WHO* 82: 563-571.
- Madan V, Jaskiran K, Gupta U & Gupta DK 2001. Oral ivermectin in scabies patients: a comparison with 1% topical lindane lotion. *J Dermatol* 28: 481-484.
- Saraceno EF, Bazarra MLG, Calviello RC, Quaranta MA, Mirarchi P & Sánchez GF 1999. Tungiasis: tratamiento de un caso con ivermectina. *Arch Argent Dermatol* 49: 91-95.
- Schwalfenberg S, Witt LH, Kehr JD, Feldmeier H, Heukelbach J 2004. Prevention of tungiasis using a biological repellent: a small case series. *Ann Trop Med Parasitol* 98: 89-94.
- Valença ZO, Cardoso AEC, Cardoso AS 1972. Tunguiase generalizada: relato de dois casos tratados com thiabendazol. *Dermatologia Ibero-Latino-Americana* 3: 375-378.