

## REACTIVATION OF CHAGAS' DISEASE SUCCESSFULLY TREATED WITH BENZNIDAZOLE IN A PATIENT WITH ACQUIRED IMMUNODEFICIENCY SYNDROME

SÉRGIO DE A. NISHIOKA<sup>†</sup>; MARCELO S. FERREIRA; ADEMIR ROCHA; MARCIUS K. N. BURGARELLI; ARNALDO M. SILVA; MARIA IRMA S. DUARTE\* & FERNANDO C. SCHMITT\*\*

Centro de Ciências Biomédicas, Universidade Federal de Uberlândia, Av. Pará 1720, 38400-902 Uberlândia, MG, Brasil \*Faculdade de Medicina, Universidade de São Paulo, São Paulo, Brasil \*\*Faculdade de Medicina, UNESP, Botucatu, SP, Brasil

Reactivation of chronic Chagas' disease in patients with human immunodeficiency virus (HIV) infection has been recognized recently (M. Del Castillo et al., 1990, *Am. J. Med.*, 88: 693-694; M. S. Ferreira et al., 1991, *Am. J. Trop. Med. Hyg.*, 45: 723-727; P. Gallo et al., 1992, *Arq. Neuropsiquiatr.*, 50: 375-377; D. Gluckstein et al., 1992, *Am. J. Med.*, 92: 429-432; D. Oddó et al., 1992, *Hum. Pathol.*, 23: 41-44; S. Rosemberg et al., 1992, *Neurology*, 42: 640-642; A. Rocha et al., 1993, *Rev. Inst. Med. Trop. São Paulo*, 35: 205-208), but most patients reported so far have died before or just after the treatment was instituted. An heterosexual hemophiliac Chilean patient with two intracranial masses diagnosed histologically as Chagas' disease survived for at least one year after being treated with itraconazole for 43 days (D. Oddó et al., *loc. cit.*). An Argentine patient with hemophilia type B had a central nervous system tumor-like lesion, and survived for more than three months after it was resected and he was given nifurtimox for four weeks (M. Del Castillo et al., *loc. cit.*). A 26-year-old Brazilian woman with a localized lesion at the midbrain was treated with benznidazole and survived for two months (Gluckstein et al., *loc. cit.*). At least the latter two patients had already died, but no post-mortem examination was performed.

We report the case of a patient with reactivation of Chagas' disease manifested as meningoencephalitis and myocarditis who survived for nearly three months after treatment with benznidazole, died from other reasons,

and had no evidence of the trypanosomiasis on post-mortem examination.

A bisexual HIV positive 33-year-old male was admitted to the hospital in November 7th, 1991, complaining of fever, malaise, vomiting, headache and diarrhea for five days, and weight loss of 6 kg in one month. He had a diagnosis of asymptomatic chronic Chagas' disease, made by a positive serum indirect immunofluorescence assay (IFA) for *Trypanosoma cruzi*, and a normal electrocardiogram (ECG). On physical examination he had a temperature of 39.5 °C, a pulse rate of 100 beats per minute, and his blood pressure was 120/80 mmHg. Oral candidiasis and mental confusion were noticed. Lung, heart, and abdominal examinations were normal. No lymphadenopathy was found.

The patient had an hematocrit of 42%, a white cell count of 3300 per mm<sup>3</sup> with 60% neutrophils, 6% band forms, 32% lymphocytes and 2% monocytes, and a platelet count of 132,000 per mm<sup>3</sup>. The CD4 count was 382/mm<sup>3</sup>. Direct examination of a Giemsa stained blood smear revealed many trypomastigote forms of *T. cruzi* (Fig. 1).

Cerebrospinal fluid (CSF) taken in November 11th revealed 15 cells per mm<sup>3</sup> (98% lymphocytes and 2% neutrophils), a protein level of 51 mg% and a glucose level of 34 mg%. Direct examination also revealed many trypomastigotes of *T. cruzi*. Results of immunofluorescent analysis for Chagas' disease and for toxoplasmosis in the CSF were negative.

An ECG showed sinus rhythm, first degree atrio-ventricular block, and left anterior hemiblock. An echocardiogram showed

<sup>†</sup>Corresponding author.

Received 8 February 1993.

Accepted 26 April 1993.

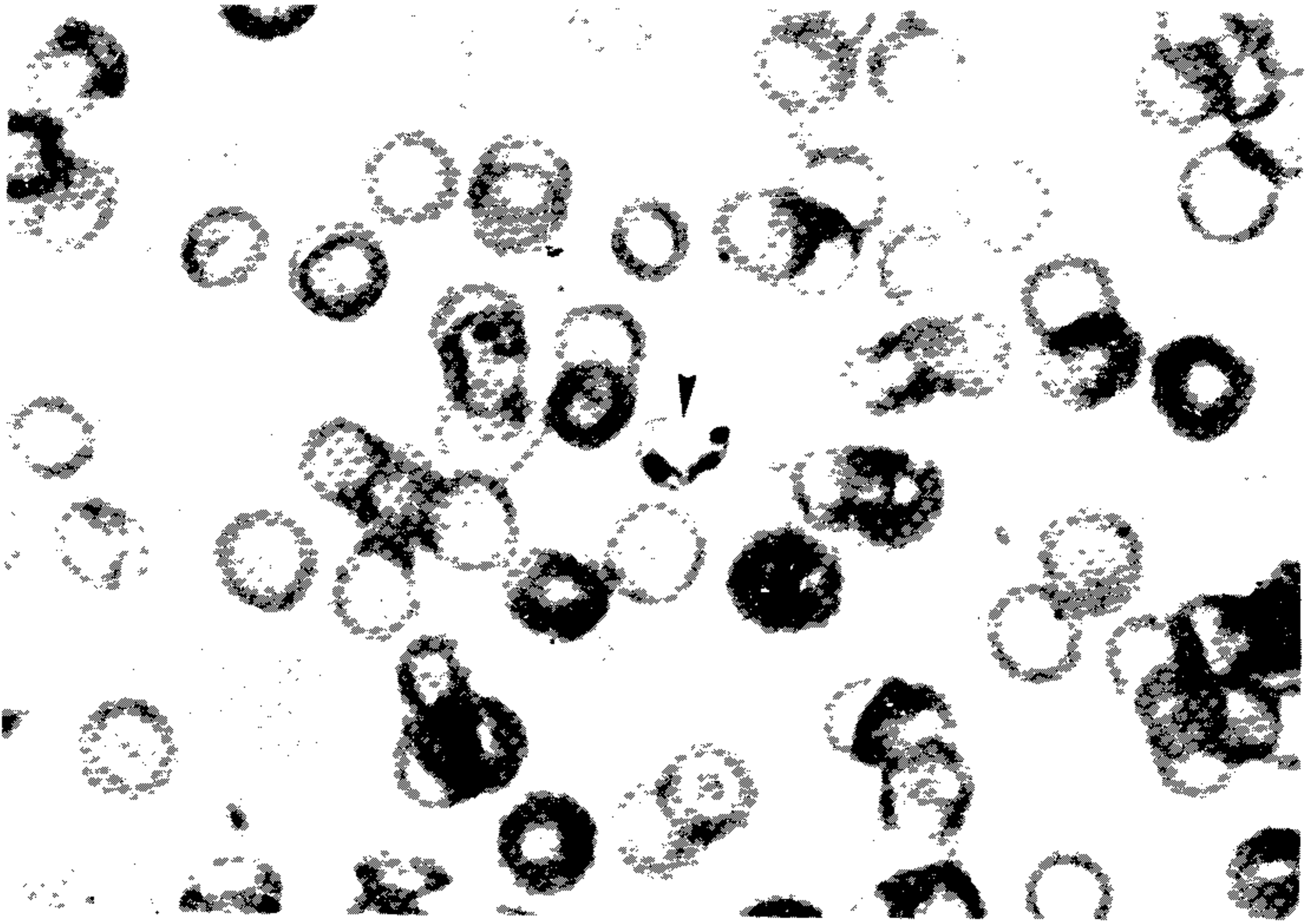


Fig. 1: trypomastigote of *Trypanosoma cruzi* in a blood smear (Arrow) (Giemsa, X 100).

hypokinesia of the left ventricle. A computed tomographic (CT) scan of the brain showed a subcortical left temporo-occipital pseudotumoral lesion, that enhanced after intravenous injection of contrast material (Fig. 2).

A diagnosis of reactivation of Chagas' disease was made.

Treatment with oral benznidazole 8 mg/kg per day was instituted, and maintained for 80 days. The patient had initially deterioration of the neurological picture, progressing to coma. An ECG four days later showed atrial fibrillation and persistence of the fascicular block. The patient developed signs of cardiac failure, and treatment with digital and prednisone 60 mg per day was successfully instituted.

Two weeks after the beginning of the treatment trypomastigotes were not found neither in blood nor CSF. Fever and the CSF and electrocardiographic abnormalities disappeared. The patient had slow improvement of the mental status, but he remained obtunded. A control CT scan of the brain four weeks later was normal. When he started walking ataxic gait was noticed.

After 80 days administration of benznidazole was stopped; three days before zidovudine had become available and had been instituted. Twelve days later the patient developed a nosocomial bacteremia by *Campylobacter fetus* ssp. jejuni and *Staphylococcus aureus*, and died.

Post-mortem examination revealed in the central nervous system: infiltrate of lymphocytes and monocytes on the leptomeninges and Virchow-Robin spaces; acute vasculitis and thrombosis (immunohistochemical test positive for *Herpes simplex* virus) in an area of 1.5 cm of diameter in the frontal lobe; mesencephalic cytomegalovirus disease, confirmed immunohistochemically; periventricular cysts of *T. gondii* in the brainstem; there was no evidence of *T. cruzi* amastigote nests. There was non-specific chronic epi, myo and endocarditis in the ventricles, with no evidence of amastigotes of *T. cruzi*. There was also no immunohistochemical evidence of *T. cruzi* antigen in brain and heart tissues. There was focal necrosis, infiltrate of lymphocytes and monocytes and many cells with basophilic intranuclear inclusion bodies (cytomegalovirus) in the adrenals; *Pneumocystis carinii* and bacterial pneumonia were also noted.



Fig. 2: computed tomographic scan of the brain showing a subcortical left temporo-occipital pseudotumoral lesion, enhanced after intravenous injection of contrast (Arrow).

Several cases of reactivation of Chagas' disease in HIV positive patients, manifested as meningoencephalitis and/or myocarditis have already been reported in the literature. Many more are expected to be diagnosed in the near future. As it is a blood-borne disease, American trypanosomiasis can be transmitted within the drug addict population, although to our knowledge this has not been reported so far.

Treatment is indicated for patients in the acute phase of Chagas' disease and for immunocompromised patients with reactivation of the disease (Z. Brener, 1984, *Mem. Inst. Oswaldo Cruz*, 79, *Suppl.*: 149-151). Benznidazole or nifurtimox are the drugs of choice (Z. Brener, *loc. cit.*), itraconazole being a promising alternative (R. E. McCabe et al., 1986, *Am. J. Trop. Med. Hyg.*, 35: 280-284). Effectiveness of the treatment in the indeterminate and chronic phases of the disease is questionable. Our patient was given a high dose of

benznidazole without important side effects but a mild rash, possibly because he was also receiving corticosteroids. The treatment was successful, as can be noted by the clinical improvement, the disappearance of the parasite from the blood and CSF, the normal control CT scan, and the absence of evidence of *T. cruzi* infection in the brain and myocardium in the post-mortem examination.

An important aspect of this case is that the patient had associated central nervous system infections that remained undetected during life. It is possible that the *T. gondii*, CMV and *H. simplex* encephalitides were late opportunistic infections in an already immunocompromised patient, as the patient had a normal CT scan of the brain during treatment.

Clinicians in all the Americas must be aware of reactivation of Chagas' disease in the differential diagnosis of fever, meningoence-

phalitis and/or myocarditis in HIV positive patients. Early diagnosis and treatment are likely to improve the prognosis of an opportunistic infection that so far has had a poor outcome in AIDS patients. Whether a mainte-

nance dose of benznidazole, nifurtimox, or other less toxic drugs like itraconazole or allopurinol (R. H. Gallerano et al., 1990, *Am. J. Trop. Med. Hyg.*, 43: 159-166) is necessary or not is a question to be answered.